



Mortality Due to Tyzzer's Disease of Muskrats (*Ondatra zibethicus*) in Northern Ohio, USA

Authors: Grear, Daniel A., Lankton, Julia S., Zaleski, Sara, Witt, Mark, and Lorch, Jeffrey M.

Source: Journal of Wildlife Diseases, 55(4) : 982-985

Published By: Wildlife Disease Association

URL: <https://doi.org/10.7589/2018-11-267>

BioOne Complete (complete.BioOne.org) is a full-text database of 200 subscribed and open-access titles in the biological, ecological, and environmental sciences published by nonprofit societies, associations, museums, institutions, and presses.

Your use of this PDF, the BioOne Complete website, and all posted and associated content indicates your acceptance of BioOne's Terms of Use, available at www.bioone.org/terms-of-use.

Mortality due to Tyzzer's Disease of Muskrats (*Ondatra zibethicus*) in Northern Ohio, USA

Daniel A. Grear,^{1,3} Julia S. Lankton,¹ Sara Zaleski,² Mark Witt,² and Jeffrey M. Lorch¹ ¹US Geological Survey, National Wildlife Health Center, 6006 Schroeder Road, Madison, Wisconsin 53711, USA; ²Ohio Department of Natural Resources, Division of Wildlife, 952 Lima Avenue, Findlay, Ohio 45840, USA; ³Corresponding author (email: dgrear@usgs.gov)

ABSTRACT: In 2017, we investigated a mortality event of muskrat (*Ondatra zibethicus*) in north-west Ohio, US, and determined the causes of death to be from Tyzzer's disease due to *Clostridium piliforme* and *Klebsiella pneumoniae* septicemia. The gross presentation resembled tularemia, which highlighted the importance of a complete diagnostic investigation.

Muskrats (*Ondatra zibethicus*) are common wetland mammals that play ecologic, wetland management, and economic roles. Over the last several decades, North American muskrat populations have been in decline, possibly due to several causes (Ahlers and Heske 2017). Disease does not appear to be the ultimate factor in these declines, but diseases are ever-present and could compound primary stressors (Pacioni et al. 2015).

Between 10 November and 22 November 2017, 18 dead muskrats were found at a managed wetland near Port Clinton, Ohio, US (41°31'N, 82°59'W). The surrounding landscape consisted of managed wetlands in public and private holdings that were characterized by emergent marshes and flooded row crops (approximately 250 ha), with some commercial development, and bounded by Lake Erie and the Portage River. Daytime high temperatures ranged from –1 C to 11 C and low temperatures were –5 C to 3 C at night. No major precipitation events occurred prior to or during the mortality; however, there was an 11 C temperature drop within a 24-h period when the carcasses were initially observed. No other neighboring property owners reported muskrat mortality; however, some mortality may have gone undetected.

We performed cause-of-death examinations on five muskrats including gross necropsy, histopathology, bacterial culture, and parasitology.

For histopathology, tissue samples (brain, heart, lung, liver, kidney, spleen, lymph node, adrenal gland, salivary gland, testis, adipose tissue, skeletal muscle, trachea, pancreas, urinary bladder, esophagus, stomach, and intestinal tract) were fixed in 10% neutral buffered formalin, dehydrated, embedded in paraffin, sectioned at 5 µm, and stained with H&E for light microscopy (Luna 1968). Liver sections were also stained with Brown and Hopps Gram stain or modified Steiner's stain.

Body condition of the five muskrats varied from poor, with depletion of all fat reserves, to good, with abundant subcutaneous and visceral fat. All five animals had from pinpoint to 1-mm diameter white or red foci throughout the liver (Fig. 1a). One animal (no. 001) also had a moderately enlarged right cervical lymph node and a mildly enlarged spleen.

Microscopically, the livers of all animals contained similar areas of random to massive coagulative necrosis. In 4/5 animals (002–005), adjacent hepatocytes multifocally contained packets of long, silver-positive bacterial rods (Fig. 1b). These bacteria were non-staining on both H&E and Gram stain. In one animal (001), short Gram-negative bacterial rods were within subcapsular hepatocellular necrosis in one section and no silver-positive rods were seen in any section. This animal also exhibited characteristics of septicemia: bacterial meningoencephalitis with malacia and neuronal necrosis, necrotizing bacterial lymphadenitis with abscessation, and splenic necrosis with bacteria. Additional microscopic findings in the remaining four animals included fat necrosis on the epicardium, renal capsule, pancreas, or mesentery and fibrinoid vascular necrosis in the liver (Table

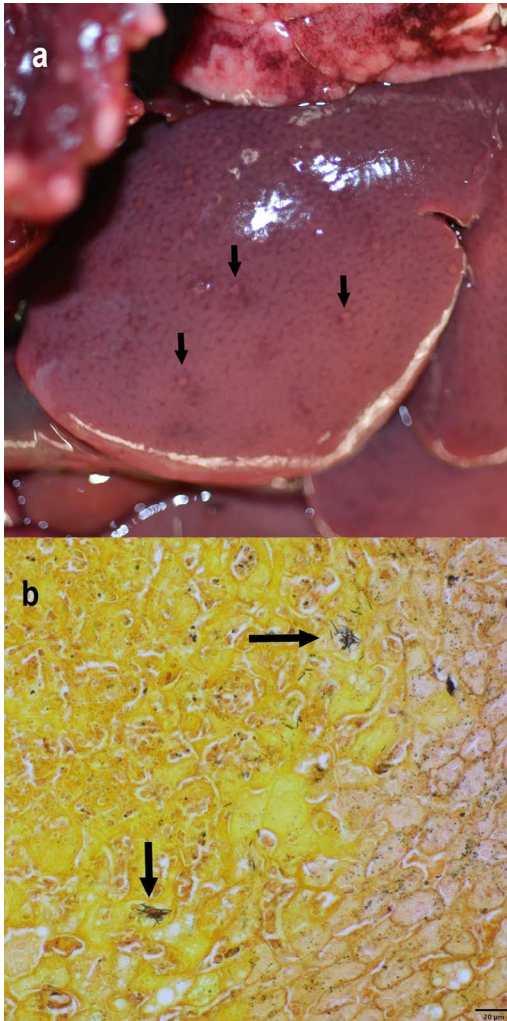


FIGURE 1. Liver from one of five muskrats (*Ondatra zibethicus*) necropsied following a mortality event that occurred between 10 November and 22 November 2017 in Ottawa County, Ohio, USA. (a) All necropsied animals had from pinpoint to 1-mm diameter white or red foci disseminated throughout the liver (arrows). (b) White foci noted grossly corresponded with areas of coagulative necrosis. Hepatocytes at the periphery of necrotic areas multifocally contained bundles of silver-positive bacterial rods (arrows). Modified Steiner's stain.

1). Autolysis interfered with the microscopic examination of the intestinal tract of all animals.

Liver from all five muskrats, lungs from three muskrats, and lymph node from one muskrat were surface-sterilized by flaming and cultured on tryptic soy agar with 5%

TABLE 1. Relevant gross, microscopic, molecular, and microbiologic findings in muskrat (*Ondatra zibethicus*) carcasses examined.

Specimen	Liver pinpoint foci	Liver pathology	Other pathology	Silver-positive rods	Gram-negative rods	<i>Klebsiella pneumoniae</i> culture growth	<i>Clostridium piliforme</i> nested PCR detection	<i>Francisella tularensis</i> PCR detection
001	Yes	Coagulative necrosis	Septicemia; bacterial meningoencephalitis; bacterial lymphadenitis; splenic necrosis	No	Yes	Yes	No	No
002	Yes	Coagulative necrosis	Fat necrosis	Yes	No	No	Yes	Not tested
003	Yes	Coagulative necrosis	Fat necrosis	Yes	No	No	Yes	Not tested
004	Yes	Coagulative necrosis; vascular necrosis	Fat necrosis	Yes	No	Yes	Yes	No
005	Yes	Coagulative necrosis	Fat necrosis	Yes	No	No	Yes	Not tested

sheep blood at 37 C. Isolated bacteria were identified by sequencing a portion of the 16S rRNA gene (Shearn-Bochsler et al. 2018).

Most bacteria recovered in culture were inconsistent between animals and likely represented postmortem colonizers (i.e., *Arthrobacter* sp. [n=1], *Buttiauxella* sp. [n=1], *Carnobacterium* sp. [n=1], *Serratia* sp. [n=1], *Streptococcus* sp. [n=2]). *Klebsiella pneumoniae* was grown from the lung, liver, and lymph node of the muskrat diagnosed with a Gram-negative bacterial septicemia. Several colonies of *K. pneumoniae* were also recovered from the liver of a second muskrat (Table 1).

Based on the characteristic bacterial silver-positive rods on histopathology, we screened liver from all five muskrats for the presence of *Clostridium piliforme* using a nested PCR, with 4/5 being PCR-positive (Niepceon and Licois 2010). Sequencing of the amplicons confirmed the presence of *C. piliforme*. The sequences were 100% identical to one another and 98–99% identical to sequences for *C. piliforme* in GenBank across the approximately 700-nucleotide region examined (GenBank accession nos. MH357836–MH357839). Portions of livers with lesions from two animals tested PCR negative for *Francisella tularensis*, and we did not pursue additional molecular testing for tularemia because the diagnostic findings consistently indicated *C. piliforme* and *Klebsiella* etiologies (Versage et al. 2003; Table 1).

Tyzzler's disease is rarely reported in muskrats or other wildlife (Wobeser 2001; Wobeser et al. 2009), and infectious diseases have not emerged as a significant threat to muskrats during a multi-decade population decline in the US (Ahlers and Heske 2017). Tyzzler's disease is sporadically reported in domestic animals and farmed wildlife but does not appear to have human health impacts (Wobeser 2001). However, the initial presentation of the disease and epizootic nature of the muskrat mortality event stresses the importance of screening for Tyzzler's disease, as well as to rule out zoonotic diseases with similar gross pathology and epidemiology, such as tularemia (caused by *F. tularensis*; Mörner and Addison 2001). We did not see

other lesions commonly reported in Tyzzler's disease, such as myocardial necrosis and necrotizing typhlitis (Wobeser et al. 1978), although autolysis interfered with full evaluation of the intestinal tract.

Tyzzler's disease mortality has been documented in North American muskrats since at least 1947 (Wobeser et al. 1979), and the disease may be underreported as the pathogen is thought to be common in the environment (Wobeser 2001; Wobeser et al. 2009). However, the few reports are not sufficient to make inference about epidemiology or the impact of Tyzzler's disease in muskrats. Ahlers and Heske (2017) presented hypotheses to explain long-term muskrat declines, several of which included mechanisms likely to result in physiologic stress. Such stress may predispose muskrats to developing Tyzzler's disease (Wobeser 2001) and, thus, *C. piliforme* may be a secondary disease risk in muskrat populations already in decline due to other stressors. In the current case report, one out of the five muskrats lacked evidence of *C. piliforme* infection but had septicemia caused by *K. pneumoniae*, another opportunistic pathogen. We therefore encourage furbearer management to consider the potential impact of both primary and secondary infectious diseases, especially where muskrat populations are under nondisease stress.

We thank Mike Sweeney for reporting the muskrat mortalities to the Ohio Division of Wildlife and for allowing the collection of carcasses from his property. We acknowledge D. Johnson, S. Steinfeldt, D. Tunseth, B. Berlowski-Zier, and others at the US Geological Survey, National Wildlife Health Center for technical support. The data produced in this research are available from the Wildlife Health Information Sharing Partnership at <https://www.nwhc.usgs.gov/whispers/160493>. The use of trade, product, or firm names is for descriptive purposes only and does not imply endorsement by the US Government.

LITERATURE CITED

- Ahlers AA, Heske EJ. 2017. Empirical evidence for declines in muskrat populations across the United States. *J Wildl Manage* 81:1408–1416.

- Luna LG. 1968. *Manual of histologic staining methods of the Armed Forces Institute of Pathology*. 3rd Ed. McGraw-Hill, New York, New York, 258 pp.
- Mörner T, Addison E. 2001. Tularemia. In: *Infectious diseases of wild mammals*, Williams ES, Barker IK, editors. Iowa State University Press, Ames, Iowa, pp. 303–312.
- Niepceron A, Licois D. 2010. Development of a high-sensitivity nested PCR assay for the detection of *Clostridium piliforme* in clinical samples. *Vet J* 185: 222–224.
- Pacioni C, Eden P, Reiss A, Ellis T, Knowles G, Wayne AF. 2015. Disease hazard identification and assessment associated with wildlife population declines. *Ecol Manag Restor* 16:142–152.
- Shearn-Bochsler V, Schulz JL, Dobbs RC, Lorch JM, Waddle JH, Grear DA. 2018. Novel dermatophilosis and concurrent amyloidosis in sanderlings (*Calidris alba*) from Louisiana, USA. *J Wildl Dis* 54:189–192.
- Versage JL, Severin DDM, Chu MC, Petersen JM. 2003. Development of a multitarget real-time TaqMan PCR assay for enhanced detection of *Francisella tularensis* in complex specimens. *J Clin Microbiol* 41: 5492–5499.
- Wobeser G. 2001. Tyzzer's disease. In: *Infectious diseases of wild mammals*, Williams ES, Barker IK, editors. Iowa State University Press, Ames, Iowa, pp. 510–513.
- Wobeser G, Campbell GD, Dallaire A, McBurney S. 2009. Tularemia, plague, yersiniosis, and Tyzzer's disease in wild rodents and lagomorphs in Canada: A review. *Can Vet J* 50:1251–1256.
- Wobeser G, Hunter DB, Daoust PY. 1978. Tyzzer's disease in muskrats: Occurrence in free-living animals. *J Wildl Dis* 14:325–328.

Submitted for publication 6 November 2018.

Accepted 9 February 2019.