



---

## SEAL POX

Authors: WILSON, T. M., CHEVILLE, N. F., and KARSTAD, L.

Source: Bulletin of the Wildlife Disease Association, 5(4) : 412-418

Published By: Wildlife Disease Association

URL: <https://doi.org/10.7589/0090-3558-5.4.412>

## SEAL POX

### Case History

In March, 1969, a captive 1-year-old female California sea lion (*Zalophus californianus*) was submitted to the Section of Wildlife Diseases, Ontario Veterinary College, for necropsy. The animal had died after a 1 week illness characterized by anorexia and respiratory distress. Gross and histopathological examination of this sea lion, including bacteriological and parasitological examination, indicated verminous pneumonia as a primary cause of death.

External examination of the carcass revealed multiple elevated growths which were most numerous about the head and neck but did occur over the entire body surface. These growths were round or oval, had a broad base, were elevated above the skin surface approximately 0.5

to 1.5 cm and were approximately 0.5 to 2 cm in diameter. Generally, the growths were solitary but in some areas they were confluent, especially about the head and neck. The cut surface of the nodule revealed it to have a grey-white epithelium and a scirrhous, white dermis (Fig. 1).

Clinical examination of five other California sea lions at the aquarium revealed that three recently purchased juveniles had skin lesions which were identical in gross appearance and distribution to the lesions described in this report. The two remaining adult sea lions had no gross evidence of skin nodules but early in captivity at the aquarium they had developed skin nodules which had completely regressed.

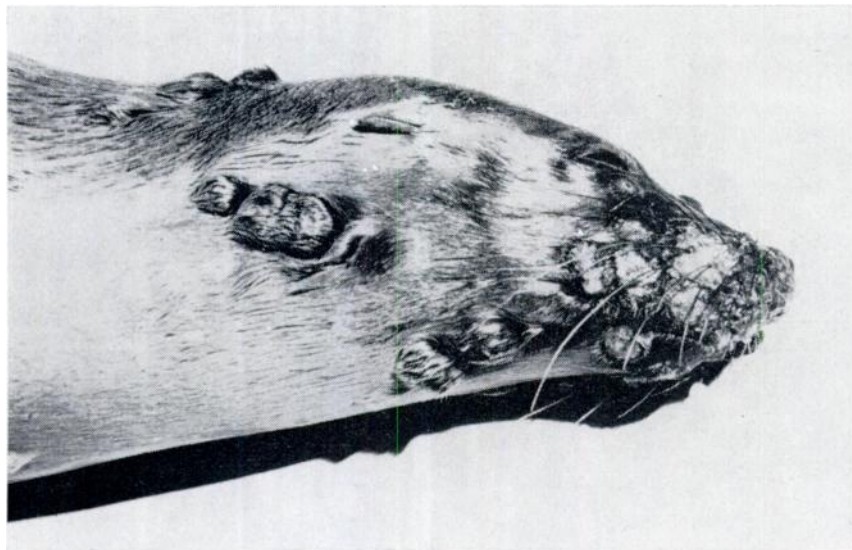
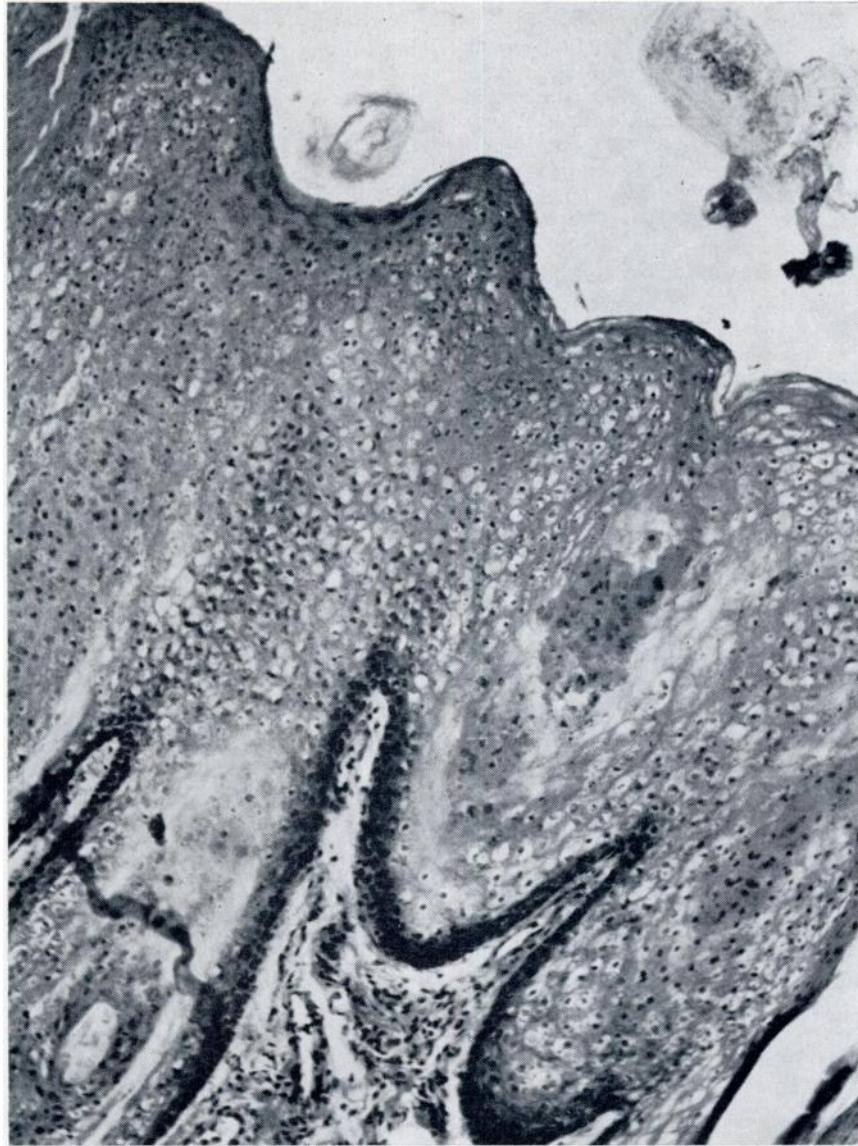


FIGURE 1. *The distribution of pox lesions about the head and neck of a 1-year-old female California sea lion.*



**FIGURE 2.** *Photomicrograph of a pox lesion illustrating hypertrophy, hyperplasia and vacuolation of cells of the stratum spinosum. H & E stain; X 100.*

### Histopathology and Electronmicroscopy

Sections of the lesion were fixed in 10% formalin, embedded in paraffin, sectioned and stained with hematoxylin and eosin (H & E). Histological examination of several skin nodules revealed minimal hyperkeratosis, parakeratosis and marked hypertrophy and hyperplasia of the cells of the stratum spinosum. Large eosinophilic intracytoplasmic inclusions were numerous in the vacuolated, enlarged cells of the stratum spinosum. An occasional basophilic intranuclear inclusion was located in cells of the stratum spinosum. The eosinophilic intracytoplasmic inclusions were weakly positive with Feulgen staining and negative with Periodic Acid Schiff. Areas of the epithelial surface were ulcerated and infiltrated by neutrophils which in some areas penetrated into the dermis. The dermis immediately adjacent to the epithelial reaction was thickened by fibroblastic proliferation. (Fig. 2, 3).

Following histologic examination, formalin-fixed tissue was retrieved and two adjacent thin slices cut from a skin lesion. One slice was rinsed in water, post-fixed in 2.5% glutaraldehyde (2 hrs.), washed in buffer (1½ hrs.), stained with OsO<sub>4</sub> (1 hr.), rinsed in buffer (1 hr.), and stored in 70% ethanol. Based on histologic examination of the second slice of tissue, 1 mm blocks were selected from the glutaraldehyde fixed tissue. These were dehydrated, embedded in epoxy resin (Epon 812), sectioned, stained with lead hydroxide, and examined with a Philips electron microscope model 200 at 60 Kv.

The outstanding cytologic changes seen by electron microscopy included: (1) increased ribosomal material in the basal cell layer; (2) hyperkeratinization in keratinocytes not producing virus; and (3) ballooning degeneration with masses

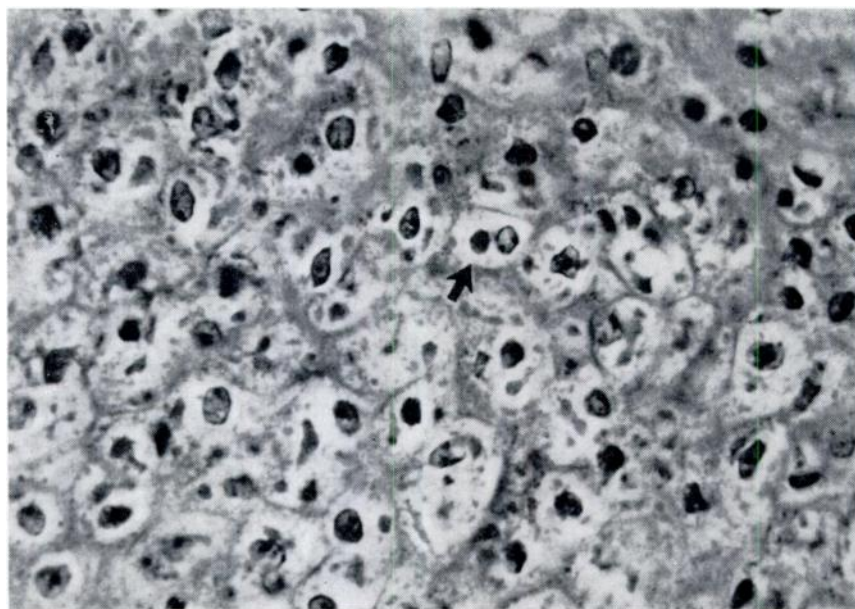


FIGURE 3. *Vacuolated, degenerating cells of the stratum spinosum containing many eosinophilic intracytoplasmic inclusions (arrow). H & E stain; X 630.*

of viroplasm and mature pox virions in keratinocytes of the spinous layer.

Infected cells in the lower spinous layer were swollen and usually contained viroplasmic areas composed of dense granular material and foci of mature virions (Fig. 4). Similar cells more superficial in the spinous layer were markedly degenerate with disappearance of nucleoli and central chromatin and masses of mature virions in cytoplasmic areas (Fig. 5). The latter corresponded to the eosinophilic inclusions seen by light microscopy. Intercellular spaces were enlarged, due chiefly to formalin fixation, and cells were connected only at desmosomal areas. The small amount of residual

keratin was located near the plasma membrane. Lipid droplets were present and were larger in size and number in more superficially-located cells. Such superficial cells, in hyperkeratotic areas, were compressed, elongate, and contained dense masses of virions, keratin fibers and lipid droplets.

The fine structure of the pox virion consisted of a dumbbell-shaped core with outer membrane, an intermediate coat (which usually contained a lateral dense body) and the outer envelope (Fig. 6). The virion size averaged 230 x 340 mu, but this was probably unreliable due to multiple fixation and long storage of tissue sections.

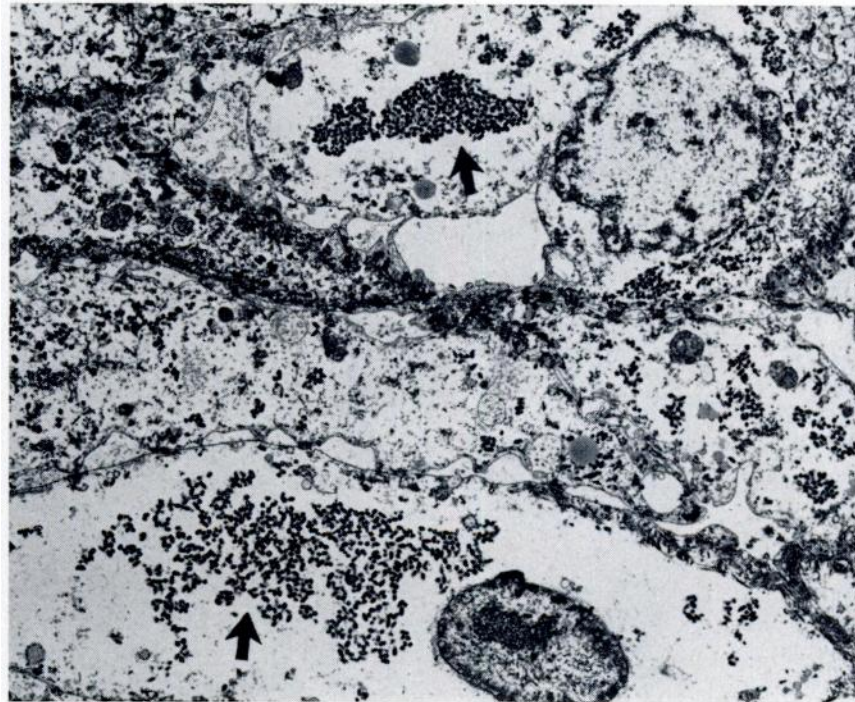


FIGURE 4. Electron micrograph of an infected cell of the stratum spinosum illustrating nucleus and intracytoplasmic inclusion composed of dense granular material and foci of mature virions (arrows) X 11,090.

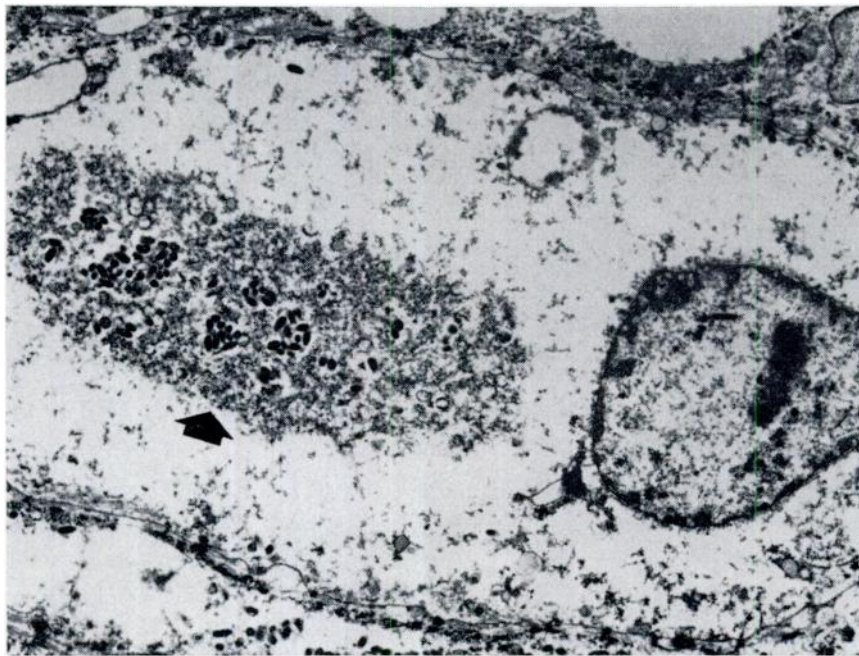


FIGURE 5. *Electron micrograph of degenerated cells of the stratum spinosum illustrating disappearance of nucleoli and central chromatin and masses of mature virions in cytoplasmic areas (arrow). X 5,240.*

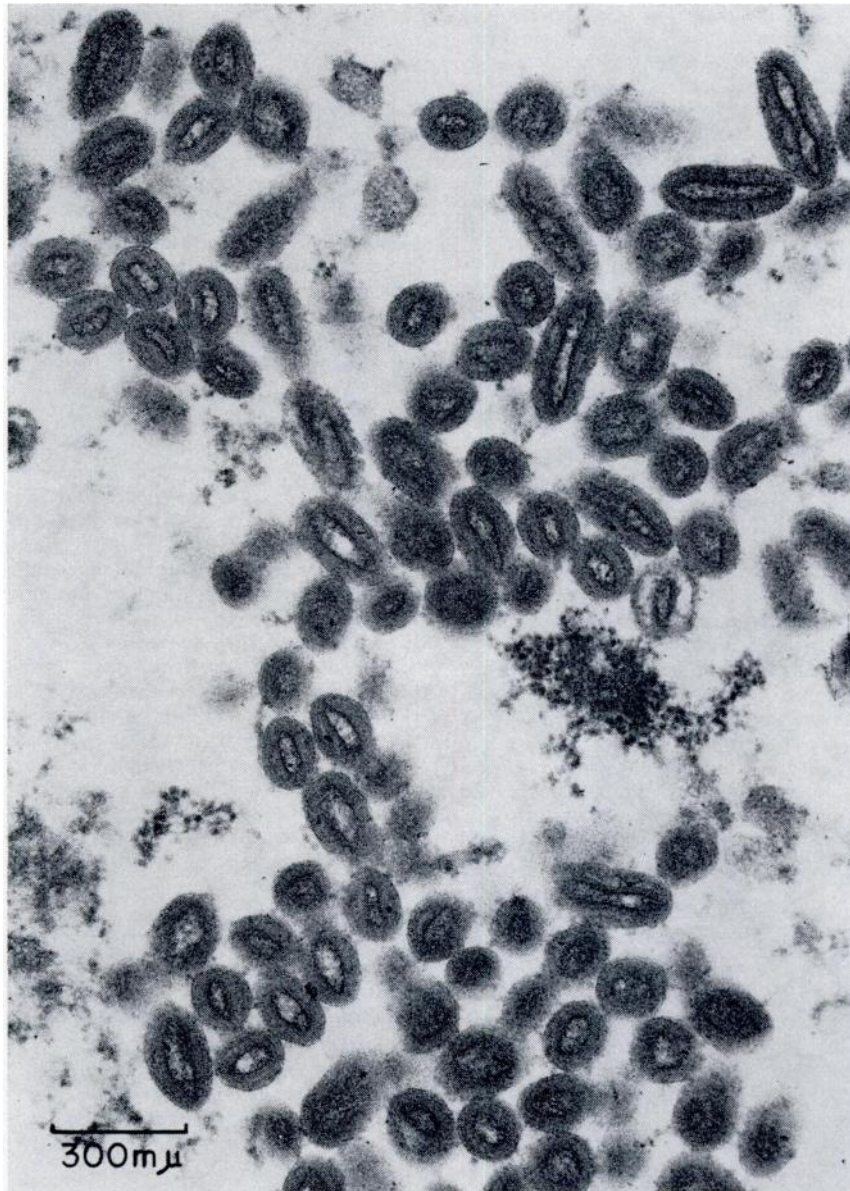


FIGURE 6. *Electron micrograph of mature pox virions X 66,583.*

### Discussion

Naturally occurring pox diseases have been reported in a wide variety of mammals and birds and depending on the strain and virulence of the poxvirus the lesions may have variable gross and histological patterns. Proliferative epithelial lesions, including large eosinophilic intracytoplasmic inclusions and basophilic intranuclear inclusions, have been reported in swine pox (Schwarte, L. H., 1941, Amer. J. Vet. Res. 2: 136-140; Cheville, N. F., 1966, Path. Vet. 3: 556-564) and monkey pox (Cheville, N., 1968, Iowa State Univ. Vet. 30: 77-81).

Other poxviruses have been reported to cause neoplastic epithelial and dermal proliferative lesions in the grey squirrel (*Sciurus carolinensis*) (Kilham, L., et al., 1953, Proc. Soc. Exp. Bio. Med. 82: 298-301), cottontail rabbit (*Sylvilagus floridanus*) (Shope, R. E., 1932, J. Exp. Med. 56: 793-822) and the monkey (Niven, J. S. F., et al., 1961, J. Path. Bact. 81: 1-14).

A survey of the literature concerning pinniped diseases did not reveal any descriptions of skin diseases similar to those contained in this report. Skin papules and granulomas of an undescribed gross and histological type and of unknown classification and origin are reported to be common among pinnipeds (Hubbard, R. C., Husbandry and Laboratory Care of Pinnipeds: 299-358, in: Harrison, R. J., Hubbard, R. C., Peterson, R. S., Rice, C. E., Schusterman, R. J., The Behavior and Physiology of Pinnipeds, 1968, Appleton-Century-Crofts, N.Y., N.Y.). Lesions identical to those described here have not been reported by others in wild or captive California sea lions or Northern

fur seals (*Callorhinus ursinus*) (Personal Communication: Hubbard, R. C., Stanford Research Institute, Menlo Park, California; Kenney, D. W., Sea World, San Diego, California; Keyes, M., Marine Mammal Biological Laboratory, Seattle, Washington; Peterson, R. S., University of California, Santa Cruz, California.)

A pox disease occurs in fish, however, a herpes virus rather than a pox virus has been documented as the etiologic agent (Wolf, K., The Fish Viruses: 35-101, in: Smith, K. M., Lauffer, M. A., Advances in Virus Research, vol. 12, 1966, Academic Press).

It was suspected that the yearling female sea lion had introduced the infection into the aquarium. This is probably unlikely because of the history of skin nodules in two adult sea lions, the presence of skin lesions in three other juveniles and because a diagnosis of papillomatosis was made in March, 1968, on a skin biopsy from a California sea lion from this aquarium. Histological examination of this biopsy revealed lesions identical to the pox lesions described in this report. Probably pox is enzootic in the aquarium and recently purchased animals are most susceptible and are apparently exposed through contact. The possibility that these sea lions became infected in the wild or during captivity before arrival at the aquarium cannot be excluded at present.

Further studies on this disease are presently being conducted. The light and electron microscopic results and epizootiological nature of this disease indicate it to be a skin disease of poxvirus origin.

T. M. WILSON <sup>1</sup> <sup>3</sup>

N. F. CHEVILLE <sup>2</sup>

L. KARSTAD <sup>1</sup>

August 19, 1969

<sup>1</sup> Department of Pathology,  
Section of Zoonoses and Wildlife  
Diseases,  
Ontario Veterinary College,  
Guelph, Ontario, Canada.

<sup>2</sup> National Animal Disease Laboratory,  
Ames, Iowa, U.S.A.

<sup>3</sup> This investigation was supported by  
an AVMA Foundation Award.