



TRYPANOSOMIASIS IN WHITE-TAILED DEER

Authors: KISTNER, T. P., and HANSON, W. L.

Source: Bulletin of the Wildlife Disease Association, 5(4) : 398-399

Published By: Wildlife Disease Association

URL: <https://doi.org/10.7589/0090-3558-5.4.398>

TRYPANOSOMIASIS IN WHITE-TAILED DEER

During routine parasitologic examinations of white-tailed deer (*Odocoileus virginianus*), lymphadenopathy and eosinophilia have been observed in the absence of other hematologic alterations. Helminth and ectoparasite burdens offered a plausible explanation in some instances, but not in others. A brief review of literature indicated that lym-

phadenopathy (Cross, Redman, and Bohl, 1968, *J.A.V.M.A.*, 153(5): 571-575), and eosinophilia (Ristic and Trager, 1958, *J. Protozool.*, 5(2): 146-148), were associated with *Trypanosoma theileri* infection in cattle. It therefore was decided to conduct a preliminary survey for trypanosomes in white-tailed deer within the southeastern United States.

Materials and Methods

Deer blood was cultured in veal infusion medium and examined for culture forms of mammalian trypanosomes. Medium was prepared in advance and taken to the field in an ice chest. Each 20 ml. vial contained 10 ml. standard veal infusion medium (DIFCO), pH adjusted to 7.2. Each ml. of medium contained 500 U. Potassium Penicillin G and 500 U. Dihydrostreptomycin Sulfate. Deer were shot through the neck and blood specimens obtained by cardiac puncture immediately after death. Five ml. of whole blood were inoculated into a vial of veal infusion medium, and vials were marked to designate collection site and animal identification. Vials were incubated at room temperature (25°C.) upon return to the laboratory. Examination of vial contents was conducted at seven and

fourteen days after collection. A drop of material from each vial was placed on a microscope slide and a cover slip added. Slides were examined by phase contrast microscopy at 440X for Trypanosomatidae. A second drop of culture material was spread on a microscope slide, allowed to dry, subsequently fixed in methanol, and stained with Giemsa's stain. Blood cultures were classified positive or negative after two weekly examinations based on fresh and stained preparations.

Deer were collected from areas representative of each physiographic province of the southeastern United States; specifically, mountainous, piedmont, and coastal plain. Collections were made during winter months from Alabama, Florida, Georgia, Louisiana, North Carolina, South Carolina, and Virginia.

Results and Discussion

Blood was collected from a total of thirty-eight (38) wild deer during December, 1968, and January/February, 1969. Ten blood specimens were collected and examined from deer in two separate areas within the mountains and piedmont. Eighteen blood specimens were examined from deer which had been collected in four areas within the coastal plains. Culture forms of trypanosomes were found in blood cultures from deer within all physiographic provinces and in each state from which specimens were obtained. A summary of the results are presented in Table 1.

Although to the authors' knowledge trypanosomes have not been reported from white-tailed deer within the United States, this investigation revealed that 29 (76.3%) of 38 deer examined were positive for mammalian trypanosomes. In-

fection was found in all age classes of deer examined, which ranged from six month old fawns to nine and one-half

TABLE 1. *Results of Blood Culture for Trypanosomes*

Physiographic Province	No. Deer Examined	No. Deer Positive
Mountainous Cleburne Co., Ala., and Caldwell Co., N.C.	10	8
Piedmont McCormick Co., S.C., and Caroline Co., Va.	10	7
Coastal Plain Clay Co., Walton Co., Fla.; Liberty Co., Ga.; and Assumption Parrish, La.	18	14

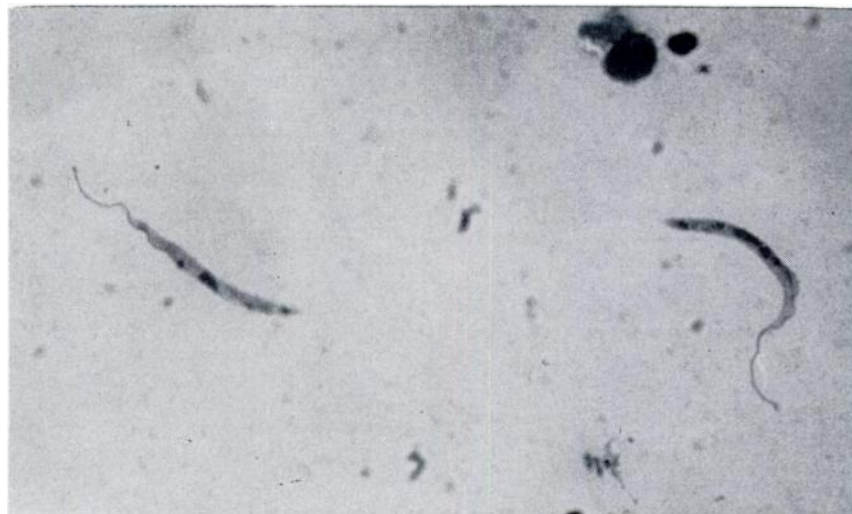


FIGURE 1. Photomicrograph of culture form of trypanosome isolated from white-tailed deer (970X).

year old does. Infection rates also were approximately equal in does and bucks. It is considered significant that trypanosomes have not been seen in thin blood films prepared and stained for differential blood counts from approximately 500 wild deer.

Attempts have not been made to positively identify this trypanosome, since only culture forms were available. The predominant form in culture is an elongate, lance-shaped flagellate with mean dimensions of $18.0\mu \times 1.91\mu$ (range $7.0\mu - 30\mu \times 1.5-3.0\mu$) (Fig. 1). Measurements do not include length of flagellum. The nucleus is located in the anterior half of the organism. The flagellum arises from a kinetoplast located anterior to

the nucleus and passes along a prominent undulating membrane before becoming free at the anterior end. This morphologic type was called crithidia in much of the older literature (Wenyon, C. M., 1926, *Protozoology*, Vol. 1, William Wood and Co., New York; Kudo, R. R., *Protozoology*, Thomas, Springfield, Ill.), corresponds to the blastocrithidia of Laird, M., *Canad. J. Zool.* 37: 749, and is the same morphologic type called the epimastigote by Hoare, C. A. and F. G. Wallace, 1966, *Nature* 21 (5068): 1385. Due to the relatively small number of animals examined, attempts have not been made at this time to determine whether lymphadenopathy and eosinophilia may be correlated with the presence of trypanosomes.

Summary

Culture forms of mammalian trypanosomes were demonstrated in blood from 29 of 38 white-tailed deer from the southeastern United States. Infections were found in Alabama, Florida, Georgia, North Carolina, South Carolina, and Virginia.

Acknowledgments

Funds for support of this study were provided by the U.S. Department of the Interior, Contract No. 14-16-0008-777, and the Federal Aid in Wildlife Restoration Act (50 Stat. 917).

T. P. KISTNER and W. L. HANSON

*Southeastern Cooperative Wildlife
Disease Study*

*Department of Pathology and
Parasitology*

*School of Veterinary Medicine
University of Georgia*

Athens, Georgia

May 23, 1969