



Thyroid Lesions in the Great Cormorant (*Phalacrocorax carbo*) of Niigata, Central Japan: A Possible Association with Dioxin Accumulation

Authors: Chiba, Akira, Oguma, Kazuo, Hatakeyama, Hiroshi, Inomata, Katsuichi, and Honma, Ryuhei

Source: Journal of Wildlife Diseases, 45(1) : 242-247

Published By: Wildlife Disease Association

URL: <https://doi.org/10.7589/0090-3558-45.1.242>

BioOne Complete (complete.BioOne.org) is a full-text database of 200 subscribed and open-access titles in the biological, ecological, and environmental sciences published by nonprofit societies, associations, museums, institutions, and presses.

Your use of this PDF, the BioOne Complete website, and all posted and associated content indicates your

Thyroid Lesions in the Great Cormorant (*Phalacrocorax carbo*) of Niigata, Central Japan: A Possible Association with Dioxin Accumulation

Akira Chiba,^{1,4} Kazuo Oguma,² Hiroshi Hatakeyama,² Katsuichi Inomata,² and Ryuhei Honma³

¹ Department of Biology, The Nippon Dental University School of Life Dentistry at Niigata, Niigata 951-8580, Japan; ² Environmental Analysis Center of Niigata Prefecture, Niigata 950-1144, Japan; ³ Niigata Prefecture Wild Bird Conservation Group, Shiunji, Shibata 957-0231, Japan; ⁴ Corresponding author (email: chiba@ngt.ndu.ac.jp)

ABSTRACT: Necropsy and histopathologic examination of three Great Cormorants (*Phalacrocorax carbo*) shot in Niigata, central Japan, revealed goitrous changes in the thyroids. Thyroids had a hypertrophic follicular epithelium, loss or deficiency of luminal colloid, occasional small follicles suggesting hyperplasia, and occasional collapsed follicles. Irregularly shaped follicles were frequent, and hyperemia, deposition of dark pigment, and sporadic lymphoid aggregates were also seen. Chemical analysis simultaneously conducted showed higher than normal levels of dioxins in the liver, muscle, and fat, i.e., polychlorinated dibenzo-dioxins, polychlorinated dibenzo-furans, and coplanar polychlorinated biphenyls. The present results, together with those of relevant previous studies, strongly suggest an association between these pollutants and thyroid lesions in the Great Cormorant.

Key words: Dioxins, Great Cormorant, Japan, organochlorines, *Phalacrocorax carbo*, thyroid lesions.

Previous studies have indicated that organochlorines are associated with various abnormalities in wild piscivores. In fish-eating birds, these abnormalities include decreased reproductive success (Fox et al., 1991; Van den Berg et al., 1992; Yamashita et al., 1993) and histopathologic changes in the thyroid gland (Moccia et al., 1986; Saita et al., 2004). Similar changes in thyroids have also been found in other wild animals, e.g., a euryhaline teleost (Zhou et al., 1999) and marine mammals (Schumacher et al., 1993; Guise et al., 1995). In experimental studies involving organochlorine-exposed rats (Sewall et al., 1995), common seal (*Phoca vitulina*, Brouwer et al., 1989), American Kestrels (*Falco sparverinus*, Hoffman et al., 1996), Mallards (*Anas platyrhynchos*, Fowles et al., 1997), and Japanese Quail

(*Coturnix japonica*, Grassle and Biessmann, 1982), morphologic changes were reported in thyroid glands as well as signs of immunosuppression and drastically reduced levels of circulating retinol and thyroid hormone. Furthermore, various data obtained in a recent study on Jungle Crows (*Corvus macrorhynchos*) in urban and suburban Tokyo (Kobayashi et al., 2005) strongly suggested an etiologic connection between dioxins and thyroid lesions. Among a multitude of environmental chemicals, much attention has been paid to dioxin and dioxin-like compounds including polychlorinated dibenzo-dioxins (PCDDs), polychlorinated dibenzo-furans (PCDFs), and coplanar polychlorinated biphenyls (Co-PCBs) because of their presence in the environment and their potential for bioaccumulation (Guruge and Tanabe, 1997; Senthilkumar et al., 2002; Braune and Simon, 2003; Kannan et al., 2003). In that respect, the Great Cormorant (*Phalacrocorax carbo*) has been a good subject for such studies because these birds can have thyroid hyperplasia (Saita et al., 2004; Nakagawa and Niizuma, 2006) in association with pollution by organohalogenes (Guruge and Tanabe, 1997; Guruge et al., 2000; Senthilkumar et al., 2002). These studies included the birds associated with metropolitan areas in Japan (Saita et al., 2004; Nakagawa and Niizuma, 2006), where the cormorants breed and have a history of exposure to environmental pollutants through the food chain. Recently, the population of the Great Cormorants has been increasing and expanding their distribution in Japan (Fukuda et al., 2002);

TABLE 1. Various measurements on carcasses of Great Cormorants (*Phalacrocorax carbo*) examined in the present study.

Specimen	Body weight ^a	Wing ^b	Testis size ^b	Liver ^a	Thyroid ^c	Thymus ^a	Bursa size ^b
Sp-1	2,300	317	10.5×3.0	55.5	84	11.3	30×24
Sp-2	2,200	336	16.0×3.0	35.0	74	3.1	28×18
Sp-3	1,900	294	13.0×2.0	54.7	126 ^d	4.3	25×22

^a g.^b mm^c mg.^d Goitrous changes with hyperemia and dark pigment deposits were seen.

however, very little is known regarding the health of these birds. The present paper reports histopathologic changes in the thyroid gland and accumulation of dioxins in the liver, muscle, and fat in the carcasses of Great Cormorant obtained from Niigata (Table 1).

Birds were randomly shot in the vicinity of a breeding colony located at Kanosé (37°41'N, 139°29'E), Niigata Prefecture, central Japan, on 6 June 2006. Carcasses were quickly frozen and kept for 48 hr at -20 C. Also, tissues from an adult male and an adult female Northern Pintail (*Anas acuta*) that were collected during the course of an unrelated field study at Hyoko Waterfowl Park, Niigata (approximately 20 km from the cormorant breeding colony), were included in this study for comparison; Northern Pintail and Great Cormorant are sympatric in the study area but differ in feeding habits. Carcasses were thawed and internal organs, including the thyroid, were fixed in 10% formalin or Bouin's fixative. Tissue blocks were embedded in paraffin following routine methods (Bloom and Fawcett, 1968) and sectioned at 8 µm. Special stains included Mayer's hematoxylin-eosin and azan trichrome or periodic acid Schiff's reagent (PAS) for demonstration of polysaccharide and Hueck's Nile blue stain for identification of lipofuscin. Selected tissue blocks were refixed in Karnovsky's solution, immersed in 1% OsO₄ for 2 hr and embedded in Spurr resin. Semithin sections were stained with

toluidine blue in borax and examined with a light microscope.

For quantitative histologic evaluation of the thyroid gland, mean follicle diameter and mean epithelial height were compared between the cormorant and pintail samples. For this purpose, 50 randomly selected follicles per individual were measured under a light microscope equipped with an ocular micrometer. Differences between the means were evaluated by using a Student's *t*-test. A value of *P*<0.05 was considered statistically significant. We did not count average follicle number per unit area as a histologic parameter of thyroid hyperplasia (Saita et al., 2004) because the follicle density was highly variable, depending on the degree of hyperemia.

Pectoral muscle, liver, and fat from subcutaneous and peritoneal adipose tissue were used for chemical detection of dioxins, and concentrations of PCDDs, PCDFs, and Co-PCBs were measured according to standard techniques (Ministry of the Environment, 2003). Values of each chemical were expressed as 2-, 3-, 7-, and 8-tetrachlorinated dibenzo-dioxin toxic equivalents (TEQs); and PCDDs, PCDFs, and Co-PCBs were also estimated as toxic equivalency factors for birds, as presented by the World Health Organization (Van den Berg et al., 1998), assuming a nondetection result as half of the detection limit.

The three cormorants (Sp-1, -2, and -3) were judged to be hatching-year males based on body size, external features,

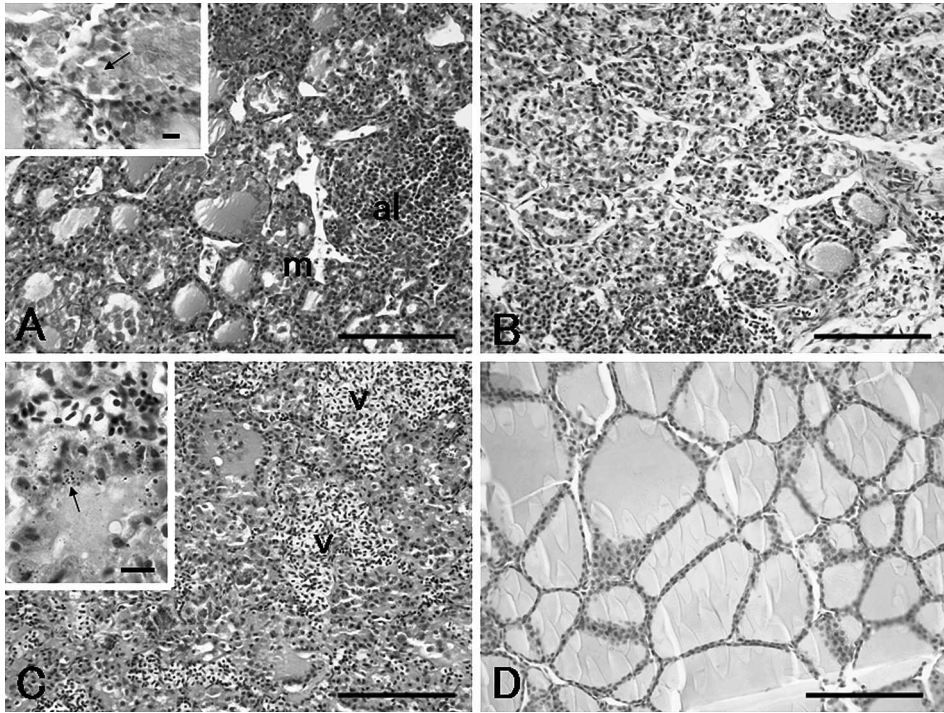


FIGURE 1. Histopathologic changes in the thyroid gland from three Great Cormorants (Sp-1, A; Sp-2, B; Sp-3, C) in comparison with the histology of a healthy gland (D) from a male Northern Pintail (control). Figure A shows a hyperplastic thyroid with small follicles (m), shed epithelial cells with engulfed colloid (arrow in inset), and aggregations of lymphoid cells (al). Figures B and C show collapsed follicles lined with hypertrophied epithelial cells and deficient luminal colloid. Inset of Figure C shows dark pigment deposits (arrow) in the parenchyma. A–C, PAS counterstained with hematoxylin. Inset of A and C, Mayer's hematoxylin-eosin stain. Bars in A–D=100 μ m, bars in insets of A and C=10 μ m.

gonad maturity, and size of the remaining bursa Fabricii (Table 1). No abnormalities were observed in the internal organs at the macroscopic level. However, histologic examination showed a striking lesion in the thyroid of all three cormorants (Fig. 1A–C) in comparison with the thyroid histology of the pintail (Fig. 1D). Hypertrophied follicular epithelium was consistent in the cormorant thyroids (Fig. 1), as shown by the difference of mean epithelial height, i.e., $7.8 \pm 1.1 \mu\text{m}$ in the cormorant versus $2.6 \pm 0.0 \mu\text{m}$ in pintails ($P < 0.05$). Occasional small follicles suggesting hyperplasia were also observed in the cormorants, although there was no significant difference in mean follicle diameter between the cormorants ($47.8 \pm 6.8 \mu\text{m}$) and pintails ($77.4 \pm 11.5 \mu\text{m}$). The amount of luminal colloid tended to be

deficient, and follicles without luminal colloid were very common in Sp-2 and -3 (Fig. 1B, C), probably due to follicle collapse, goitrous changes, or both. Also in Sp-1, changes leading to follicular collapse were evident, as depicted by the presence of epithelial cells that had fallen into the lumen and enlarged epithelial cells that appeared to have engulfed a colloid mass (Fig. 1A). Moreover, sections from Sp-1 showed sporadic lymphoid aggregates in the stroma (Fig. 1A). Hyperemia and numerous deposits of lipofuscin-like dark pigments were recognized in the gland of Sp-3 with goitrous changes (Fig. 1C, inset). No fibrosis was found in the thyroids.

Chemical analysis indicated higher values of dioxin in the liver, pectoral muscle, and fat of the cormorants in comparison with those values for the pintail (Table 2).

TABLE 2. Dioxin levels of Great Cormorants (*Phalacrocorax carbo*) shot in the wild in Niigata, central Japan, and of a Northern Pintail (*Anas acuta*) for comparison.

Tissue Animals	Concentrations (pg-TEQ/g · wet) of dioxins			
	PCDDs	PCDFs	Co-PCBs	Total
Muscle				
Cormorant ^a	1.5±0.4 (1.1–1.9) ^c	1.2±0.5 (0.58–1.6)	6.3±3.3 (3.0–9.6)	(5.0–13.0)
Pintail ^b	0.20	0.19	0.57	0.96
Liver				
Cormorant	1.8±0.9 (0.82–2.4)	3.3±1.2 (2.7–4.7)	17.1±21.6 (4.0–42)	(9.2–46)
Pintail	0.08	0.28	0.27	0.63
Fat				
Cormorant	38.7±9.6 (30–49)	37.6±25.9 (18–67)	846.6±1,258.6 (120–2,300)	(180–2,400)
Pintail	3.7	3.7	12	19

^a n=3.^b n=1.^c average±SD (range).

Values of PCDDs (pg-TEQ/g · wet weight) were 1.1–1.9 for muscle, 0.82–2.4 for liver, and 30–49 for fat, being approximately 8- to 22-fold higher on average than those of the pintail. The range of values of PCDFs was 0.58–1.6 for muscle, 2.7–4.7 for liver, and 18–67 for fat, and these values were higher than those for pintails, 0.19, 0.28, and 3.7, respectively (Table 2). Values of Co-PCBs ranged from 3.0 to 9.6 for muscle, 4.0–42 for liver, and 120–2,300 for fat and were 11- to 71-fold higher, on average, than those of the pintails.

The present study, although limited in the number of samples, showed thyroid lesions and significant dioxin accumulation in the internal organs of the Great Cormorants from Niigata. Thyroid lesions observed in these cormorants were histopathologically more severe than those of Great Cormorants from Tokyo (Saita et al., 2004) and Aichi (Nakagawa and Niizuma, 2006) or those of Jungle Crows from Tokyo (Kobayashi et al., 2005). Thyroids of animals from Tokyo and Aichi were diagnosed as being simply hyperplastic. The severe thyroid lesions that presented in our study seemed to be histopathologically more complicated and were comparable to lesions observed in marine

mammals affected by PCB pollution (Schumacher et al., 1993). Although these lesions were observed in hatch-year birds, it is possible that the exposure and lesions occurred earlier, i.e., as chicks or embryos, and probably through maternal exposure. We assume that the observed thyroid lesions were caused by environmental pollutants, most probably dioxins and related chemicals, as suggested by previous studies (Moccia et al., 1986; Capen and Martin, 1989; Rolland, 2000; Saita et al., 2004; Kobayashi et al., 2005). Among the dioxins detected, Co-PCBs showed the highest tissue concentration, but dioxin concentrations (PCDDs, PCDFs, and Co-PCBs) were generally lower than those previously reported in conspecific samples from Lake Biwa, Shinobazu Pond, and Godaiba Island in Japan (Guruge et al., 2000). For example, mean hepatic Co-PCB concentration (pgTEQs /g · wet weight) in the samples from Niigata (present specimens) was 17.1, whereas the corresponding values were 670 for adults from Lake Biwa and 21, 410, and 1,900 for chicks, juveniles, and adults, respectively, from Shinobazu Pond (Guruge et al., 2000). No histopathologic data were given in the paper of Guruge et al. (2000). Saita et al. (2004) suggested a

possible connection between high concentrations of some dioxins (e.g., Co-PCBs) and thyroid hyperplasia, based on their examination of the Great Cormorants from Lake Biwa and Tokyo Bay, where the mean values of Co-PCBs (pgTEQs / g · wet weight) in pectoral muscles were 104.1 ± 17.7 (SE) and 177.8 ± 22.6 , respectively. It is possible that the severity of thyroid lesions in the Great Cormorant is not directly correlated with tissue concentrations of dioxins. Other factors, such as dioxins coupling with dietary iodine, may be involved in the development of thyroid lesions, although currently we have no evidence to support this. Causal mechanisms of organochlorines, with respect to thyroid abnormality, have been comprehensively reviewed (Capen and Martin, 1989; Rolland, 2000). Concerning this subject, effects of hydroxylated metabolites of PCBs should be specially noted because they are structurally similar to thyroxine (T4) and possibly alter thyroid hormone status by being bound to plasma thyroid hormone-binding proteins (Sandau et al., 2002), disrupting thyroid hormone-mediated neuronal development (Kimura-Kuroda et al., 2007). This mechanism may explain the lesions observed in thyroid glands that were previously reported in various wild animals (Grassle and Biessmann, 1982; Brouwer et al., 1989; Sewall et al., 1995; Hoffman et al., 1996; Fowles et al., 1997; Kobayashi et al., 2005) and in the present case.

In conclusion, our results support previously reported results from the Great Cormorant (Saita et al., 2004; Nakagawa and Niizuma, 2006) and other wild animals (Grassle and Biessmann, 1982; Brouwer et al., 1989; Sewall et al., 1995; Hoffman et al., 1996; Fowles et al., 1997; Kobayashi et al., 2005) by providing detailed histopathologic evidence correlating organochlorine pollution and thyroid lesions in the wildlife of Japan.

We thank M. Fukuda of Tokyo Sea Life Park for his support in the literature search. The present study was partly

supported by a grant-in-aid from Niigata Prefecture Government (no. 5673498765) and a research promotion grant (NDUF-07-15) from the Nippon Dental University.

LITERATURE CITED

- BRAUNE, B. M., AND M. SIMON. 2003. Dioxins, furans, and non-ortho PCBs in Canadian Arctic seabirds. *Environmental Science and Technology* 37: 3071–3077.
- BLOOM, W., AND D. W. FAWCETT. 1968. A textbook of histology. W. B. Saunders Company, Philadelphia, Pennsylvania, 858 pp.
- BROUWER, A., P. H. J. REIJNERS, AND J. K. KOEMANN. 1989. Polychlorinated biphenyl (PCB)-contaminated fish induces vitamin A and thyroid hormone deficiency in the common seal (*Phoca vitulina*). *Aquatic Toxicology* 15: 99–106.
- CAPEN, C. C., AND S. L. MARTIN. 1989. The effects of xenobiotics on the structure and function of thyroid follicular and C-cells. *Toxicology and Pathology* 17: 266–293.
- FOWLES, J. R., A. FAIRBROTHER, A. TRUST, AND N. I. KERKVLIIET. 1997. Effects of aroclor 1254 on the thyroid gland, immune function, and hepatic cytochrome P450 activity in mallard. *Environmental Research* 75: 119–129.
- FOX, G. A., D. V. WESELOH, T. K. KUBIAK, AND T. C. ERDMAN. 1991. Reproductive outcomes in colonial fish-eating birds: A biomarker for developmental toxicants in Great Lakes food chains. *Journal of Great Lakes Research* 17: 153–157.
- FUKUDA, M., M. NARUSUE, AND N. KATO. 2002. Changes in the distribution and abundance of the great cormorant *Phalacrocorax carbo* in Japan. *Japanese Journal of Ornithology* 51: 4–11. (Japanese with English summary)
- GRASSLE, B., AND A. BIESSMANN. 1982. Effects of DDT, polychlorinated biphenyls and thiouracil on circulating thyroid hormones, thyroid histology and eggshell quality in Japanese quail (*Coturnix coturnix japonica*). *Chemico-biological Interactions* 42: 371–377.
- GUISE, S. D., D. D'MARTINEAU, P. BELAND, AND M. FOURINER. 1995. Possible mechanisms of action of environmental contaminants on St. Lawrence beluga whales (*Delphinapterus leucas*). *Environmental Health Perspectives* 103: 73–77.
- GURUGE, K. S., AND S. TANABE. 1997. Congener specific accumulation and toxic assessment of polychlorinated biphenyls in common cormorants, *Phalacrocorax carbo*, from Lake Biwa, Japan. *Environmental Pollution* 96: 425–433.
- , ———, AND M. FUKUDA. 2000. Toxic assessment of PCBs by the 2, 3, 7, 8-tetrachlorodibenzo-p-dioxin equivalent in common cormorant (*Phalacrocorax carbo*) from Japan. Ar-

- chives of Environmental Contamination and Toxicology 38: 509–521.
- HOFFMAN, D. J., M. J. MELANCON, P. N. KLEIN, C. P. RICE, J. D. EISEMANN, R. K. HINES, J. W. SPANN, AND G. W. PENDLETON. 1996. Developmental toxicity of PCB 126 (3, 3', 4, 4', 5-pentachlorobiphenyl) in nestling American kestrels (*Falco sparverius*). *Fundamental and Applied Toxicology* 34: 188–200.
- KANNAN, K., K. S. KUMAR, H. NAKATA, J. FALANDYSZ, G. OEHME, AND S. MASUNAGA. 2003. Polychlorinated biphenyls, dibenzo-p-dioxins, dibenzofurans, and p-p'-DDE in livers of white-tailed sea eagles from Eastern Germany, 1979–1998. *Environmental Science and Technology* 37: 1249–1255.
- KIMURA-KURODA, J., I. NAGATA, AND Y. KURODA. 2007. Disrupting effects of hydroxypolychlorinated biphenyl (PCB) congeners on neuronal development of cerebellar Purkinje cell: A possible causal factor for developmental brain disorders? *Chemosphere* 67: S412–S420.
- KOBAYASHI, M., Y. KASHIDA, K. YONEDA, H. IWATA, M. WATANABE, S. TANABE, H. FUKATSU, N. MACHIDA, AND K. MITSUMORI. 2005. Thyroid lesions and dioxin accumulation in the livers of jungle crows (*Corvus macrorhynchos*) in urban and suburban Tokyo. *Archives of Environmental Contamination and Toxicology* 48: 424–432.
- MINISTRY OF THE ENVIRONMENT. 2003. Dioxins survey manual for wildlife of Japan. Wildlife Research Center, Tokyo, 228 pp.
- MOCCIA, R. D., G. A. FOX, AND A. BRITTON. 1986. A quantitative assessment of thyroid histopathology of herring gull (*Larus argentatus*) from the Great Lakes and a hypothesis on the causal role of environmental contaminants. *Journal of Wildlife Diseases* 22: 60–70.
- NAKAGAWA, Y., AND Y. NIZUMA. 2006. Thyroid hyperplasia in great cormorant in Aichi Prefecture. *Japanese Journal of Ornithology* 55: 88–91. (Japanese with English summary)
- ROLLAND, R. M. 2000. A review of chemically-induced alterations in thyroid and vitamin A status from field studies of wildlife and fish. *Journal of Wildlife Diseases* 36: 615–635.
- SAITA, E., S. HAYAMA, H. KAJIWARA, K. YONEDA, G. WATANABE, AND K. TAYA. 2004. Histological changes in thyroid glands from great cormorant (*Phalacrocorax carbo*) in Tokyo Bay, Japan: Possible association with environmental contaminants. *Journal of Wildlife Diseases* 40: 763–768.
- SANDAU, C. D., P. AYOTTE, E. DEWAILLY, J. DUFFE, AND R. J. NORSTROM. 2002. Pentachlorophenol and hydroxylated polychlorinated biphenyl metabolites in umbilical cord plasma of neonates from coastal populations in Québec. *Environmental and Health Perspectives* 110: 411–417.
- SCHUMACHER, U., S. ZAHLER, H.-P. HORNY, G. HEIDEMANN, K. SKIMISSON, AND U. WELSCH. 1993. Histological investigations on the thyroid glands of marine mammals (*Phoca vitulina*, *Phocoena phocoena*) and the possible implications of marine pollution. *Journal of Wildlife Diseases* 29: 103–108.
- SENTHILKUMAR, K., N. ISEKI, S. HAYAMA, J. NAKANISHI, AND S. MASUNAGA. 2002. Polychlorinated dibenzo-p-dioxins, dibenzofurans, and dioxin-like polychlorinated biphenyls in livers of birds from Japan. *Archives of Environmental Contamination and Toxicology* 42: 244–255.
- SEWALL, C. H., N. FLAGLER, J. P. VANDEN HEUVEL, G. C. CLARK, A. M. TRITSCHER, R. M. MARONPOT, AND G. W. LUCHIER. 1995. Alterations in thyroid function in female Sprague-Dawley rats following chronic treatment with 2, 3, 7, 8-tetrachlorodibenzo-p-dioxin. *Toxicology and Applied Pharmacology* 132: 237–244.
- VAN DEN BERG, M., L. H. J. CRAANE, T. SINNIGE, T. BOUDEWIJN, I. J. LUTRK-SCHIPHOLT, B. SPENKELINK, AND A. BROUWER. 1992. The use of biochemical parameters in comparative toxicological studies with the cormorant (*Phalacrocorax carbo*) in the Netherlands. *Chemosphere* 25: 1265–1270.
- VANDEN BERG, M., M. L. BIRNBAUM, A. T. BOSVELD, B. BRUNSTROM, P. COOK, M. FREELY, J. P. GIESY, A. HANBERG, R. HASEGAWA, S. W. KENNEDY, T. KUBIAK, J. C. LARSEN, F. X. VAN LEEUWEN, A. K. LIEM, C. NOLT, R. E. PETERSON, L. POELLINGER, S. SAFE, D. SCHRENK, D. TILLITT, M. TYSKLIND, M. YOUNES, F. WAERN, AND T. ZACHAREWSKI. 1998. Toxic equivalency factors (TEFs) for PCBs, PCDDs, PCDFs, for humans and wildlife. *Environmental Health and Perspectives* 106: 775–792.
- YAMASHITA, N., S. TANABE, J. P. P. LUDWIG, H. KURITA, M. E. LUDWIG, AND R. TATSUKAWA. 1993. Embryonic abnormalities and organochlorine contamination in double-crested cormorants (*Phalacrocorax carbo*) and Caspian terns (*Hydroprogne caspia*) from the upper Great Lakes in 1988. *Environmental Pollution* 79: 163–173.
- ZHOU, T., H. B. JOHN-ALDER, P. WEIS, AND J. S. WEIS. 1999. Thyroidal status of mummichogs (*Fundulus heteroclitus*) from a polluted versus a reference habitat. *Environmental Toxicology and Chemistry* 18: 2817–2823.

Received for publication 8 June 2007.