



---

## **VIROLOGIC INVESTIGATIONS OF FREE-LIVING EUROPEAN BISON (BISON BONASUS) FROM THE BIALOWIEZA PRIMEVAL FOREST, POLAND**

Authors: Borchers, Kerstin, Brackmann, Jens, Wolf, Olaf, Rudolph, Michael, Glatzel, Peter, et al.

Source: Journal of Wildlife Diseases, 38(3) : 533-538

Published By: Wildlife Disease Association

URL: <https://doi.org/10.7589/0090-3558-38.3.533>

## VIROLOGIC INVESTIGATIONS OF FREE-LIVING EUROPEAN BISON (*BISON BONASUS*) FROM THE BIALOWIEZA PRIMEVAL FOREST, POLAND

Kerstin Borchers,<sup>1,6</sup> Jens Brackmann,<sup>1</sup> Olaf Wolf,<sup>2</sup> Michael Rudolph,<sup>2</sup> Peter Glatzel,<sup>3</sup> Matgorzata Krasinska,<sup>4</sup> Zbigniew A. Krasinski,<sup>5</sup> and Kai Frölich<sup>2</sup>

<sup>1</sup> Institute of Virology, FU Berlin, Königin-Luise-Str. 49, 14195 Berlin, Germany

<sup>2</sup> Institute for Zoo Biology and Wildlife Research (Berlin), Alfred-Kowalke-Str. 17, 10315 Berlin, Germany

<sup>3</sup> Clinic for Animal Reproduction, FU Berlin, Königsweg 63, 14163 Berlin, Germany

<sup>4</sup> Mammal Research Institute PAS, 17-230 Bialowieza, Poland

<sup>5</sup> Bialowieza National Park, 17-230 Bialowieza, Poland

<sup>6</sup> Corresponding author (email: borchers@zedat.fu-berlin.de)

**ABSTRACT:** We conducted virologic investigations on postmortem specimens from 261 free-living European bison (*Bison bonasus*) from the Bialowieza Primeval Forest, Poland collected between 1990 and 2000. Fifty-four of 94 males had balanoposthitis; none of the 167 female bison examined had reproductive tract lesions. Peripheral blood, swabs, and various tissues were analyzed for bovine viruses as well as for viral DNA by bovine herpesvirus 1 (BoHV-1) and bovine herpesvirus 4 (BoHV-4) specific polymerase chain reaction (PCR) technique. An infectious bovine rhinotracheitis like BoHV-1 strain was isolated from the spleen of a female bison calf and additionally was detected by nested PCR from splenic tissue. None of the bison had significant antibody titers against BoHV-1, bovine herpesvirus 2, BoHV-4, caprine herpesvirus 1, cervid herpesvirus 1, or bovine viral diarrhoea (BVD) virus-1. However, low antibody titers in two animals indicate that this European bison population has been exposed to BVD virus or BVD-like viruses and BoHV-2.

**Key words:** Balanoposthitis, BoHV-1, *Bison bonasus*, bovine herpesvirus 1, European bison, polymerase chain reaction, survey.

### INTRODUCTION

Balanoposthitis of European bison (*Bison bonasus*) is characterized by chronic necrotizing and ulcerative inflammation of the prepuce and penis (Jakob et al., 2000; Wolf et al., 2000). This disease was noted for the first time in 1980 in European bison in the Polish part of the Bialowieza Primeval Forest (Piusinski et al., 1997). In 1996, about 15% of male bison were affected. Since then, despite intensive interdisciplinary microbiological investigations, the etiologic agent has not been conclusively found. Recent studies have indicated that *Fusobacterium necrophorum* is prevalent in advanced necrotic preputial lesions (Jakob et al., 2000). Other infectious agents and/or mechanical factors, however, were considered to be the most likely initiators of the disease. Polish studies have reported bovine herpesvirus 1 (BoHV-1) and bovine viral diarrhoea virus (BVDV) seropositive female and male bison in the Bialowieza Forest (Kita and Anusz, 1991; Krasochko et al., 1997). Attempts to isolate

BoHV-1 from affected tissues, however, were not successful.

Antibodies against BoHV-1, bovine herpesvirus 4 (BoHV-4), and BVDV have been reported in free-ranging American bison (*Bison bison*) (Thiry et al., 1990; Taylor et al., 1997). Malignant catarrhal fever (MCF) has been described in European bison kept in a German zoo (Hänichen et al., 1998) and antibodies to ovine herpesvirus 2 (OvHV-2) have been demonstrated in serum of American bison (Li et al., 1996). Balanoposthitis has not been associated with MCF in bison (Schultheiss et al., 2000).

Bovine herpesvirus 1 may play a role in the pathogenesis of balanoposthitis in Polish bison because it can cause infectious pustular vulvovaginitis and balanoposthitis in cattle (Engels et al., 1981; reviewed by Ludwig, 1983). Another virus commonly infecting cattle and causing epithelial lesions is bovine herpesvirus 2 (BoHV-2) or bovine mamillitis virus. Bovine herpesvirus 4 has been implicated in a variety of dis-

eases including MCF (Thiry et al., 1989; reviewed by Goltz and Ludwig, 1991) and may serve as a passenger virus in cattle (Moreno-Lopez et al., 1989). In addition BoHV-4 and BVDV (Krasochko et al., 1997) infections might induce immunosuppression in bison making the animals more susceptible to diseases such as balanoposthitis. Since caprine herpesvirus 1 (CpHV-1) has been isolated from lesions in goats with ulcerative vulvitis and balanoposthitis in Australia (Tarigan and Webb, 1987), we included this virus in our serologic studies. Because European bison in Poland have contact with deer we also tested the sera for cervid herpesvirus 1 (CvHV-1) antibodies.

The etiologic role of bovine viruses in the pathogenesis of balanoposthitis in the European bison from the Bialowieza Primeval Forest is unclear. Therefore, the objective of this study was to survey 54 diseased and 207 clinically healthy bison by virologic and serologic methods to determine if bovine viruses are associated with this condition.

#### MATERIAL AND METHODS

Between winter 1990 and spring 2000, 261 bison were culled by the Bialowieza Primeval Forest (52°45'N, 23°50'E) management. Twenty-seven of these animals were from a reserve in the forest and 234 were free-living bison. Seven bulls from the reserve and 47 bulls from the free-living population had balanoposthitis; the female bison were clinically normal. To survey for BoHV-1, BoHV-2, BoHV-4, CpHV-1, CvHV-1, and BVDV in this herd, 167 female and 94 male bison were studied. Postmortem specimens including portions of spleen, lung, penis, prepuce, vagina, clitoris, lung, inguinal lymph nodes, nasal and genital swabs, peripheral blood, and vaginal washings were collected, transported on ice, and assayed for infectious virus, viral DNA, and virus specific antibodies.

For isolation of infectious or latent virus, samples were cut into small pieces and co-cultivated on a semi-confluent monolayer of Madin Darby bovine kidney (MDBK) cells and bovine and European bison fetal lung cells. Nasal and genital swabs were extracted in isolation medium (Eagles's minimum essential medium, Dulbecco's modification [EDM]), supplement-

ed with 200 IU/ml penicillin and 200 ng/ml streptomycin and the extract was co-cultivated on MDBK cell cultures. Genital washings (Hank's balanced salt solution) were centrifuged (15 min, 7,000×G) and the pellet was co-cultivated on bovine or bison fetal lung cells.

For detection of infectious virus in plaque assay, pieces of the various organs were individually minced with scissors and homogenized with sterile sea sand using a mortar and pestle. After suspension in 1 ml EDM the debris was separated by centrifugation (5 min, 700×G). One hundred microliters of the supernatant were incubated on MDBK cells. The cell cultures used for co-cultivation and plaque assays were observed microscopically daily for viral cytopathic effect (CPE). If no CPE was detectable after 5 days of incubation, the cultures were repassaged up to three times at weekly intervals with fresh MDBK cells.

After appearance of CPE, supernatants were harvested and centrifuged through a 30% sucrose cushion at 10,000×G for 15 min to eliminate gross debris. Thereafter, the supernatant was centrifuged at 135,000×G for 5 min and the sediment was placed on 400 mesh copper grids (Baltec, Walluf, Germany) covered with formvar film and coated with carbon (Plano, Marburg, Germany). Finally, the grids were negatively stained with 2% uranyl acetate (Serva, Heidelberg, Germany) and checked by an EM 902 A electron microscope (Carl Zeiss, Oberkochen, Germany).

For genetic analysis, virus from supernatants was pelleted by centrifugation through a 30% sucrose cushion (2 hr at 60,000×G) and viral DNA was extracted with 1% sodium dodecyl sulfate (SDS) and proteinase K (Boehringer, Mannheim, Germany). Subsequently, DNA was purified by equilibrium density centrifugation in CsCl-ethidium bromide gradients. Purified viral DNA (200 ng) was digested with the restriction enzymes *Hpa* I, *Eco* RI, *Bam* HI, *Hind* III, and *Sal* I, respectively. The fragments generated were separated by electrophoresis through a 0.7% agarose gel and stained with ethidium bromide.

A different technique was used for DNA extracted from buffy coat cells, swabs, and tissues. Citrated venous blood was centrifuged through a ficoll (Seromed, Berlin, Germany) gradient (density:  $\rho = 1.077$  g/ml) and buffy coats were isolated, washed, and pelleted by low speed centrifugation. Nasal and genital swabs were extracted in isolation medium and the fluid was centrifuged for 10 min at 15,000×G. Tissue samples were cut into small pieces. Buffy coats, pellets derived from swab material, and tissue sections were then suspended in individual tubes with digestion buff-

er (24 mM EDTA, 75 mM NaCl, 1% SDS, 0.2 mg/ml proteinase K, pH 8.0) and incubated overnight at 56 C. Proteinase was destroyed by heating the samples for 10 min at 95 C, and the quantity of DNA yield was checked spectrophotometrically before using 1–2 µg DNA in polymerase chain reaction (PCR). As proof of DNA quality, all preparations were analyzed by β-actin PCR. Only samples that tested positive were used for virus specific PCR analysis. A tube with all reagents but no specimen was included as control.

For BoHV-1 specific nested PCR, two primer sets amplifying a 653 bp and a final 274 bp fragment were used as described by Ashbaugh et al. (1997). The PCR mixes (50 µl) contained 1–2 µg of cellular DNA, 0.4 µM of each primer, 0.2 mM desoxyribonucleotide triphosphates (NTPs) (Applied Biosystems, Weiterstadt, Germany), 1.5 U Taq polymerase (Quiagen, Hilden, Germany), reaction buffer, and Q-solution (Quiagen). Finally, the aqueous phase was covered with 1 drop of mineral oil (Sigma, St. Louis, Missouri, USA). The cycling conditions were optimized on a MWG thermal cycler (MWG-Biotech, Ebersberg, Germany). One amplification cycle consisted of the following two steps, which were repeated 40 times each: denaturation at 97 C for 60 sec; annealing and extension at 74 C for 60 sec. The amplification products were analyzed by electrophoresis in a 1% agarose gel and detected by staining with ethidium bromide. The sensitivity of the nested PCR was evaluated by serial tenfold dilutions of BoHV-1 DNA. Two genome equivalents of DNA produced a band in the agarose gel that was clearly visible after the second round of PCR. No cross-reactivity with purified BoHV-2 and BoHV-4 DNA was evident.

The BoHV-4 specific PCR primer pair (P1: 5'-GGCCTGAAGAGGCTATCTGG-3' and P2: 5'-CTCCAGTCCGGCTCCCT-3') were used on a Bio-Med cycler 60/2 (Bio-Med, Theres, Germany) under the following conditions: after an initial 4 min denaturation step at 94 C, 40 cycles of each 2 min at 94 C, 56 C, and 72 C followed. The reaction was finished by a final 10 min elongation step at 72 C. The PCR mix consisted of the same components as described for the BoHV-1 PCR, with the exception that no Q-solution was used. The 144 bp amplification product was specified by Southern hybridization with a digoxigenin labeled (Boehringer) BoHV-4 genomic probe.

For transmission electron microscopy (TEM), tissue samples were fixed with Karnovsky solution, post-fixed in 2% osmium tetroxide, dehydrated with ethanol and embedded in glycidether. Ultrathin sections were stained with uranyl acetate and lead citrate. The sam-

ples were examined with a TEM Zeiss 902 A microscope.

To test for neutralizing BoHV-1 and BoHV-2 antibodies, serial two-fold dilutions of complement-inactivated plasma or serum were incubated with 100 plaque forming units (PFU) of BoHV-1 Cooper strain (kindly supplied by G. Letchworth, University of Wisconsin, Madison, USA) and BoHV-2 strain BMV (kindly supplied by B. Roizman, University of Chicago, Illinois, USA) for 1 hr at 37 C. After addition of  $1 \times 10^5$  MDBK cells incubation was continued for 1 hr in EDM with 5% newborn calf serum (NCS) (Life Technologie GmbH, Berlin, Germany). An overlay of 1.6% carboxymethylcellulose (CMC) and 2% NCS in EDM was placed on the monolayer, and the reaction was stopped after 2 days with 3% formalin in phosphate buffered saline (PBS). Neutralization titers were calculated based on the dilution that produced 50% plaque reduction. Known positive and negative control sera were included with each batch of bison sera tested. Titers  $\geq 1:20$  were considered suspicious.

A commercial enzyme-linked immunosorbent assay (ELISA) (CHEKIT-ELISA, Dr. Bommelli AG, Liebefeld-Bern, Switzerland) was used for detection of antibodies against BoHV-1. Indirect immunofluorescence assay (IFA) for detection of BoHV-4 specific antibodies were performed on 96-well plates seeded with MDBK cells infected with  $1 \times 10^3$  PFU BoHV-4 strain 66-p-347 per cell. Cells were fixed with 3% formalin/PBS when CPE were seen. After washing in PBS, cells were permeabilized with 1% Triton X-100 and successively incubated with serial two-fold dilutions of the respective serum and subsequently with the second antibody (fluorescein-conjugated anti-bovine IgG, Dianova/Immunotech, Hamburg, Germany). Unbound antibody was washed away with 1% NCS in PBS at every step. Cells were examined under a fluorescence microscope (ICM 405, Zeiss, Göttingen, Germany). The IFA-titer was calculated as the last serum dilution giving positive fluorescence.

A standard microneutralization test was used for detection of CpHV-1 and CvHV-1 specific antibodies. Georgia bovine kidney cells and EDM with 5% fetal bovine serum were used for propagation. In an initial screening 1:4 serum dilutions were incubated with 70 PFU of virus. After 1 hr incubation at 37 C,  $3 \times 10^4$  cells were seeded into each well. After 3 hr, the CMC overlay was added. All sera that tested positive, were titrated in two-fold dilutions in a second neutralization test. The monolayers were examined for CPE after 2 days for CpHV-1 and 5 days for CvHV-1. Titers were expressed as the reciprocal of the highest dilution of se-



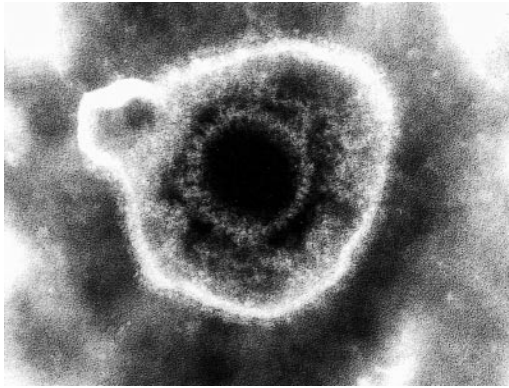


FIGURE 1. Purified and negative stained virus particles grown from spleen of a healthy female bison calf visualized by negative stain electron microscopy. The particle shown (magnification  $\times 260,000$ ) is a typical herpesvirus.

rum exhibiting 50% inhibition of CPE. Titers  $\geq 1:4$  were considered positive.

A microneutralization test as described by Frey and Liess (1971) was used for detection of BVDV specific antibodies. One cytopathogenic BVDV strain (SH9/11) from a roe deer (*Capreolus capreolus*) (Frölich and Hofmann 1995) and three cytopathogenic BVDV strains (Grub 313/83, NADL, Osloss) were used. For the neutralization reaction 100 50% tissue culture infectious doses of BVDV were incubated with two-fold serum dilutions for 1 hr at 37 C. Subsequently,  $3 \times 10^4$  MDBK cells and bovine fetal lung cells (American Type Culture Collection, Rockville, Maryland, USA), respectively, were added to each well. Four days later cell cultures were evaluated for the presence of CPE and antibody titers were calculated. Titers  $> 1:4$  were considered positive.

## RESULTS

Infectious virus was not detected in any of the tissues, swabs, or buffy coats with one exception. A virus was isolated from the spleen of one healthy, female, 5-month-old bison calf shot in winter 1997/98. The virus was propagated on bovine fetal lung cells in the first passage and visualized by negative stain electron microscopy (Fig. 1). The virus was confirmed as BoHV-1 by staining the plaques with BoHV-1 specific antiserum and by neutralization tests. DNA from this isolate was compared to Cooper strain, which causes infectious bovine rhinotracheitis (IBR) (Madin et al.,

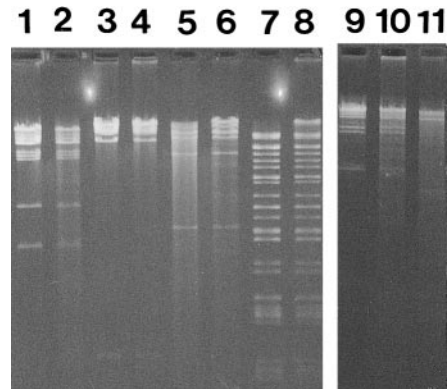


FIGURE 2. Purified viral DNA of the BoHV-1 bison isolate (lanes 2, 4, 6, 8, 10), from BoHV-1 IBR reference strains Cooper (lanes 1, 3, 5, 7, 9) as well as from IPV-strain K22 (lane 11) were digested with the restriction enzymes *Hind* III (lanes 1, 2), *Bam* HI (lanes 3, 4), *Eco* RI (lanes 5, 6), *Sal* I (lanes 7, 8) and *Hpa* I (lanes 9–11) and electrophoretically separated on a 0.7% agarose gel.

1956; Zucke and Chow, 1961), and the infectious pustular vulvovaginitis-strain K22 (Kendrick et al., 1958) by restriction enzyme digestion (Engels et al., 1981) and subtyped by the *Hpa* I restriction pattern as an IBR-strain (Gregersen et al., 1985) (Fig. 2). Additionally, two of five spleen samples of the animal tested contained BoHV-1 genomes by nested PCR. All other tissues derived from healthy animals and diseased bison were PCR negative. Tissue samples from 18 randomly selected bison tested for BoHV-4 by PCR were negative.

Various tissue samples from 25 male and 45 female bison shot since 1999 and screened by electron microscopy were negative for virus particles.

None of the animals, including the female calf with BoHV-1 in its spleen, had antibodies detectable by BoHV-1 neutralization tests or ELISA. Two female bison had a virus neutralization titer of 1:20 against BoHV-2. Because BoHV-4 does not induce significant neutralizing antibodies (Dubuisson et al., 1989), we analyzed bison sera for specific antibodies by IFA. All bison sera were negative using this test.

Antibodies against CpHV-1 and CvHV-1 were not detected.

Low BVDV specific antibodies (1:5 to 1:16) against the Grub313/83 strain were found in 11 apparently healthy and one diseased bull bison.

#### DISCUSSION

None of the bison with balanoposthitis had antibody titers against BoHV-1, BoHV-2, BoHV-4, CpHV-1, CvHV-1, or BVDV. Recovery of infectious BoHV-1 from a healthy female calf spleen, however, indicates that individual bison become infected with this virus, possibly by occasional contact with domestic cattle. The possibility of laboratory contamination can be excluded, since we not only isolated BoHV-1, but also independently detected viral DNA by nested PCR in that spleen, and because we handled the samples in BoHV-1 free areas.

Absence of detectable BoHV-1 specific antibodies in the bison calf with infectious virus in the spleen, suggests a recent infection in which the humoral immune response had not developed at the time of tissue sampling. Localization of infectious virus in the spleen further supports this assumption rather than a reactivation of latent virus, since during latency, BoHV-1 is known to be located in the trigeminal ganglia (Ackermann et al., 1982; Rock et al., 1986).

Overall, BoHV-1 was considered unlikely to have an etiologic role in balanoposthitis cases for three reasons. First, the virus was not recovered from diseased bison. Second, none of the bison had antibody titers to BoHV-1, and third, we typed the bison isolate as an IBR-strain which is generally associated with respiratory infections (Engels et al., 1981).

Low antibody titers against BVDV and BoHV-2 suggested that bison have been exposed to these or closely related viruses. Based on our serologic investigations we don't believe that BoHV-1, BoHV-2, BoHV-4, CpHV-1, CvHV-1, or BVDV are

causative agents of balanoposthitis observed in bison.

#### ACKNOWLEDGMENTS

We acknowledge T. Leiskau, B. Kirsch, K. Hönig, D. Viertel, A. Arasim, M. Szuma, L. Szuma, and H. Zalewska for excellent assistance and H. Ludwig for helpful discussions and critical comments on this project. The authors thank the Tierseuchenforschungsförderung, the Adolf and Hildegard Isler-Stiftung, the Andreas Stiehl-Stiftung, the Schaumann-Stiftung, BASF-AG, the Bayer-AG and the Riemser Arzneimittel GmbH for financial support. We also thank the Veterinary Faculty in Warsaw for the provision of 115 blood sera from European bison for serologic examinations.

#### LITERATURE CITED

- ACKERMANN, M., E. PETERHANS, AND R. WYLER. 1982. DNA of bovine herpesvirus type 1 in the trigeminal ganglia of latently infected calves. *American Journal of Veterinary Research* 43: 36–40.
- ASHBAUGH, S. E., K. E. THOMPSON, E. B. BELKNAP, P. C. SCHULTHEISS, S. CHOWDHURY, AND J. K. COLLINS. 1997. Specific detection of shedding and latency of bovine herpesvirus 1 and 5 using a nested polymerase chain reaction. *Journal of Veterinary Diagnostic Investigation* 9: 387–394.
- DUBUISSON, J., E. THIRY, M. BUBLOT, M. SNEYERS, D. BOULANGER, J. GUILLAUME, AND P. P. PASTORET. 1989. Production and characterization of monoclonal antibodies to bovid herpesvirus 4. *Veterinary Microbiology* 19: 305–315.
- ENGELS, M., F. STECK, AND R. WYLER. 1981. Comparison of the genomes of infectious bovine rhinotracheitis and infectious pustular vulvovaginitis virus strains by restriction endonuclease analysis. *Archives of Virology* 67: 169–174.
- FREY, H. R., AND B. LIESS. 1971. Vermehrungskinetik und Verwendbarkeit eines stark zytopathogenen Virusdiarrhoe/Mucosal Disease-Virusstammes für diagnostische Untersuchungen mit der Mikrotitermethode. *Zentralblatt für Veterinärmedizin* 18: 61–71.
- FRÖLICH, K., AND M. HOFMANN. 1995. Isolation of bovine viral diarrhea virus-like (BVD-like) viruses from roe deer (*Capreolus capreolus*). *Journal of Wildlife Diseases* 31: 243–246.
- GOLTZ, M., AND H. LUDWIG. 1991. Biological and molecular aspects of bovine herpesvirus 4 (BHV-4). *Comparative Immunology, Microbiology and Infectious Diseases* 2: 187–195.
- GREGERSEN, J. P., G. PAULI, AND H. LUDWIG. 1985. Bovine herpesvirus 1: Differentiation of IBR- and IPV-viruses and identification and functional role of their major immunogenic components. *Archives of Virology* 84: 91–103.

- HÄNICHEN, T., H. W. REID, H. WIESNER, AND W. HERMANN. 1998. Bösartiges Katarrhalfieber bei Zoowiedererkäuern. *Tierärztliche Praxis* 26 (G): 294–300.
- JAKOB, W., H.-D. SCHRÖDER, M. RUDOLPH, Z. A. KRASINSKI, M. KRASINSKA, O. WOLF, A. LANGE, E. COOPER, AND K. FRÖLICH. 2000. Necrobacillosis in free-living male European bison in Poland. *Journal of Wildlife Diseases* 36: 248–256.
- KENDRICK, J. W., J. H. GILLESPIE, AND K. MC-ENTEE. 1958. Infectious pustular vulvovaginitis of cattle. *Cornell Veterinarian* 48: 458–495.
- KITA, J., AND K. ANUSZ. 1991. Serologic survey for bovine pathogens in free-ranging European bison from Poland. *Journal of Wildlife Diseases* 27: 16–20.
- KRASOCHKO, P. A., I. A. KRASOCHKO, A. S. SKASHENKO, Y. P. KOCHKO, V. I. GAEVSKY, AND A. N. BUNEVICH. 1997. Propagation of infectious diseases in European bison in Belovezhskaya pushcha. In *Bleovezhskaya pushch forest biodiversity conservation*, Luchkow, A., V. Tolkach, S. Berwick and P. Brylski (eds.). World Bank Grant GEF 05-28621-BY, pp. 209–214.
- LI, H., D. T. SHEN, D. A. JESSUP, D. P. KNOWLES, J. R. GORHAM, T. THORNE, D. O'TOOLE, AND T. B. CRAWFORD. 1996. Prevalence of antibody to malignant catarrhal fever virus in wild and domestic ruminants by competitive-inhibition ELISA. *Journal of Wildlife Diseases* 32: 437–443.
- LUDWIG, H. 1983. Herpesviruses of bovidae. In *The herpesviruses*, Vol. 2. B. Roizman (ed.). Plenum Press, New York, New York, pp. 135–214.
- MADIN, S. H., C. J. YORK, AND D. G. MCKERCHER. 1956. Isolation of infectious bovine rhinotracheitis virus. *Science* 124: 721–722.
- MORENO-LOPEZ, J., M. GOLTZ, C. REHBINDER, K. V. VALSALA, AND H. LUDWIG. 1989. A bovine herpesvirus (BHV-4) as a passenger virus in ethmoidal tumours in Indian cattle. *Zentralblatt für Veterinärmedizin (B)* 36: 481–486.
- PIUSINSKI, W., W. BIELECKI, J. MALICKA, J. KITA, K. DZIABA, B. OSINSKA, K. ANUSZ, B. KOWALSKI, AND Z. LENARTOWICZ-KUBRAT. 1997. Patomorfologia i patogenez schorzenia narządu płciowego (napletka i pracia) zubrow w Puszczy Białowiejskiej. *Medycyna Weterynaryjna* 53: 596–600.
- ROCK, D. L., W. A. HAGEMOSER, F. A. OSORIO, AND D. E. REEDS. 1986. Detection of bovine herpesvirus type 1 RNA in trigeminal ganglia of latently infected rabbits by *in situ* hybridization. *Journal of General Virology* 67: 2,515–2,520.
- SCHULTHEISS, P. C., J. K. COLLINS, T. R. SPRAKER, AND J. C. DEMARTINI. 2000. Epizootic malignant catarrhal fever in three bison herds: Differences from cattle and association with ovine herpesvirus-2. *Journal of Veterinary Diagnostic Investigations* 12: 497–502.
- TARIGAN, S., AND R. J. WEBB. 1987. Caprine herpesvirus from balanoposthitis. *Australian Veterinary Journal* 38: 441–446.
- TAYLOR, S. K., V. M. LANE, D. L. HUNTER, K. G. EYRE, S. KAUFMAN, S. FRYE, AND M. R. JOHNSON. 1997. Serologic survey for infectious pathogens in free-ranging American bison. *Journal of Wildlife Diseases* 33: 308–311.
- THIRY, E., M. BUBLOT, I. DUBUISSON, AND P.-P. PASTORET. 1989. Bovine herpesvirus-4 (BHV-4) infections of cattle. In *Herpesvirus diseases of cattle*, G. Wittmann (ed.). Norwek, Kluwer Academic Publishers, London, pp. 96–115.
- , I. DUBUISSON, M. BUBLOT, M. F. VAN BRESSEM, AND P.-P. PASTORET. 1990. The biology of bovine herpesvirus-4 infection of cattle. *Deutsche Tierärztliche Wochenschrift* 97: 72–77.
- WOLF, O., W. JAKOB, H.-D. SCHRÖDER, H. NATTERMANN, M. RUDOLPH, A. LANGE, K. BORCHERS, AND K. FRÖLICH. 1986. Balanoposthitis bei Wisentent (*Bison bonasus*) im Urwald von Bielawieza (Polen). *Tierärztliche Praxis* 28 (G): 218–224.
- ZUCHECK, R., AND T. L. CHOW. 1961. Immunogenicity of two infectious bovine rhinotracheitis vaccines. *Journal of the American Veterinary Medical Association* 139: 236–237.

Received for publication 16 April 2001.