



SALT TOXICOSIS IN WATERFOWL IN NORTH DAKOTA

Authors: Windingstad, Ronald M., Kartch, Frank X., Stroud, Richard K., and Smith, Milton R.

Source: Journal of Wildlife Diseases, 23(3) : 443-446

Published By: Wildlife Disease Association

URL: <https://doi.org/10.7589/0090-3558-23.3.443>

SALT TOXICOSIS IN WATERFOWL IN NORTH DAKOTA

Ronald M. Windingstad,¹ Frank X. Kartch,² Richard K. Stroud,¹
and Milton R. Smith¹

¹ United States Fish and Wildlife Service, 6006 Schroeder Road,
National Wildlife Health Center, Madison, Wisconsin 53711, USA

² United States Fish and Wildlife Service, Des Lacs National Wildlife Refuge Complex,
Kenmare, North Dakota 58746, USA

ABSTRACT: About 150 waterfowl died and another 250 became weak and lethargic from suspected salt poisoning after using White Lake, a highly saline lake in Mountrail County, North Dakota. Frigid temperatures made fresh water unavailable, forcing the birds to ingest the saline waters with resultant toxic effects. Sick birds recovered when removed from the salt water and released into fresh water marshes. Brain sodium levels were higher in dead geese submitted for necropsy than in controls.

Key words: Waterfowl, salt toxicosis, brain sodium, saline lakes, salt glands.

INTRODUCTION

Salt poisoning is well known in domestic mammals and poultry (Scott and Krook, 1972; Buck et al., 1976), but reports in wild birds are limited. Trainer and Karstad (1960) reported accidental ingestion of salt (used for road maintenance) and subsequent mortality of ring-necked pheasant (*Phasianus colchicus*) and northern bobwhite (*Colinus virginianus*) in Wisconsin. Mountain ducks (*Tadorna tadornoides*) of western Australia were believed to be suffering from salt poisoning when forced to use saline water during drought conditions (Riggert, 1977). Sandhill cranes (*Grus canadensis*) developed salt toxicity when sea salt was added to their normal drinking water to experimentally simulate a brackish environment (Franson et al., 1981). We report here apparent salt toxicity in waterfowl from northcentral North Dakota during November 1985.

MATERIALS AND METHODS

White Lake in Mountrail County, North Dakota, covers about 1,300 ha and varies from 1 to 5 m in depth. The lake is highly saline with surface waters having sodium concentrations of over 17,000 mg/liter when measured in July 1986. The salinity is high enough to have warranted attempts by private enterprise to mine salt from the lake. About 20% of the lake had not yet frozen by early November, whereas nearby wetlands and less saline lakes had frozen by late October.

Minimum daily temperatures from the Stanley, North Dakota, weather station 6 km from White Lake reached freezing or below for 27 of 30 days before 14 November 1985, when the die-off was reported (Fig. 1). Maximum daily temperatures had been less than 0 C for 10 days before finding sick and dead birds.

Sick and dead waterfowl were reported by local landowners to personnel of the Des Lacs National Wildlife Refuge (NWR). Sixty percent of the affected waterfowl were Canada geese (*Branta canadensis*) and 30% were snow geese (*Chen caerulescens*). Other affected species included the common merganser (*Mergus merganser*), lesser scaup (*Aythya affinis*), and Ross' goose (*Chen rossii*).

Sick waterfowl were taken to shelter and released in an area containing fresh water. Supplemental grain was given to those birds unable to fly, but which could not be caught.

Dead birds were picked up and representative specimens, seven Canada geese and one snow goose, were sent to the National Wildlife Health Center (NWHC) for necropsy. After routine necropsy, tissues were submitted for virological and bacteriological examination for avian viruses and known aerobic avian bacterial pathogens and histologic processing. Brain cholinesterase activity of Canada geese was tested and compared with four hunter-killed controls as described by Hill and Fleming (1982). Brains for sodium analysis were prepared by weighing 250 mg of tissue into a grinder, adding 5 ml of distilled water, and grinding the sample into slurry. The slurry was transferred to a 50 ml volumetric flask which was filled with distilled water. One ml of 7.5% potassium chloride solution and 5 ml of the diluted brain slurry were combined and diluted to 25 ml with distilled water and analyzed by flame emission on a Per-

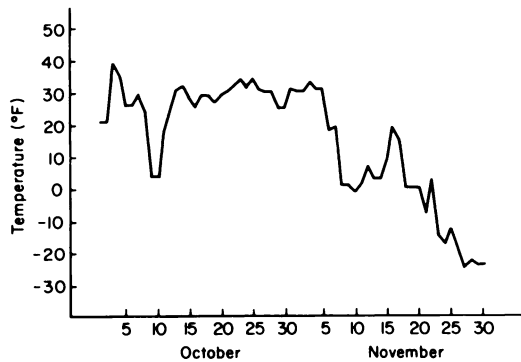


FIGURE 1. Daily minimum temperatures for October through November 1985, at Stanley near White Lake, Mountrail County, North Dakota.

kin-Elmer Model 2380 atomic absorption spectrophotometer (Perkin-Elmer Analytical Instruments, Norwalk, Connecticut) at a wave length of 589.0 nm. Standards containing 0, 1, and 3 μg sodium/ml in 0.3% potassium chloride were prepared from analytical grade sodium chloride and potassium chloride. To prevent sodium contamination, all glassware was washed with 5% nitric acid and then rinsed three times with distilled/deionized water before use. Final results were expressed as ppm (μg of sodium/g brain).

RESULTS

An estimated 150 waterfowl were found dead and another 250 observed sick on White Lake in early November 1985. Dead and sick birds were found encrusted with ice and had 3 cm or larger chunks of ice adhering to their bodies. Many were frozen to the ice and had frayed and broken wing and tail feathers resulting from attempts to free themselves from the ice. Several sick birds which were sheltered, cleaned, and given access to fresh water gained strength, regained the ability to fly and were released.

Principal findings of geese necropsied included heavy salt accumulations on feathers (Fig. 2), dehydration, excessive mucus on the mucosal surface of the proventriculus, and sloughing of the gizzard lining. Blood was thick and dark. Other conditions noted with less frequency included petechial hemorrhages on mesenteric and coronary fat, hemopericardium,

congestion of kidney and brain, swollen liver, splenic necrosis, necrosis of gizzard mucosa, and presence of urates within the lumen of the small intestine. All specimens were in good nutritional condition with abundant subcutaneous fat deposits and well-developed pectoral muscles.

Frequently observed histologic characteristics included diffuse vacuolation of liver cells and renal tubular degeneration with accumulation of proteinaceous debris in collecting ducts. Other microscopic lesions included congestion of the brain and spleen, intracytoplasmic vacuolation of the glandular tissue of adrenal glands, and some increase in cellularity of intestinal lamina propria. Compared to salt glands from waterfowl adapted to saline environments, the glands from affected waterfowl were smaller and appeared less active.

Pathogenic bacteria or virus were not recovered. Brain cholinesterase activity was not inhibited in four Canada geese found dead which strongly implies that organophosphates and carbamates were not involved in causing the die-off. Brain sodium concentrations in four affected Canada geese ranged from 1,900 to 2,100 ppm with an average of 1,993 ppm. Four control Canada geese had an average brain sodium concentration of 1,653 ppm (range = 1,600–1,710 ppm).

Fifty-five sick waterfowl were caught, taken to shelter, given fresh water, and then released. Within 48 hr, 20 of these recovered and the rest had died.

DISCUSSION

Evidence supporting our diagnosis of salt poisoning includes (1) increase in sodium concentration found in brains of affected geese compared to the concentrations found in the controls, (2) gross necropsy findings including general dehydration, occasional hemorrhages, crusted salt, and inactive supraorbital salt gland, (3) histological changes in the kidney consistent with dehydration, (4) the fact that sick birds recovered when taken into shelter

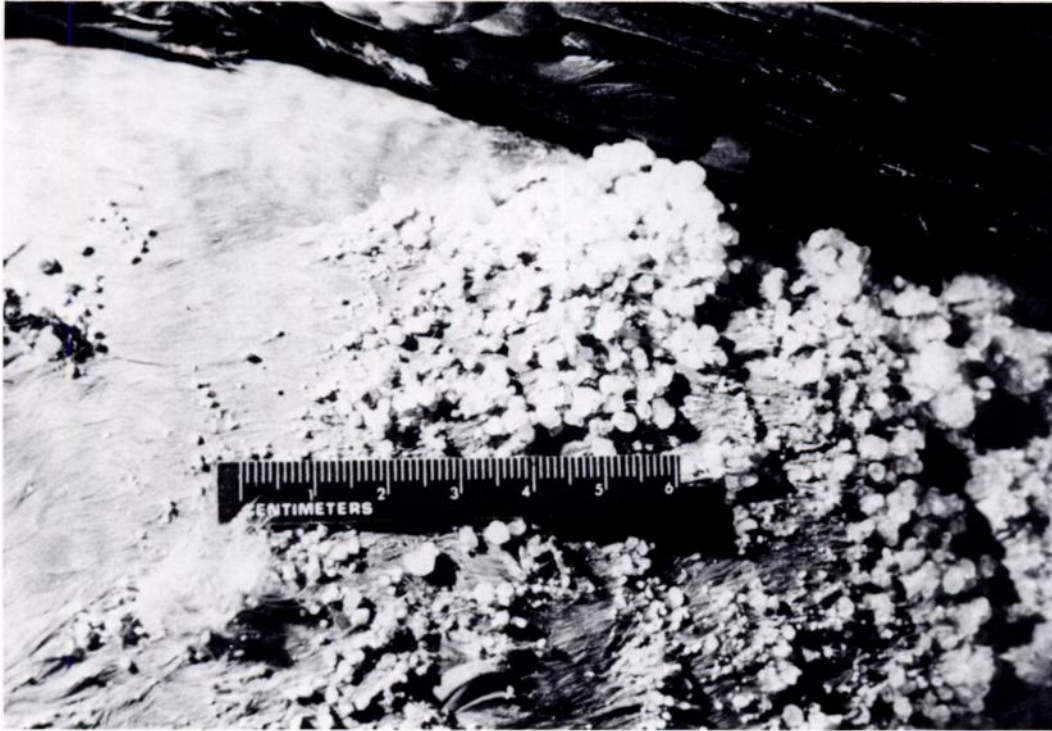


FIGURE 2. Salt accumulation on feathers of Canada goose that died of salt poisoning at White Lake, North Dakota.

and/or released after gaining access to fresh water, and (5) no evidence of other toxic, traumatic or infectious diseases.

Our pathological observations are consistent with those reported by others. Hemorrhage and visceral congestion were found by Scott and Krook (1972) in salt-poisoned poultry. Lesions observed by Selye (1943) in domestic fowl included petechial hemorrhages on mesenteric fat, swollen livers, and hemopericardium.

Sodium concentrations in the brains of our affected birds were greater than 1,800 ppm, a concentration used for tentative diagnosis of salt poisoning in swine (Buck et al., 1976), but less than the 2,104 ppm reported by Franson et al. (1981) in a sandhill crane that succumbed to salt poisoning. Brain lesions (eosinophilic meningoencephalitis) commonly seen in swine (Buck et al., 1976) were not observed. Trainer and Karstad (1960) likewise did not ob-

serve brain lesions in wild birds that died of salt toxicity.

The importance of the supraorbital salt glands to survival arises when a bird has ingested a salt load greater than that which can be handled by the kidney (Couch, 1964). The gland responds to acetylcholine which is released after the stimulation of osmoreceptors. The degree of response may be inhibited by acetylcholine inhibitors such as botulism type C toxin or organophosphate pesticides. Stress also has been shown to inhibit salt gland function (Peaker and Linzell, 1975). The capacity of the gland to secrete excess salt loads is enhanced by both hyperplasia and hypertrophy of the cellular components of the gland (Peaker and Linzell, 1975).

In species of waterfowl regularly inhabiting salt water environments, the salt gland is markedly larger than species from fresh water environments. Even within the same

species, differences in size and function of glands have been observed in birds raised in and adapted to hyperosmotic versus hypoosmotic conditions (Couch, 1964). The elimination of sodium chloride via the salt gland in response to acute osmotic stress (salt loading) is significantly greater in concentration, volume and response time in Pekin ducks that were "salt water adapted" after a period of 140 days (Schmidt-Nielsen and Kim, 1964). It must be assumed that the geese involved in this die-off were not salt adapted and may in fact have been compromised by the stress of migration, severe weather, and dehydration. Salt toxicosis occurred when the amount of ingested salts from the alkaline lake exceeded the birds' ability to excrete salt through the kidney. As they became weakened, additional factors such as salt loading on the feathers and severe weather contributed to the mortality.

Conversations with local residents indicate that this is not the first time migrating waterfowl have been lost at White Lake. Weather conditions similar to those reported here have occurred in previous years and sick and dead waterfowl have been seen. Climatological factors that allow fresh water areas to freeze and the saline White Lake to remain open for waterfowl use affect morbidity/mortality. This report documents the loss of waterfowl in 1985 to salt toxicity and indicates that previous losses may also have resulted from the ingestion of these saline waters.

ACKNOWLEDGMENTS

The authors thank the personnel at Des Lacs National Wildlife Refuge complex and the Na-

tional Wildlife Health Center for assistance with carcass pickup and laboratory analysis of tissues submitted.

LITERATURE CITED

- BUCK, W. B., G. D. OSWEILER, AND G. A. VAN GELDER. 1976. Clinical and diagnostic veterinary toxicology. Kendall/Hunt Publishing Co., Dubuque, Iowa, 380 pp.
- COUCH, F. G. 1964. A preliminary study of the survival of a functional salt gland in prairie Anatidae. *Auk* 81: 380-393.
- FRANSON, J. C., L. SILEO, AND W. J. FLEMING. 1981. Iatrogenic salt poisoning in captive sandhill cranes. *Journal of the American Veterinary Association* 179: 1211-1213.
- HILL, E. F., AND W. J. FLEMING. 1982. Anticholinesterase poisoning of birds: Field monitoring and diagnosis of acute poisoning. *Environmental Toxicological Chemistry* 1: 27-38.
- PEAKER, M., AND J. L. LINZELL. 1975. Salt glands in birds and reptiles. Cambridge University Press, Cambridge, England, 307 pp.
- RIGGERT, T. L. 1977. The biology of the mountain duck on Rottnest Island, western Australia. *Wildlife Monographs* 52: 67 pp.
- SCHMIDT-NIELSEN, K., AND Y. T. KIM. 1964. The effect of salt intake on the site and function of the salt gland of ducks. *Auk* 81: 160-172.
- SCOTT, M. I., AND L. KROOK. 1972. Nutritional deficiency diseases. In *Diseases of poultry*, M. S. Hofstad, B. W. Calnek, C. F. Helmboldt, W. M. Reid, and H. W. Yoder, Jr. (eds.). Iowa State University Press, Ames, Iowa, pp. 50-80.
- SELYE, H. 1943. Production of nephrosclerosis in the fowl by sodium chloride. *Journal of the American Veterinary Association* 163: 140-143.
- TRAINER, D. O., AND L. KARSTAD. 1960. Salt poisoning in Wisconsin wildlife. *Journal of the American Veterinary Association* 136: 14-17.

Received for publication 19 September 1986.