



Successful correction of flat-chested kitten syndrome in two littermate kittens

Authors: Fusi, Jasmine, Bagardi, Mara, Bassi, Jessica, Ferrari, Francesco, and Veronesi, Maria Cristina

Source: Journal of Feline Medicine and Surgery Open Reports, 10(2)

Published By: SAGE Publishing

URL: <https://doi.org/10.1177/20551169241273665>



Successful correction of flat-chested kitten syndrome in two littermate kittens

Jasmine Fusi, Mara Bagardi, Jessica Bassi , Francesco Ferrari and Maria Cristina Veronesi

Journal of Feline Medicine and Surgery Open Reports
1–8

© The Author(s) 2024

Article reuse guidelines:

sagepub.com/journals-permissions

DOI: 10.1177/20551169241273665

journals.sagepub.com/home/jfmsopenreports

This paper was handled and processed by the European Editorial Office (ISFM) for publication in *JFMS Open Reports*



Abstract

Case summary Two 18-day-old domestic shorthair kittens presented with dyspnoea, mild cyanosis, heart murmur, lung pattern, abnormal crawling and a marked dorsoventral flattening of the thorax. Deformity of the thoracic wall without pectus excavatum was diagnosed. Cardboard corsets tailored to each kitten were applied. This gave immediate respiratory relief, easing distress and pain. After 10 days, clinical and radiographic monitoring revealed normalisation of the shape of the chest wall with an improvement in general condition. At 6 months of age, clinical examination showed normal growth and development of both kittens, with a normal thoracic profile and shape also seen on radiographs.

Relevance and novel information Data about flat-chested kitten syndrome and its aetiopathogenesis, treatment and outcome are scarce, but there is significant experience among breeders that is shared through online communities. High mortality rates are reported. The use of a cardboard splint appears to be novel in the published literature; in this case report, it proved to be a rapid and easy solution. For this reason, cardboard splints could be considered as a first approach for the clinical management of flat-chested kitten syndrome.

Keywords: Kitten; flat chest; cardboard corset; successful outcome

Accepted: 10 July 2024

Introduction

Flat-chested kitten syndrome (FCKS) is a pathological condition mainly reported in oriental breeds, notably Burmese and Bengal cats. In these breeds, deformities of the thoracic wall are described in 3–4% and 5% of kittens born, respectively,^{1,2} sharing some familial bloodline origins. However, thoracic deformities can be considered to be of multifactorial origin.¹ FCKS is characterised by a reduction in the thoracic dorsoventral diameter, giving a ‘flattened’ appearance of the thorax without bone defects or deviations. It differs from pectus excavatum in which the narrowed thoracic profile is caused by a sternbral deviation.³ Kittens are often referred for dyspnoea, suckling problems, failure to gain weight, reduced activity and lethargy. The disease is reported to be fatal in 50–60% of cases;^{1,4,5} however, spontaneous resolution is sometimes reported within hours to days,¹ with no more evidence of flattening. The etiopathogenesis is not clear,

but several possible causes have been suggested. A myopathy of diaphragmatic and intercostal muscles may pave the way for this condition when combined with the elasticity of the neonatal skeletal system.¹ Taurine has a role in neuromuscular tissue functionality, and a link between its tissue concentrations and the onset of FCKS is still debated.^{1,6} FCKS was more often diagnosed in kittens from dams with a taurine-depleted diet,⁶ but in affected Burmese kittens, higher concentrations of taurine in circulating blood were found.¹ Therefore, the real

Department of Veterinary Medicine and Animal Sciences, Università degli Studi di Milano, Italy

Corresponding author:

Jessica Bassi DVM, Department of Veterinary Medicine and Animal Sciences, Università degli Studi di Milano, Via dell'Università, 6, Lodi, 26900, Italy
Email: jessica.bassi@unimi.it



Creative Commons Non Commercial CC BY-NC: This article is distributed under the terms of the Creative Commons

Attribution-NonCommercial 4.0 License (<https://creativecommons.org/licenses/by-nc/4.0/>) which permits non-commercial use, reproduction and distribution of the work without further permission provided the original work is attributed as specified on the SAGE and Open Access pages (<https://us.sagepub.com/en-us/nam/open-access-at-sage>).

impact of taurine on the disease remains unclear. As has been described in human babies,⁷ chest wall bone deformities have been associated with a lysosomal storage disease in kittens,⁸ with a report of rib angular deformities in a kitten affected by mucopolysaccharidosis type VII.⁹

To the authors' knowledge, to date, limited peer-reviewed literature on FCKS is available, especially regarding treatment and outcome. This case report describes the clinical aspects and treatment with cardboard corsets of two kittens affected by FCKS.

Case report

Two kittens aged 18 days were referred to the Veterinary Teaching Hospital (VTH) of Università degli Studi di Milano (Milan, Italy) for dyspnoea.

Medical history

A domestic shorthair queen gave birth to five kittens. Two kittens (one male and one female) died after 2 days, and three females survived. A post-mortem examination on one kitten revealed *Streptococcus agalactiae* and *Staphylococcus aureus* infections, and an antimicrobial sensitivity test was performed.

Over the first 17 days of life, two littermates (kitten 1, K1, and kitten 2, K2) showed progressive unsatisfactory suckling, occasional dysphagia, prolonged crying, anorexia and lethargy. In addition, K1 showed severe dyspnoea and was hospitalised. Chest flatness was not detected at this time by the attending veterinarian in any of the kittens.

Clinical examination

Before physical examination, K1 required overnight hospitalisation with oxygen delivered via face mask. On examination, both kittens had a normal body weight for their age, although slightly less than the other surviving littermate (K1: 265 g, K2: 255 g, other littermate: 287 g), normal neonatal reflexes for age, normothermia, mild cyanosis, severe (K1) and mild (K2) dyspnoea, tachycardia and tachypnoea, and occasional crying. Discomfort and panting were also seen when the kittens were placed on an examination surface and they were reluctant to crawl correctly. Auscultation revealed severe (K1) and mild (K2) respiratory sounds, along with a systolic basal heart murmur graded 3/6 (K1) and 1/6 (K2). Through palpation, severe (K1) and moderate (K2) dorsoventral thorax flattening with profile deformity was detected, while no abnormalities were detected during abdominal palpation in both kittens. In addition, mild ventral thorax skin scrapes were observed in K2 and mild sialorrhoea in K1.

Diagnostics

Thoracic radiographic examinations of both kittens were performed (Figure 1): subjective reduction in the

dorsoventral diameter of the thorax was visible, the ribs were parallel to each other and the rib cage assumed a barrel shape on the ventrodorsal view. Frontosagittal and vertebral indices were measured (FSI and VI, respectively) (Table 1), and values obtained were consistent with thoracic deformity.¹⁰ There were also areas of increased lung opacity with faint air bronchograms along the ventral aspect of the cranial and medial lung lobes. These changes were more severe in K1 and consistent with pneumonia.

Treatment

To avoid putting weight on the deformed thorax, and to possibly pursue a correction of the thoracic wall profile, a corset derived from cardboard tubes was tailored for each kitten, slightly modified from what has been described for puppies.¹¹ A C-shaped corset was built and covered with medical cotton to protect the skin. It was then covered with medical tape (Figure 2), applied and covered with elastic gauze (Self Fix; Pic Solution) (Figure 3). To avoid displacement while crawling, a spica bandage was applied (Figure 4). These corsets were light and allowed a space of approximately 1 cm between the ventral thoracic wall and the corset, distributing the body weight and preventing the kitten from loading its entire body weight on the ventral thoracic wall. This, and the space left, allowed a better expansion of the thorax during respiratory dynamics. A few minutes after application, both kittens showed general improvement with better viability, attempts at crawling, regularised respiratory rates and vigorous suckling behaviours.

According to the radiographic lung pattern suggesting pneumonia and based on the antimicrobial susceptibility test performed on the dead littermate, K1 was treated with antibiotics (amoxicillin + clavulanic acid 25 mg/kg q12h PO). In addition, a multivitamin supplement (Nutribound; Virbac) was prescribed to both kittens (1.5 ml per kitten/day for 15 days).

Clinical follow-up

Over the first 14 days of follow-up, a daily update with data, photos and videos was requested to assess the general status of the kittens. Details of respiratory conditions such as cyanosis, dyspnoea, respiratory efforts and daily weight gain of both kittens were also requested. However, on day 5, the owners spontaneously decided to remove the corsets at home. This led to a relapse of the clinical signs a few hours later, so the patients were promptly brought back to VTH, where the corsets were reapplied. At 11 days after the first consultation, a clinical examination at VTH showed good general condition, a steady increase in body weight, and normal growth and development of both kittens according to their age and when compared with the other normal littermate. The heart murmur had also improved

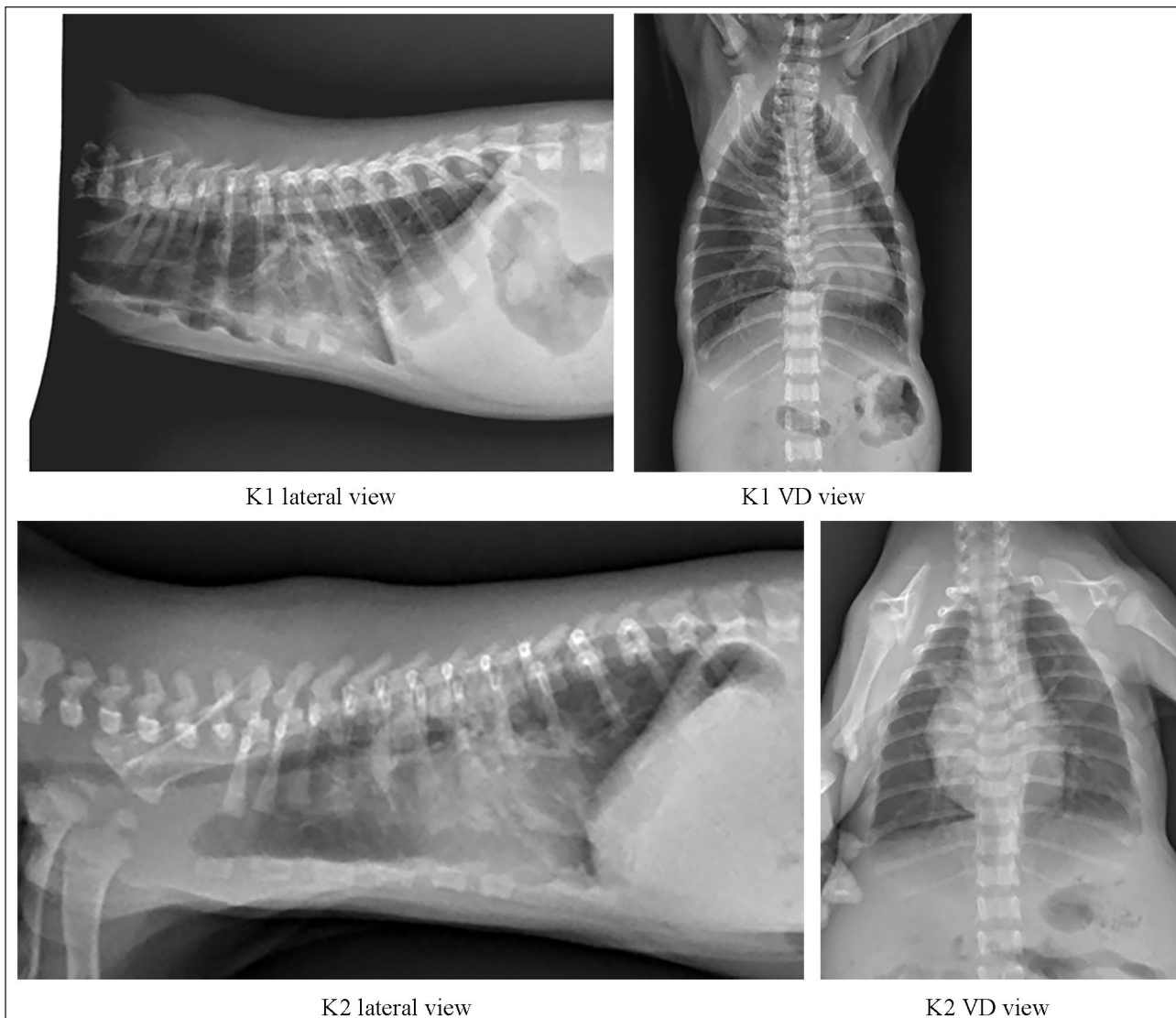


Figure 1 Lateral and ventrodorsal (VD) views of kitten 1 (K1) and kitten 2 (K2) at presentation

Table 1 Radiographic FSI and VI measurements at presentation and follow-ups in kitten 1 (K1) and kitten 2 (K2)

		FSI	VI
Normal values ¹⁰		0.7–1.3	12.6–18.8
Presentation	K1	1.9	10.9
	K2	2	10
Follow-up at 11 days	K1	1.8	11.3
	K2	1.7	10.4
Follow-up at 47 days	K1	1	14
	K2	1.2	14.5
Follow-up at 6 months of age	K1	0.9	18
	K2	1	15.5

FSI = frontosagittal index; VI = vertebral index



Figure 2 C-shaped corset derived from cardboard tubes covered with cotton and medical tape

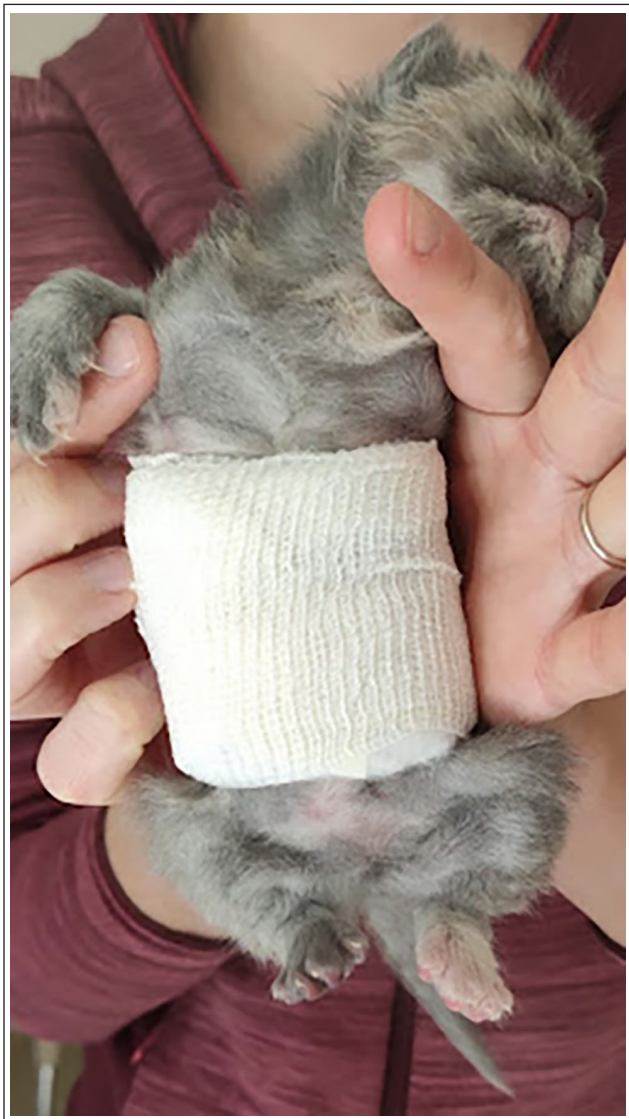

Figure 3 Application of the C-shaped corset, covered with elastic gauze

(1/6 in both kittens), and no respiratory noises were detected. Palpation revealed a clear improvement of the thoracic wall shape, while radiographic examination

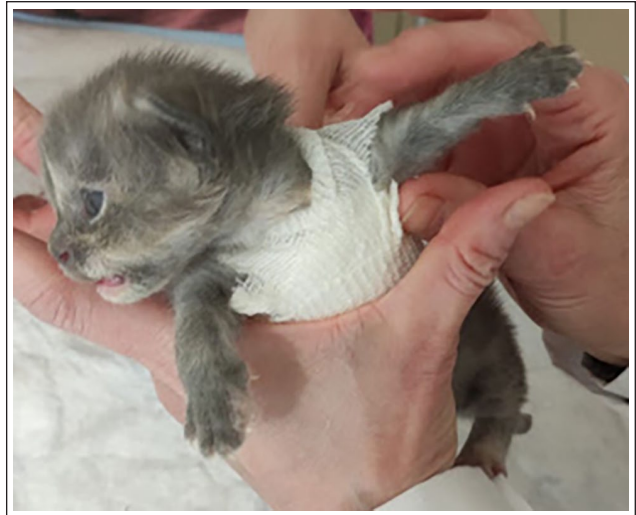

Figure 4 After application, a spica bandage was applied to avoid displacement of the corset

showed a progressive reduction of the lung opacity (Figure 5). At the age of 1 month, the corsets were removed to facilitate proper walking.

Over the following month, email follow-ups were required every 3 days to ensure the kittens were developing normally without relapsing, until a subsequent follow-up visit when clinical and diagnostic examinations were performed (Figure 6).

At 6 months of age, a complete clinical examination of both kittens confirmed normal thoracic morphology, body weight (K1: 2.4kg, K2: 1.9kg, normal littermate: 2.4kg) and development. Thoracic radiographs and echocardiography showed the absence of thoracic abnormalities and normal values of FSI and VI,¹⁰ and excluded echocardiographic and electrocardiographic abnormalities (Figure 7).

Discussion

Although rare, FCKS can impair wellbeing and the chance of survival in affected individuals, depending on its severity.¹ Because of the scarce data available about possible treatments and outcomes, in the present cases, the authors chose to apply a cardboard corset. The corsets were modelled on those described for puppies with pectus excavatum,¹¹ and successfully corrected the thoracic wall deformity. Radiographic evaluation and measurement of FSI and VI confirmed the chest deformity and the progressive normalisation at follow-ups.¹⁰ The kittens were admitted with different degrees of dyspnoea, but both displayed poor general condition, marked thoracic wall deformity and abnormal positioning of the body on the floor, which, in turn, prevented the development of normal crawling according to age. The authors chose not to use 3D-printed prostheses as their first choice of treatment

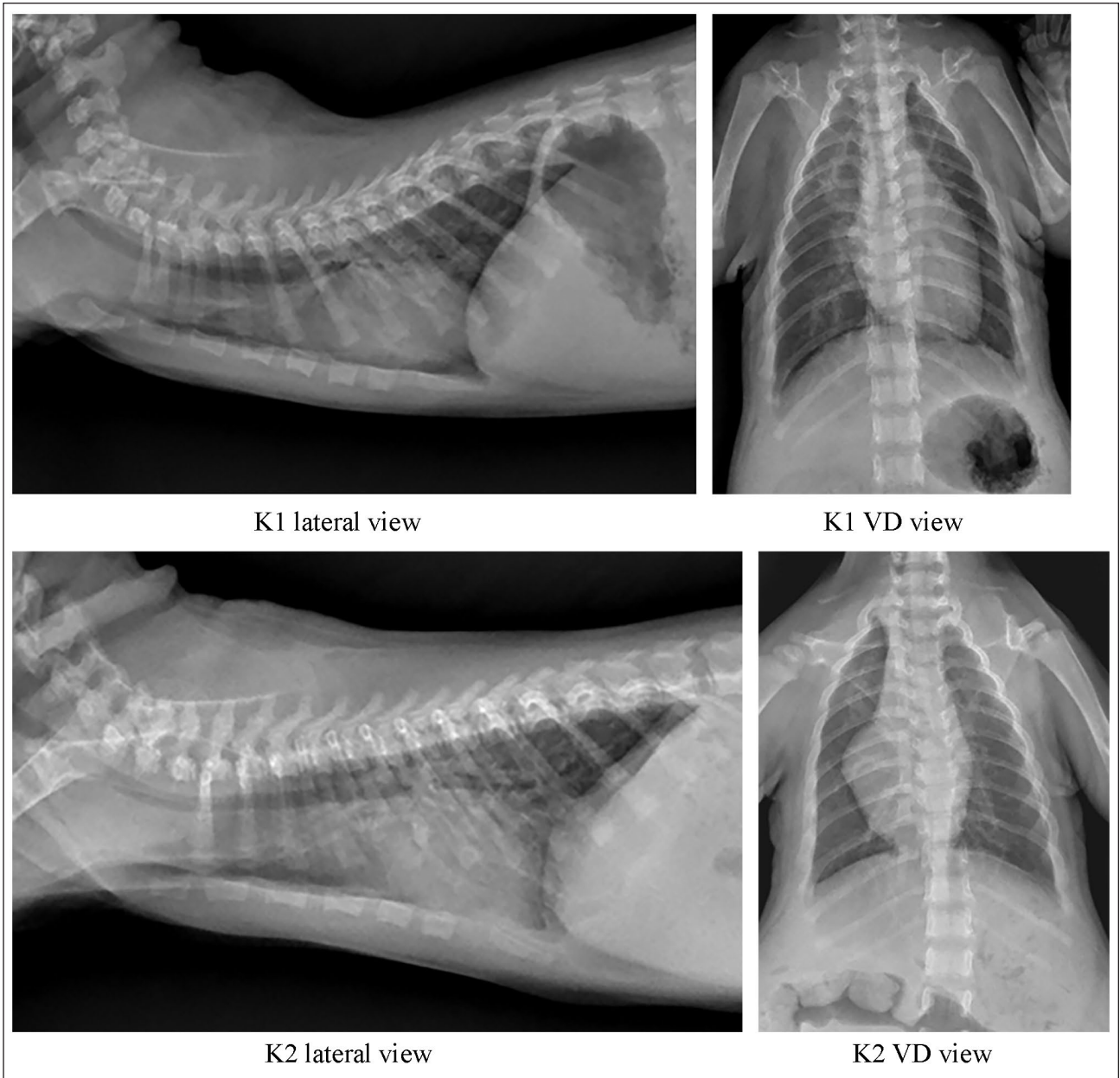


Figure 5 Clinical follow-up 11 days after treatment: lateral and ventrodorsal (VD) views of kitten 1 (K1) and kitten 2 (K2)

so as to provide a rapid solution and avoid the need for CT imaging with anaesthesia in diseased newborn kittens and having to wait for the prostheses to be made. Most importantly, the prompt application of the corsets led to rapid relief of dyspnoea and improvement in general condition, even without the use of painkillers. The quick improvement observed could be the result of several mechanisms. First, leaving space between the thorax and the corset allowed better pulmonary expansion with more efficient respiration, improving general condition. Second, with the same mechanism, the pain due to the body weight load on the thorax, though difficult to evaluate objectively, was probably relieved by

the corsets. The more severe dyspnoea in K1 could also be attributable to heart deviation, in turn caused by the abnormal compression of the chest, which might have impaired oxygenation, as previously reported.^{12,13} Even if a possible spontaneous recovery without corset application cannot be excluded, the relapse of the clinical signs when the owners removed the corsets 5 days after application and their disappearance after corset reapplication suggests the effectiveness of the corset. The great improvement of the thoracic wall profile after only 10 days of corset application underlines the strong plasticity of the neonatal skeletal system. This can be responsible for the rapid onset of the disease, but on the

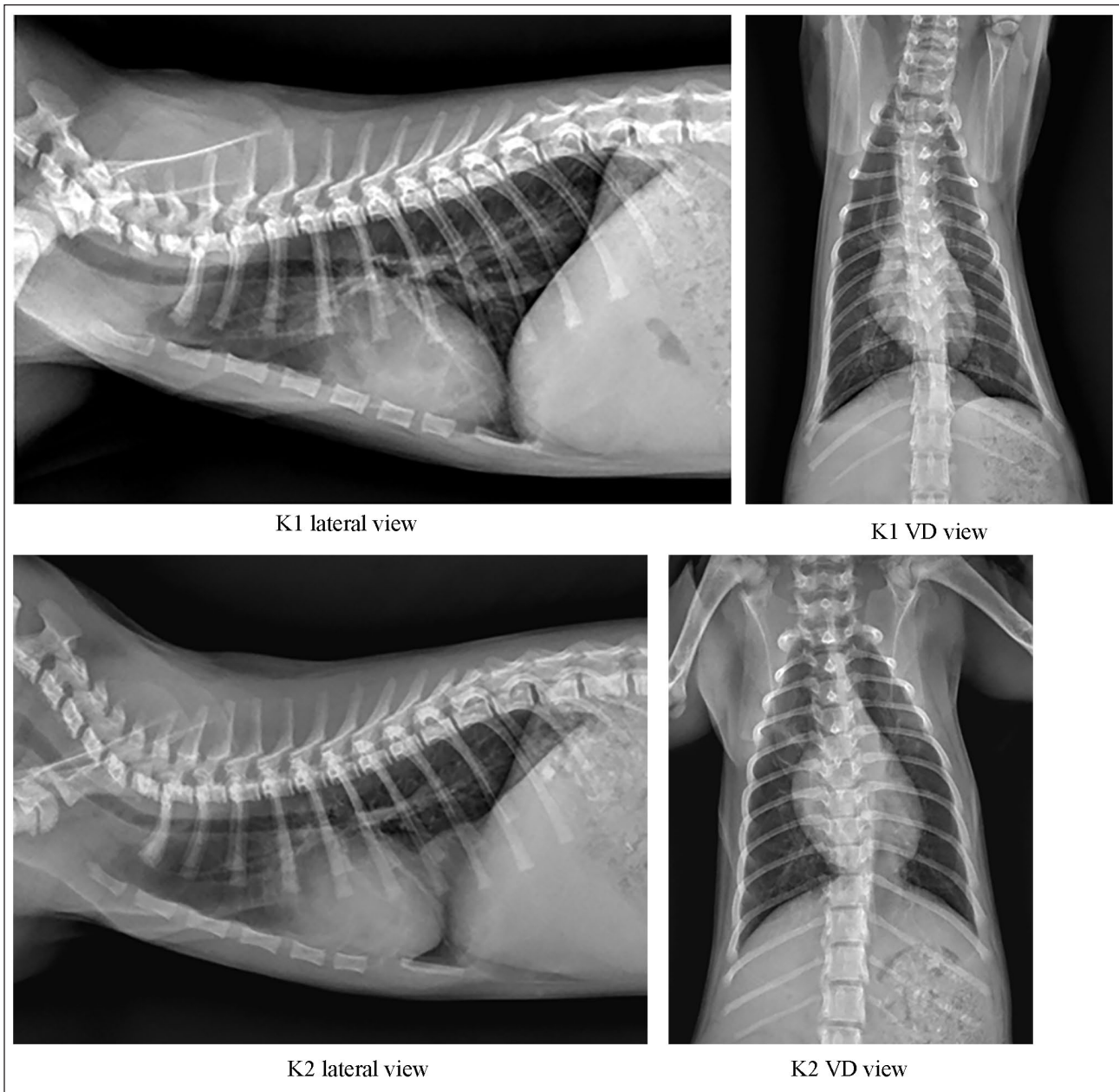


Figure 6 Clinical follow-up 47 days after treatment: lateral and ventrodorsal (VD) views of kitten 1 (K1) and kitten 2 (K2)

other hand explains the quick improvement of the thoracic profile observed.

The follow-ups at 47 days after treatment and at 6 months of age confirmed the normalisation of the thoracic wall profile and the absence of congenital heart diseases. Impaired systolic function, in particular of the right ventricle, pericardial effusion and malignant ventricular arrhythmias were also ruled out.

Conclusions

Corsets derived from cardboard tubes could be considered a handy, easy and cheap first-step approach for the rapid management of kittens affected by FCKS, especially in emergency care, alongside supportive therapy. The successful outcome also suggests that cardboard corsets could be useful tools for the correction of FCKS in cases not complicated by pectus excavatum.

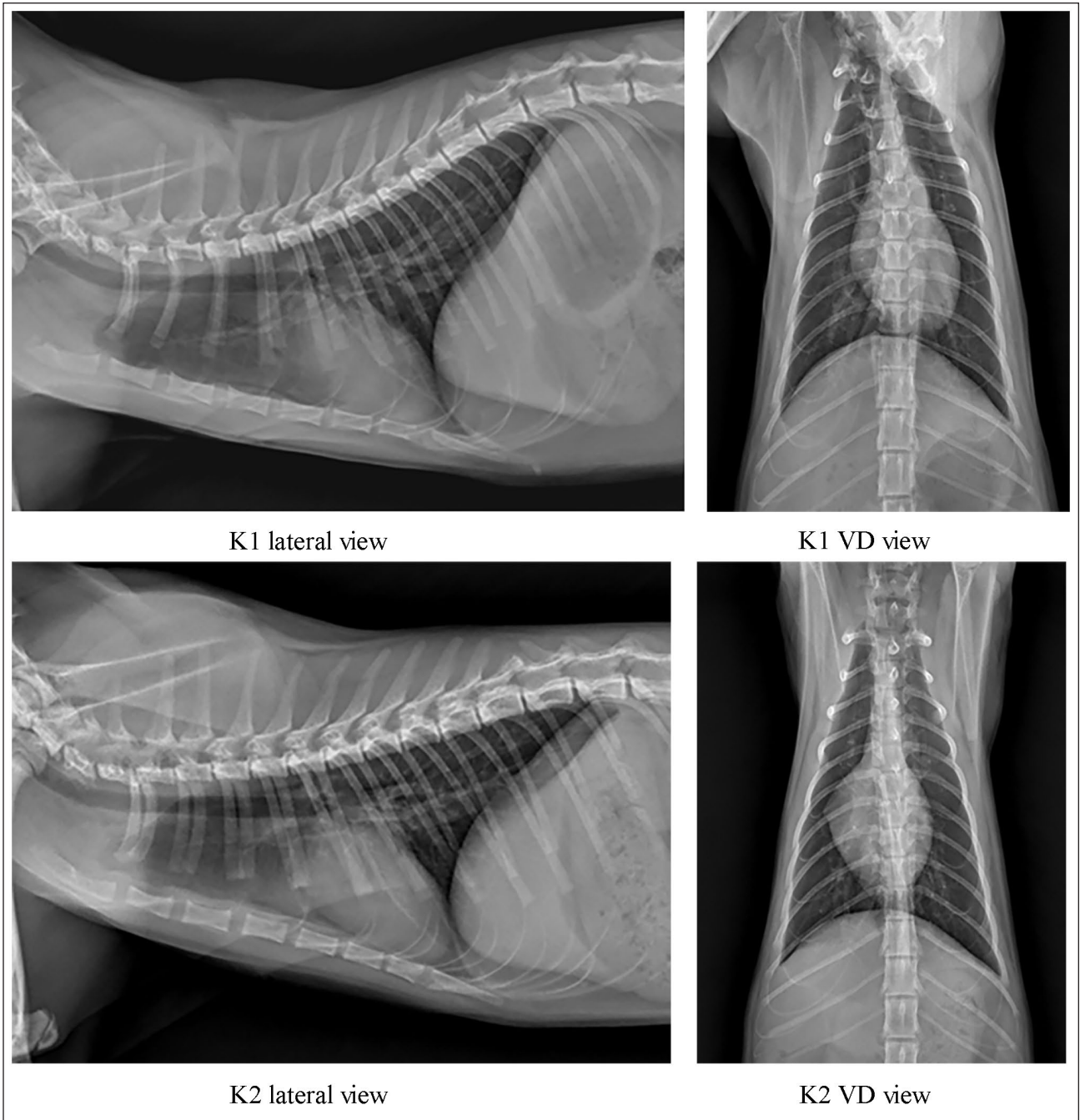


Figure 7 Follow-up at 6 months of age: lateral and ventrodorsal (VD) views of kitten 1 (K1) and kitten 2 (K2)

Conflict of interest The authors declared no potential conflicts of interest with respect to the research, authorship, and/or publication of this article.

Funding The authors received no financial support for the research, authorship, and/or publication of this article.

Ethical approval The work described in this manuscript involved the use of non-experimental (owned or unowned) animals. Established internationally recognised high standards ('best practice') of veterinary clinical care for the individual

patient were always followed and/or this work involved the use of cadavers. Ethical approval from a committee was therefore not specifically required for publication in *JFMS Open Reports*. Although not required, where ethical approval was still obtained, it is stated in the manuscript.

Informed consent Informed consent (verbal or written) was obtained from the owner or legal custodian of all animal(s) described in this work (experimental or non-experimental animals, including cadavers, tissues and samples) for all

procedure(s) undertaken (prospective or retrospective studies). For any animals or people individually identifiable within this publication, informed consent (verbal or written) for their use in the publication was obtained from the people involved.

ORCID ID Jessica Bassi  <https://orcid.org/0009-0006-0776-8161>

References

- 1 Sturgess CP, Waters L, Gruffydd-Jones TJ, et al. **Investigation of the association between whole blood and tissue taurine levels and the development of thoracic deformities in neonatal Burmese kittens.** *Vet Rec* 1997; 141: 566–570.
- 2 Charlesworth TM and Sturgess CP. **Increased incidence of thoracic wall deformities in related Bengal kittens.** *J Feline Med Surg* 2012; 14: 365–368.
- 3 Orton EC. **Thoracic wall.** In: Slatter D (ed). *Textbook of small animal surgery*. 3rd ed. Philadelphia: Saunders, 2003, pp 373–386.
- 4 Boudrieau RJ, Fossum TW, Rudy RL, et al. **Pectus excavatum in dogs and cats.** *Compend Contin Educ Pract Vet* 1990; 12: 341–354.
- 5 Soderstrom MJ, Gilson SD and Gulbas N. **Fatal reexpansion pulmonary edema in a kitten following surgical correction of pectus excavatum.** *J Am Anim Hosp Assoc* 1995; 31: 133–136.
- 6 Sturman JA, Palackal T, Imaki H, et al. **Nutritional taurine deficiency and feline pregnancy and outcome.** In: Huxtable RJ, Franconi F and Giotti A (eds). *The biology of taurine*. New York: Springer, 1987, pp 113–124.
- 7 Yamauchi K, Hirano D, Wada M, et al. **Pectus carinatum as the key to early diagnosis of Morquio A syndrome: a case report.** *J Med Case Rep* 2021; 15: 150. DOI: 10.1186/s13256-021-02737-1.
- 8 Cheville NF. **Malattia genetica.** In: Cornaglia E and Valenza F (eds). *Patologia generale veterinaria*. Torino: Utet Scienze Mediche, 2003, pp 297–313.
- 9 Schultheiss PC, Gardner SA, Owens JM, et al. **Mucopolysaccharidosis VII in a cat.** *Vet Pathol* 2000; 37: 502–505.
- 10 Yoon HY, Mann FA and Jeong SW. **Surgical correction of pectus excavatum in two cats.** *J Vet Sci* 2008; 9: 335–337.
- 11 Pereira KHNP, Fuchs KDM, Terçariol LAA, et al. **Two types of management for the noninvasive treatment of pectus excavatum in neonatal puppies-case reports.** *Animals (Basel)* 2023; 13. DOI: 10.3390/ani13050906.
- 12 Phillips JD and Hoover JD. **Chest wall deformities and congenital lung lesions: what the general/thoracic surgeon should know.** *Surg Clin North Am* 2022; 102: 883–911.
- 13 Monnet E. **Thoracic wall.** In: Orton EC, Monnet E (eds). *Small animal thoracic surgery*. Hoboken: Wiley-Blackwell, 2018, pp 65–76.