



Caudal and middle segmental mandibulectomies for the treatment of unilateral temporomandibular joint ankylosis in cats

Authors: Villamizar-Martinez, Lenin A, Ferro, Daniel G, Carvalho, Vanessa G, Ferreira, Jonathan, and Reiter, Alexander M

Source: Journal of Feline Medicine and Surgery Open Reports, 8(1)

Published By: SAGE Publishing

URL: <https://doi.org/10.1177/20551169221086438>



Caudal and middle segmental mandibulectomies for the treatment of unilateral temporomandibular joint ankylosis in cats

Journal of Feline Medicine and Surgery Open Reports
1–13

© The Author(s) 2022

Article reuse guidelines:

sagepub.com/journals-permissions

DOI: 10.1177/20551169221086438

journals.sagepub.com/home/jfmsopenreports

This paper was handled and processed by the American Editorial Office (AAFP) for publication in *JFMS Open Reports*



Lenin A Villamizar-Martinez¹ , Daniel G Ferro¹,
Vanessa G Carvalho², Jonathan Ferreira³
and Alexander M Reiter⁴

Abstract

Case series summary Three cats affected by unilateral temporomandibular joint ankylosis underwent segmental mandibulectomy, while one cat with bilateral ankylosis underwent right temporomandibular joint gap arthroplasty and left segmental mandibulectomy. Minimal intraoperative complications were linked to the segmental mandibulectomies in the cases reported. All cats recovered their ability to open the mouth, and the vertical range of motion was unaltered during the postoperative period. Mandibular drift and dental malocclusion were the main postoperative complications related to the segmental mandibulectomies.

Relevance and novel information Surgical excision of ankylotic tissue at the temporomandibular joint region may be technically challenging and associated with severe iatrogenic trauma of surrounding tissues. The results of this case series suggest that middle or caudal segmental mandibulectomy is a safe, feasible and effective surgical procedure to treat unilateral temporomandibular ankylosis in cats and could be considered as an alternative surgical technique to surgical excision of ankylotic tissue at the temporomandibular joint.

Keywords: Ankylosis; temporomandibular joint; mandibulectomy; osteotomy

Accepted: 22 February 2022

Introduction

Temporomandibular joint ankylosis (TMJA) is an uncommon, debilitating condition reported in several species. It is characterized by the abnormal mobility of one or both temporomandibular joints (TMJs).^{1,2} This condition leads to partial or near-total inability to open the mouth. Veterinary patients suffering from this condition may show an interest in food but have difficulty with prehension. Clinical findings include weight loss, vocalizing or whining while trying to eat, malocclusion, skull malformation, halitosis and unkempt haircoat owing to reduced self-grooming.^{3–6}

TMJA results from intra- (true TMJA) and extra-articular (false TMJA or pseudoankylosis), bony, fibrous or fibro-osseous tissue proliferation from traumatic, neoplastic or degenerative processes. Diagnosis of TMJA is based on the patient's history, clinical signs and

diagnostic imaging.^{2,5,7,8} Although radiographic orthogonal projections of the head have been used for TMJA diagnosis, more advanced imaging techniques such as

¹Dentistry and Oral Surgery Service, Department of Clinical Sciences, College of Veterinary Medicine, North Carolina State University, Raleigh, NC, USA

²Smile4pets, Veterinary Dentistry Service, Sao Paulo, SP, Brazil

³Odontovet, Veterinary Dentistry Center, Sao Paulo, SP, Brazil

⁴Dentistry and Oral Surgery Service, Department of Clinical Sciences and Advanced Medicine, School of Veterinary Medicine, University of Pennsylvania, Philadelphia, PA, USA

Corresponding author:

Lenin A Villamizar-Martinez DVM, MSc, PhD, DAVDC, Dentistry and Oral Surgery Service, Department of Clinical Sciences, College of Veterinary Medicine, North Carolina State University, 1060 William Moore Drive, Raleigh, NC 27607, USA
Email: lavillam@ncsu.edu



Creative Commons Non Commercial CC BY-NC: This article is distributed under the terms of the Creative Commons

Attribution-NonCommercial 4.0 License (<https://creativecommons.org/licenses/by-nc/4.0/>) which permits non-commercial use, reproduction and distribution of the work without further permission provided the original work is attributed as specified on the SAGE and Open Access pages (<https://us.sagepub.com/en-us/nam/open-access-at-sage>).

conventional CT and cone beam CT (CBCT) are currently considered the gold standard techniques for TMJ bone assessment.⁹⁻¹² In humans, MRI is regarded as a gold standard diagnostic imaging technique for evaluating the articular disk and the joint surrounding soft tissue. Its use and clinical application in the dog and cat have not yet been determined.¹³⁻¹⁵

Surgical removal of the ankylotic tissue through condylectomy, gap arthroplasty or wide extra-articular osteotomy has been advocated for treating this condition in dogs and cats.^{3,16} However, these surgical techniques have been anecdotally associated with intraoperative iatrogenic complications such as severe hemorrhage, nerve damage and suboptimal abnormal tissue removal. Postoperative complications such as inability to blink, decreased range of motion of the mandibles and TMJA recurrence have also been linked to the techniques mentioned above.¹⁶⁻¹⁸

Segmental mandibulectomy was previously recommended as a salvage surgical technique for patients suffering from TMJA.^{19,20} A recent study performed in cadaver heads of cats determined the mandibular region to be ectomized during a segmental mandibulectomy.²¹ This research showed that caudal segmental mandibulectomy (CSM), performed between the first molar tooth and the angle of the mandible, and middle segmental mandibulectomy (MSM), performed between the fourth premolar and first molar teeth, could be suitable

procedures for treating patients with unilateral TMJA. CSM and MSM could be considered alternative surgical options for patients affected by unilateral TMJA as they are less time-consuming, less challenging from an anatomical standpoint and safer. As segmental mandibulectomies avoid the complex anatomy of the base of the skull and the temporomandibular region, we hypothesized that these techniques could decrease the risk of intraoperative iatrogenic trauma and postoperative complications associated with surgical procedures involving the TMJ and the base of the skull.²¹ Thus, the purpose of this retrospective study was to evaluate the CSM and MSM applicability for the treatment of unilateral TMJA in three cats and one cat with bilateral TMJA that underwent gap arthroplasty on one of the TMJs and CSM on the contralateral mandible.

Case report

Medical and diagnostic imaging records from four cats that underwent CSM and MSM to treat TMJA at three veterinary dental and oral surgery reference centers were retrospectively assessed. Patients that underwent condylectomy, gap arthroplasty or wide extra-articular osteotomy of the temporomandibular region as the only treatment were excluded from this study. Data collected from the records for each patient included breed, sex, age, physical examination findings, history and type of TMJA (intra- vs extra-articular) (Table 1).

Table 1 Demographic data, history and diagnosis

Cat	Breed	Sex	Age (months)	Weight (kg)	Clinical findings at physical examination	History	Diagnosis
1	DSH	MC	36	4.1	Malocclusion, severe gingivitis, halitosis, mandibular deformation, dental fractures and inability to open the mouth (RM = 10 mm approximately)	Hit by a car; left compressive temporomandibular fracture at 29 months of age	Left intra-articular TMJA
2	DSH	F	10	2.5	Malocclusion, severe mandibular asymmetry, severe gingivitis and stomatitis, halitosis, foreign body, low weight, unkempt hair coat, inability to open the mouth (RM = 7 mm approximately)	Bite trauma from another cat at first month of age	Right intra- and extra-articular TMJA
3	DSH	M	39	3.5	Malocclusion, mandibular deformation, severe gingivitis, missing teeth, halitosis, low weight, unkempt hair coat, inability to open the mouth (RM = 7 mm approximately)	Unknown	Bilateral TMJA
4	DSH	M	8	2.8	Severe gingivitis, progressive inability to open the mouth after mandibular trauma (RM = 10 mm approximately)	Left caudal mandibular fracture	Left extra- and intra-articular TMJA

DSH = domestic shorthair; MC = male castrated; RM = range of vertical mandibular motion; TMJA = temporomandibular joint ankylosis; F = female; M = male

All patients in this study underwent general anesthesia for both the diagnostic imaging and surgical procedures. Before the anesthetic events, a comprehensive physical examination was performed, and complete blood count and chemistry panel were obtained. Blood tests for the four cats were within the reference intervals. Physical examinations were performed by a board-certified dentist (cats 1 and 2) or a Brazilian veterinary dental and oral surgery specialist (cats 3 and 4). A board-certified anesthesiologist or veterinarian with special interest in anesthesia established the anesthesia protocols according to each patient’s clinical status. Three cats underwent general anesthesia twice (cats 2, 3 and 4), first for diagnostic imaging and then for the surgical procedure. Owing to financial restrictions, one cat had the same anesthetic event for diagnostic imaging and surgery (cat 1). Two cats had a temporary tracheotomy performed as previously described in the literature for general anesthesia. One patient (cat 3) underwent a temporary tracheotomy twice, the first for the CT scan and the second for the surgical procedure. Table 2 summarizes the anesthetic and postoperative pain-management protocols used in the cases of this study.

Case 1

A 36-month-old male castrated domestic shorthair (DSH) cat was presented to the Dentistry and Oral Surgery Service at the School of Veterinary Medicine of the University of Pennsylvania (DOSS-UPENN) for inability to open the mouth, halitosis and malocclusion. The patient had a history of motor vehicular trauma 8 months prior to presentation to DOSS-UPENN. On physical examination, the maximum range of vertical mandibular motion was about 1 cm. The left eye was absent owing to previous enucleation, and skeletal asymmetry at the left temporomandibular region was noted on palpation.

CT scan, intraoral assessment and surgical procedure were performed during the same anesthetic event. Tomographic images revealed an old comminuted malunion fracture of the left coronoid process and ipsilateral TMJ. Although bone proliferation was not observed, fibrous tissue was suspected (Figure 1). After confirming that the pathological process presented at the left TMJ region was consistent with TMJA, it was decided to perform a MSM.

MSM: intraoral approach As described in a previous study,²¹ a full-thickness mucoperiosteal flap between the mandibular fourth premolar and first molar teeth was made. Sharp dissection with periosteal elevators separated the gingival and mucoperiosteal tissues from the ventrolateral surface of the mandibular body. The osteotomy was accomplished with a #700L carbide bur in a sterile high-speed dental handpiece, cooled by

Table 2 Anesthesia and postoperative medications

Cat	Tracheostomy?	Anesthetic protocol		Induction	Regional anesthesia	Maintenance	Postoperative medications
		Premedication					
1	Yes	Atropine (0.08mg/kg), ketamine (3mg/kg), hydromorphone (0.4mg/kg), midazolam (0.1mg/kg)		Propofol (5mg/kg)	Left inferior alveolar nerve block, extraoral approach (bupivacaine 1mg/kg)	Isoflurane: low-flow, closed-circuit system at an oxygen flow rate	Fentanyl patch 25µg/h, gabapentin (10mg/kg PO, q8h for 7 days), meloxicam (0.05mg/kg PO q24h for 7 days)
2	No	Butorphanol (0.2mg/kg), midazolam (0.2mg/kg), dexmedetomidine (4mg/kg), ketamine (3mg/kg)		Propofol (5mg/kg)	Right inferior alveolar nerve block, extraoral approach (bupivacaine 1mg/kg and lidocaine 2mg/kg)	Isoflurane: low-flow, closed-circuit system at an oxygen flow rate	Buprenorphine hydrochloride (0.01mg/kg SL q12h for 7 days); robenacoxib (1mg/kg PO q24h for 3 days)
3	Yes	Dexmedetomidine (10µg/kg), methadone (0.25mg/kg)		Propofol (5mg/kg)	Left inferior alveolar nerve block, extraoral approach (bupivacaine 1mg/kg)	Isoflurane: low-flow, closed-circuit system at an oxygen flow rate	Meloxicam (0.05mg/kg PO q24h for 7 days), dipyrone (25mg/kg PO q24h for 5 days)
4	No	Methadone (0.2mg/kg), midazolam (0.2mg/kg)		Propofol (5mg/kg)	Not performed	Isoflurane: low-flow, closed-circuit system at an oxygen flow rate	Prednisolone (1mg/kg PO q24h for 4 days); dipyrone (25mg/kg PO q24h for 4 days)

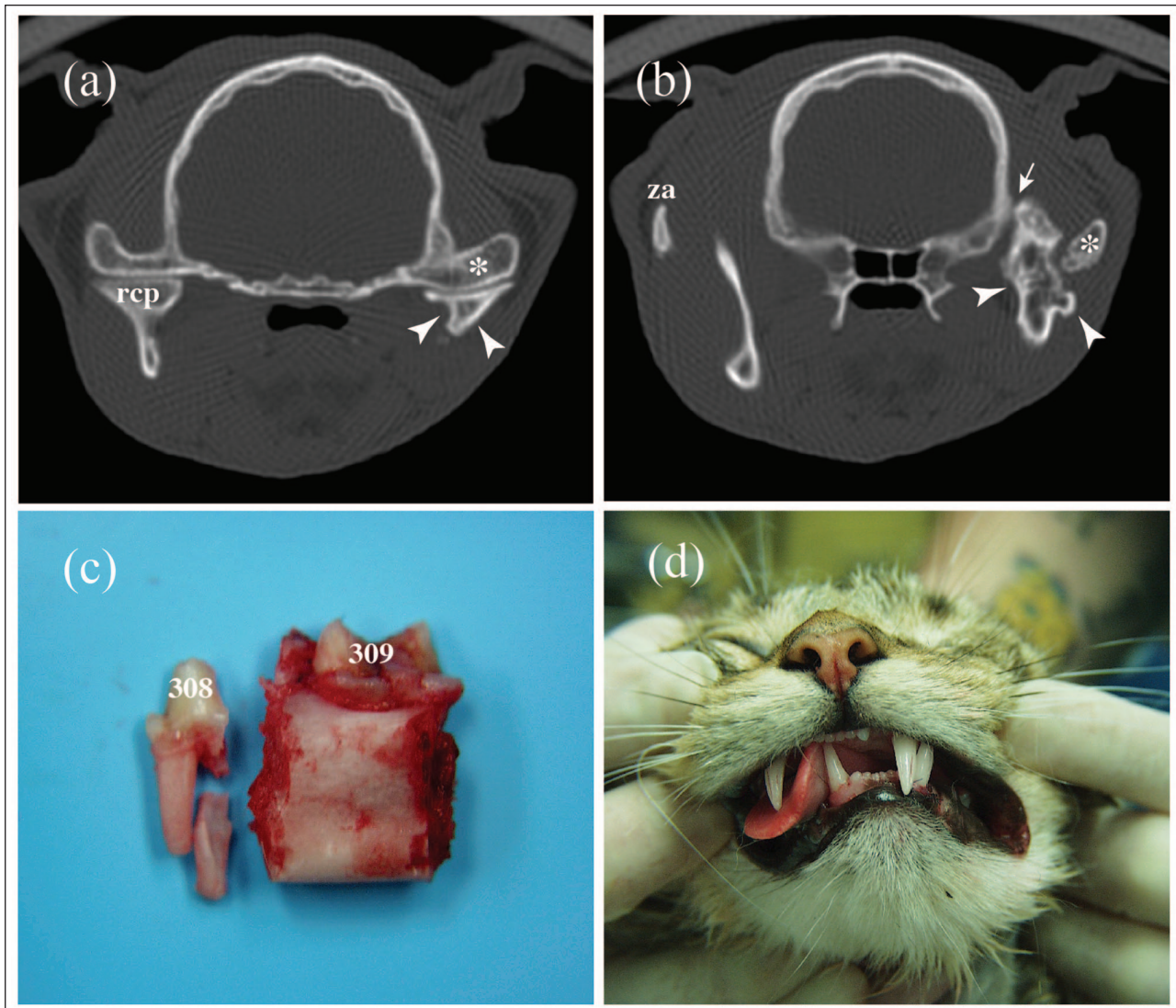


Figure 1 (a,b) CT transversal reconstructions using bone algorithm, (c) excised anatomical specimen and (d) postoperative malocclusion of a 36-month-old male domestic shorthair castrated cat affected by left intra-articular temporomandibular joint ankylosis. (a) Misshapen left condylar process (arrowheads) and thickening of the petrous part of the temporal bone (asterisk). Right coronoid process (rcp). (b) Bone tissue proliferation at the left ramus of the mandible (arrowheads). Note how the abnormal mineralized tissue extends to the lateral skull surface (arrow). Thickened abnormal left zygomatic arch (asterisk). Normal right zygomatic arch (za). (c) Mandibular segment removed during the middle segmental mandibulectomy. Left mandibular four premolar (308) and first molar teeth (309). (d) Immediate postoperative left mandibular drift. The right mandibular canine tooth occludes at the hard palate mucosa

irrigation with lactated Ringer's solution. It was started on the buccoventral surface and extended to the lingual aspect of the mandible. The rostral osteotomy was made at the mandibular fourth premolar's furcation. The bone was cut partially around the mandibular canal to avoid iatrogenic trauma to the inferior alveolar neurovascular bundle. Minnesota and Senn tissue retractors were used during the osteotomy to avoid iatrogenic trauma to the adjacent sublingual and buccal soft tissues.

A dental elevator was inserted into the osteotomy line and carefully rotated to break any remaining bony attachments around the mandibular canal without

causing damage to the inferior alveolar neurovascular bundle. Next, the bundle was ligated at the rostral aspect of the mandibular segment and transected. A caudal osteotomy was made at the distal margin of the first molar tooth in a similar fashion to that already described to expose, ligate and transect the neurovascular bundle. After excision of the mandibular segment, the remaining mesial root of the fourth premolar tooth was extracted using a dental elevator. Sharp edges at the osteotomy sites of the remaining mandible were smoothed with a sterile #22 round diamond bur in a high-speed hand-piece while irrigating with lactated Ringer's solution.

The mucoperiosteal flap was intraorally sutured in a simple interrupted pattern with 4-0 absorbable monofilament suture material (poliglecaprone 25).

Case 2

A 10-month-old female DSH cat was presented to the DOSS-UPENN for inability to open the mouth, severe

halitosis, poor body condition and mandibular deformation. The patient had sustained bite trauma from another cat at 2 months of age. On physical examination, the patient was bright and alert. Unkempt hair coat and low body weight (2.5 kg), severe mandibular asymmetry and mandibular shifting to the right were observed. Severe gingivitis and stomatitis were noted due to hair

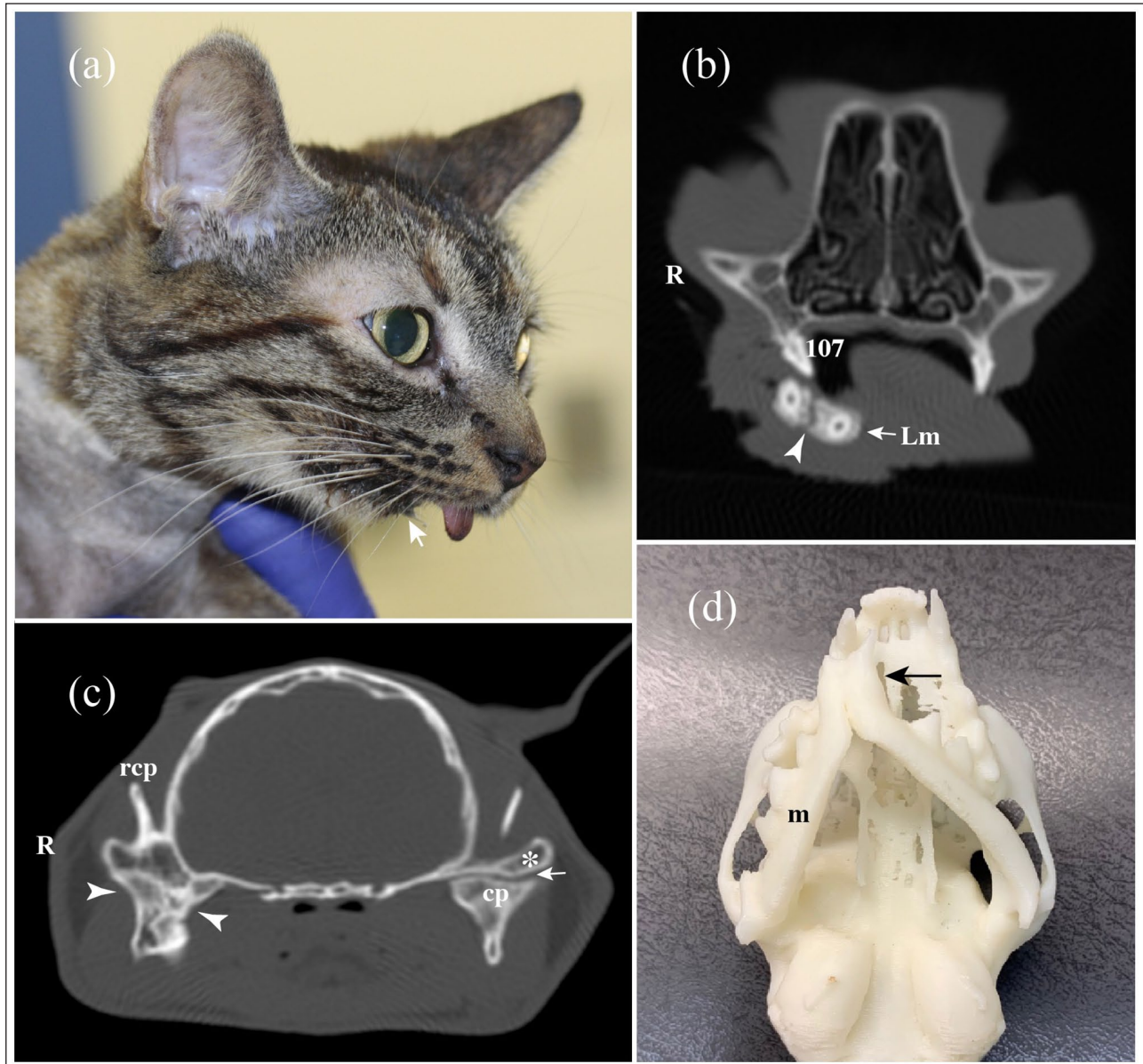


Figure 2 (a) Lateral view of the head, (b,c) CT transversal reconstructions using bone algorithm and (d) three-dimensional printing model of a 10-month-old female domestic shorthair cat affected by unilateral (right) intra- and extra-articular temporomandibular joint ankylosis (TMJA). (a) Mandibular distocclusion (arrow) and sialorrhea. (b) Right mandibular drift. Left mandible (Lm), mandibular symphysis (arrowhead) and palatovertebral 107. (c) Irregular bone proliferation at the right temporomandibular joint (arrowheads). Note how the right coronoid process (rcp) is fused to the ankylotic tissue. Even though the left condylar process appears mildly sclerotic (cp), the joint space is still present (arrow). Zygomatic process of the temporal bone (asterisk). (d) Mandibular drifting and asymmetry (arrow). Note how the mandible affected by TMJA appears shorter (m) than the contralateral mandible

impaction and food accumulation in the right maxillary and mandibular vestibular sulci. The rest of the physical examination was unremarkable.

CT scan images revealed a misshapen right TMJ with absence of the joint space and bone proliferation between the caudal aspect of the mandibular ramus and the TMJ. A three-dimensional printed model was used to demonstrate to the pet owner the severe mandibular asymmetry and malocclusion. After diagnosing right intra- and extra-articular TMJA, the patient underwent MSM using a combined buccotomy–intraoral approach (Figures 2 and 3).

MSM: combined buccotomy–intraoral approach A combined buccotomy–intraoral approach was performed to expose the mandibular segment between the fourth premolar and first molar teeth. For the buccotomy, the skin around the commissure was clipped, prepared aseptically and draped, while the oral cavity was rinsed with 0.12% chlorhexidine solution. A rostrocaudal full-thickness skin–oral mucosa incision from the lip commissure was made, followed by blunt tissue dissection. The rostral aspect of the masseter muscle was retracted to expose the portion of the mandible that would be removed.

The rest of the procedure, including flap design, osteotomy, breaking of remaining bony attachments and ligation of the inferior alveolar neurovascular bundle, was carried out as described for case 1. The intraoral mucoperiosteal flap was sutured to the sublingual mucosa with a 5-0 absorbable monofilament suture (poliglecaprone 25) in a simple interrupted pattern. Tissue apposition at the commissure incision was made first at the oral mucosa using the same suture material and technique. The second- and third-layer closures were performed with continuous subcutaneous and subcuticular suture patterns, respectively. The skin was sutured with 4-0 non-absorbable monofilament material (nylon) in a cruciate pattern.

Case 3

A 39-month-old male DSH cat presented to a veterinary dentistry and oral surgery referral centre in Brazil (Smile4pets) for evaluation of an inability to open the mouth and malocclusion. The patient exhibited severe halitosis, gingivitis, dental calculus and several missing teeth on physical examination. CT showed bilateral bone proliferation along the caudal portion of the zygomatic arches, coronoid processes and both TMJs. Bone proliferation was observed extending from the region of the angle of the left mandible to the pterygoid bone (Figure 4).

Gap arthroplasty of the right TMJ was performed as described in the literature,¹⁶ while wide excision at the left TMJ region was elected. No intra- or postoperative complications were reported to the gap arthroplasty performed on the right side. However, owing to the

intraoperative challenge after initiating the removal of the abnormal tissue that extended near the left ventrolateral aspect of the skull, a CSM was considered as a subjectively safer surgical option to remove the ankylotic tissue at the left TMJ region. Inferior alveolar neurovascular bundle laceration and Horner's syndrome occurred during the intra- and postoperative periods, respectively. Persistent inability to blink the left eye was present up to 3 months postoperatively.

CSM As described in a previous study,²¹ after hair clipping, aseptic preparation and draping of the surgical region, a 3.5 cm long full-thickness skin incision at the ventrocaudal border of the mandibular body was performed. This incision allowed exposure of the ventral margin of the mandible between the first molar tooth and the rostral aspect of the mandibular foramen. The buccal and lingual soft tissues were raised dorsally with a periosteal elevator to reach the level of the gingiva.

Mandibular osteotomies were made at the first molar tooth furcation and the rostral aspect of the mandibular foramen using a #700L carbide bur in a sterile high-speed dental handpiece irrigated with lactated Ringer's solution. Breaking of remaining bony attachments and ligation and transection of the inferior alveolar neurovascular bundle rostrally and caudally were made as described earlier. After excision of the mandibular segment, the remaining distal root of the first molar tooth was extracted using a dental elevator. Sharp edges at the osteotomy sites of the remaining mandible were smoothed with a sterile round diamond bur under irrigation.

The wound was briefly irrigated with chlorhexidine 0.12% and then thoroughly rinsed with lactated Ringer's solution. Sublingual and buccal soft tissue apposition was achieved with 4-0 monofilament absorbable suture material (poliglecaprone 25) in a simple interrupted suture pattern. Subcuticular continuous, subcutaneous continuous and cruciate suture patterns were used for skin apposition. The gingival tissue was intraorally sutured in a simple interrupted pattern with 5-0 absorbable monofilament suture material (poliglecaprone 25).

Case 4

Patient 4 was an 8-month-old male DSH cat diagnosed with left intra- and extra-articular TMJA after a previous bilateral mandibular fracture. The initial surgical approach at the referring veterinarian included a wire cerclage placed at the mandibular symphysis to treat a symphyseal separation and a taped muzzle to treat fractures at the left TMJ and right caudal mandibular body. While the mandibular symphysis and caudal portion of the right mandible had healed after 4 weeks, the range of mouth opening gradually decreased. The patient was referred after 2 months from the initial trauma to a veterinary dentistry and oral surgery facility

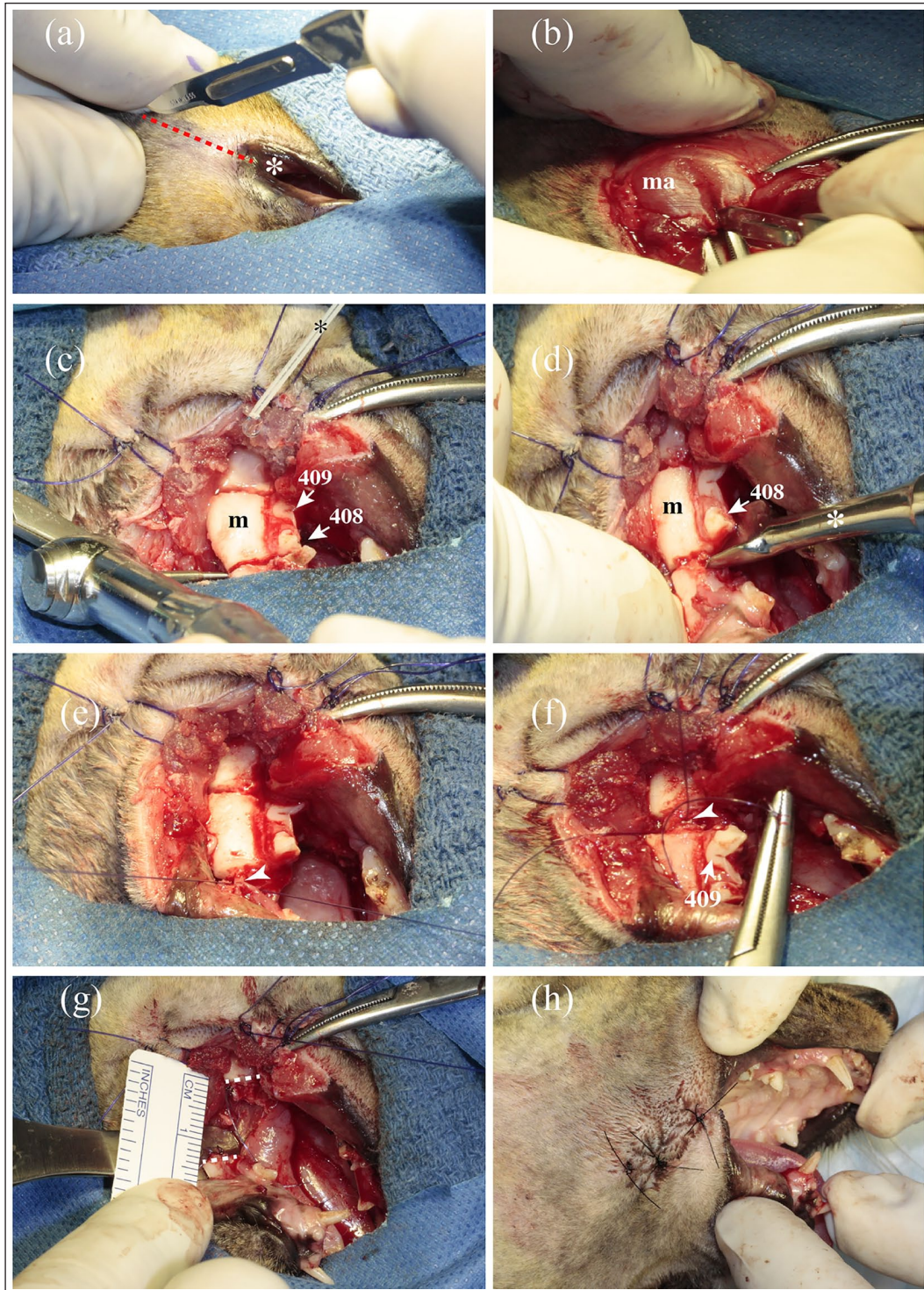


Figure 3 Middle segmental mandibulectomy (MSM): combined buccotomy–intraoral approach. (a) A rostrocaudal 1–2 cm length full-thickness skin–oral mucosa incision was made at the right labial commissure (asterisk) using a scalpel blade #15 (dashed line), (b) followed by sharp and blunt dissection with Metzenbaum scissors of the masseter muscle (ma). (c) The masseter muscle is retracted to expose the portion of the mandible (m) between the fourth premolar (408) and first molar (409) teeth. Osteotomy was performed through the furcation area of 408 and the distal margin of 409. (d) Rotation of a dental elevator inside the osteotomy (asterisk) allowed separation of the remaining bony attachments, thus preserving the inferior alveolar neurovascular bundle. (e) Ligature and transection of the inferior alveolar neurovascular bundle (arrowhead). (f) The same technique as in (d) to separate the mandibular segment at its caudal margin, followed by ligature and transection of the neurovascular structures (arrowhead). (g) Mandibular gap after removal of the mandibular segment (dashed lines). (h) Immediate postoperative range of motion. The skin is sutured with non-absorbable suture material in a cruciate pattern

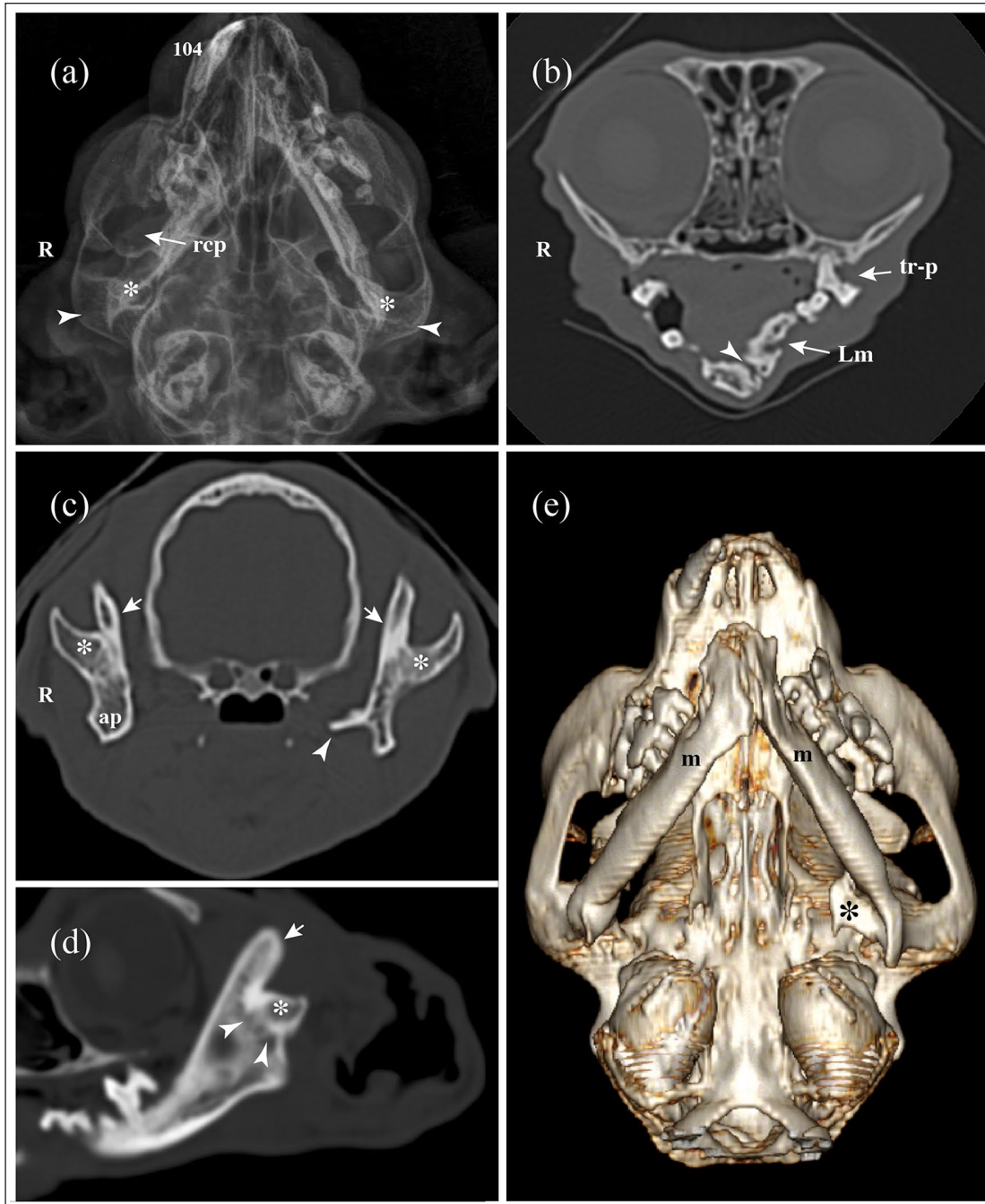


Figure 4 (a) Dorsoventral head radiograph, (b–d) CT bone window multiplanar and (e) three-dimensional volumetric reconstructions of a 36-month-old domestic shorthair cat suffering from bilateral intra- and extra-articular temporomandibular joint ankylosis. (a) Abnormal bilateral condylar process conformation (asterisks) with absence of the articular space (arrowheads). Overlapping bone structures in the temporomandibular joint (TMJ) regions do not allow evaluation of the actual extent of ankylotic tissue. Right coronoid process (rcp) and maloccluded right maxillary canine tooth (104). (b) Transversal reconstruction at the level of the eye globe. Bilateral malformation of the rostral aspect of the mandibles. The left mandible (Lm) appears more dorsally positioned than the right mandible. Mandibular symphysis (arrowhead). Periodontitis and tooth resorption of 208 (tr-p). (c) Transversal reconstruction shows fusion between the zygomatic process of the temporal bones (asterisks) and the caudal surface of the ramus of the mandibles (arrows). Note the thickening of the right angular process (ap) and bone proliferation at the ventromedial region of the left mandible (arrowhead). (d) Right TMJ sagittal reconstruction showing total obliteration of the joint space (arrowheads) and absence of distinct anatomical structures of the TMJ, such as the mandibular head of the condylar process of the mandible and mandibular fossa and retroarticular process of the temporal bone (asterisk). Right coronoid process (arrow). (e) Note the irregular bone proliferation at the ventromedial aspect of the caudal region of the mandible (asterisk) and bilateral shortening of the mandibular bodies causing malocclusion (m)

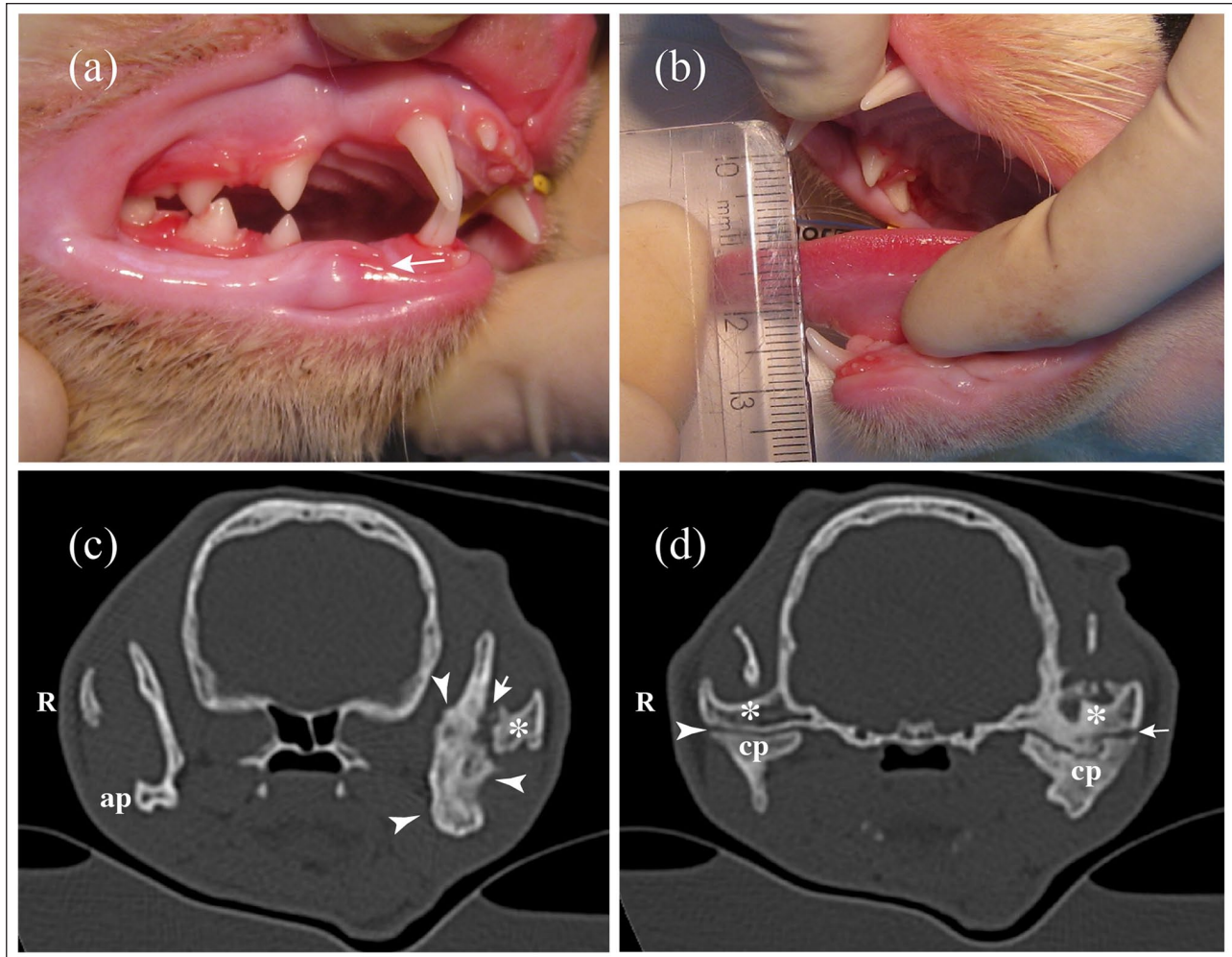


Figure 5 (a) Pre- and (b) postoperative vertical range of mandibular motion and CT transversal reconstructions using bone algorithm of an 8-month-old male domestic shorthair cat affected by unilateral (left) intra- and extra-articular temporomandibular joint ankylosis. (a) The teeth were scaled and the mouth rinsed with chlorhexidine gluconate 0.12%. Note the generalized gingivitis, moderate mandibular distorsion (arrow) and decreased vertical range of mandibular motion. (b) Postoperative vertical range of mandibular motion. (c) Irregular bone proliferation affecting the left mandibular ramus (arrowheads). Note the hypoattenuating irregular area (arrow) between the misshapen ramus of the mandible and the zygomatic process of the temporal bone (asterisk), suggesting that the bone proliferation was fractured during forceful opening of the mouth. The angular process of the right mandible (ap) appears projected to the lateral aspect of the ramus of the mandible, which could confirm the history of a caudal mandibular fracture. (d) Ankylosis affects the left TMJ. Notice the hypoattenuating irregular space (arrow) between the mandibular fossa (asterisks) and condylar process of the mandible (cp), suggesting a pseudo-joint formation after forceful opening of the mouth. Right TMJ space (arrowhead)

in Brazil (Odontovet) for further evaluation, diagnostic imaging and surgical procedure.

CT showed a severely misshapen left TMJ with irregular bone proliferation, causing fusion of the caudal aspect of the coronoid process to the joint. Although the left TMJ space was present, it appeared distorted. Other CT abnormalities confirmed previous trauma to the mandibles (Figure 5). A CSM was elected, as described for case 3.

All cats in this case series report showed immediate postoperative ability to eat a soft diet. No assisted feeding was needed, such as syringe feeding or an

esophageal tube. All cats also gained weight, recovered their grooming habits and the ability to bite during playing. Diagnostic imaging and surgical techniques, intra- and postoperative complications, and follow-up for the patients of this study are summarized in Table 3.

Discussion

The authors of the present study previously evaluated the feasibility of segmental mandibulectomy for the treatment of unilateral TMJA in a cadaver cat model.²¹ Rostral segmental mandibulectomies, CSMs and MSMs were compared, demonstrating significantly improved

Table 3 Diagnostic imaging, surgical technique, and intra- and postoperative complications

Cat	Diagnostic imaging	Diagnosis	Surgical technique	Intraoperative complication and treatment	Immediate postoperative RM	Follow-up – postoperative complications
1	Skull radiographs and CT scan	Left intra-articular TMJA	Left MSM 308–309 (AMSr = 10mm)	Mandibular drift and malocclusion (selective dental extractions, odontoplasty 304, 404)	NR	4-week recheck: persistent mandibular drift and malocclusion; ability to open the mouth stable. Weight = 4.4 kg
2	CT scan and 3D printing	Right intra- and extra-articular TMJA	Right MSM 408–409 (AMSr = 10mm)	Mandibular drift and malocclusion (selective dental extractions of maloccluded teeth)	27 mm approximately	48-week recheck: persistent mandibular drift, postoperative RM stable. Weight = 3.6 kg
3	Skull radiographs and CT scan	Bilateral TMJA	Left CSM (caudal margin of 309 – rostral region MF) (AMSr = 13mm); gap arthroplasty of the right TMJ	Iatrogenic laceration of the left inferior alveolar neurovascular bundle (temporary compression and double circumferential ligature); full-mouth extractions owing to severe periodontitis	38 mm approximately	Immediate postoperative left eye (Horner's syndrome); 12-week recheck: persistent inability to blink the left eye 56-week recheck: mandibular drift; postoperative RM stable Weight = 4.3 kg
4	Skull radiographs and CT scan	Left intra- and extra-articular TMJA	Left CSM (caudal margin of 309 – rostral region MF) (AMSr = 14 mm)	Mandibular drift and malocclusion	30 mm approximately	152-week recheck (mild mandibular drift); postoperative RM stable. Weight = 4.5 kg

RM = range of motion; TMJA = temporomandibular joint ankylosis; MSM = middle segmental mandibulectomy; AMSr = approximated mandibular segment removed; NR = not reported; 3D = three-dimensional; CSM = caudal segmental mandibulectomy; MF = mandibular foramen; TMJ = temporomandibular joint

recovery of mouth opening when CSMs and MSMs were performed (90.4% and 81.9% recovery, respectively) compared with only 50.4% improvement with rostral segmental mandibulectomy.²¹ To our knowledge, the present case series regarding the use of CSMs and MSMs for the treatment of unilateral TMJA is the first of its kind in client-owned cats.

The etiology of TMJA in dogs and cats can vary, but the consensus in the literature is that trauma is the leading cause.^{1,2,4,6,20} Young patients in particular have a tendency to develop rapidly progressing unilateral or bilateral TMJA after trauma. This is possibly due to the intense healing capacity of damaged bone tissue at a young age, which leads to exuberant fibrous and bone tissue formation in the TMJ region. Surgical excision of the abnormal proliferative tissue has been recommended for TMJA treatment. However, this technique can be associated with intra- and postoperative complications. Iatrogenic trauma of neurovascular structures such as the maxillary artery or facial nerve branches could lead to severe intraoperative hemorrhage and postoperative neurological deficiencies, respectively.^{8,16,22}

The immediate postoperative left-eye Horner's syndrome and persistent inability to blink in case 3 could be associated with iatrogenic trauma during the initial attempt to surgically remove ankylotic tissue in the left TMJ region. Horner's syndrome has previously been linked to damage of the efferent sympathetic nervous system of the eye during TMJ trauma, while damage of the auriculopalpebral nerve – a branch of the facial nerve – could be the reason for the blinking deficiency.²³ Both Horner's syndrome and blinking disorders associated with surgical procedures at the temporoauricular region are usually temporary. However, temporary or persistent conditions may require additional care, such as application of artificial eye drops to prevent corneal ulcers.

Intraoperative iatrogenic trauma to the left inferior alveolar neurovascular bundle was reported in case 3. Such injury can occur during the osteotomy of the mandible, manipulation of the mandibular segment, and during and after ligation and transection of the neurovascular bundle. Even though the use of a sterile high-speed dental handpiece is not contraindicated for

maxillofacial surgery, soft tissue can become entrapped in the spinning burs when not used properly and carefully.²⁴⁻²⁶ Piezoelectric devices may reduce the trauma to underlying soft tissue structures during maxillofacial osteotomies and have been recommended for ankylotic tissue removal in the TMJ region during gap arthroplasty and wide excision. This technology may reduce the risk of iatrogenic trauma compared with a carbide bur, osteotome or mallet.²⁷

Although one (25%) of four cats in the current report presented with an intraoperative complication associated with the CSM, this percentage is not likely to reflect the possible intraoperative complications owing to the low number of patients described in this report. Further studies with more patients are necessary to objectively determine possible complications such as sublingual tissue trauma while performing a segmental mandibulectomy, as described in this study.

In line with previous reports, all cats in the present study showed mandibular drift as the main postoperative complication. Mandibular drifting and resulting soft tissue trauma from malocclusion are frequent complications in veterinary patients that underwent segmental, subtotal or total mandibulectomy.^{6,16,28,29} Even though the pre-existing mandibular asymmetry resulting from the TMJ trauma and ankylosis may worsen the postoperative mandibular displacement, factors such as the masticatory muscle action of the intact mandible and soft tissue retraction during the healing process at the mandibulectomy site may contribute to the drifting effect.^{29,30} Mandibular drift and malocclusion may make it difficult, or even prevent, proper prehension and mastication of food. Although elastic power chain placement has been reported to prevent mandibular drift after mandibulectomy in veterinary patients,³¹ selective dental extractions and odontoplasty of maloccluding teeth, as demonstrated in the cases of the present study, are suitable techniques to solve the negative effects of mandibular drifting.

The four cases in the present study did not show postoperative loss of vertical range of mandibular motion or TMJA recurrence. Recurrence of this condition has previously been reported as a postoperative complication after gap arthroplasty or wide excision to remove ankylotic tissue at the TMJ. This complication has been related to the inability to remove all abnormal fibrous and bone tissue owing to the proximity of vital neurovascular structures.^{4,16}

Although radiographic images can be used in the initial screening of patients affected by TMJA, CT and CBTC are undoubtedly the gold standard techniques in determining affected anatomical structures, assessing the extent and quality of abnormal tissue and for surgical treatment planning.^{10,12,32-34} The main limitations of plain radiography include overlap of bone structures

and low image resolution vs CT and CBCT images. Bone and fibrous tissue proliferation at the TMJ region may also make it difficult to identify the joint space and the relationship between the articular surfaces, which could underestimate the actual extent of TMJA during the radiographic assessment.

The mandibular segment removed ranged between 10 and 14 mm, which is similar to what has been reported in a previous similar study during MSM and CSM in cadavers. The results from the cats in the present report suggest the amount of mandibular bone removed during the segmental mandibulectomies was sufficient to avoid bone regeneration at the surgical site. Excision of smaller mandibular segments could lead to bone consolidation at the mandibulectomy site and subsequent TMJA recurrence.

Three patients in the present study were re-evaluated at 48, 56 and 152 weeks, respectively, and the postoperative range of mouth opening remained unchanged. Cat 1 also presented a stable postoperative range of vertical mandibular motion; however, long-term follow-up data for this patient were not available. Long-term follow-up performed in cats 2, 3 and 4 indicated that the segmental mandibulectomy was a suitable surgical procedure to treat cats affected by unilateral TMJA. However, this assumption should be confirmed in a further study enrolling more cats suffering from this condition. Longer-term follow-up is required to ensure TMJA remission, particularly in older patients where bone callus formation may be slower.

Segmental mandibulectomy was previously suggested for the treatment of cats with unilateral TMJA.²¹ However, one cat affected by bilateral TMJA in the present study underwent gap arthroplasty on the right TMJ and CSM on the left side. This patient did not show an inability to eat or drink during the postoperative period. If both sides had undergone segmental mandibulectomy, the patient could have developed a constant inability to close the mouth and swallow food during the postoperative period. The fact this patient maintained both mandibles in a good position during swallowing could be attributed to the masticatory muscle action in the caudal portion of the mandible that was not subjected to segmental mandibulectomy. The pterygoid, temporal and masseter muscles appear to maintain the mandibular movements necessary for swallowing food and water.

Although segmental mandibulectomies represented a viable treatment option in three cats affected by unilateral TMJA and one cat with bilateral TMJA undergoing gap arthroplasty for one of its affected TMJs, additional studies are necessary to prove the feasibility of these procedures in patients undergoing bilateral MSM or CSM. The segmental removal of the middle or caudal portion of the mandibular body, as suggested here and in a previous study,²¹ may be less technically challenging

and time-consuming when compared with the more invasive surgical techniques that require removal of large portions of fibrous and bony tissue in the TMJ region.

Limitations of this study include the small sample size and lack of advanced diagnostic images such as CT and CBCT during follow-up. Although the surgical outcome of the few client-owned cases reported here is consistent with what has been suggested in a previous cadaver study,²¹ it would be desirable to have tomographic imaging (CBCT or CT) several months or years after segmental mandibulectomy. This would allow for better assessment of the quality of tissue at the segmental mandibulectomy site, status of the ankylotic tissue that remained at the affected TMJ, mandibular drift-induced pathological changes at the contralateral TMJ, occurrence of masticatory muscle atrophy, ability to open and close the mouth and overall quality of life (weight increment, play biting and ability to groom themselves).

Conclusions

Mandibular drift and malocclusion were the most common postoperative side effects of the segmental mandibulectomies discussed in this study. The CSM and MSM proved to be safe, feasible and effective surgical procedures to treat cats with unilateral TMJA. They could be considered an alternative surgical technique to surgical excision of ankylotic tissue at the TMJ. All cats in this study achieved a good quality of life after the segmental mandibulectomies.

Conflict of interest The authors declared no potential conflicts of interest with respect to the research, authorship, and/or publication of this article.

Funding The authors received no financial support for the research, authorship, and/or publication of this article.

Ethical approval This work did not involve the use of experimental animals and therefore ethical approval was not necessarily required.

Informed consent This is a retrospective study of clinical procedures on patient animals. Informed consent for the medical procedure was provided by the owner at the time of examination. No animals or humans are identifiable within this publication, and therefore additional informed consent for publication was not required.

ORCID iD Lenin A Villamizar-Martinez  <https://orcid.org/0000-0002-3604-6807>

References

1 Sullivan M. **Temporomandibular ankylosis in the cat.** *J Small Anim Pract* 1989; 30: 401–405.

- 2 Gatineau M, El-Warrak AOMarretta SM, et al. **Locked jaw syndrome in dogs and cats: 37 cases (1998–2005).** *J Vet Dent* 2008; 25: 16–22.
- 3 Lantz G. **Temporomandibular joint ankylosis: surgical correction of three cases.** *J Am Anim Hosp Assoc* 1985; 21: 173–177.
- 4 Maas CPHJ and Theyse LFH. **Temporomandibular joint ankylosis in cats and dogs: a report of 10 cases.** *Vet Comp Orthop Traumatol* 2007; 20: 192–197.
- 5 Gemmill T. **Conditions of the temporomandibular joint in dogs and cats.** *In Pract* 2008; 30: 36–43.
- 6 Meomartino L, Fatone G, Brunetti A, et al. **Temporomandibular ankylosis in the cat: a review of seven cases.** *J Small Anim Pract* 1999; 40: 7–10.
- 7 Tomlinson J and Presnell K. **Mandibular condylectomy effects in normal dogs.** *Vet Surg* 1983; 12: 148–154.
- 8 Strøm PC, Arzi B, Cissell DD, et al. **Ankylosis and pseudoankylosis of the temporomandibular joint in 10 dogs (1993–2015).** *Vet Comp Orthop Traumatol* 2016; 29: 409–415.
- 9 Villamizar-Martinez LA, Villegas CM, Gioso MA, et al. **Morphologic and morphometric description of the temporomandibular joint in the domestic dog using computed tomography.** *J Vet Dent* 2016; 33: 75–82.
- 10 Arzi B, Cissell DD, Verstraete FJM, et al. **Computed tomographic findings in dogs and cats with temporomandibular joint disorders: 58 cases (2006–2011).** *J Am Vet Med Assoc* 2013; 242: 69–75.
- 11 Heney CM, Arzi B, Kass PH, et al. **Diagnostic yield of dental radiography and cone-beam computed tomography for the identification of anatomic structures in cats.** *Front Vet Sci* 2019; 6: 58. DOI: 10.3389/fvets.2019.00058.
- 12 Delesalle Q, Lopes AM, Gawor JP, et al. **Comparative morphometry of the temporomandibular joint in brachycephalic and mesocephalic cats using multislice CT and cone beam CT.** *J Feline Med Surg* 2021; 23: 507–512.
- 13 Talmaceanu D, Lenghel LM, Bolog N, et al. **Imaging modalities for temporomandibular joint disorders: an update.** *Dent Med Clujul Med* 2018; 91: 280–287.
- 14 Macready DM, Hecht S, Craig LE, et al. **Magnetic resonance imaging features of the temporomandibular joint in normal dogs.** *Vet Radiol Ultrasound* 2010; 51: 436–440.
- 15 De Mattos Garcia M, Freitas K, Machado S, et al. **Ressonância magnética e tomografia computadorizada da articulação temporomandibular: além da disfunção.** *Radiol Bras* 2008; 41: 337–342.
- 16 Aghashani A, Verstraete FJM and Arzi B. **Temporomandibular joint gap arthroplasty in cats.** *Front Vet Sci* 2020; 7: 482. DOI: 10.3389/fvets.2020.00482.
- 17 Anderson MA, Orsini PG and Harvey CE. **Temporomandibular ankylosis: treatment by unilateral condylectomy in two dogs and two cats.** *J Vet Dent* 1996; 13: 23–25.
- 18 Rajan R, Reddy NVV, Potturi A, et al. **Gap arthroplasty of temporomandibular joint ankylosis by transoral access: a case series.** *Int J Oral Maxillofac Surg* 2014; 43: 1468–1472.
- 19 Villamizar LA and Reiter A. **Caudal segmental mandibulectomy as alternative treatment for unilateral temporomandibular joint ankylosis in two cats and one dog.** 31st Veterinary Dental Forum, Nashville, TN, September 14–17, 2017, p 11.

- 20 Arzi B. **Temporomandibular joint ankylosis and pseudo-ankylosis.** In: Verstraete FJM, Lommer M and Arzi B (eds). *Oral and maxillofacial surgery in dogs and cats*. 2nd ed. St Louis, MO: Elsevier, 2020, pp 377–382.
- 21 Villamizar-Martinez LA, Chia H, Robertson JB, et al. **Comparison of unilateral rostral, middle and caudal segmental mandibulectomies as an alternative treatment for unilateral temporomandibular joint ankylosis in cats: an ex vivo study.** *J Feline Med Surg* 2021; 23: 783–793.
- 22 Villamizar LA, Kowalesky J, Fugita M, et al. **Anquilosis temporomandibular en un gato Persa.** *Sel Vet* 2013; 21: 51–59.
- 23 Baines SJ and Langley-Hobbs S. **Horner’s syndrome associated with a mandibular symphyseal fracture and bilateral temporomandibular luxation.** *J Small Anim Pract* 2001; 42: 607–610.
- 24 Villamizar-Martinez LA, Reiter AM, Sánchez MD, et al. **Benign cementoblastoma (true cementoma) in a cat.** *JFMS Open Rep* 2016; 2. DOI: 10.1177/2055116915626847.
- 25 Soukup J and Lobprise HB. **Oral surgery – oral and maxillofacial tumors.** In: Lobprise HB and Dodd JR (eds). *Wiggs’s veterinary dentistry principles and practice*. 2nd ed. Hoboken, NJ: John Wiley & Sons, 2019, pp 289–309.
- 26 Walker KS, Reiter AM and Lewis JR. **Marginal mandibulectomy in the dog.** *J Vet Dent* 2009; 26: 194–198.
- 27 Hennet P. **Piezoelectric bone surgery: a review of the literature and potential applications in veterinary oromaxillofacial surgery.** *Front Vet Sci* 2015, 8. DOI: 10.3389/fvets.2015.00008.
- 28 Verstraete FJM. **Mandibulectomy and maxillectomy.** *Vet Clin North Am Small Anim Pract* 2005; 35: 1009–1039.
- 29 Matthiesen DT and Manfra Marretta S. **Results and complications associated with partial mandibulectomy and maxillectomy techniques.** *Probl Vet Med* 1990; 2: 248–275.
- 30 Fiani N and Peralta S. **Extended subtotal mandibulectomy for the treatment of oral tumors invading the mandibular canal in dogs – a novel surgical technique.** *Front Vet Sci* 2019; 6: 339. DOI: 10.3389/fvets.2019.00339.
- 31 Bar-Am Y and Verstraete FJM. **Elastic training for the prevention of mandibular drift following mandibulectomy in dogs: 18 cases (2005–2008).** *Vet Surg* 2010; 39: 574–580.
- 32 Schwarz T, Weller R, Dickie AM, et al. **Imaging of the canine and feline temporomandibular joint: a review.** *Vet Radiol Ultrasound* 2002; 43: 85–97.
- 33 Hammond G, King A and Lapaglia J. **Assessment of five oblique radiographic projections of the canine temporomandibular joint.** *Vet Radiol Ultrasound* 2012; 53: 501–506.
- 34 Ferretti C, Bryant R, Becker P, et al. **Temporomandibular joint morphology following post-traumatic ankylosis in 26 patients.** *Int J Oral Maxillofac Surg* 2005; 34: 376–381.