



Successful treatment of a lung abscess without surgical intervention in a cat

Authors: Nishi, Reo, Ohmi, Aki, Tsuboi, Masaya, Yamamoto, Kie, and Tomiyasu, Hirotaka

Source: Journal of Feline Medicine and Surgery Open Reports, 8(1)

Published By: SAGE Publishing

URL: <https://doi.org/10.1177/20551169221086434>



Successful treatment of a lung abscess without surgical intervention in a cat

Reo Nishi^{1,2}, Aki Ohmi² , Masaya Tsuboi², Kie Yamamoto² and Hirotaka Tomiyasu³

Journal of Feline Medicine and Surgery Open Reports
1–6

© The Author(s) 2022

Article reuse guidelines:

sagepub.com/journals-permissions

DOI: 10.1177/20551169221086434

journals.sagepub.com/home/jfmsopenreports

This paper was handled and processed by the European Editorial Office (ISFM) for publication in *JFMS Open Reports*



Abstract

Case summary An 8-year-old neutered female domestic shorthair cat was referred with complaints of lethargy, anorexia, fever, tachypnoea and a pulmonary mass on thoracic radiography. Whole-body CT revealed the presence of a nodular lesion in the right caudal lobe of the lung. Fine-needle aspiration of the lung mass yielded purulent fluid and cytology showed a large number of mildly to moderately degenerated neutrophils with numerous cocci and bacilli, leading to the diagnosis of a lung abscess. Empirical administration of doxycycline and orbifloxacin was initiated on the day of referral. Bacterial culture and antibiotic susceptibility tests using the collected fluid sample detected two types of bacteria, which were susceptible to both antibiotics. The clinical signs of the cat improved after the initiation of treatment, and the antibiotics were discontinued 28 days later, after the lung lesions disappeared. No recurrence of lung abscess was observed until 588 days after the discontinuation of treatment.

Relevance and novel information Only one case of a lung abscess has been previously reported in cats. Furthermore, while surgical resection is the most common treatment for lung abscesses in the field of veterinary medicine, this is the first report of successful treatment with antibiotic administration alone.

Keywords: Antibiotic; lung mass; tumour; pulmonary abscess

Accepted: 18 February 2022

Introduction

A lung abscess is a condition in which purulent exudate accumulates in a cavity formed by necrosis of the lung tissue. Lung abscesses are generally caused by trauma, bacterial infections, fungal infections, foreign bodies, neoplasia and parasites. In veterinary medicine, there have been only a few case reports of lung abscesses in dogs and cats, suggesting an extremely rare incidence of the disease.^{1–6} In the previous reports, all cases were treated surgically or otherwise euthanased. To the best of the authors' knowledge, no case has been reported in which medical therapy was successful. Therefore, little information is available on the appropriate clinical treatment and outcomes of lung abscesses in dogs and cats.

This report describes a cat diagnosed with a lung abscess that responded to medical treatment alone.

Case description

An 8-year-old neutered female domestic shorthair cat, kept indoors with no other animals and not given raw food, was presented to a primary hospital for a routine examination, owing to its history of chronic kidney disease (CKD). The CKD had been diagnosed a year previously based on the sustained elevation of renal

¹Department of Veterinary Clinical Pathobiology, The University of Tokyo, Tokyo, Japan

²Veterinary Medical Center, The University of Tokyo, Tokyo, Japan

³Department of Veterinary Internal Medicine, The University of Tokyo, Tokyo, Japan

Corresponding author:

Aki Ohmi DVM, PhD, Veterinary Medical Center, The University of Tokyo, Yayoi 1-1-1, Bunkyo-ku, Tokyo 113-8657, Japan
Email: a-ohmi@g.ecc.u-tokyo.ac.jp



Creative Commons Non Commercial CC BY-NC: This article is distributed under the terms of the Creative Commons

Attribution-NonCommercial 4.0 License (<https://creativecommons.org/licenses/by-nc/4.0/>) which permits non-commercial use, reproduction and distribution of the work without further permission provided the original work is attributed as specified on the SAGE and Open Access pages (<https://us.sagepub.com/en-us/nam/open-access-at-sage>).

Table 1 Laboratory test results on the day of referral

	Result	RI
Red blood cells (10 ⁶ cells/ μ l)	7.04	6.54–12.2
Haematocrit (%)	31.5	30.3–52.3
White blood cells (cells/ μ l)	30,370*	2,870–17,000
Segmented neutrophils (cells/ μ l)	23,390*	2,300–10,290
Lymphocytes (cells/ μ l)	3,640	920–6,880
Monocytes (cells/ μ l)	3,040*	50–670
Eosinophils (cells/ μ l)	700	170–1,570
Platelets (10 ³ cells/ μ l)	697*	151–600
Total protein (g/dl)	8.0*	5.7–7.8
Albumin (g/dl)	2.7	2.3–3.5
Blood urea nitrogen (mg/dl)	65.9*	17.6–32.8
Creatinine (mg/dl)	2.68*	0.8–1.8
Sodium (mEq/l)	154	147–156
Potassium (mEq/l)	3.3*	3.4–4.6
Chloride (mEq/l)	116	107–120
Serum amyloid A (μ g/ml)	56.05*	<5.5

RI = reference interval

*Abnormal result

panel results and low urine specific gravity. The cat had been treated for CKD with telmisartan and subcutaneous fluids with lactated Ringer's solution at home under the supervision of a veterinarian. The veterinarian incidentally noted fever (body temperature 39.7°C; reference interval [RI] 36.7–38.9),⁷ respiratory distress on physical examination and pleural effusion on thoracic radiography. A lesion in the right caudal lobe of the lung was observed after removal of the pleural effusion. A large number of inflammatory cells, mostly neutrophils, were found on the pleural effusion smear, but no obvious tumour cells or pathogens were detected. No other analysis for pleural effusion, such as total protein concentration, cell count measurements or bacterial culture tests, was performed at that time. Pleural effusion was resolved after several thoracocenteses and administration of erythromycin (5.0 mg/kg q48h) and prednisolone (1.0 mg/kg q48h) for 3 weeks. However, the respiratory signs and fever persisted and the size of the mass remained unchanged. Furthermore, the cat showed a gradual decrease in activity and appetite and was referred to the Veterinary Medical Center of the University of Tokyo for further investigation.

At the first visit, the cat weighed 3.1 kg (body condition score 3/5)⁸ and was lethargic, anorexic and tachypnoeic (respiratory rate 52 breaths/min; RI 9–37)⁹ without fever (body temperature 38.7°C). The cat was first stabilised in an oxygen chamber and then underwent further examinations, as described below. The main abnormal findings on laboratory testing were leukocytosis with neutrophilia, monocytosis and thrombocytosis (Procyte Dx; IDEXX Laboratories), which were confirmed by peripheral blood smear with no significant morphological findings such as a left shift or toxic changes,

elevation of blood urea nitrogen, creatinine and mild hypokalaemia possibly associated with CKD (DRI-CHEM 7000V; FUJIFILM VET Systems), and elevation of serum amyloid A (SAA [DRI-CHEMIMMUNO AU10V; FUJIFILM VET]) (Table 1). Feline immunodeficiency viral antibodies and feline leukaemia viral antigens were negative. Thoracic radiography revealed a nodular lesion (16 mm [height] \times 22 mm [length]) in the right caudal lobe of the lung, with a mild, diffuse bronchial pattern and interlobar fissure sign (Figure 1). No pleural effusion was observed. With an intravenous drip of lactated Ringer's solution, whole-body contrast-enhanced CT under propofol-induced and isoflurane-maintained anaesthesia was performed using an 80-row multislice CT scanner (Aquilion Prime; Canon Medical Systems) with a pitch of 0.81, rotation time of 0.5 s and slice thickness of 1.0 mm. CT showed a 17 mm (width) \times 16 mm (height) \times 20 mm (length) well-defined nodular lesion with a peripherally enhanced and centrally hypoattenuated appearance on the dorsal side of the right caudal lobe of the lung (Figure 2). Ground-glass opacities were scattered in the right caudal lobe, left cranial lobe and left caudal lobe. In addition, thickening and contrast enhancement of the bronchial wall were observed throughout the lungs.

Fine-needle aspiration (FNA) of the nodular lesion in the lung was performed under CT guidance, and white purulent fluid was collected. In the smear, a large number of mildly to moderately degenerated neutrophils and macrophages were mixed with numerous cocci and bacilli, and bacterial phagocytosis by neutrophils was often observed (Figure 3). No finding indicating any neoplastic diseases was observed. Part of the sample was subjected to microbial culture and antibiotic

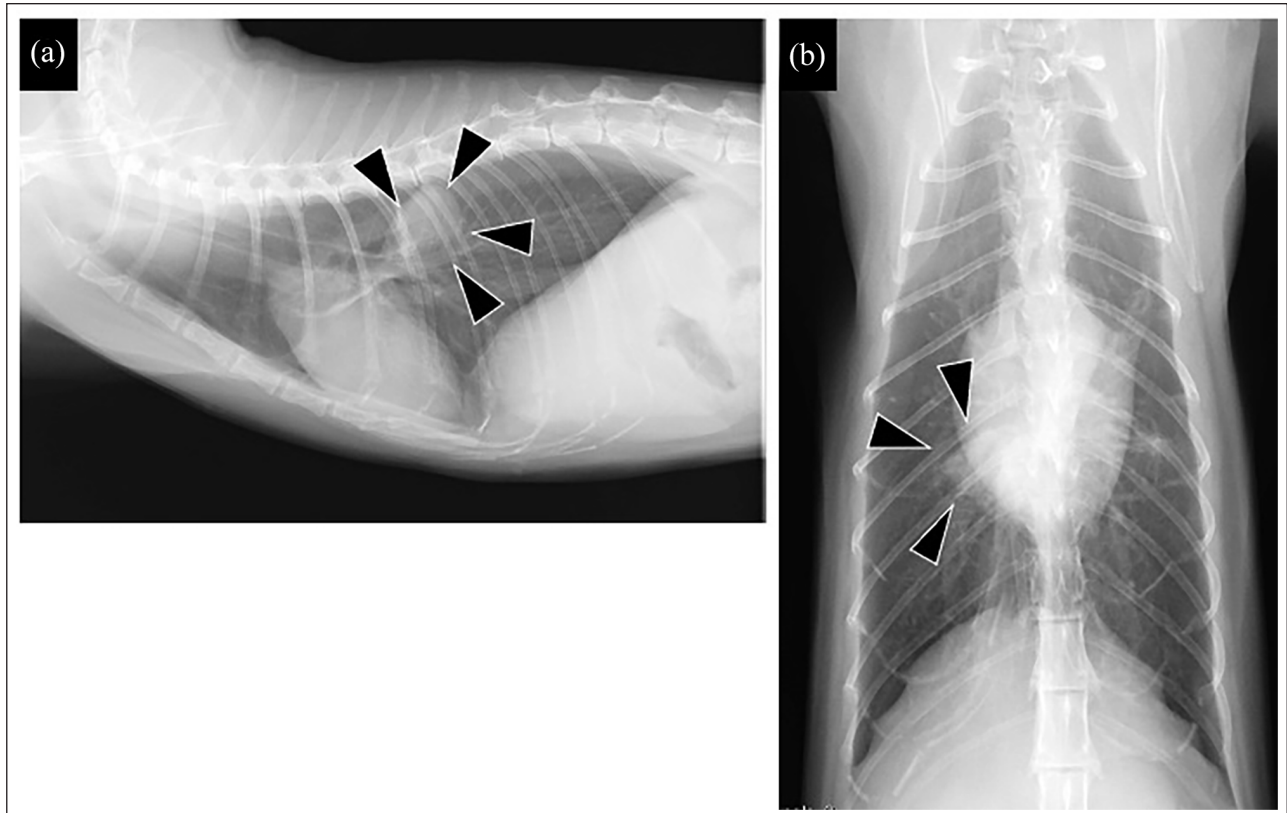


Figure 1 (a) Lateral and (b) ventrodorsal thoracic radiographs of the cat on the day of referral. A mass lesion of soft tissue density was observed in the right caudal lobe of the lung (arrowheads)

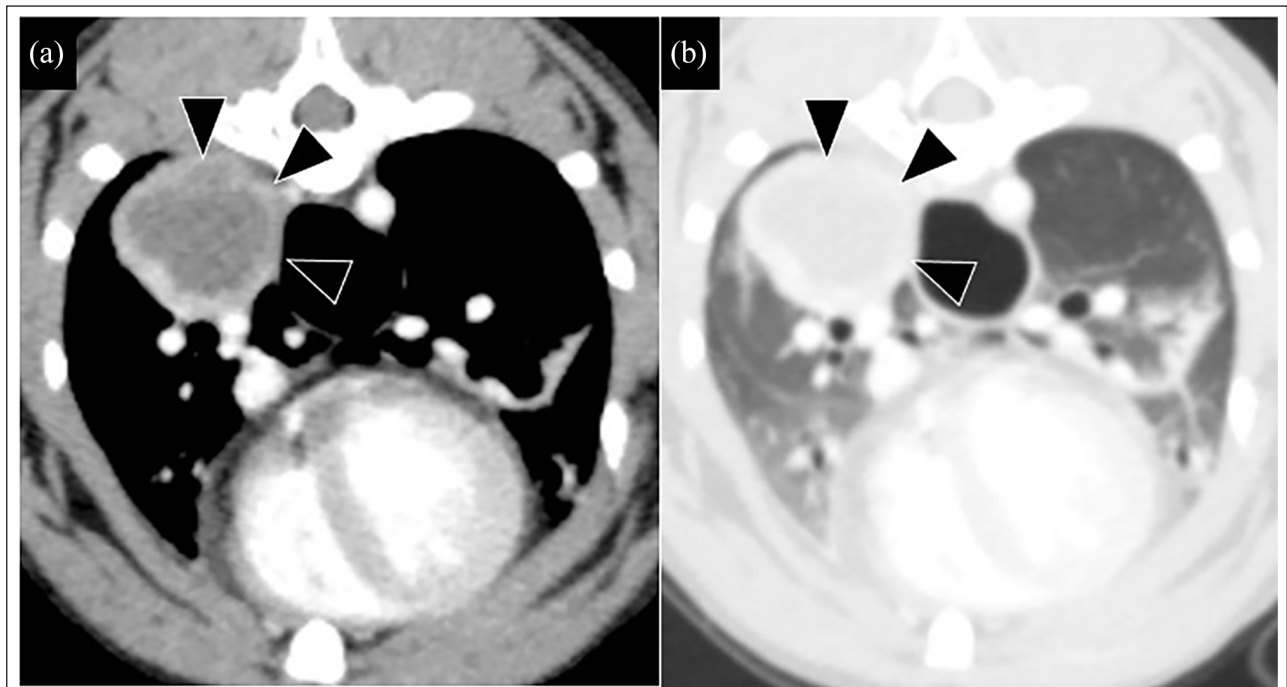


Figure 2 Axial view on contrast-enhanced CT at the level of the eighth intercostal space in (a) a soft tissue window and (b) a lung window. A well-defined nodular lesion with a peripherally enhanced and centrally hypoattenuated appearance was observed in the right caudal lobe of the lung (arrowheads)

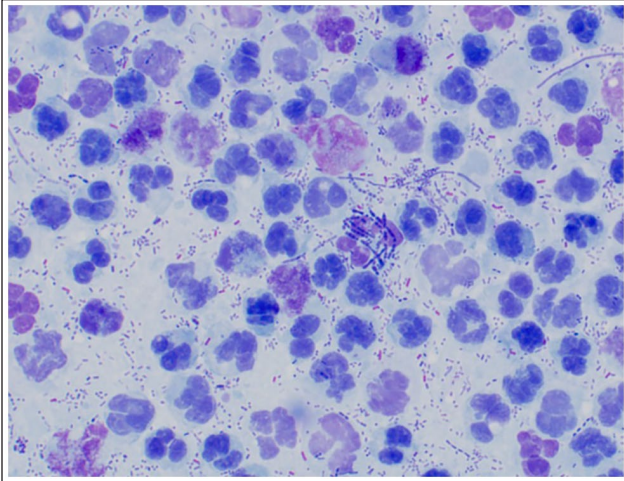


Figure 3 Cytological findings of purulent fluid collected from the nodular lesion in the lung. A large number of mildly to moderately degenerated neutrophils and macrophages were observed with numerous mixed cocci and bacilli in the background. Bacterial phagocytosis by neutrophils was also found (Wright–Giemsa stain, $\times 400$)

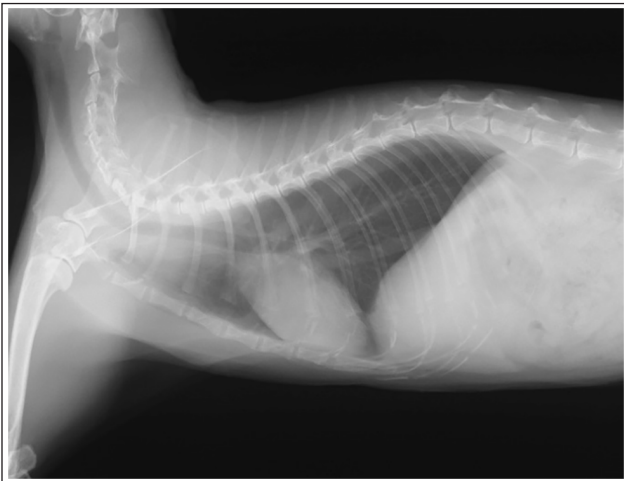


Figure 4 Lateral thoracic radiographs of the cat after 28 days of antibiotic use. The mass lesion in the lung had disappeared

susceptibility tests. Doxycycline (8.0 mg/kg PO q12h) and orbifloxacin (6.4 mg/kg PO q24h) were prescribed until the test results were obtained, and the administration of telmisartan and subcutaneous fluid therapy for CKD were maintained. Treatment and follow-up of the cat were continued at the referring primary hospital. *Escherichia coli* and *Bacteroides* species were isolated and confirmed to be sensitive to both antibiotics prescribed. The activity and respiratory distress of the cat improved approximately 14 days after the initiation of the antibiotics. Thoracic radiography at the primary hospital demonstrated regression of the lung lesions after another 14 days of antibiotic administration, resulting in a total

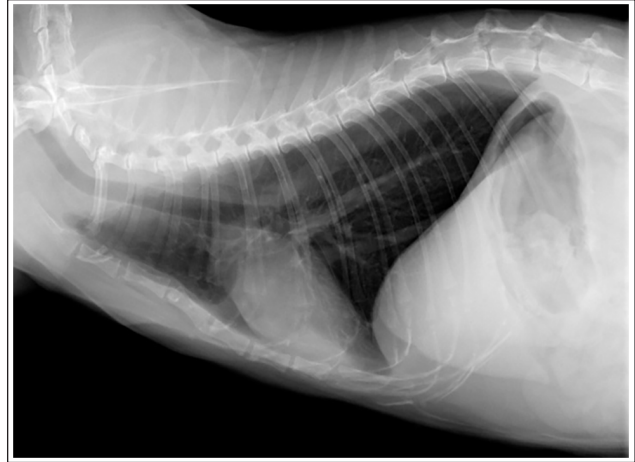


Figure 5 Lateral thoracic radiographs of the cat after 588 days of the discontinuation of antibiotics. No recurrence of lung lesions or pleural effusion were observed

of 28 days (Figure 4). Therefore, both antibiotics were discontinued. No recurrence of lung lesions or pleural effusion was observed on thoracic radiography taken 588 days after discontinuation of the antibiotics (Figure 5) and the cat remained well without any clinical signs.

Discussion

Lung abscesses appear to be rare in veterinary medicine, with case reports of only one cat and five dogs documented.^{1–6} Pneumonia and accidental foreign body inhalation were suspected as causative factors of the lung abscesses in some of the previous case reports,^{3,6} but the cause was unknown in most.^{1,2,4,5} Regarding the cat in the present report, there was no history of going outdoors, trauma or fighting, and no underlying disease except for CKD. As the CT showed diffuse ground-glass opacities in multiple lobes of the lung separate from the lung abscess, some lower respiratory tract diseases such as bronchopneumonia or feline asthma could have been the underlying condition. However, this possibility was unlikely because the cat had no respiratory signs before the detection of the lung abscess, and the changes were considered to be secondary to the lung abscess. Therefore, the apparent cause of lung abscess formation could not be determined.

In the present case, FNA of the pulmonary mass led to the diagnosis of a lung abscess. This contrasts with most previous veterinary reports, where the lung abscesses were diagnosed only after surgical removal or necropsy in all but one case.¹ In dogs and cats, nodular lesions of the lung are often derived from neoplastic diseases and surgical resection is usually the first choice of treatment.^{1,2,6} However, it is necessary to include lung abscess in the differential diagnoses of lung masses because treatment and prognosis are different between infectious and neoplastic diseases. The CT appearance

of a mass that shows a typical abscess, such as a peripherally enhanced and centrally hypoattenuated appearance, may be useful in deciding whether to suspect a lung abscess and perform FNA prior to more invasive treatment, including lung lobectomy. Although FNA of the lung carries some risk of pneumothorax and haemorrhage, positive consideration of FNA testing for pulmonary masses may enable an early diagnosis of lung abscesses and prompt treatment.

The treatment of lung abscesses in veterinary medicine has not yet been established, but surgery has been generally the main treatment. There have been only four case reports describing the treatment and outcome of lung abscesses thus far; they consist of three cases in dogs and one case in a cat. All three cases that were treated surgically had a favourable outcome.^{1,2,6} In the one cat among these cases, no response was observed when empirical antibiotics were administered before surgery, but the clinical signs improved after the lesion was resected and appropriate antibiotics were re-selected according to the bacterial culture results of the resected mass.¹ Conversely, the remaining dog in which treatment with antibiotic administration alone was attempted showed no improvement, and multi-drug-resistant bacteria were detected in post-mortem bacterial culture.³

In the present case report, doxycycline (8.0 mg/kg q12h) was selected because it is recommended as an appropriate antibiotic for feline infectious lower respiratory tract disease based on its broad antibacterial spectrum against various bacteria, including *Mycoplasma* species.¹⁰ In addition, orbifloxacin (6.4 mg/kg q24h), which is a fluoroquinolone, was selected because bacilli were detected in the cytology obtained from the lung abscess lesion and anaerobic bacterial infection was considered.¹⁰ As the cat's condition was stable on room air and the owner wanted to treat the cat on an outpatient basis, oral administration of antimicrobial agents was chosen. However, in cases of severe respiratory distress, parenteral administration of antimicrobial agents is considered necessary, along with oxygen therapy during hospitalisation.

Erythromycin administered before the referral was ineffective, but when doxycycline and orbifloxacin were started, the lung lesions disappeared. Bacterial culture of the sample obtained by FNA of the lesion revealed two species of bacteria, both of which were susceptible to doxycycline and orbifloxacin, while one of the bacteria was resistant to erythromycin. The results of previous and current reports suggest that the presence of drug-resistant bacteria is a major factor in the failure of antibiotic therapy for lung abscesses. The selection of appropriate antibiotics based on bacterial culture and drug susceptibility testing may lead to successful treatment of canine and feline lung abscesses

without surgical intervention. To collect samples for bacteriological examination, FNA of the lesion was considered non-invasive and highly useful. In addition, the reason for the ineffectiveness of erythromycin in this case could have been due to the insufficient dosage of the antibiotic or the concomitant use of prednisolone. Doxycycline and orbifloxacin were continued at the primary hospital after the bacterial culture results were obtained; however, de-escalation of antimicrobial agents should have been considered in terms of preventing the emergence of antimicrobial resistance.

In humans, empirical administration of antimicrobials prior to drainage or surgical resection is generally considered an acceptable treatment option when clinical symptoms and imaging findings suggest lung abscess.¹¹ As multiple bacterial infections are observed in many cases, concomitant use with beta-lactam antibiotics in addition to clindamycin is recommended, which is expected to have a good response rate of 80%.^{12,13} It is considered necessary to continue antimicrobial therapy for 3 weeks or more, even if the mass lesions in the lung disappeared on chest radiography.¹⁴ In the cat presented here, the administration of two antimicrobials was discontinued after 4 weeks of treatment when thoracic radiographs showed the disappearance of the mass, and there was no recurrence of the lesions or pleural effusion thereafter.

This study had several limitations. First, only FNA, general microbial culture and antibiotic susceptibility tests were performed in this case, and the necessary investigations were not completed. It may have been possible to diagnose or exclude other underlying diseases by performing specific tests such as analysis of bronchoalveolar lavage fluid, cytology and histopathology using bronchoscopy and detection of specific pathogens based on PCR. Secondly, no follow-up for blood examination, including leukocytosis with neutrophilia and elevation of SAA level, was performed because the treatment for the cat was continued at the primary hospital. Thirdly, as the present report involved only one cat, further case studies are needed to determine appropriate treatment options for lung abscesses in dogs and cats, including indication, selection and duration of antibiotics.

Conclusions

This is the first report to describe the successful treatment of a lung abscess with antibiotics alone in veterinary medicine. We provide evidence that a good prognosis for a lung abscess can be obtained without surgical intervention. It is important to select and administer appropriate antibiotics based on the results of bacterial culture and antibiotic susceptibility tests for the treatment of lung abscesses.

Acknowledgements The authors would like to thank the owners who took care of this case.

Conflict of interest The authors declared no potential conflicts of interest with respect to the research, authorship, and/or publication of this article.

Funding The authors received no financial support for the research, authorship, and/or publication of this article.

Ethical approval The work described in this manuscript involved the use of non-experimental (owned or unowned) animals. Established internationally recognised high standards ('best practice') of veterinary clinical care for the individual patient were always followed and/or this work involved the use of cadavers. Ethical approval from a committee was therefore not specifically required for publication in *JFMS Open Reports*. Although not required, where ethical approval was still obtained, it is stated in the manuscript.

Informed consent Informed consent (verbal or written) was obtained from the owner or legal custodian of all animal(s) described in this work (experimental or non-experimental animals, including cadavers) for all procedure(s) undertaken (prospective or retrospective studies). No animals or people are identifiable within this publication, and therefore additional informed consent for publication was not required.

ORCID iD Aki Ohmi  <https://orcid.org/0000-0001-7592-6391>

References

- 1 Crisp MS, Birchard SJ, Lawrence AE, et al. **Pulmonary abscess caused by a *Mycoplasma* sp in a cat.** *J Am Vet Med Assoc* 1987; 191: 340–342.
- 2 Robinson DA, DeNardo GA and Burnside DM. **What is your diagnosis? Pulmonary abscess.** *J Am Vet Med Assoc* 2003; 223: 1259–1260.
- 3 Walker JR and Nakamura RK. **What is your diagnosis? Pulmonary abscess.** *J Am Vet Med Assoc* 2014; 245: 277–278.
- 4 Hesselink JW and van den Tweel JG. **Hypertrophic osteopathy in a dog with a chronic lung abscess.** *J Am Vet Med Assoc* 1990; 196: 760–762.
- 5 Leighton RL and Olson S. **Hypertrophic osteoarthropathy in a dog with a pulmonary abscess.** *J Am Vet Med Assoc* 1967; 150: 1516–1520.
- 6 Hylands R. **Veterinary diagnostic imaging. Ruptured lung lobe abscess secondary to a localized alveolar disease.** *Can Vet J* 2006; 47: 181–182.
- 7 Levy JK, Nutt KR and Tucker SJ. **Reference interval for rectal temperature in healthy confined adult cats.** *J Feline Med Surg* 2015; 17: 950–952.
- 8 Baldwin K, Bartges J, Buffington T, et al. **AAHA nutritional assessment guidelines for dogs and cats.** *J Am Anim Hosp Assoc* 2010; 46: 285–296.
- 9 Ljungvall I, Rishniw M, Porciello F, et al. **Sleeping and resting respiratory rates in healthy adult cats and cats with subclinical heart disease.** *J Feline Med Surg* 2014; 16: 281–290
- 10 Lappin MR, Blondeau J, Boothe D, et al. **Antimicrobial use guidelines for treatment of respiratory tract disease in dogs and cats: Antimicrobial Guidelines Working Group of the International Society for Companion Animal Infectious Diseases.** *J Vet Intern Med* 2017; 31: 279–294.
- 11 Wali SO. **An update on the drainage of pyogenic lung abscesses.** *Ann Thorac Med* 2012; 7: 3–7.
- 12 Levison ME, Mangura CT, Lorber B, et al. **Clindamycin compared with penicillin for the treatment of anaerobic lung abscess.** *Ann Intern Med* 1983; 98: 466–471.
- 13 Marina M, Strong CA, Civen R, et al. **Bacteriology of anaerobic pleuropulmonary infections: preliminary report.** *Clin Infect Dis* 1993; 16 Suppl 4: S256–S262.
- 14 Fernández-Sabé N, Carratalà J, Dorca J, et al. **Efficacy and safety of sequential amoxicillin-clavulanate in the treatment of anaerobic lung infections.** *Eur J Clin Microbiol Infect Dis* 2003; 22: 185–187.