



Long-term survival in a cat with tonsillar squamous cell carcinoma treated with surgery and chemotherapy

Authors: Treggiari, Elisabetta, Romanelli, Giorgio, Ferro, Silvia, and Roccabianca, Paola

Source: Journal of Feline Medicine and Surgery Open Reports, 7(1)

Published By: SAGE Publishing

URL: <https://doi.org/10.1177/2055116920984387>



Long-term survival in a cat with tonsillar squamous cell carcinoma treated with surgery and chemotherapy

Journal of Feline Medicine and Surgery Open Reports
1–6

© The Author(s) 2021

Article reuse guidelines:

sagepub.com/journals-permissions

DOI: 10.1177/2055116920984387

journals.sagepub.com/home/jfmsopenreports

This paper was handled and processed by the European Editorial Office (ISFM) for publication in *JFMS Open Reports*



Elisabetta Treggiari¹ , Giorgio Romanelli¹, Silvia Ferro² and Paola Roccabianca³

Abstract

Case summary A 13-year-old neutered female domestic shorthair cat was presented for further investigation of a right-sided cervical mass. Oral cavity examination revealed a unilateral, right tonsillar mass. Following a contrast-enhanced CT scan of head, thorax and abdomen, which showed no clear evidence of distant metastasis, cytology of the cervical mass was consistent with a metastatic retropharyngeal lymph node, and the patient underwent tonsillectomy and lymphadenectomy. The tumour was histopathologically confirmed to be a well-differentiated squamous cell carcinoma with lymph node metastasis, and sequential chemotherapy treatments with carboplatin were administered. The cat underwent a second surgery to treat local recurrence and chemotherapy was continued. Subsequently, multiple lymphadenectomies to remove additional metastatic lymph nodes were performed, followed by adjuvant treatment with doxorubicin. Restaging procedures, performed every 3–6 months did not document any local recurrence nor any local or distant metastasis. The patient was euthanased after developing neoplastic pleural effusion 965 days following tonsillectomy.

Relevance and novel information Tonsillar tumours are rare in cats, but clinical presentation can be similar to that in dogs. Treatment with surgery and chemotherapy, and more importantly multiple lymphadenectomies, may delay the onset of distant metastasis and it should be considered in similar cases to possibly prolong survival.

Keywords: Tonsillar carcinoma; metastatic; surgery; chemotherapy

Accepted: 4 December 2020

Introduction

Squamous cell carcinoma (SCC) is the most common tumour of the oral cavity in cats and usually involves the mandibular/maxillary bone or the oral mucosa.^{1,2} The tongue and tonsils can also be affected.^{3,4} Treatment options include surgery, radiotherapy (RT) alone or in association with chemotherapy, and tyrosine kinase inhibitors (TKIs).^{1,2,5–7}

A retrospective study evaluating 31 cats with oral SCCs (located in the tongue, mandible, maxilla, tonsil and cheek) without distant metastases treated with RT and carboplatin as a radiosensitiser reported a median survival time (MST) of 163 days (range 53–770 days). In this study, four cats with tonsillar SCCs, of which two underwent lymphadenectomy to treat local metastatic

disease, were grouped together with one case of SCC involving the oral mucosa: MST was not reached, and cats were still alive at the time of study closure, with a mean survival of 724 days, which was significantly longer when compared to the outcome of those patients

¹Veterinary Specialist Centre, Milan, Italy

²Department of Comparative Biomedicine and Food Science, University of Padua, Padova, Italy

³School of Veterinary Medicine, Department of Veterinary Medicine, University of Milan, Milan, Italy

Corresponding author:

Elisabetta Treggiari DVM, MSc, DipECVIM-CA (Oncology), Centro Specialistico Veterinario, Via dei Fontanili 11/a, Milan 20141, Italy
Email: e.treggiari@gmail.com



Creative Commons Non Commercial CC BY-NC: This article is distributed under the terms of the Creative Commons

Attribution-NonCommercial 4.0 License (<https://creativecommons.org/licenses/by-nc/4.0/>) which permits non-commercial use, reproduction and distribution of the work without further permission provided the original work is attributed as specified on the SAGE and Open Access pages (<https://us.sagepub.com/en-us/nam/open-access-at-sage>).

with tumours in other anatomical locations (cats with SCCs of the tongue, mandible and maxilla experienced an MST of 141 days).⁴

Tonsillar SCCs are more frequently reported in dogs when compared to the feline specie; treatment options include surgery, RT and chemotherapy (usually carboplatin or anthracycline-based chemotherapy), although MST remains short and is usually in the range of 180–221 days.^{8,9} A more recent study found an overall MST of 243 days in 15 dogs with tonsillar carcinomas; those dogs with unilateral involvement and no evidence of metastatic disease had an MST of 637 days vs 134 and 75 days for those patients with local or distant metastasis, respectively.¹⁰ Literature about tonsillar SCC in cats is sparse, with the few cases described being included in reports regarding treatment of oral tumours with RT, surgery and chemotherapy.^{4,7,11} At present, there is no evidence for the efficacy of surgery and/or chemotherapy in the adjuvant setting, nor any detailed information about survival in cats not treated with RT.

This case report describes the outcome of a cat with tonsillar SCC treated with a combination of surgery and adjuvant chemotherapy.

Case description

A 13-year-old neutered female domestic shorthair cat was presented to our institution for further investigation of a right-sided cervical mass. The mass was incidentally noted by the owner a few weeks before presentation; the cat was asymptomatic. Cytology performed by the referring veterinarian was consistent with an epithelial neoplasm, most likely a carcinoma.

At the time of presentation, the cat weighed 4.3 kg and was in good body condition (body condition score 5/9). Clinical examination showed the presence of a 30 × 30 mm (caliper measurements) cervical mass, the location of which was consistent with an enlarged retropharyngeal lymph node. The remainder of the clinical examination was unremarkable, with no other peripheral lymphadenopathy.

Examination of the oral cavity under general anaesthesia revealed the presence of a large, friable and lobulated mass arising from the right tonsil (Figure 1). A contrast-enhanced CT scan of head, thorax and abdomen showed a right-sided tonsillar mass measuring 17 × 13 × 17 mm. There was no evidence of distant metastasis, although a marked enlargement of the right retropharyngeal lymph node was detected. Three-view thoracic radiographs were also performed for comparison at the time of subsequent follow-up, together with an excisional biopsy of the tonsillar mass; histopathology was consistent with a tonsillar SCC (Figure 2). Lymphadenectomy of the right ipsilateral retropharyngeal node was performed 3 weeks later, and histopathology confirmed lymph node metastasis from the tonsillar SCC (Figures 3 and 4).

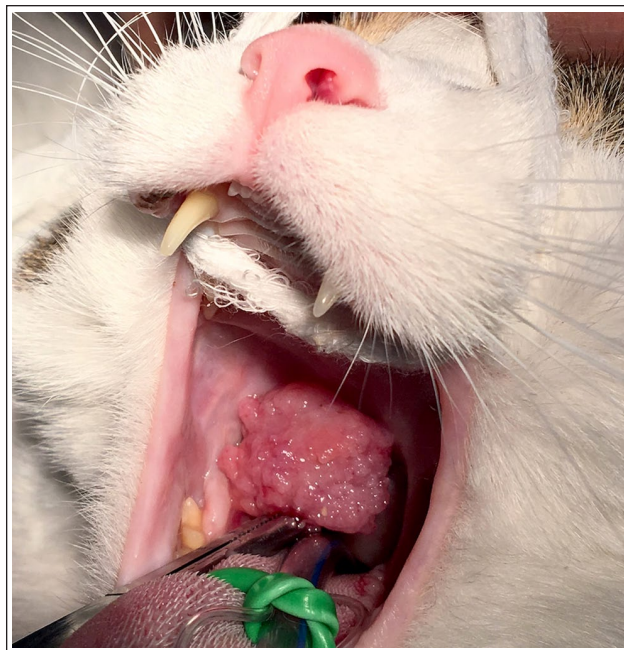


Figure 1 Patient at the time of oral cavity examination under general anaesthesia. Note the exophytic, large mass arising at the level of the right tonsillar crypt. The patient underwent an excisional biopsy

Fourteen days after lymphadenectomy, adjuvant chemotherapy with single-agent carboplatin (Carboplatino Teva; Teva Pharma) was started at 3-weekly intervals, at a dose of 240 mg/m² as a slow (10 mins) intravenous (IV) infusion, following premedication with maropitant (Cerenia; Zoetis) at 1 mg/kg IV. The cat developed grade II gastrointestinal (GI) toxicity (nausea and inappetence) and grade II neutropenia, classified according to the Veterinary Cooperative Oncology Group-Common Terminology Criteria for Adverse Events (VCOG-CTCAE).¹² Subsequent doses were administered at 210 mg/m² and were not associated with any toxicity. The cat was restaged at the time of the fourth carboplatin treatment, 115 days following tonsillectomy, with oral cavity examination and thoracic radiographs performed under general anaesthesia. The latter were negative for distant metastatic disease; however, a 5 × 3 mm mass arising from the right tonsillar crypt was detected and cytology confirmed recurrence of the previously excised SCC. The right mandibular lymph node was subjectively enlarged, and fine-needle aspiration (FNA) were performed; cytology was negative for metastatic disease, while the remainder of the peripheral lymph nodes of the cervical region were normal in shape and size and were therefore not sampled. The oral mass was excised and the oral mass was excised and histopathology confirmed local recurrence of the tonsillar tumour, with complete margins. A right mandibular lymphadenectomy was also concurrently performed to enable a more accurate assessment, and

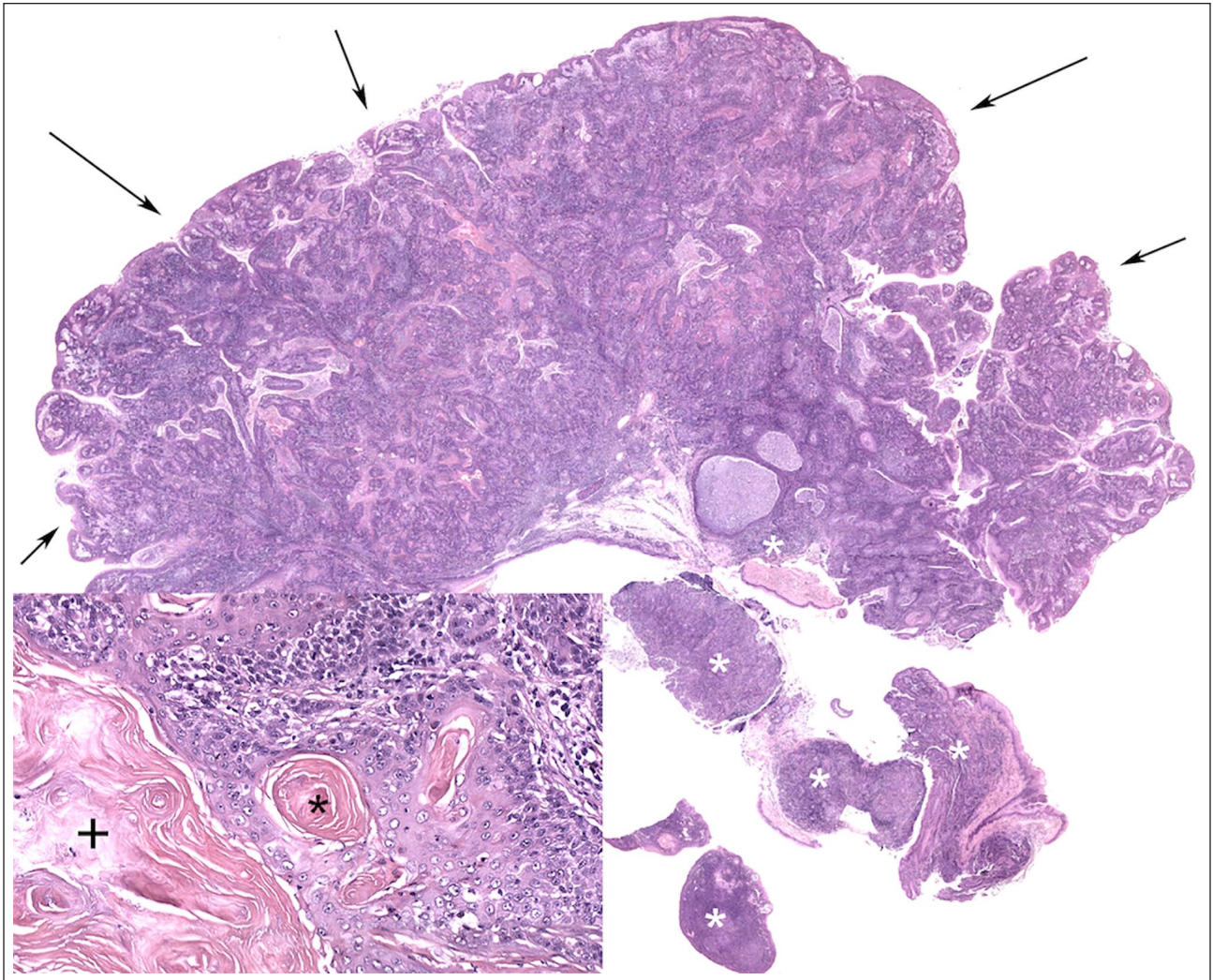


Figure 2 Right tonsil, squamous cell carcinoma. There is a partially exophytic, mostly infiltrating mass expanding the majority of the tonsil (arrows). The residual tonsillar parenchyma is indicated by white asterisks. Haematoxylin and eosin stain, $\times 2$ magnification. Inset: higher magnification shows infiltrative neoplastic cords composed of well-differentiated epithelial cells forming keratin cysts (+) and keratin pearls (black asterisk). A moderate stromal lymphoplasmacytic infiltrate surrounds the neoplastic cells

subsequent histopathology showed no evidence of metastasis to this site. The patient received two more cycles of chemotherapy and was restaged with oral cavity examination and three-view thoracic radiographs 162 days following tonsillectomy, at the time of the sixth carboplatin treatment: on clinical examination, the left mandibular lymph node was moderately enlarged vs the remaining contralateral, while all the others felt normal on palpation and were not sampled. Cytology of the left mandibular lymph node was consistent with suspected SCC metastasis and three-view thoracic radiographs were not suggestive of distant metastatic disease. The sixth carboplatin cycle was therefore administered. Three weeks later the patient was admitted for surgical excision of the previously confirmed metastatic left mandibular lymph node, and also for multiple

lymphadenectomy to more accurately assess these sites for concurrent metastases. Histopathology findings of both mandibular lymph nodes, the left retropharyngeal and the right cervical lymph nodes were consistent with metastasis of a well-differentiated SCC, with tumour cells effacing approximately 80% of the left retropharyngeal and approximately 10% of the right mandibular lymph node.

Toceranib phosphate was discussed and offered as a maintenance therapy; however, the owner was unable to safely administer an oral antineoplastic agent and so a decision was made to prescribe meloxicam at 0.1 mg/kg PO q48h at home. This was well tolerated, and no GI toxicity was reported. Ninety days after the latest surgery, the patient was admitted for a recheck and an additional, enlarged right cervical lymph node was noted, while the

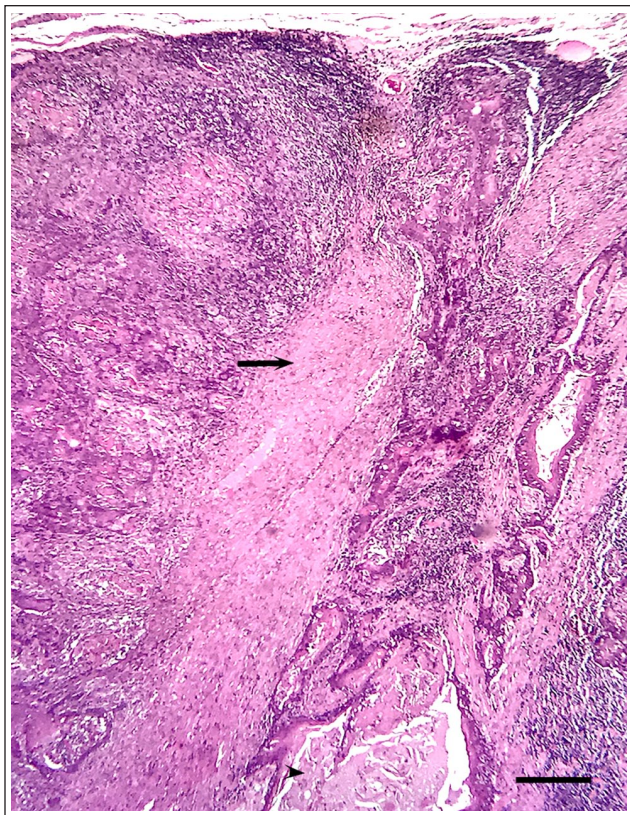


Figure 3 Right retropharyngeal lymph node consistent with extensive metastasis by a well-differentiated squamous cell carcinoma. The sample is characterised microscopically by replacement of paracortex and medulla and 50% of the cortex by epithelial cords, and cystic structures (arrowhead) containing luminal keratin and necrotic debris and surrounded by a desmoplastic response (arrow). Neoplastic epithelial cells in cords and lining cysts have variable nuclear/cytoplasmic ratios, moderate amounts of light-to-glassy, intensely eosinophilic cytoplasm and occasionally polarised nuclei. Haematoxylin and eosin stain, low magnification. Bar = 190 μ m

remainder of the peripheral lymph nodes were normal on palpation. FNA of the right cervical lymph node and three-view thoracic radiographs were performed, cytology was compatible with SCC metastases and no pulmonary radiographic changes consistent with distant metastasis were identified. The cat underwent lymphadenectomy on the same day; histopathology later confirmed metastatic disease. Adjuvant chemotherapy was once again discussed with the owner, who agreed to start single-agent doxorubicin (Doxorubicina Teva; Teva Pharma). This was administered as a slow IV infusion at the standard dose of 1 mg/kg over 20 mins through an indwelling IV catheter, every 21 days. Urine specific gravity and renal parameters were within normal limits prior to each treatment; side effects consistent with myelosuppression, renal or GI toxicity were not detected

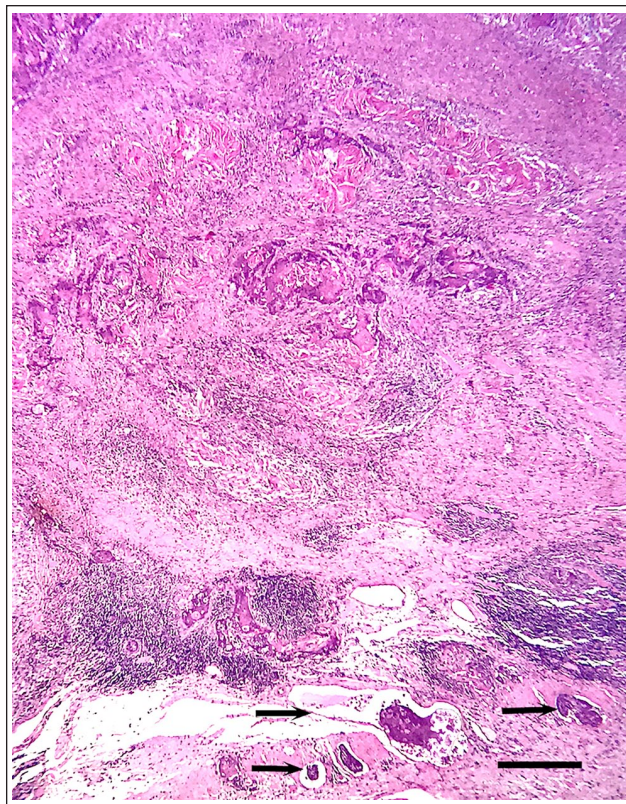


Figure 4 Right retropharyngeal lymph node with complete substitution of the medullary architecture by lobules, cords and cystic structures composed and lined by cubical-to-polygonal neoplastic epithelial cells with severe cellular atypia (anisocytosis, anisokaryosis). Numerous neoplastic emboli of well-differentiated, cohesive epithelial cells are visible within expanded lymphatic vessels of the hilum (arrows) consistent with a retrograde invasion by a squamous cell carcinoma. Haematoxylin and eosin stain, low magnification. Bar = 190 μ m

during the chemotherapy course, with the only abnormality being a VCOG grade III normocytic normochromic non-regenerative anaemia, which was not present prior to starting chemotherapy. The cat received a total of four treatments and was subsequently restaged with physical and oral cavity examination and three-view thoracic radiographs every 3–6 months for more than a year following diagnosis, with no evidence of local recurrence or metastases (local and distant), 576 days following tonsillectomy. Despite recommending further rechecks every 6 months thereafter, the owner elected not to pursue them. The cat was presented to their local veterinarian, 383 days following the last restaging, as it suddenly developed respiratory distress; it was diagnosed with pleural effusion, with cytology consistent with an epithelial neoplasm, most likely a SCC. The owner declined any further investigations and the patient was euthanased 965 days following tonsillectomy.

Discussion

Tonsillar carcinoma is rarely reported in cats and its biological behaviour is not fully understood. Early studies in dogs indicate a poor prognosis, regardless of treatment received,^{8,9} although more recent results on 15 canine patients suggest a longer survival, when compared with historical controls, for those dogs with stage I disease and those treated with surgery and adjuvant chemotherapy (MST = 464 days).¹⁰ In a case series of cats with oral SCCs, including four tonsillar tumours, treated with surgery, radiation and chemotherapy, MST was not reached and cats were still alive at the time of study closure, with a mean survival of 724 days.⁴ Interestingly, two of these cases underwent lymphadenectomy, which could potentially improve the outcome of similar cases with local metastatic disease. At least two studies about canine oral SCCs have tried to correlate the histopathological grade with prognosis;^{13,14} although there is no similar study in cats, particularly in cases of tonsillar SCCs, the long survival experienced by our patient could also be related to the histopathological features of a well-differentiated tumour with a slower progression.

As local control in the canine specie could potentially result in a longer disease-free interval, the same principle may also apply to cats.¹⁵ Our patient received multiple lymphadenectomies over time and it is possible that some early metastases were missed, as not all the lymph nodes were cytologically sampled at the time of initial staging, as suggested by an early study.¹⁶ Additionally, a radical cervical lymph node extirpation was not considered sooner given the normal appearance and size of the majority of the lymph nodes examined.

Radiation treatment has been reported in dogs with tonsillar SCCs to treat inoperable tumours and associated metastatic lymph nodes, or as an adjuvant treatment in combination with chemotherapy,^{8,9} as well as in a few feline cases of tonsillar SCCs.^{3,4,11} Treatment with RT could have been considered in our case to prophylactically irradiate all the lymph nodes in the cervical region, as well as the previous surgery site; however, as it was not readily available in our practice and local metastases were not all detected at the same time, we opted to perform multiple lymphadenectomies and to manage local recurrence surgically, followed by medical treatment with cytotoxic drugs.

Distant metastatic disease in our case was likely delayed by the use of adjuvant chemotherapy, which has been described in the management of tonsillar tumours. Carboplatin has been used in both dogs and cats with various SCCs of the oral cavity, specifically as a radiosensitiser.^{4,6-10} A phase 1 clinical trial in cats concluded that carboplatin could be administered at a maximum tolerated dose of 240 mg/m² IV;¹⁷ in our case, although only a grade II GI and haematological toxicity was shown, a dose reduction was made due to owner's

concerns and subsequent treatments were reported to be well tolerated since. Despite instituting adjuvant treatment, local recurrence developed, suggesting chemotherapy may not have any efficacy in controlling the disease locally. Margins could not be evaluated following the first tonsillectomy and so it is possible that residual disease had been initially overlooked. The sixth carboplatin treatment was administered as planned at the time local recurrence was found, as it was intended to delay distant metastasis, although the patient developed local metastatic disease following treatment.

Toceranib phosphate has been described in the treatment of solid tumours in dogs,¹⁸ including tonsillar SCC, and it has been similarly described for treatment of oral SCCs in cats.⁵ A maintenance therapy with this drug was discussed but declined as the owner was unable to administer oral medications. Furthermore, there is limited to no evidence in veterinary medicine that treatment with TKIs may be effective in similar cases. Instead, meloxicam was prescribed as there is published evidence of cyclooxygenase (COX)-2 expression in oral SCCs in cats and dogs and it was thought that a COX inhibitor could potentially delay disease progression.¹⁹⁻²¹ Doxorubicin was used following the latest lymphadenectomy in light of the reported activity of anthracyclines against epithelial tumours in cats, and tonsillar SCCs in dogs;^{8,22,23} treatment was well tolerated throughout and no further local or distant metastasis was detected.

Despite developing neoplastic pleural effusion, most likely related to the development of pulmonary metastases, the long survival experienced by our patient may suggest that local control with multiple lymphadenectomies in association with adjuvant chemotherapy may be able to delay the onset of distant metastatic disease, particularly in case of well-differentiated tumours.

Conclusions

Tonsillar SCCs in cats may have a similar clinical presentation when compared with dogs; multimodal treatment with surgery, including multiple lymphadenectomies, and adjuvant chemotherapy might be able to control local and distant metastases and prolong survival. Further investigations into the biological behaviour and ideal treatment of tonsillar carcinomas in cats are warranted.

Conflict of interest The author(s) declared no potential conflicts of interest with respect to the research, authorship, and/or publication of this article.

Funding The author(s) received no financial support for the research, authorship, and/or publication of this article.

Ethical approval This work involved the use of non-experimental animals only (including owned or unowned animals

and data from prospective or retrospective studies). Established internationally recognised high standards ('best practice') of individual veterinary clinical patient care were followed. Ethical approval from a committee was therefore not specifically required for publication in *JFMS*.

Informed consent Informed consent (either verbal or written) was obtained from the owner or legal custodian of all animal(s) described in this work (either experimental or non-experimental animals) for the procedure(s) undertaken (either prospective or retrospective studies). No animals or humans are identifiable within this publication, and therefore additional informed consent for publication was not required.

ORCID ID Elisabetta Treggiari  <https://orcid.org/0000-0002-5081-2440>

References

- Hutson CA, Willauer CC, Walder EJ, et al. **Treatment of mandibular squamous cell carcinoma in cats by use of mandibulectomy and radiotherapy: seven cases (1987–1989).** *J Am Vet Med Assoc* 1992; 201: 777–781.
- Northrup NC, Selting KA, Rassnick KM, et al. **Outcomes of cats with oral tumors treated with mandibulectomy: 42 cases.** *J Am Anim Hosp Assoc* 2006; 42: 350–360.
- Bilgic O, Duda L, Sanchez MD, et al. **Feline oral squamous cell carcinoma: clinical manifestations and literature review.** *J Vet Dent* 2015; 32: 30–40.
- Fidel J, Lyons J, Tripp C, et al. **Treatment of oral squamous cell carcinoma with accelerated radiation therapy and concomitant carboplatin in cats.** *J Vet Intern Med* 2011; 25: 504–510.
- Wiles V, Hohenhaus A, Lamb K, et al. **Retrospective evaluation of toceranib phosphate (Palladia) in cats with oral squamous cell carcinoma.** *J Feline Med Surg* 2017; 19: 185–193.
- Fidel JL, Sellon RK, Houston RK, et al. **A nine-day accelerated radiation protocol for feline squamous cell carcinoma.** *Vet Radiol Ultrasound* 2007; 48: 482–485.
- Rejec A, Benoit J, Tutt C, et al. **Evaluation of an accelerated chemoradiotherapy protocol for oropharyngeal squamous cell carcinoma in 5 cats and 3 dogs.** *J Vet Dent* 2015; 32: 212–221.
- Mas A, Blackwood L, Cripps P, et al. **Canine tonsillar squamous cell carcinoma – a multi-centre retrospective review of 44 clinical cases.** *J Small Anim Pract* 2011; 52: 359–364.
- Murphy S, Hayes A, Adams V, et al. **Role of carboplatin in multi-modality treatment of canine tonsillar squamous cell carcinoma – a case series of five dogs.** *J Small Anim Pract* 2006; 47: 216–220.
- Grant J and North S. **Evaluation of the factors contributing to long-term survival in canine tonsillar squamous cell carcinoma.** *Aust Vet J* 2016; 94: 197–202.
- Sabhlok A and Ayl R. **Palliative radiation therapy outcomes for cats with oral squamous cell carcinoma (1999–2005).** *Vet Radiol Ultrasound* 2014; 55: 565–570.
- Veterinary cooperative oncology group – common terminology criteria for adverse events (VCOG-CTCAE) following chemotherapy or biological antineoplastic therapy in dogs and cats v1.1.** *Vet Comp Oncol* 2016; 14: 417–446.
- Nemec A, Murphy B, Kass PH, et al. **Histological subtypes of oral non-tonsillar squamous cell carcinoma in dogs.** *J Comp Pathol* 2012; 147: 111–120.
- Mestrinho LA, Faísca P, Peleteiro MC, et al. **PCNA and grade in 13 canine oral squamous cell carcinomas: association with prognosis.** *Vet Comp Oncol* 2017; 15: 18–24.
- Soltero-Rivera MM, Krick EL, Reiter AM, et al. **Prevalence of regional and distant metastasis in cats with advanced oral squamous cell carcinoma: 49 cases (2005–2011).** *J Feline Med Surg* 2014; 16: 164–169.
- Herring ES, Smith MM and Robertson JL. **Lymph node staging of oral and maxillofacial neoplasms in 31 dogs and cats.** *J Vet Dent* 2002; 19: 122–126.
- Kisseberth WC, Vail DM, Yaissle J, et al. **Phase I clinical evaluation of carboplatin in tumor-bearing cats: a Veterinary Cooperative Oncology Group study.** *J Vet Intern Med* 2008; 22: 83–88.
- London C, Mathie T, Stingle N, et al. **Preliminary evidence for biologic activity of toceranib phosphate (Palladia®) in solid tumours.** *Vet Comp Oncol* 2012; 10: 194–205.
- Millanta F, Andreani G, Rocchigiani G, et al. **Correlation between cyclo-oxygenase-2 and vascular endothelial growth factor expression in canine and feline squamous cell carcinomas.** *J Comp Pathol* 2016; 154: 297–303.
- Nasry WHS, Wang H, Jones K, et al. **CD147 and cyclooxygenase expression in feline oral squamous cell carcinoma.** *Vet Sci* 2018; 5. DOI: 10.3390/vetsci5030072.
- Szweda M, Rychlik A, Babińska I, et al. **Cyclooxygenase-2 as a biomarker with diagnostic, therapeutic, prognostic, and predictive relevance in small animal oncology.** *J Vet Res* 2020; 64: 151–160.
- Novosad CA, Bergman PJ, O'Brien MG, et al. **Retrospective evaluation of adjunctive doxorubicin for the treatment of feline mammary gland adenocarcinoma: 67 cases.** *J Am Anim Hosp Assoc* 2006; 42: 110–120.
- McNeill CJ, Sorenmo KU, Shofer FS, et al. **Evaluation of adjuvant doxorubicin-based chemotherapy for the treatment of feline mammary carcinoma.** *J Vet Intern Med* 2009; 23: 123–129.