



Oral histiocytic sarcoma in a cat

Authors: Néčová, Slavomíra, North, Susan, Cahalan, Stephen, and Das, Smita

Source: Journal of Feline Medicine and Surgery Open Reports, 6(2)

Published By: SAGE Publishing

URL: <https://doi.org/10.1177/2055116920971248>



Oral histiocytic sarcoma in a cat

Slavomíra Něčová¹ , Susan North¹, Stephen Cahalan² and Smita Das³

Journal of Feline Medicine and Surgery Open Reports
1–5

© The Author(s) 2020

Article reuse guidelines:

sagepub.com/journals-permissions

DOI: 10.1177/2055116920971248

journals.sagepub.com/home/jfmsopenreports

This paper was handled and processed by the European Editorial Office (ISFM) for publication in *JFMS Open Reports*



Abstract

Case summary A 15-year-old neutered male domestic shorthair cat presented with a 4-week history of dysphonia and reluctance to chew hard food. Oral examination revealed a mass lesion on the caudal soft palate. Biopsy was performed and histopathology with immunohistochemistry was most consistent with histiocytic sarcoma. CT of the head identified a discrete, left-sided, soft tissue mass lesion cranial to the tonsil with bilaterally symmetrical regional lymph nodes. CT of the thorax was unremarkable. Surgical removal achieved cytoreduction but not complete removal. Adjuvant chemotherapy with lomustine 10 mg (30 mg/m²) was initiated. The patient developed suspected pancreatitis 2–3 weeks postoperatively, so further chemotherapy treatment was discontinued, but supportive treatment with pain relief and appetite stimulants was provided. Three months postoperatively, the patient developed recurrent dysphonia, and oral examination revealed a suspicion of local recurrence. Confirmation of diagnosis (cytopathology or histopathology) was not obtained. Supportive treatment to maintain a good quality of life was continued and the patient was euthanased 6 months after diagnosis owing to progressive disease.

Relevance and novel information Only a few reports have been published describing histiocytic diseases of cats. To our knowledge, this is the first report of a feline histiocytic sarcoma of the oral cavity. Therefore, histiocytic sarcoma should be considered as a differential diagnosis in feline patients with an oral mass, especially if histopathology suggests a pleomorphic and poorly differentiated sarcoma. Immunohistochemistry for the confirmation of cell line origin would be strongly recommended.

Keywords: Histiocytic sarcoma; oral neoplasia; lomustine; undifferentiated sarcoma; CCNU

Accepted: 14 October 2020

Case description

A 15-year-old neutered male domestic shorthair cat, weighing 7.4 kg, presented to the primary veterinary practice for dysphonia and difficulty chewing hard foods. Physical examination at the time was reported to be unremarkable. Haematology was also unremarkable. Biochemistry showed a mild increase in alanine aminotransferase activity (ALT) 100 U/l (reference interval [RI] 18–77 U/l), while other parameters were within normal limits. Treatment with robenacoxib (12 mg PO q24h [Onsior; Novartis]) did not improve the clinical signs. Intra-oral examination 1 week later, under general anaesthesia, revealed a mass-like lesion on the left side of the caudal soft palate. The non-steroidal medication was continued and tramadol (50 mg PO q8h [Tramadol capsules; Bristol]) was started for additional pain relief. Biopsy was performed and histopathology was consistent with a pleomorphic and poorly differentiated sarcoma. The main

differential diagnoses included soft tissue sarcoma, mast cell tumour, melanoma and histiocytic sarcoma (HS). Neoplastic cells did not contain metachromatic granules in Giemsa stains; occasional well-differentiated mast cells were scattered in the mass. Immunohistochemistry revealed strong antibody labelling with CD18 (leukocyte antigen) and vimentin (present in cells of mesenchymal origin and in mesenchymal-derived tumours). There was

¹Southfields Veterinary Specialists (formerly VRCC Veterinary referrals), Laindon, UK

²Synlab VPG/Histology Ltd, Bristol, UK

³Davies Veterinary Specialists, Higham Gobion, UK

Corresponding author:

Slavomíra Něčová DVM, MRCVS, Small Animal Oncology, Southfields Veterinary Specialists (formerly VRCC), 1 Westmayne Industrial Park, Laindon, Essex SS15 6TP, UK
Email: slavomira.necova@southfields.co.uk



Creative Commons Non Commercial CC BY-NC: This article is distributed under the terms of the Creative Commons

Attribution-NonCommercial 4.0 License (<https://creativecommons.org/licenses/by-nc/4.0/>) which permits non-commercial use, reproduction and distribution of the work without further permission provided the original work is attributed as specified on the SAGE and Open Access pages (<https://us.sagepub.com/en-us/nam/open-access-at-sage>).

no labelling with actin- or desmin- (tumours of myogenic origin) specific antibodies. This confirmed a sarcoma of likely histiocytic origin. An oesophageal feeding tube was placed to facilitate nutritional management. Robenacoxib and tramadol was continued at the previous dose and the patient was referred for further treatment.

On presentation to the referral hospital, the owner reported improved appetite since the biopsy. The patient was alert and responsive. Physical examination was unremarkable, except for the presence of an oesophageal feeding tube. Serum biochemistry was unremarkable and packed cell volume and total solids were 32% and 6.8g/dl, respectively.

The cat was premedicated with butorphanol (0.2mg/kg IM [Vetergesic 0.3mg/ml; Ceva]) and dexmedetomidine (10µg/kg IM [Dexdomitor 0.5mg/ml injectable solution; Zoetis]) to allow placement of an intravenous (IV) catheter. Anaesthesia was induced with IV administration of propofol (Vetofol 1.0% w/v emulsion for injection; Norbrook) and maintained with isoflurane (Isocare 100% w/v; Animalcare) carried by oxygen following endotracheal intubation. Oral examination under general anaesthesia showed a discrete lobulated palatal mass lesion 9mm×7mm in diameter. Thoracic and head CT (Somatom Spirit, two-slice; Siemens) was then performed to better evaluate the extent of the disease. Thoracic CT showed no evidence of pulmonary metastasis, and other thoracic structures were normal. The palatal lesion located on the left side cranial to the tonsil appeared discrete and the regional lymph nodes were of physiological size. Aspiration of regional lymph nodes was attempted but was unsuccessful owing to the small size of the nodes.

Treatment options (cytoreductive surgical removal and adjuvant radiotherapy and/or chemotherapy, palliative radiotherapy, palliative chemotherapy) were discussed, and the client agreed to proceed with surgical removal. The patient was premedicated with methadone (0.2mg/kg IV [Comfortan 10mg/ml solution for injection for dogs and cats; Dechra]) and dexmedetomidine (3µg/kg IV [Dexdomitor 0.5mg/ml injectable solution; Zoetis]). Propofol (Vetofol 1.0% w/v emulsion for injection; Norbrook) was administered IV titrated to effect for anaesthetic induction, the trachea was intubated and anaesthesia maintained using isoflurane (Isocare 100% w/v Inhalation Vapour; Animalcare) carried by oxygen throughout general anaesthesia. Cytoreductive surgery with no planned surgical margin was performed via an intra-oral approach to remove the mass, which required full-thickness excision of the soft palate. Palatine reconstruction resulted in a slight shortening of the soft palate. Polyglecaprone 4-0 (Monocryl 4-0, 1.5Ph. Eur; Ethicon) was used for a two-layer closure to appose the nasal and then the oral mucosae.

The patient's recovery was uneventful. The cat was supported postoperatively with IV fluid therapy (Hartman's solution 2ml/kg/h) until full recovery and pain relief with buprenorphine (0.02mg/kg IV q6h [Buprecare 0.3mg/ml; Animalcare]). Meloxicam (0.2mg/

kg SC q24h [Metacam; Boehringer Ingelheim]) followed by oral administration was started for additional pain management. The patient was comfortable and eating well 24h postoperatively, indicating no functional issues caused by the shortening of the soft palate, and was discharged the same day. Seven days later the client reported a full recovery with resolution of the presenting clinical signs.

Once excised, the mass tissue was fixed in 10% neutral buffered formalin, then processed for paraffin embedding, sectioning and staining with haematoxylin and eosin. Histopathology of the mass showed a poorly demarcated and non-encapsulated submucosal proliferation of neoplastic cells forming solid sheets and poorly defined streams and bundles supported by a thin fibrovascular stroma. Neoplastic infiltration of the overlying mucosa was not noted. Neoplastic cells were large, polygonal to occasionally spindle, with indistinct cell borders and moderate-to-abundant eosinophilic and vacuolated cytoplasm. Nuclei were round-to-ovoid to occasionally indented, with finely stippled-to-reticular-to-vesicular chromatin and 1–2 large magenta nucleoli. An approximately five-fold degree of anisokaryosis and anisocytosis and frequent multinucleated giant cells were seen. Mitotic figures were one per 10 high-power fields. Scattered neutrophils, macrophages and lymphocytes were noted throughout the mass (Figure 1). Fungal organisms and

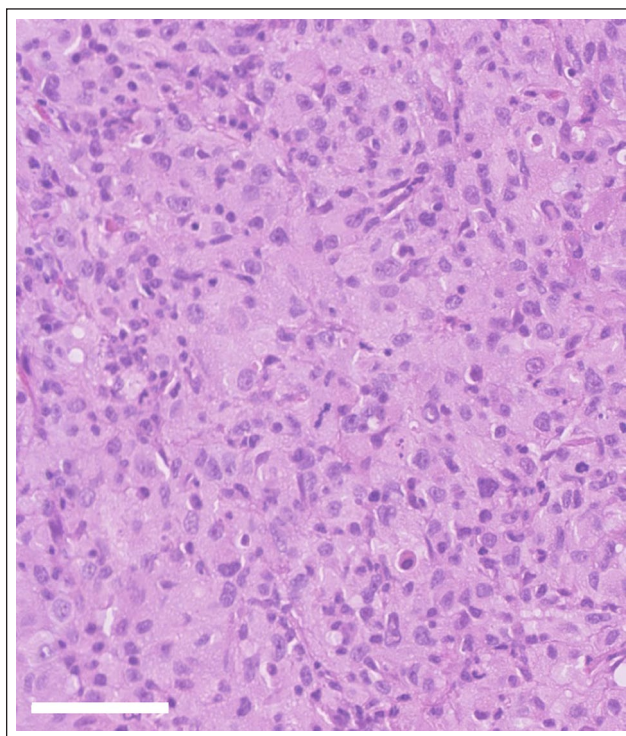


Figure 1 Photomicrograph of a haematoxylin and eosin-stained histological section of the neoplasm, taken at ×20 magnification showing the neoplastic round cell population. The large neoplastic cells contain abundant finely vacuolated eosinophilic cytoplasm and indented nuclei. Scale bar represents 50µm

acid-fast bacteria were not observed on periodic acid–Schiff and Ziehl–Neelsen stains.

Sections $>4\mu\text{m}$ were taken from the paraffin-embedded tissues and mounted on positively charged glass slides (Superfrost Plus; Menzel). Sections were dewaxed and heat-mediated antigen retrieval performed in a high (Tris/EDTA buffer, pH 9) or low (citrate buffer, pH 6.1) pH solution (Envision FLEX Target Retrieval Solutions; DAKO) in a computer-controlled heated water bath (PT Link; DAKO) at 97°C for 30 mins. Immunohistochemistry was performed using an automated immunohistochemical staining machine (Cytomation Autostainer Plus; DAKO). Endogenous peroxidase activity was blocked by incubation in hydrogen peroxide solution for 30 mins (EnVision FLEX Peroxidase-Blocking Reagent; DAKO). The tissue sections were incubated with the diluted (Envision FLEX antibody diluent; DAKO) primary antibody for 30 mins at room temperature. Immunohistochemical staining was detected using a goat antimouse/rabbit IgG and horseradish peroxidase-tagged polymer system (EnVisionFLEX/HRP; DAKO). Staining was developed with 3,3'-diaminobenzidine tetrahydrochloride (EnVision FLEX DAB+ Chromogen; DAKO) and counterstained with haematoxylin. Negative controls were performed by replacing the primary antibody with antibody dilution buffer. Immunohistochemistry for CD18 showed strong membranous staining in a population of round cells scattered throughout the mass (macrophages) with weaker diffuse membranous staining throughout the neoplastic cell population (Figure 2). Human leukocyte antigen – DR isotype (HLA-DR) showed diffuse strong membranous staining throughout the mass (Figure 3). IBA1 showed scattered, rare, weak cytoplasmic staining within neoplastic cells. Immunohistochemistry for Melan A, melanoma-associated antigen (PNL2) and CD117 was negative. In addition, the proliferative cells within the soft palate mass were negative for CD3, CD20 and CD79a, further ruling out lymphoid neoplasia. The results were consistent with an HS.

Owing to the location, lack of complete excision and potential for metastatic behaviour, adjuvant chemotherapy was recommended. Haematology and alkaline phosphatase were within normal limits, and alanine transaminase was mildly elevated (153U/l ; RI $12\text{--}130\text{U/l}$). Twelve days postoperatively, the patient received lomustine 10mg ($30\text{mg}/\text{m}^2$; PO q3 weeks [Lomustine 10mg capsules; The Specials Laboratory]).¹

The cat presented for re-examination 3 days after the initiation of chemotherapy owing to hyporexia, which had been present since the chemotherapy was administered. General physical examination was unremarkable. Intra-oral examination under sedation identified no concerns with the surgical site. Mirtazapine (1.88mg PO q48h [Mirtazapine $15\text{mg}/\text{ml}$ oral solution; Rosemont Pharmaceuticals]) was prescribed to stimulate appetite. The patient returned 2 weeks later owing to recurrence of hyporexia. Physical examination

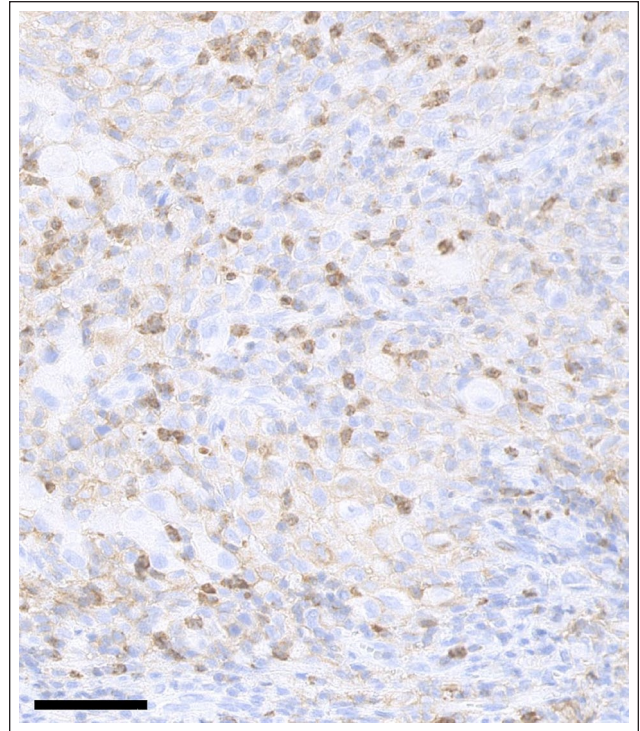


Figure 2 Photomicrograph of tumour section immunohistochemically stained with anti-CD18 antibody. Image taken at $\times 20$ magnification showed strong membranous staining in a population of round cells scattered throughout the mass (macrophages) with weaker diffuse membranous staining throughout the larger neoplastic cell population. Scale bar represents $50\mu\text{m}$

showed slight abdominal discomfort. Abdominal ultrasound identified a hyperechoic pancreas with hypoechoic nodules, which could be indicative of pancreatitis. Supportive treatment was initiated with fluid therapy (Hartmann's solution $2\text{ml}/\text{kg}/\text{h}$) and buprenorphine ($0.02\text{mg}/\text{kg}$ IV q6h [Vetergesic $0.3\text{mg}/\text{ml}$ solution for injection for dogs, cats and horses; CEVA]). The cat's appetite improved and normalised over 4 days.

The owner declined further chemotherapy owing to the episode of hyporexia. The cat then presented 11 weeks after the initial surgery for recurrent dysphonia. Oral examination under sedation with alfaxalone (Alfaxan $10\text{mg}/\text{ml}$ solution for injection for dogs and cats; Jurox) titrated intravenously to effect revealed a soft tissue mass lesion at the previous surgical site, most likely consistent with local recurrence of the HS. The client declined further sampling, staging and any further therapy; therefore, no samples from the mass were collected at that time. The patient was euthanased 6 months after surgical excision owing to anorexia, weight loss and dyspnoea resulting in poor quality of life as a result of disease progression. A post-mortem examination was declined by the cat's owner.

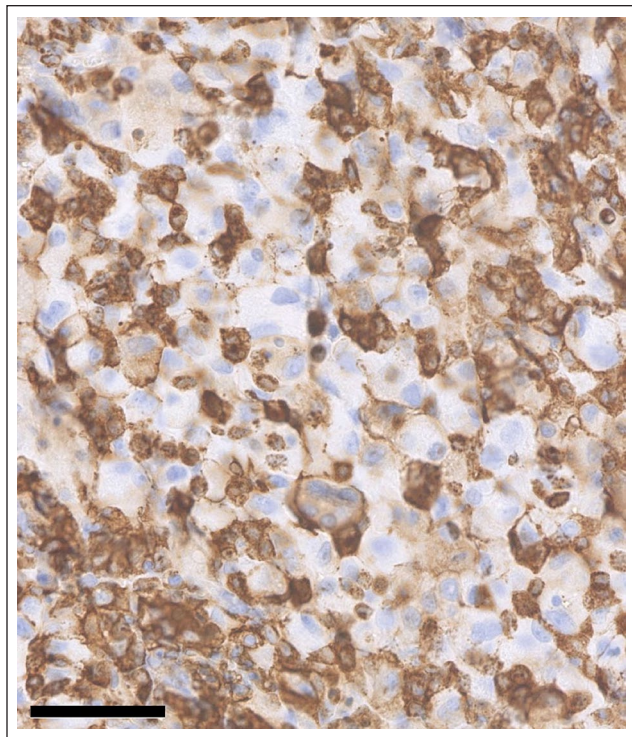


Figure 3 Photomicrograph of tumour section immunohistochemically stained with anti-human leukocyte antigen – DR isotype (HLA-DR) antibody. Image taken at $\times 20$ magnification showed diffuse strong membranous staining throughout the mass. Scale bar represents 50 μm

Discussion

Neoplasms of the oral cavity in cats comprise approximately 3–12% of all feline tumours.^{2–4} Previous reports have analysed the histopathological characteristics of feline oral lesions.^{5,6} Inflammatory lesions accounted for 52–58% of all analysed samples. Malignant neoplasms were diagnosed in 22–47% of cats, of which squamous cell carcinoma was the most common malignancy, followed by fibrosarcoma. Oral melanoma was less commonly diagnosed in these studies and HS was not described. Interestingly, although HS is more common in dogs than in cats, there are no reports of solitary HS of the canine oral cavity of which the authors are aware.

Feline histiocytic diseases are less common, compared with dogs. A fairly small number of case reports and reviews related to feline histiocytic disorders exist in the current literature, with a more recent publication describing clinical findings and outcome in feline histiocytic disorders, including characterisation of the expression of platelet-derived growth factor receptor beta and KIT.⁷ In cats, three distinct forms have been reported to date, including pulmonary Langerhans cell histiocytosis, progressive histiocytosis and HS. The lack of peripheral, nodular or plaque-like dermal lesions in this case makes

progressive histiocytosis a less likely differential, although terminal involvement of internal organs has been described in this condition.⁸ HS can present as a solitary mass or as a disseminated form characterised by involvement of multiple organ systems. Two cell lines of origin were described in feline patients. These include HS of dendritic origin and haemophagocytic HS of macrophage origin. HS is a malignant tumour with typically aggressive biological behaviour, which carries a guarded-to-poor prognosis.^{9–19} Owing to the rare diagnosis of HS in cats, the optimum therapy is not known in feline patients. The choice of adjuvant chemotherapy was supported by the recent publication summarising, apart from other treatments, chemotherapy response in cats treated with histiocytic disorders⁷ and previous knowledge in dogs.^{20–22}

In this case, the HS presented as a solitary mass in the soft palate, which, to our knowledge, is the first described case of an oral HS in a cat. Histopathologically, the samples contained a proliferation of atypical neoplastic cells that exhibited a prominent pleomorphism and a low mitotic index. Cells were characterised by indented nuclei and vacuolated cytoplasm. These features were most suggestive of an HS, although pyogranulomatous inflammation was also considered, owing to the relatively low mitotic rate present. However, the lack of tissue organisation, along with the cellular pleomorphism, and negative special stain results, made the differential of sarcoma more likely, although further culture or PCR would help to rule out this differential more conclusively. The aggressive behaviour with rapid regrowth also supports tumour over granuloma. The presence of strong membranous HLA-DR immunopositivity throughout the mass, along with membranous CD18 immunopositivity within tumour macrophages and much weaker CD18 and IBA1 staining within the surrounding neoplastic cell population makes a tumour of leukocytic, and, more specifically, macrophage origin most likely, although the addition of CD1a and CD11c would likely clarify this diagnosis, as these are considered markers of HSs in cats.²³ Unfortunately, these were not performed as fresh frozen tissue required for the use of CD1a and CD11c had not been taken at the time of sampling and these markers are not available in UK.

Conclusions

To our knowledge, this is the first report of a feline HS of the oral cavity. Despite more common oral malignancies presenting in cats, HS should be considered as a differential diagnosis in feline patients with an oral mass, especially if histopathology suggests a pleomorphic and poorly differentiated sarcoma. Immunohistochemistry for the confirmation of cell line origin would be strongly recommended in those instances.

Author note This work was presented as a poster at the BSAVA Congress Birmingham, UK, April 2019.

Conflict of interest The authors declared no potential conflicts of interest with respect to the research, authorship, and/or publication of this article.

Funding The authors received no financial support for the research, authorship, and/or publication of this article.

Ethical approval This work involved the use of non-experimental animals only (including owned or unowned animals and data from prospective or retrospective studies). Established internationally recognised high standards ('best practice') of individual veterinary clinical patient care were followed. Ethical approval from a committee was therefore not necessarily required.

Informed consent Informed consent (either verbal or written) was obtained from the owner or legal custodian of all animals described in this work for the procedures undertaken. For any animals or humans individually identifiable within this publication, informed consent (either verbal or written) for their use in the publication was obtained from the people involved.

ORCID ID Slavomíra Něčová  <https://orcid.org/0000-0002-1705-6305>

References

- Fan TM, Kitchell BE, Dhaliwal RS, et al. **Hematological toxicity and therapeutic efficacy of lomustine in 20 tumor-bearing cats: critical assessment of a practical dosing regimen.** *J Am Anim Hosp Assoc* 2002; 38: 357–363.
- Dorn CR. **Epidemiology of canine and feline tumors.** *J Am Anim Hosp Assoc* 1976; 12: 307–310.
- Dorn CR and Priester WA. **Epidemiologic analysis of oral and pharyngeal cancer in dogs, cats, horses, and cattle.** *J Am Vet Med Assoc* 1976; 169: 1202–1206.
- Stebbins KE, Morse CC and Goldschmidt MH. **Feline oral neoplasia: a ten-year survey.** *Vet Pathol* 1989; 26: 121–128.
- Mikiewicz M, Paździor-Czapula K, Gesek M, et al. **Canine and feline oral cavity tumours and tumour-like lesions: a retrospective study of 486 cases (2015–2017).** *J Comp Pathol* 2019; 172: 80–87.
- Wingo K. **Histopathologic diagnoses from biopsies of the oral cavity in 403 dogs and 73 cats.** *J Vet Dent* 2018; 35: 7–17.
- Treggiari E, Ressel L, Polton GA, et al. **Clinical outcome, PDGFR β and KIT expression in feline histiocytic disorders: a multicentre study.** *Vet Comp Oncol* 2015; 15: 65–77.
- Affolter VK and Moore PF. **Feline progressive histiocytosis.** *Vet Pathol* 2006; 43: 646–655.
- Bell R, Philbey AW, Martineau H, et al. **Dynamic tracheal collapse associated with disseminated histiocytic sarcoma in a cat.** *J Small Anim Pract* 2006; 47: 461–464.
- Friedrichs KR and Young KM. **Histiocytic sarcoma of macrophage origin in a cat: case report with a literature review of feline histiocytic malignancies and comparison with canine hemophagocytic histiocytic sarcoma.** *Vet Clin Pathol* 2008; 37: 121–128.
- Ide T, Uchida K, Tamura S, et al. **Histiocytic sarcoma in the brain of a cat.** *J Vet Med Sci* 2010; 72: 99–102.
- Ide T, Setoguchi-Mukai A, Nakagawa T, et al. **Disseminated histiocytic sarcoma with excessive hemophagocytosis in a cat.** *J Vet Med Sci* 2009; 71: 817–820.
- Pinard J, Wagg CR, Girard C, et al. **Histiocytic sarcoma in the tarsus of a cat.** *Vet Pathol* 2006; 43: 1014–1017.
- Smoliga J, Schatzberg S, Peters J, et al. **Myelopathy caused by a histiocytic sarcoma in a cat.** *J Small Anim Pract* 2005; 46: 34–38.
- Wong VM, Snyman HN, Ackerley C, et al. **Primary nasal histiocytic sarcoma of the macrophage-myeloid type in a cat.** *J Comp Pathol* 2012; 147: 209–213.
- Kraje AC, Patton CS and Edwards DF. **Malignant histiocytosis in 3 cats.** *J Vet Intern Med* 2001; 15: 252–256.
- Walton RM, Brown DE, Burkhard MJ, et al. **Malignant histiocytosis in a domestic cat: cytomorphologic and immunohistochemical features.** *Vet Clin Pathol* 1997; 26: 56–60.
- Busch MDM, Reilly CM, Luff JA, et al. **Feline pulmonary Langerhans cell histiocytosis with multiorgan involvement.** *Vet Pathol* 2008; 45: 816–824.
- Scurrall E, Trott A, Rozmanec M, et al. **Ocular histiocytic sarcoma in a cat.** *Vet Ophthalmol* 2013; 16 Suppl 1: 173–176.
- Skorupski K, Clifford C, Paoloni M, et al. **CCNU for the treatment of dogs with histiocytic sarcoma.** *J Vet Intern Med* 2007; 21: 121–126.
- Rassnick K, Moore A, Russell D, et al. **Phase II, open-label trial of single-agent CCNU in dogs with previously untreated histiocytic sarcoma.** *J Vet Intern Med* 2010; 24: 1528–1531.
- Skorupski K, Rodriguez C, Krick E, et al. **Long-term survival in dogs with localized histiocytic sarcoma treated with CCNU as an adjuvant to local therapy.** *Vet Comp Oncol* 2009; 7: 139–144.
- Moore PF. **A review of histiocytic disease of dogs and cats.** *Vet Pathol* 2014; 51: 167–184.