



Diagnosis and clinical outcome following surgical resection of an intracranial grade III anaplastic gemistocytic astrocytoma in a cat

Authors: Murthy, Vishal D, Liepnieks, Molly L, Roy, Melissa A, Woolard, Kevin D, Sturges, Beverly K, et al.

Source: Journal of Feline Medicine and Surgery Open Reports, 6(2)

Published By: SAGE Publishing

URL: <https://doi.org/10.1177/2055116920939479>



Diagnosis and clinical outcome following surgical resection of an intracranial grade III anaplastic gemistocytic astrocytoma in a cat

Journal of Feline Medicine and Surgery Open Reports
1–8

© The Author(s) 2020

Article reuse guidelines:

sagepub.com/journals-permissions

DOI: 10.1177/2055116920939479

journals.sagepub.com/home/jfmsopenreports

This paper was handled and processed by the American Editorial Office (AAFP) for publication in *JFMS Open Reports*



Vishal D Murthy¹ , Molly L Liepnieks², Melissa A Roy², Kevin D Woolard³, Beverly K Sturges⁴ and Chai-Fei Li⁴

Abstract

Case summary A 10-year-old Maine Coon cat was presented for acute onset seizures and cerebrothalamic signs. An intracranial mass, suspected to be a meningioma, was diagnosed on MRI and surgically excised. Histopathology appeared consistent with an atypical meningioma. However, following rapid regrowth of the neoplasm, the patient was humanely euthanized 3 months later. On post-mortem histopathology, the neoplasm was diagnosed as a grade III anaplastic gemistocytic astrocytoma.

Relevance and novel information Gemistocytic astrocytomas are rare brain tumors in the feline patient. This case represents the first report of a feline grade III anaplastic gemistocytic astrocytoma in the cerebrum of a cat with surgical excision and recurrence. The challenging nature of ante-mortem diagnosis and the guarded prognosis, despite surgical intervention, are presented in this report.

Keywords: Astrocytoma; magnetic resonance imaging; brain neoplasms; neurosurgery

Accepted: 24 May 2020

Introduction

Astrocytomas are a rare neoplasm of the feline central nervous system, accounting for 3.5% of spinal neoplasias and 2.8% of intracranial neoplasias.^{1–3} Gemistocytic astrocytomas are rarely reported in cats, while anaplastic astrocytomas are even rarer.^{3–10} There have been scattered reports of glioblastoma (grade IV) and pilocytic astrocytomas (grade I), and a handful of previous reports with astrocytomas of unknown grade.^{1,11–15} There are no reports of surgical management and postoperative recurrence of intracranial feline astrocytoma. This is also the first report of a cerebral grade III anaplastic astrocytoma of the gemistocytic subtype, as gemistocytic astrocytomas typically have morphologic features associated with a lower grade (grade II) (all grading based on the 2007 World Health Organization [WHO] classification of tumors of the central nervous system).¹⁶

Case description

A 10-year-old male castrated Maine Coon weighing 3.6 kg was presented for a 1-week history of lethargy,

circling to the right, pawing at the right ear and head shaking that progressed to a generalized tonic-clonic seizure with opisthotonus. On presentation to an emergency hospital postictally, the patient was normoglycemic and normocalcemic, with compulsive circling to the right. No treatment was initiated, and three seizures

¹Veterinary Medical Teaching Hospital, University of California, Davis, CA, USA

²Comparative Pathology Laboratory, University of California, Davis, CA, USA

³Department of Pathology, Microbiology & Immunology, University of California, Davis, CA, USA

⁴Department of Surgical and Radiological Sciences, University of California, Davis, California, USA

Corresponding author:

Chai-Fei Li DVM, DACVIM (Neurology), Department of Surgical and Radiological Sciences, University of California, Davis, School of Veterinary Medicine, One Shields Avenue, 2112 Tupper Hall, Davis, CA 95616, USA
Email: cfli@ucdavis.edu



Creative Commons Non Commercial CC BY-NC: This article is distributed under the terms of the Creative Commons

Attribution-NonCommercial 4.0 License (<https://creativecommons.org/licenses/by-nc/4.0/>) which permits non-commercial use, reproduction and distribution of the work without further permission provided the original work is attributed as specified on the SAGE and Open Access pages (<https://us.sagepub.com/en-us/nam/open-access-at-sage>).

were witnessed in the next 2 days before presentation to a neurologist. Prior to this, the patient had been a healthy indoor cat with no travel history and had not been routinely vaccinated.

General physical examination and vital parameters were within normal limits. On neurological examination, the patient was quiet, but alert, and responsive to stimuli on the right side but not the left side of the body. The cat was ambulatory with compulsive tight circling to the right, a right head and body turn, and no overt ataxia or paresis. The menace response and visual tracking were intact in the right eye, and decreased and inconsistent in the left eye. Nasocortical stimulation response was decreased on the left. Subtle proprioceptive deficits were noted in the left thoracic and pelvic limbs. The rest of the neurological examination was normal. Based on these findings, a lesion was localized to the right cerebrum. Primary differential diagnoses at that time included neoplasia (eg, meningioma and lymphoma), cerebrovascular infarct and encephalitis (eg, feline infectious peritonitis, *Toxoplasma gondii* and *Cryptococcus neoformans*).

A complete blood count, serum biochemical profile and total thyroxine were tested, with no significant abnormalities found. The patient was anesthetized, and

brain MRI revealed an ovoid right parietal mass that measured approximately 1.9 cm × 1.6 cm (Figure 1). It extended from the corpus callosum cranially to the caudal colliculi caudally and from the meninges dorsolaterally to the medial geniculate nucleus ventromedially. The edges of the mass were well defined on all sequences. It appeared to contact the meninges with a thin layer of overlying parenchyma at the cranial margin. The mass appeared heterogeneously isointense to hypointense to gray matter on T1-weighted (T1W) imaging with a mildly hyperintense rim, suggestive of hemorrhage, high protein or fat content, or calcification along the periphery of the mass. Within the mass there was an irregular region of T1W hypointensity. Peripherally, there was strong contrast enhancement with moderate heterogeneous contrast uptake within the mass. On T2-weighted (T2W) imaging, the mass appeared heterogeneously hyperintense. A marked midline shift to the left was seen, effacing the right lateral ventricle, with a mild obstructive hydrocephalus. Moderate-to-marked T2W hyperintensity was seen in the surrounding gray and white matter, consistent with perilesional edema. There was both transtentorial and foramen magnum herniation.

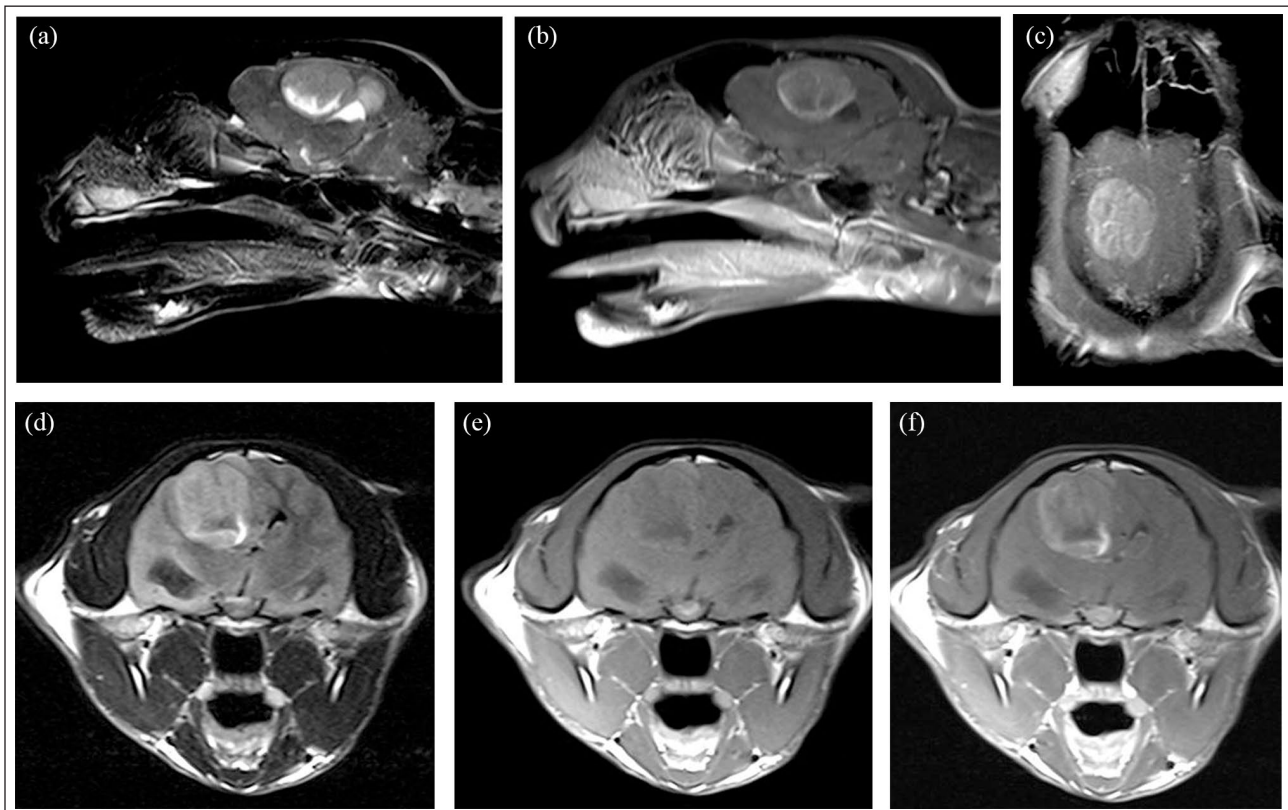

Figure 1 MRI of the brain: (a) T2-weighted (T2W) parasagittal image through the mass; (b) T1-weighted (T1W) post-contrast parasagittal image through the mass; (c) T1W post-contrast dorsal plane through mass; (d) T2W fluid-attenuated inversion recovery transverse image through largest portion of mass; (e) T1W pre-contrast transverse image; and (f) T1W post-contrast transverse image

Cerebrospinal fluid was not collected owing to concerns for elevated intracranial pressure characterized by brain herniation seen on MRI. Serum titers for *Cryptococcus* antigen and toxoplasma (IgG/IgM antibodies) were tested and were negative. The top differential diagnosis was neoplasia. While the apparent meningeal contact was suggestive of meningioma, given the atypical imaging characteristics, an intra-axial neoplasm could not be ruled out. Treatment with prednisolone (1.4 mg/kg PO q24h) and phenobarbital (2.2 mg/kg PO q12h) was initiated. Within 24h of discharge, the patient experienced cluster seizures, with progressive obtundation, and became non-ambulatory with opisthotonus. At that time, the cat was presented to the UC Davis William R Pritchard Veterinary Medical Teaching Hospital, where examination showed the patient to be markedly obtunded with miotic pupils, non-ambulatory with severe tetraparesis, and a whole body turn to the right. Postural reactions were absent in all limbs. Menace response was absent, and nasocortical stimulation responses and pupillary light reflexes were markedly diminished bilaterally. A weak physiologic nystagmus was seen and, during handling, the patient developed bilateral facial twitching. Multifocal or diffuse brain disease, worse on the right, with secondary intracranial hypertension, was diagnosed. Hypertonic saline (7.2%; 5 ml/kg) was administered along with dexamethasone sodium phosphate (0.1 mg/kg IV). Within 60 mins miosis resolved, mentation improved and the patient became ambulatory. Phenobarbital was continued at 4 mg/kg (IV q12h). Following stabilization overnight and ongoing treatment over the next 5 days (IV fluids, phenobarbital 4 mg/kg PO q12h, dexamethasone sodium phosphate 0.1 mg/kg IV q24h and buprenorphine 0.01 mg/kg IV q8h), the cat appeared neurologically static with no further seizures. A craniotomy was pursued for excisional biopsy.

A routine rostrotentorial craniectomy was performed on the right side.¹⁷ Adherent to, but not definitively arising from, the dura was a soft, friable tan mass that appeared distinct from the surrounding brain. Following excision of the mass for cytology, histopathology and tumor banking, an ultrasonic aspirator (Sonopet; Stryker) was used in the tumor cavity to achieve total gross resection. A piece of porcine submucosa (Vetrix BioSIS ECM; Vetrix) was adhered over the skull defect. A thin skull cap of polymethylmethacrylate (PMMA) was shaped to mimic the removed bone and placed over the craniotomy defect prior to closure.

The patient recovered well postoperatively and was treated with opiate analgesia, phenobarbital and anti-inflammatory corticosteroids. The cat was discharged 3 days later to the owner's care on phenobarbital (2.2 mg/kg PO q12h) and a month's tapering course of prednisolone (0.7 mg/kg PO q24h tapered in 50% decrements weekly). At the time of discharge, the cat had a mild

generalized ataxia but was otherwise normal. Adjunctive radiation therapy was declined.

Initial cytology, as well as histology from the surgical biopsy, were suspicious for an aggressive meningioma with characteristics of both papillary (predominant) and rhabdoid subtypes. Immunohistochemistry for CD18 was negative, ruling out a histiocytic origin. Based on histopathological morphology and clinical information, an atypical meningioma was considered to be most likely.

The cat became neurologically normal and remained seizure-free for 3 months. Then, following a week of progressive ataxia and head shaking, a generalized seizure occurred. Over the following 2 weeks, declining mental state and circling to the right were reported, raising suspicion for tumor regrowth. Repeat MRI was declined. Prednisolone was restarted (0.45 mg/kg PO q24h) and then increased (0.9 mg/kg PO q24h) after 2 days owing to lack of response. Despite this, the cat did not improve significantly, and 4 days later was euthanized owing to deterioration in mentation. A full necropsy was performed.

On gross examination, the PMMA skull cap was elevated off the skull, revealing tan, well-demarcated discoloration of the dura. On sectioning, approximately 35% of the right hemisphere (occipital, parietal, temporal and frontal lobes) was infiltrated by a pale tan, soft, ill-defined, poorly demarcated mass, measuring approximately 3 × 4 × 3 cm (Figure 2). The remainder of the gross examination was unremarkable.

Histologically, the neuropil was invaded by an unencapsulated, poorly circumscribed, densely cellular neoplasm composed of round-to-polygonal cells with interspersed small caliber blood vessels. Neoplastic cells largely effaced the parenchyma and invaded into the lateral ventricle (Figure 3). Regions of neoplastic cells were arranged in papillary structures, and others were large, solidly cellular regions. Neoplastic cells had variably distinct cell borders. Cells had small-to-moderate amounts of glassy eosinophilic cytoplasm, and a peripheralized, eccentric round-to-ovoid nucleus. Nuclei had coarse-to-clumped chromatin with one to two variably distinct nucleoli. Anisocytosis and anisokaryosis were marked with six mitotic figures in 10 high-power fields. Approximately 10–20% of the tumor was necrotic with hypereosinophilic regions variably surrounded by pseudopalisading glial cells (Figure 4a). The adjacent white matter was vacuolated with an increased number of microglial cells.

The large round/polygonal cells with glassy eosinophilic cytoplasm and eccentric nuclei were most consistent with neoplastic astrocytes exhibiting a gemistocytic appearance (Figure 4b). This was supported by transmission electron microscopy, which showed the mass was composed of sheets of large gemistocytes with eccentric nuclei and cytoplasm nearly entirely filled with intermediate filaments that

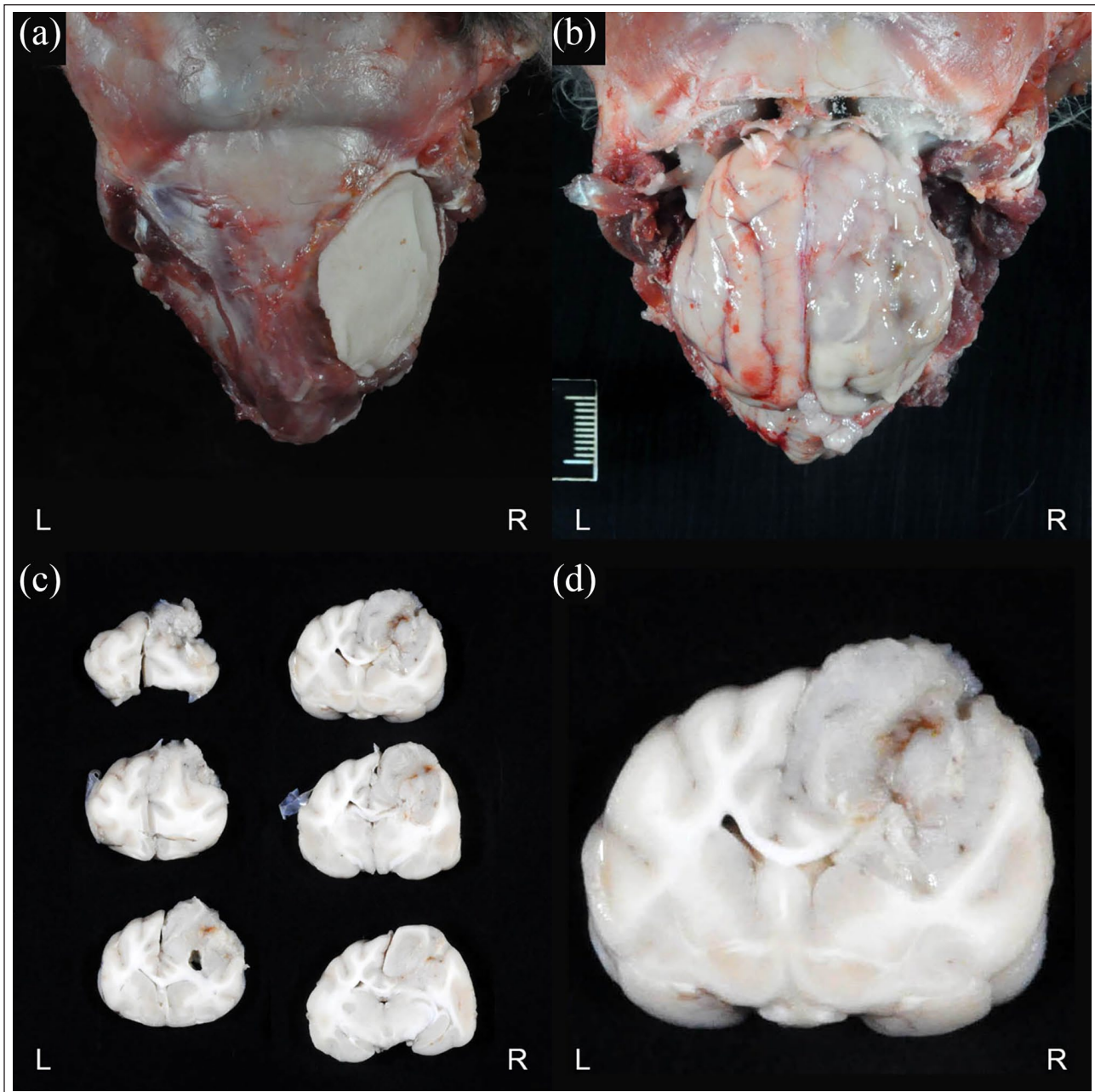


Figure 2 (a) Skull with polymethylmethacrylate implant over previous surgical site. (b) Gross brain in situ. Note the discoloration and malacia on the right hemisphere. (c) Pale tan, poorly defined mass in the right hemisphere, seen on cross section (top to bottom, left [L] to right [R]). (d) Cross section of brain through the mass

were 9–11 nm in diameter (Figure 5). Immunophenotyping of the tumor showed prominent, discrete nuclear immunoreactivity for the glial marker oligodendrocyte transcription factor (Figure 6a), and variable, but specific, labeling for glial fibrillary acidic protein (Figure 6b), most consistent with an infiltrative gemistocytic astrocytoma. Whilst most gemistocytic astrocytomas correspond to a WHO grade II classification, the prominent anisocytosis, anisokaryosis, spontaneous necrosis and elevated mitotic index warranted designation as a grade III, anaplastic gemistocytic

astrocytoma. No evidence of neoplasia was seen in the spinal cord. No other significant abnormalities were noted.

Discussion

Astrocytomas are a rare feline brain tumor with only scattered case reports in the literature.³ There are few reports of gemistocytic astrocytomas (six intracranial cases and six spinal cord cases) reported in the veterinary literature (Table 1).^{4–6,18–21} There are fewer reports of anaplastic astrocytomas (Table 1). Stigen and

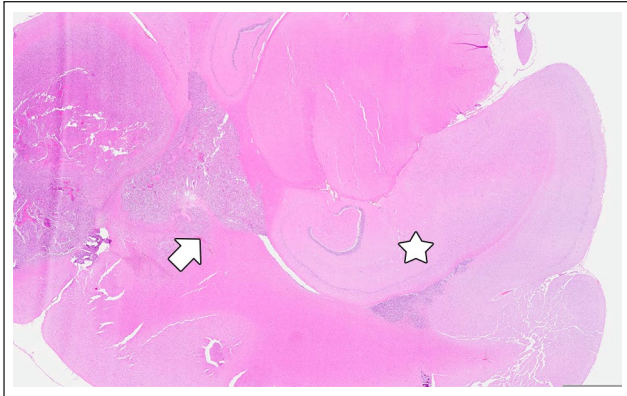

Figure 3 Hematoxylin and eosin-stained section ($\times 0.46$ magnification). The neuropil is invaded by an unencapsulated, poorly circumscribed, densely cellular neoplasm that replaces the parenchyma and invades into the lateral ventricle (arrow). Note the dentate gyrus for anatomical reference (star)

Eggertsdottir reported one untreated case in 2001.²² In 2017, Rissi and Miller reported two untreated cases, one in the hypothalamus and one in the spinal cord.⁷ Kondo et al described an untreated case in a cougar.⁸ In a retrospective review of cats with intracranial neoplasia, Troxel et al reported 24 h postoperative survival in a cat with a gemistocytic astrocytoma.³ The best described case of a treated anaplastic astrocytoma in a cat was by Tamura et al,⁹ who described the surgical treatment and long-term survival of a cat with spinal cord anaplastic astrocytoma (grade III). Recurrence was seen 4 years and 11 months after the first surgery

and a second surgery was performed.¹⁰ The patient later died acutely of unknown causes.¹⁰ Compared with the above reports, our patient survived over 3 months (98 days) postoperatively.

Intraoperatively, total gross resection was achieved with the use of an ultrasonic aspirator, to take the margins into normal brain. As such, the short survival time likely reflects the high grade of the anaplastic astrocytoma. The mass, at the time of necropsy, had an estimated volume of 36 cm^3 , which is nine times the median astrocytoma volume of 4.2 cm^3 and over twice the size of the largest feline astrocytoma (15.6 cm^3) reported by Troxel et al.³ Use of an intraoperative surgical microscope, endoscopy, MRI, cellular labeling for fluorescence-guided resection and postoperative radiation therapy may improve margins and survival, but there is insufficient evidence to say so definitively.^{23–26}

The lack of a broad-based meningeal attachment, contour of the parenchyma around the margins of the mass, degree of peritumoral edema and the heterogeneity of the mass on MRI are not consistent with the typical imaging characteristics of a meningioma and argue for inclusion of other differentials, including glial tumors.^{27,28} However, the ovoid shape and strong contrast enhancement, along with the location and apparent meningeal contact, are consistent with the reported appearance of feline meningiomas on MRI.^{27,28} While an 82% accuracy of diagnosis of meningiomas has been reported on MRI, the distinction between intra- and extra-axial tumors can be challenging on imaging alone.^{19,27} This case serves as a reminder to include neoplasms such as astrocytomas on the differential diagnosis list as well. Additionally, different regions within a tumor

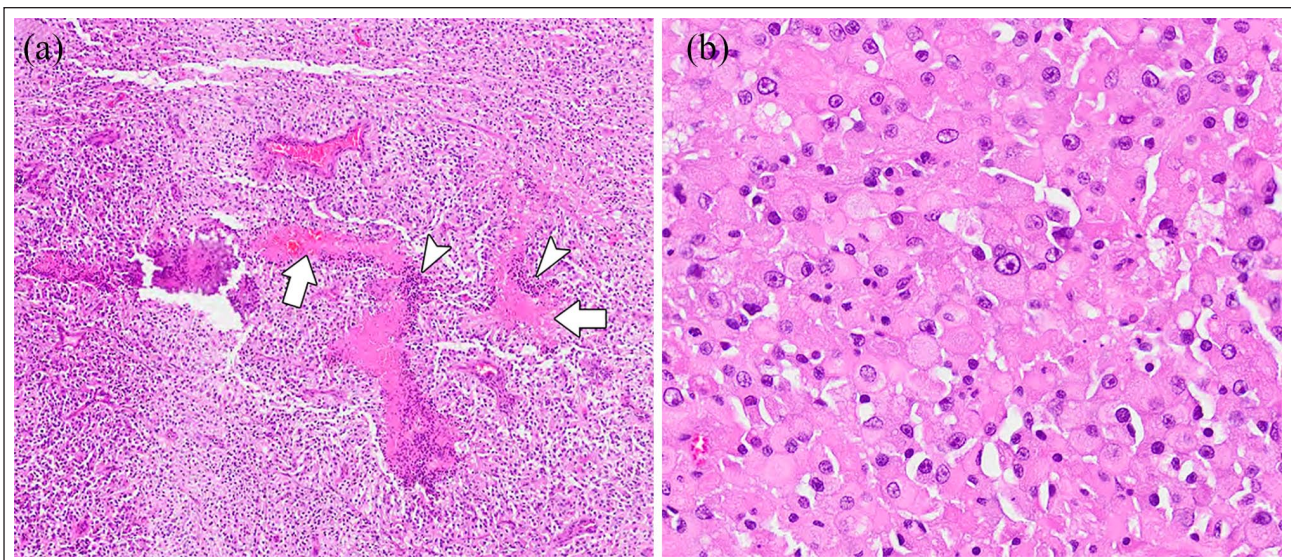


Figure 4 (a) Hematoxylin and eosin (H&E)-stained section ($\times 5$ magnification). Approximately 10–20% of the tumor is necrotic (arrows) with hyper eosinophilic regions variably surrounded by pseudopalisading glial cells (arrowheads). (b) H&E-stained section ($\times 40$ magnification). Gemistocytic astrocytes characterized by large round/polygonal cells with glassy eosinophilic cytoplasm and eccentric nuclei. Marked anisocytosis and anisokaryosis

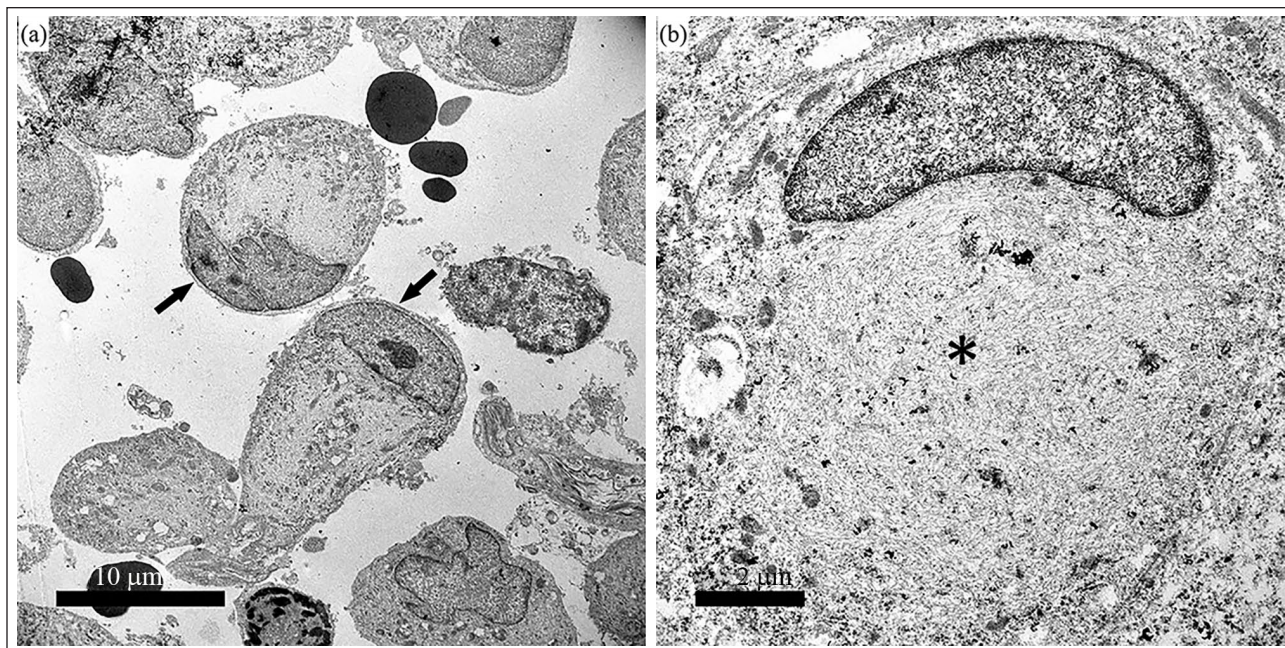


Figure 5 (a) Ultrastructure of feline gemistocytic astrocytoma. Numerous cells display a peripheralized nucleus (arrows). Original magnification, $\times 1200$. (b) The cytoplasm is expanded by abundant glial intermediate filaments (glial fibrillary acidic protein, asterisk). Original magnification, $\times 4000$

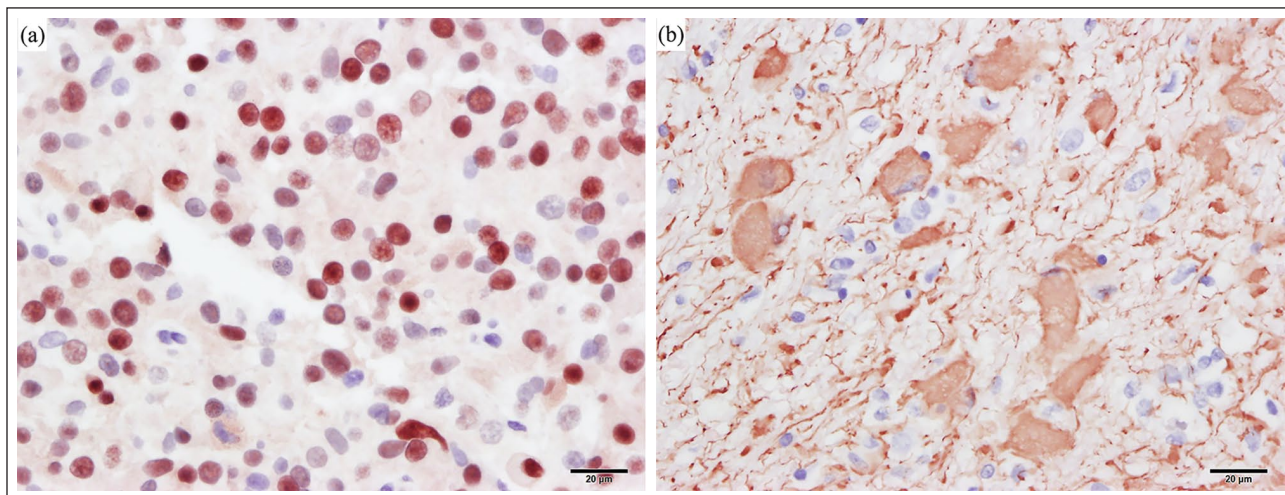


Figure 6 (a) Oligodendrocyte transcription factor immunoreactivity in nuclei of the tumor. (b) Positive immunolabeling for glial fibrillary acidic protein within the tumor

can have different distributions of cell types, and can lead to discordances between biopsy and post-mortem histopathology.^{6,29} Immunohistochemistry for multiple tumor types is not routinely run owing to cost constraints in veterinary medicine and only selective immunohistochemistry was performed in this case at the time of biopsy processing. This case also highlights the need for immunohistochemical staining for multiple tumor types, which may be initially lower on the differential list, to aid in a definitive diagnosis.

Conclusions

We have described the first case of a cat treated surgically for a cerebral grade III anaplastic gemistocytic astrocytoma. The patient did well initially postoperatively but had recurrence within 3 months. Though such neoplasms appear to be rare in cats, it is important to keep such masses on the list of differentials. Further study is required to evaluate the best treatment options for this uncommon brain tumor.

Table 1 Summary of previous feline gemistocytic astrocytoma and anaplastic astrocytoma reports in the veterinary literature

	Number of cases	Age	Treatment	Survival	Location
Gemistocytic astrocytomas					
Troxel et al ³	2	NA	One surgery, other unknown	1 day postoperatively, other unknown	Cerebrum
Aikawa et al ⁴	1	9 years	Surgery and radiation	95 days postoperatively	Cerebrum
Aloisio et al ⁵	1	3 years	–	–	Spinal cord
Demierre et al ⁶	3	11 years 8 years	– Prednisone 1 mg/kg/day	– 30 days	Medulla Cerebrum, spinal cord
Jakab et al ¹⁸	1	13 years 7 months	Phenobarbital 7.5 mg q12h –	45 days –	Caudate nucleus Right ventricle
Hammond et al ¹⁹	2	6 years 8 years	– –	– –	Spinal cord Spinal cord
Marioni-Henry et al ²⁰	1	NA	NA	NA	Spinal cord
Silva et al ²¹	1	6 years	NA	7 days	Spinal cord
Anaplastic astrocytomas					
Rissi and Miller ⁷	2	11 years 3 years	– –	– –	Spinal cord Hypothalamus
Kondo et al ⁸ (cougar)	1	17 years	–	–	Cerebrum
Tamura et al ^{9,10}	1	10 years	Surgery	5 years 7 months	Spinal
Stigen and Eggertsdottir ²²	1	9 years	–	–	Spinal cord

NA = not available; (–) = no treatment/survival, patient euthanized immediately

Acknowledgements The authors would like to acknowledge Dr J Brad Pesavento of the California Animal Health and Food Safety Laboratory System, School of Veterinary Medicine, University of California Davis, for his assistance with preparation of transmission electron microscopy imaging.

Conflict of interest The authors declared no potential conflicts of interest with respect to the research, authorship, and/or publication of this article.

Funding The authors received no financial support for the research, authorship, and/or publication of this article.

Ethical approval This work involved the use of non-experimental animals only (including owned or unowned animals and data from prospective or retrospective studies). Established internationally recognised high standards ('best practice') of individual veterinary clinical patient care were followed. Ethical approval from a committee was therefore not necessarily required.

Informed consent Informed consent (either verbal or written) was obtained from the owner or legal custodian of all animal(s) described in this work (either experimental or non-experimental animals) for the procedure(s) undertaken (either

prospective or retrospective studies). No animals or humans are identifiable within this publication, and therefore additional informed consent for publication was not required.

ORCID iD Vishal D Murthy  <https://orcid.org/0000-0002-2879-9593>

References

- 1 Tomek A, Cizinauskas S, Doherr M, et al. **Intracranial neoplasia in 61 cats: localisation, tumour types and seizure patterns.** *J Feline Med Surg* 2006; 8: 243–253.
- 2 Marioni-Henry K. **Feline spinal cord diseases.** *Vet Clin North Am Small Anim Pract* 2010; 40: 1011–1028.
- 3 Troxel MT, Vite CH, Van Winkle TJ, et al. **Feline intracranial neoplasia: retrospective review of 160 cases (1985–2001).** *J Vet Intern Med* 2003; 17: 850–859.
- 4 Aikawa T, Takahashi T, Fujita H, et al. **Cerebral gemistocytic astrocytoma in a cat.** *Japanese J Vet Anesth Surg* 2010; 41: 23–27.
- 5 Aloisio F, Levine JM and Edwards JF. **Immunohistochemical features of a feline spinal cord gemistocytic astrocytoma.** *J Vet Diagnostic Invest* 2008; 20: 836–838.
- 6 Demierre S, Bley T, Botteron C, et al. **Intracranial astrocytomas in eight cats: clinical and pathological findings.** *Schweiz Arch Tierheilkd* 2002; 144: 66–73.

- 7 Rissi DR and Miller AD. **Feline glioma: a retrospective study and review of the literature.** *J Feline Med Surg* 2017; 19: 1307–1314.
- 8 Kondo H, Leone AM, Erlacher-Reid C, et al. **Medium-grade astrocytoma in a cougar (*Puma concolor*).** *J Zoo Wildl Med* 2012; 43: 956–960.
- 9 Tamura S, Hori Y, Tamura Y, et al. **Long-term follow-up of surgical treatment of spinal anaplastic astrocytoma in a cat.** *J Feline Med Surg* 2013; 15: 921–926.
- 10 Tamura S, Tamura Y and Uchida K. **Recurrence of spinal anaplastic astrocytoma in a cat after surgical treatment and long-term follow-up.** *J Feline Med Surg* 2018; 20: 200–201.
- 11 Sato T, Nakamura A, Shibuya H, et al. **Cerebral high-grade astrocytoma (glioblastoma) in a cat.** *J Vet Med Ser A Physiol Pathol Clin Med* 2003; 50: 269–271.
- 12 Sant'ana FJF, Serakides R and Graça DL. **Pilocytic astrocytoma in a cat.** *Vet Pathol* 2002; 39: 759–761.
- 13 Sarfaty D, Carrillo J and Patnaik A. **Cerebral astrocytoma in four cats: clinical and pathologic findings.** *J Am Vet Med Assoc* 1987; 191: 976–978.
- 14 Zaki FA and Hurvitz AI. **Spontaneous neoplasms of the central nervous system of the cat.** *J Small Anim Pract* 1976; 17: 773–782.
- 15 Komarnisky MD. **Astrocytoma in a cat.** *Can Vet J* 1985; 26: 237–240.
- 16 Louis DN, Ohgaki H, Wiestler OD, et al. **The 2007 WHO classification of tumours of the central nervous system.** *Acta Neuropathol* 2007; 114: 97–109.
- 17 Sturges BK and Dickinson PJ. **Cranial surgery.** In: Johnston SA and Tobias KM (eds). *Veterinary surgery: small animal expert consult.* St Louis, MO: Elsevier, 2017, pp 549–569.
- 18 Jakab C, Gal J and Kovacs R. **Gemistocytic astrocytoma in a 7-month-old cat. Case report.** *Magy Allatorvosok Lapja* 2004; 126: 487–491.
- 19 Hammond JJ, deLahunta A, Glass EN, et al. **Feline spinal cord gliomas: clinicopathologic and diagnostic features of seven cases.** *J Vet Diagn Invest* 2014; 26: 513–520.
- 20 Marioni-Henry K, Van Winkle TJ, Smith SH, et al. **Tumors affecting the spinal cord of cats: 85 cases (1980–2005).** *J Am Vet Med Assoc* 2008; 232: 237–243.
- 21 Silva EO, Ferioli RB, Moreno K, et al. **Case study: feline spinal cord gemistocytic astrocytoma.** *Online J Vet Res* 2011; 15: 200–210.
- 22 Stigen YB and Eggertsdottir AV. **Spinal cord astrocytoma in a cat.** *J Small Anim Pract* 2001; 42: 306–310.
- 23 Hu H, Barker A, Harcourt-Brown T, et al. **Systematic review of brain tumor treatment in dogs.** *J Vet Intern Med* 2015; 29: 1456–1463.
- 24 Klopp LS and Rao S. **Endoscopic-assisted intracranial tumor removal in dogs and cats: long-term outcome of 39 cases.** *J Vet Intern Med* 2009; 23: 108–115.
- 25 Ijiri A, Yoshiki K, Tsuboi S, et al. **Surgical resection of twenty-three cases of brain meningioma.** *J Vet Med Sci* 2014; 76: 331–338.
- 26 Nakano Y, Nakata K, Shibata S, et al. **Fluorescein sodium-guided resection of intracranial lesions in 22 dogs.** *Vet Surg* 2018; 47: 302–309.
- 27 Troxel MT, Vite CH, Massicotte C, et al. **Magnetic resonance imaging features of feline intracranial neoplasia: retrospective analysis of 46 cats.** *J Vet Intern Med* 2004; 18: 176–189.
- 28 Bentley RT. **Magnetic resonance imaging diagnosis of brain tumors in dogs.** *Vet J* 2015; 14: 3209–3218.
- 29 Summers B, Cummings J and DeLahunta A. **Tumors of the central nervous system.** In: Summers B, Cummings J and DeLahunta A (eds). *Veterinary neuropathology.* St Louis, MO: Mosby, 1994, p 364.