



---

## **Suspected pancreatic carcinoma needle tract seeding in a cat**

Authors: Jegatheeson, Selvi, Dandrieux, Julien RS, and Cannon, Claire M

Source: Journal of Feline Medicine and Surgery Open Reports, 6(1)

Published By: SAGE Publishing

URL: <https://doi.org/10.1177/2055116920918161>



# Suspected pancreatic carcinoma needle tract seeding in a cat

Selvi Jegatheeson , Julien RS Dandrieux   
 and Claire M Cannon

*Journal of Feline Medicine and Surgery Open Reports*  
 1–6

© The Author(s) 2020

Article reuse guidelines:

sagepub.com/journals-permissions

DOI: 10.1177/2055116920918161

journals.sagepub.com/home/jfmsopenreports

This paper was handled and processed

by the European Editorial Office (ISFM)

for publication in *JFMS Open Reports*



## Abstract

**Case summary** A 15-year-old male neutered domestic longhair cat was referred for investigation of a pancreatic nodule. Fine-needle aspiration of the nodule was performed on two occasions, 2 weeks apart, and cytology revealed pyogranulomatous inflammation and moderately dysplastic exocrine pancreatic epithelium, suspicious for neoplasia. Thoracic radiographs were unremarkable and a partial pancreatectomy was performed. On histopathology, the nodule was diagnosed as a moderately differentiated pancreatic adenocarcinoma. Two weeks after surgery, a firm subcutaneous nodule was detected on the left ventrolateral abdomen. Cytology of the nodule was suggestive of pancreatic carcinoma and needle tract seeding was suspected. With palliative treatment, the cat lived a further 136 days.

**Relevance and novel information** To our knowledge, this represents the first report of suspected transabdominal needle tract seeding of pancreatic carcinoma following fine-needle aspiration in veterinary medicine. Veterinarians should consider this when discussing risks of pancreatic fine-needle aspiration with owners and should attempt to minimise the number of needle aspirations where possible.

**Keywords:** Fine-needle biopsy; pancreatic adenocarcinoma; complications; tumour seeding

**Accepted:** 15 March 2020

## Case description

A 4.5 kg 15-year-old male neutered domestic longhair cat was seen by the referring veterinary clinic for a 2-week history of vomiting. Previous medical history included treatment with radioactive iodine ( $I^{131}$ ) for hyperthyroidism 18 months previously. On abdominal ultrasound prior to  $I^{131}$  treatment, multiple 3–6 mm hypoechoic pancreatic nodules were noted. Fine-needle aspirates were taken prior to  $I^{131}$  treatment, but the samples were acellular and non-diagnostic.

At the time of presentation for vomiting, a complete blood count, total thyroxine (T4) and biochemistry were within normal limits. Feline pancreatic lipase was elevated (16.6  $\mu\text{g/l}$ ; reference interval [RI] 0.1–3.5  $\mu\text{g/l}$ ). An abdominal ultrasound was performed by an internal medicine specialist, who noted a 12.4  $\times$  13.5 mm hypoechoic mass affecting the left limb of the pancreas (Figure 1).

The right limb of the pancreas was normal, and no other abnormalities were noted. Fine-needle aspiration (FNA) of the mass was performed. Needle gauge and number of aspirates were not recorded. The cytological

diagnosis was pyogranulomatous inflammation; however, dysplastic epithelium was also noted. The cat was referred to U-Vet Werribee Animal Hospital for further investigation. Physical examination revealed an approximately 2 cm firm mid-abdominal mass, and a grade II/VI parasternal systolic heart murmur. The cat was in a good body condition. No other concerns were noted on physical examination. An abdominal ultrasound was performed by a radiology resident and reviewed by a board-certified radiologist. The mass in the left limb of the pancreas measured 14.2  $\times$  13 mm and multiple smaller (<5 mm) hypoechoic nodules

Department of Veterinary Clinical Sciences, University of Melbourne, Werribee, VIC, Australia

### Corresponding author:

Selvi Jegatheeson BSc(hons), DVM, MANZCVS (Small Animal Medicine), Department of Veterinary Clinical Sciences, University of Melbourne, 250 Princes Highway, Werribee, VIC 3010, Australia

Email: selvi.jegatheeson@unimelb.edu.au



Creative Commons Non Commercial CC BY-NC: This article is distributed under the terms of the Creative Commons

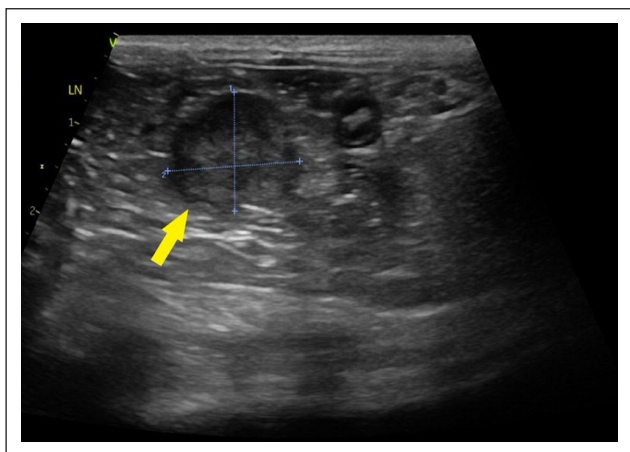
Attribution-NonCommercial 4.0 License (<https://creativecommons.org/licenses/by-nc/4.0/>) which permits non-commercial use,

reproduction and distribution of the work without further permission provided the original work is attributed as specified on the SAGE and Open

Access pages (<https://us.sagepub.com/en-us/nam/open-access-at-sage>).

Downloaded From: <https://staging.bioone.org/journals/Journal-of-Feline-Medicine-and-Surgery-Open-Reports> on 14 Dec 2024

Terms of Use: <https://staging.bioone.org/terms-of-use>



**Figure 1** Ultrasound image showing the hypoechoic mass in the left limb of the pancreas (arrow)

were noted in the pancreatic body. The right limb of the pancreas was noted to be normal. Mild thickening of the muscularis of one segment of jejunum was noted. Regional lymph nodes were normal and no other abnormalities were detected. The larger pancreatic mass was aspirated with a 22G needle with five passes. On cytology, a population of cohesive epithelial cells with moderate cellular atypia on a background of marked inflammation were described (Figure 2).

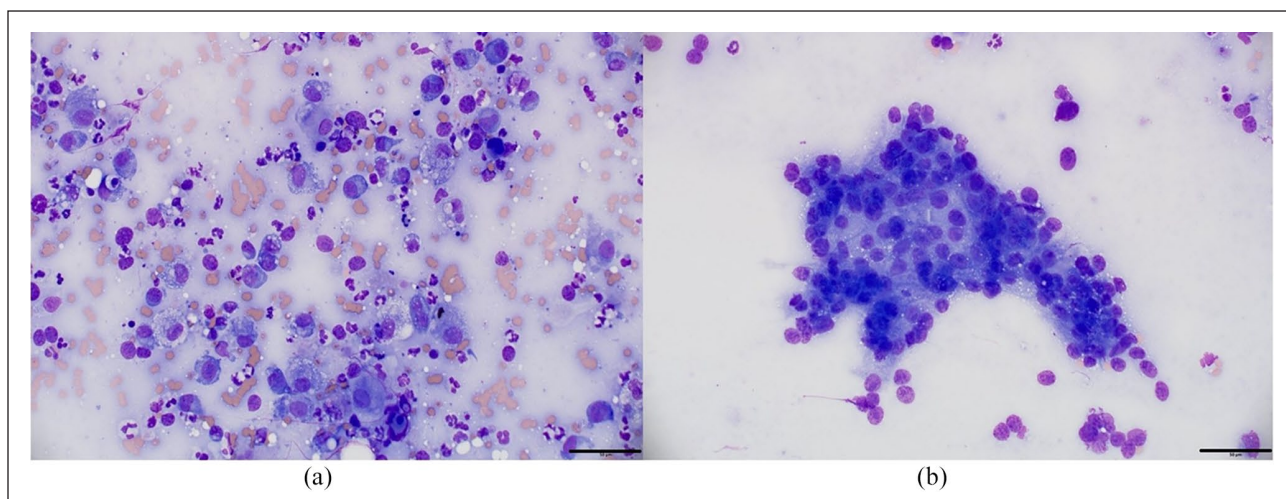
The major differentials were pyogranulomatous inflammation (secondary to infectious diseases such as toxoplasmosis or feline infectious peritonitis) or a well-differentiated adenocarcinoma. Toxoplasma serology revealed an elevated IgG (1:1024) and negative IgM (<1:16), suggestive of previous exposure rather than active infection. Clindamycin (Antirobe; Zoetis) 50 mg PO q12h for 4 weeks was dispensed while awaiting serology results. Four weeks later, repeat toxoplasma serology revealed the IgG had reduced to <1:64, which

was not suggestive of active or previous infection and thus clindamycin was discontinued.

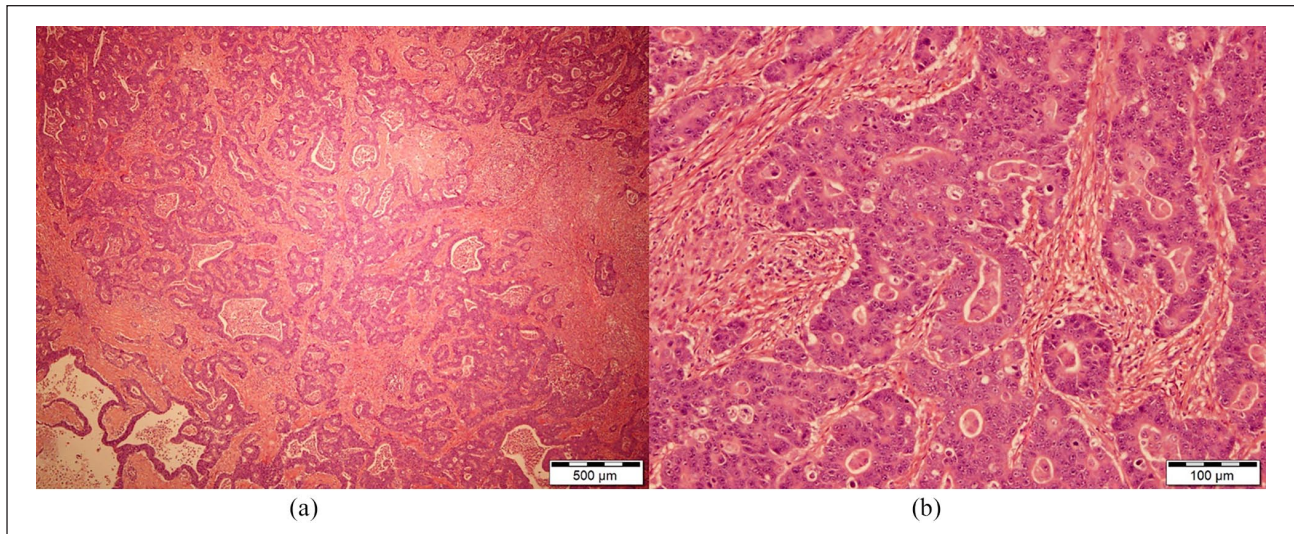
The cat was re-evaluated 5 weeks following the ultrasound, as the owners reported melaena. No other clinical signs were reported. On physical examination, weight loss of 400 g was noted and the cat was in thin body condition (body condition score [BCS] 3/9). Evaluation of the haemogram showed a low-to-normal haematocrit (Hct; 0.31 l/l; RI 0.30–0.45 l/l) with no evidence of regeneration ( $5 \times 10^9/l$ ; RI  $3\text{--}50 \times 10^9/l$ ) and normocytic normochromic red blood cells. Biochemistry did not show any abnormalities. Omeprazole (Losec; Sandoz) 5 mg PO q12h was prescribed and removal of the pancreatic mass was advised, as there was concern for a possible gastrinoma causing upper gastrointestinal bleeding.

Eleven days later, the cat was re-evaluated. The haematocrit was assessed and showed a mild anaemia (Hct 0.281/l). Thoracic radiographs were performed and no abnormalities were noted. A repeat abdominal ultrasound was then performed by a radiology resident, 2 months after the initial presentation. The previously noted hypoechoic nodule in the left limb of the pancreas was static and the previously ill-defined hypoechoic nodules throughout the body of the pancreas were not identified. The mild thickening of jejunum had resolved. There was no evidence of regional lymphadenopathy and therefore lymph node aspiration was not performed. The following day, upper gastrointestinal endoscopy was performed to assess for proximal gastrointestinal bleeding as the cause of anaemia and melaena; however, no abnormalities were noted. Exploratory laparotomy and partial pancreatectomy were performed, along with full-thickness biopsies of the stomach, small intestines and gastric lymph node. Surgical drains were not used.

Histopathology of the pancreatic mass showed effacement of tissue with neoplastic epithelial cells, with 22/10 mitoses/high-power field, consistent with a



**Figure 2** Cytology of a second aspirate of the hypoechoic pancreatic mass: (a) representative image of mixed inflammation; (b) representative clusters of cohesive epithelial cells suspected to be exocrine pancreatic cells, showing mild-to-moderate anisocytosis and anisokaryosis. The bars in (a) and (b) represent 50 µm



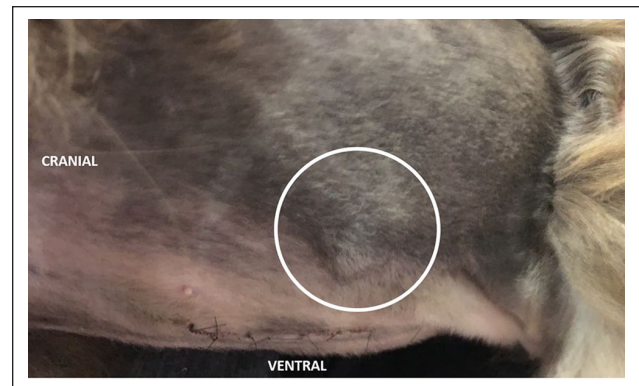
**Figure 3** Photomicrograph showing the moderately differentiated pancreatic adenocarcinoma. (a) The neoplastic population is arranged in incomplete glandular structures (haematoxylin and eosin, bar = 500 µm). (b) Neoplastic cells are columnar and display moderate anisocytosis and anisokaryosis; thick fibrous bands (desmoplasia) interspace the neoplastic cells (haematoxylin and eosin, bar = 100 µm)

moderately differentiated pancreatic adenocarcinoma (Figure 3). The tumour impinged upon adjacent adipose tissue, and no vascular or lymphatic invasion was noted. Histopathology of the gastric lymph node showed oedema. Diffuse lymphoplasmacytic enteritis and gastritis was diagnosed from small intestinal and gastric biopsies. There was no evidence of involvement of the epithelium, or erosion from the small intestine and stomach biopsies; for this reason, gastrointestinal bleeding secondary to diffuse inflammation was deemed unlikely.

Recovery from surgery was unremarkable. At a revisit 2 weeks postoperatively, the owners reported a mass at the left ventrolateral abdomen (Figure 4) and ongoing melaena.

On physical examination, a 24 × 15 × 9 mm lobulated firm, fixed subcutaneous nodule was noted on the left caudoventral body wall, adjacent to the 13th rib. Fine-needle aspirates were collected from the nodule. Cytology showed neoplastic epithelial cells with occasional acinar-like arrangements and fine pink pigment or globular material consistent with a carcinoma of glandular-origin, highly suspicious for metastatic pancreatic adenocarcinoma (Figure 5).

Haemogram, biochemistry and total T4 were performed. A worsening non-regenerative anaemia with a Hct of 0.21 l/l (RI 0.30–0.45 l/l) was noted, as well as elevated total calcium of 2.85 mmol/l (RI 1.75–2.50 mmol/l), elevated urea of 13.8 mmol/l (RI 5.4–10.7 mmol/l) and creatinine of 227 µmol/l (RI 70–160 µmol/l). Ionised calcium was not assessed and the mild azotaemia was considered likely to be pre-renal (no urinalysis was performed at the time to confirm this suspicion); however, underlying renal disease or metastatic disease could not be ruled out.

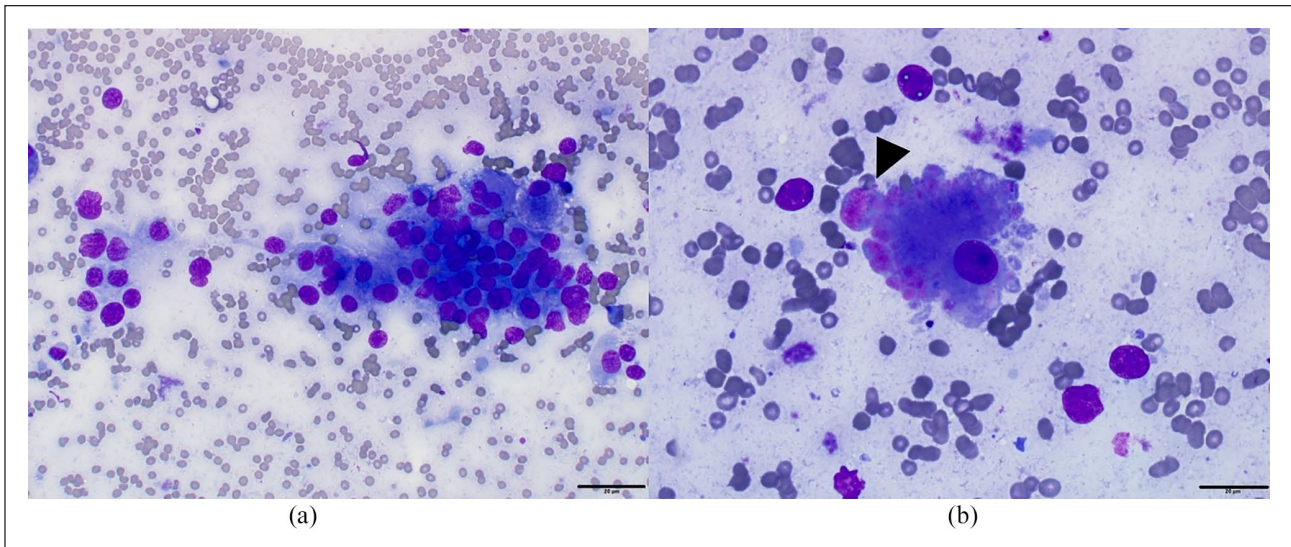


**Figure 4** Gross image of the body wall nodule (circle) 2 weeks following partial pancreatectomy

Options discussed with the owner included a thoracic and abdominal CT, surgical resection of the nodule and adjuvant chemotherapy; chemotherapy alone (either intravenous chemotherapy or oral toceranib); or palliative care. The owners elected palliative care only and treatment with prednisolone (Pred-X; Apex) 2.5 mg PO q24h, mirtazapine (Apo-mirtazapine; Apotex) 1.875 mg q72h and maropitant (Cerenia; Zoetis) 8 mg PO q24h was started. A recheck 90 days after the start of palliative treatment noted severe weight loss (3.5 kg, BCS 1/9) and progression of the abdominal wall nodule that measured approximately 8 cm in diameter. The cat was eventually euthanased after 136 days of palliative treatment owing to progressive weight loss and poor quality of life, and no necropsy was performed.

## Discussion

We present the first report of suspected needle tract seeding of a pancreatic carcinoma in the veterinary literature.



**Figure 5** Fine-needle aspirate smear of the body wall nodule, stained with Wright's Giemsa. (a) Clumps of polygonal epithelial cells with round nuclei and a variable amount of granular blue cytoplasm with indistinct cell borders, suspected to be of exocrine pancreatic origin, in a light blue proteinaceous background containing blood and ruptured cells. The cells display several atypical features, including moderate anisocytosis and anisokaryosis, lacy chromatin with prominent nucleoli and a variable nuclear to cytoplasmic ratio. (b) Pink granular material (arrowhead) associated with the atypical epithelial cells, suggestive of a glandular secretion. The bars in (a) and (b) represent 20 µm

Exocrine pancreatic carcinoma is a rare diagnosis in dogs and cats, representing <0.5% of all cancers, and shows an aggressive biological behaviour.<sup>1</sup> The tumour in the present case was histologically reviewed and diagnosed as a moderately differentiated pancreatic adenocarcinoma. While no validated grading system has been established for feline pancreatic carcinomas, the disease shows an aggressive biological behaviour, and neither mitotic rate nor extent of differentiation has been shown to affect prognosis.<sup>2</sup> Cats with pancreatic carcinoma can show non-specific and often chronic signs, including vomiting, anorexia, paraneoplastic alopecia and icterus if the common bile duct is obstructed.<sup>1</sup> In many cases, the cancer has already metastasised to regional lymph nodes, the liver or to more distant sites at the time of presentation.<sup>2</sup> Poor prognostic factors reported include the presence of abdominal effusion and metastatic disease.<sup>2,3</sup> In this case, there was rapid growth of the subcutaneous nodule, and at the last recheck, the cat was in a poor body condition. Owing to the owner's decision to palliate, further imaging was not performed, so while no further subcutaneous lesions were detected, internal progressive or metastatic disease cannot be ruled out.

Older studies report survival times ranging from a median of 33 days in cats with metastatic disease to 165 days in cats treated with surgery and chemotherapy.<sup>2</sup> More recently, a study of nine cats with solitary exocrine pancreatic carcinoma that were treated with surgery ± adjuvant chemotherapy had a median survival time of 316.5 days, suggesting that the prognosis for this disease

may not be as grave as earlier reports suggest, if diagnosis and surgical treatment is undertaken early.<sup>3</sup>

Differential diagnoses for pancreatic masses in cats include pancreatitis, exocrine pancreatic carcinoma, nodular hyperplasia, pseudocysts, adenomas, metastatic tumours, pancreatic abscesses and endocrine tumours.<sup>2</sup> Diagnosis of pancreatic carcinoma can be challenging as abdominal ultrasound alone has poor specificity for differentiating focal inflammatory lesions and nodular hyperplasia from neoplasia.<sup>4,5</sup> The accuracy of cytology for investigating pancreatic lesions in dogs and humans has a reported diagnostic yield of 70–95%, and is thus considered a valid and important technique.<sup>6–10</sup>

A case-control study assessing the safety of FNA of the pancreas in 73 cats with ultrasonographic evidence of pancreatic disease, including 33 cats that had pancreatic masses/nodules, compared with 63 cats that had FNA of abdominal organs other than the pancreas, found no significant difference in the incidence of complications, with complication rates of 11% and 14%, respectively. Complications included haemorrhage, hypotension, respiratory distress and pleural effusion.<sup>11</sup> This study had a minimum follow-up period of 48h and a maximum follow-up of 7 days, so only acute complications were assessed.<sup>11</sup> In humans, endoscopic ultrasound (EUS)-guided FNA of the pancreas is routinely performed, and is reportedly safer than percutaneous pancreatic FNA, with an overall complication rate of 1.5–3.0%.<sup>11–14</sup> Reported complications following percutaneous and EUS-guided pancreatic aspiration in humans included mild-to-severe

pancreatitis, pancreatic abscessation, fistula formation, haemorrhage, sepsis and needle tract seeding.<sup>9,13,15</sup>

In the present case, the cat developed melaena 5 weeks after pancreatic aspiration. Given the time between pancreatic aspiration and the development of melaena, bleeding secondary to pancreatic trauma following FNA was considered unlikely. Other possible causes of the melaena, including the presence of a gastrinoma, other gastrointestinal tumours or gastric ulceration, were not identified, despite extensive work-up (endoscopy and exploratory laparotomy), but they cannot be ruled out completely.

Needle tract seeding is rare but has been reported in a number of cancers in human oncology, including breast, hepatocellular, pulmonary, prostate, pancreatic and bladder carcinoma, as well as, rarely, with sarcomas.<sup>9,15–18</sup> The incidence of needle tract seeding in pancreatic cancer is reportedly higher than for other malignancies in humans – between 0.003% and 0.009%, although this may be an underestimation because the time for development of metastasis is longer than the rapid progression and short life span of affected patients.<sup>9</sup> With each needle pass there are reportedly between 100 and 10,000 cells shed; however, the majority of these cells are likely lost to tissues surrounding the lesion with very few actually implanting within the subcutaneous tissue or skin.<sup>9</sup> The risks of seeding are thought to be greater when FNA is performed percutaneously via CT or ultrasound guidance vs EUS-guided FNA.<sup>19</sup> Other factors thought to increase the risk of pancreatic seeding along a biopsy tract include greater number of needle passes, larger-gauge needles and less well-differentiated tumours.<sup>9,20</sup>

In human medicine, preoperative biopsy (including FNA) is not recommended for solitary pancreatic lesions, unless the results would change the management of the patient.<sup>9</sup> It is argued by one author that ‘it is unacceptable to subject patients to the risks (of pancreatic FNA) including dissemination of disease, when they may have potentially curable lesions’.<sup>9</sup> Instead, in patients who have potentially resectable disease, exploratory surgery is recommended without prior FNA.<sup>9</sup> In our opinion, given the rarity of seeding events in humans (<1 in 10,000) and veterinary medicine, in animals with a pancreatic nodule, obtaining a diagnosis via a relatively non-invasive, safe and cost-effective method such as FNA and cytology would provide a good chance for therapeutic planning and prognostication for veterinary patients, as opposed to pursuing more invasive and expensive laparotomy with potentially increased morbidity.

Needle tract seeding of other carcinomas, mostly of urothelial or pulmonary origin, has been reported in dogs and cats.<sup>21–24</sup> The current lack of published reports describing pancreatic needle tract seeding in the veterinary literature is therefore likely due to the rarity of both the event and this form of cancer, as well as the short survival of affected animals. Based on clinician and patient

surveys, the average time to the development of metastasis from FNA in humans is 4 months. In the present case, the pancreas was aspirated at three time points: 18 months prior to the presentation discussed here, when the mass was not present, and then 12 and 14 weeks prior to detection of the body wall nodule. Owing to the long time frame and lack of macroscopic disease at the time of the first sampling of the pancreas, it is considered less likely that needle tract seeding occurred at this time point; however, microscopic spread internally cannot be ruled out. It is considered more likely that the presumed needle tract seeding event occurred following the aspirates taken either 12 or 14 weeks prior to detection of the body wall nodule.

The impact of needle tract seeding on survival in humans is currently unclear, with some reports of patients rapidly deteriorating following seeding, while others do not show a change in their disease course if the tumour tract is resected. In the present case, the prognosis given to the owners was poorer than when the cat was thought to be free of gross disease; however, following diagnosis of the subcutaneous nodule the cat went on to live another 136 days with palliative treatment alone, before elective euthanasia owing to clinical deterioration. There are few established standardised protocols for the treatment of metastatic pancreatic carcinoma in cats. Surgery for resectable disease is indicated and chemotherapy protocols using doublet therapy with carboplatin and gemcitabine have reported efficacy.<sup>3,25</sup> Tyrosine kinase inhibitors (TKIs) are used in human medicine for treatment of pancreatic carcinoma, often in combination with gemcitabine; however, the efficacy of TKIs for feline pancreatic carcinoma is unknown.<sup>3</sup>

There are several limitations in the present report, including the lack of advanced imaging, such as a CT scan, to better define the location of the abdominal wall lesion; no information regarding the needle gauge or number of needle passes taken from the pancreatic nodule at the first aspirate; no necropsy to confirm the seeding and assess for metastasis elsewhere; and a lack of histopathology from the subcutaneous nodule. However, given that the cytology from this nodule was highly suggestive of pancreatic adenocarcinoma and the location was consistent with where a pancreatic FNA might have been taken, it is reasonable to make the assumption of needle tract seeding.

## Conclusions

Pancreatic carcinoma in cats has the potential to seed through a needle tract, as reported in humans; however, such events are likely to be extremely rare based on the human literature and a lack of previous reports in the veterinary literature. In our opinion, veterinarians should consider the risk of seeding of a tumour when educating owners about the possible risks of FNA of the pancreas.

Strategies to reduce the risk of tumour seeding, such as minimising the number of aspirations and utilising a smaller needle gauge, should be considered where possible.

**Acknowledgements** The authors wish to acknowledge Dr Natalie Courtman for her review of cytological samples and Dr Panos Loukopoulos for his review of histological specimens.

**Conflict of interest** The authors declared no potential conflicts of interest with respect to the research, authorship, and/or publication of this article.

**Funding** The authors received no financial support for the research, authorship, and/or publication of this article.

**Ethical approval** This work involved the use of non-experimental animals only (including owned or unowned animals and data from prospective or retrospective studies). Established internationally recognised high standards ('best practice') of individual veterinary clinical patient care were followed. Ethical approval from a committee was therefore not necessarily required.

**Informed consent** Informed consent (either verbal or written) was obtained from the owner or legal custodian of all animal(s) described in this work (either experimental or non-experimental animals) for the procedure(s) undertaken (either prospective or retrospective studies). No animals or humans are identifiable within this publication, and therefore additional informed consent for publication was not required.

**ORCID iDs** Selvi Jegatheeson  <https://orcid.org/0000-0001-6510-0238>

Julien RS Dandrieux  <https://orcid.org/0000-0001-6308-8749>

## References

- 1 Withrow SJ, Page R and Vail DM. *Withrow and MacEwen's small animal clinical oncology*. St Louis, MO: Elsevier Health Sciences, 2013.
- 2 Linderman M, Brodsky E, de Lorimier LP, et al. **Feline exocrine pancreatic carcinoma: a retrospective study of 34 cases**. *Vet Comp Oncol* 2013; 11: 208–218.
- 3 Nicoletti R, Chun R, Curran KM, et al. **Postsurgical outcome in cats with exocrine pancreatic carcinoma: nine cases (2007–2016)**. *J Am Anim Hosp Assoc* 2018; 54: 291–295.
- 4 Lamb C, Simpson K, Boswood A, et al. **Ultrasonography of pancreatic neoplasia in the dog: a retrospective review of 16 cases**. *Vet Rec* 1995; 137: 65–68.
- 5 Hecht S, Penninck DG, Keating JH, et al. **Imaging findings in pancreatic neoplasia and nodular hyperplasia in 19 cats**. *J Vet Radiol* 2007; 48: 45–50.
- 6 McGuire DE, Venu RP, Brown RD, et al. **Brush cytology for pancreatic carcinoma: an analysis of factors influencing results**. *Gastrointest Endosc* 1996; 44: 300–304.
- 7 Siddiqui AA, Brown LJ, Hong S-KS, et al. **Relationship of pancreatic mass size and diagnostic yield of endoscopic ultrasound-guided fine needle aspiration**. *Dig Dis Sci* 2011; 56: 3370–3375.
- 8 Cordner AP, Sharkey LC, Armstrong PJ, et al. **Cytologic findings and diagnostic yield in 92 dogs undergoing fine-needle aspiration of the pancreas**. *J Vet Diagn Invest* 2015; 27: 236–240.
- 9 Goldin SB, Bradner MW, Zervos EE, et al. **Assessment of pancreatic neoplasms: review of biopsy techniques**. *J Gastrointest Surg* 2007; 11: 783–790.
- 10 Eloubeidi MA, Varadarajulu S, Desai S, et al. **A prospective evaluation of an algorithm incorporating routine preoperative endoscopic ultrasound-guided fine needle aspiration in suspected pancreatic cancer**. *J Gastrointest Surg* 2007; 11: 813–819.
- 11 Crain SK, Sharkey LC, Cordner AP, et al. **Safety of ultrasound-guided fine-needle aspiration of the feline pancreas: a case-control study**. *J Feline Med Surg* 2015; 17: 858–863.
- 12 Zamboni GA, D'Onofrio M, Idili A, et al. **Ultrasound-guided percutaneous fine-needle aspiration of 545 focal pancreatic lesions**. *Am J Roentgenol* 2009; 193: 1691–1695.
- 13 Levin DP and Bret PM. **Percutaneous fine-needle aspiration biopsy of the pancreas resulting in death**. *Gastrointest Radiol* 1991; 16: 67–69.
- 14 O'Toole D, Palazzo L, Arotçarena R, et al. **Assessment of complications of EUS-guided fine-needle aspiration**. *Gastrointest Endosc* 2001; 53: 470–474.
- 15 Smith EH. **Complications of percutaneous abdominal fine-needle biopsy. Review**. *Radiology* 1991; 178: 253–258.
- 16 Kim S, Lim H, Lee W, et al. **Needle-tract implantation in hepatocellular carcinoma: frequency and CT findings after biopsy with a 19.5-gauge automated biopsy gun**. *J Am Vet Med Assoc* 2000; 25: 246–250.
- 17 Laird A, Couper CH, Glancy S, et al. **Renal cell carcinoma needle biopsy: sowing the seed for later complications?** *BMJ Case Rep* 2014; 2014. DOI: 10.1136/bcr-2014-203691.
- 18 Volanis D, Neal DE, Warren AY, et al. **Incidence of needle-tract seeding following prostate biopsy for suspected cancer: a review of the literature**. *BJU Int* 2015; 115: 698–704.
- 19 Paquin SC, Gariépy G, Lepanto L, et al. **A first report of tumor seeding because of EUS-guided FNA of a pancreatic adenocarcinoma**. *J Gastrointest Endosc* 2005; 61: 610–611.
- 20 Shyamala K, Girish H and Murgod S. **Risk of tumor cell seeding through biopsy and aspiration cytology**. *J Int Soc Prev Commun Dent* 2014; 4: 5–11. DOI: 10.4103/2231-0762.129446.
- 21 Higuchi T, Burcham GN, Childress MO, et al. **Characterization and treatment of transitional cell carcinoma of the abdominal wall in dogs: 24 cases (1985–2010)**. *J Am Vet Med Assoc* 2013; 242: 499–506.
- 22 Nyland TG, Wallack ST and Wisner ER. **Needle-tract implantation following US-guided fine-needle aspiration biopsy of transitional cell carcinoma of the bladder, urethra, and prostate**. *Vet Radiol Ultrasound* 2002; 43: 50–53.
- 23 Warren-Smith C, Roe K, de la Puerta B, et al. **Pulmonary adenocarcinoma seeding along a fine needle aspiration tract in a dog**. *Vet Rec* 2011; 169: 181. DOI: 10.1136/vr.d2357.
- 24 Vignoli, Rossi, Chierici, et al. **Needle tract implantation after fine needle aspiration biopsy (FNAB) of transitional cell carcinoma of the urinary bladder and adenocarcinoma of the lung**. *Swiss Arch Vet Med* 2007; 149: 314–318.
- 25 Martinez-Ruzafa I, Dominguez P, Dervisis N, et al. **Tolerability of gemcitabine and carboplatin doublet therapy in cats with carcinomas**. *J Vet Intern Med* 2009; 23: 570–577.