



Histologic identification of intraocular *Cytauxzoon felis* in three cats

Authors: Meekins, Jessica, and Cino-Ozuna, Ada G

Source: Journal of Feline Medicine and Surgery Open Reports, 4(2)

Published By: SAGE Publishing

URL: <https://doi.org/10.1177/2055116918813242>



Histologic identification of intraocular *Cytauxzoon felis* in three cats

Jessica Meekins¹ and Ada G Cino-Ozuna²

Journal of Feline Medicine and Surgery
Open Reports
 1–5

© The Author(s) 2018

Article reuse guidelines:

sagepub.com/journals-permissions

DOI: 10.1177/2055116918813242

journals.sagepub.com/home/jfmsopenreports

This paper was handled and processed
 by the American Editorial Office (AAFP)
 for publication in *JFMS Open Reports*



Abstract

Case series summary A 5-month-old male intact domestic shorthair (DSH) cat (cat 1), a 1-year-old male neutered DSH cat (cat 2) and a 1.5-year-old female spayed DSH cat (cat 3) were submitted for gross necropsy after acute death, with the clinical suspicion of cytauxzoonosis. All three cats displayed signs of rapidly progressive clinical deterioration, including lethargy, anorexia, and hyper- or hypothermia. Cat 1 was euthanized owing to the grave prognosis for survival, whereas cats 2 and 3 were found dead 1–4 days after the onset of clinical signs. Remains were submitted to the Kansas State University Veterinary Diagnostic Laboratory for gross necropsy. In all three cats, general examination findings included icterus of the mucous membranes, multifocal pulmonary parenchymal hemorrhages, and splenic reddening and enlargement. Histologic examination revealed macrophages laden with protozoal schizonts diffusely distributed within blood vessels and vascular spaces of all affected organs, including the blood vessels of the uveal tract. The ciliary body within the anterior uveal tract was most affected.

Relevance and novel information This is the first description of cytauxzoonosis affecting the eyes of infected cats. This report confirms involvement of ocular blood vessels similar to the classic lesions of the lungs, spleen and liver. In cats presenting with a history and clinical findings suggestive of cytauxzoonosis, complete ophthalmic examination is indicated to confirm or rule out ocular involvement.

Keywords: *Cytauxzoon felis*; cytauxzoonosis; intraocular; eye; uveitis

Accepted: 18 October 2018

Case series description

Case 1

A 5-month-old intact male domestic shorthair (DSH) cat was evaluated by its veterinarian because of the sudden onset of lethargy and inability to stand. The cat lived outdoors on a rural farm in central Kansas, in a group of 12 cats. Two other cats on the premises were found dead the day prior to presentation. The cat was unvaccinated, and there was no known exposure to toxins or chemicals.

The cat was moribund and hypothermic upon presentation. Results of a complete blood count showed leukopenia (1070 leukocytes/ μ l; reference interval [RI] 5500–18,500 leukocytes/ μ l), with marked neutropenia (240 neutrophils/ μ l; RI 2500–14,000 neutrophils/ μ l) and lymphopenia (760 lymphocytes/ μ l; RI 1500–7000 lymphocytes/ μ l), mild anemia (hematocrit 21.6%; RI 24–45%) and marked thrombocytopenia (1000 platelets/ μ l; RI 300,000–800,000 platelets/ μ l). Serum biochemical

analysis findings included high serum total bilirubin concentration (4.1 mg/dl; RI 0.1–0.6 mg/dl), high serum phosphorus concentration (14.3 mg/dl; RI 3.4–8.5 mg/dl), hypoglycemia (38 mg/dl; RI 70–150 mg/dl) and high blood urea nitrogen (BUN) concentration (95 mg/dl; RI 10–30 mg/dl). Feline immunodeficiency virus

¹Department of Clinical Sciences, College of Veterinary Medicine, Kansas State University, Manhattan, KS, USA

²Department of Diagnostic Medicine/Pathobiology, College of Veterinary Medicine, Kansas State University, Manhattan, KS, USA

Corresponding author:

Jessica Meekins DVM, MS, DACVO, Associate Professor, Ophthalmology, College of Veterinary Medicine, Kansas State University, 1800 Denison Avenue, Mosier Hall, Manhattan, KS 66506, USA

Email: jslack@vet.k-state.edu



Creative Commons Non Commercial CC BY-NC: This article is distributed under the terms of the Creative Commons

Attribution-NonCommercial 4.0 License (<http://www.creativecommons.org/licenses/by-nc/4.0/>) which permits non-commercial use, reproduction and distribution of the work without further permission provided the original work is attributed as specified on the SAGE and Open Access pages (<https://us.sagepub.com/en-us/nam/open-access-at-sage>).

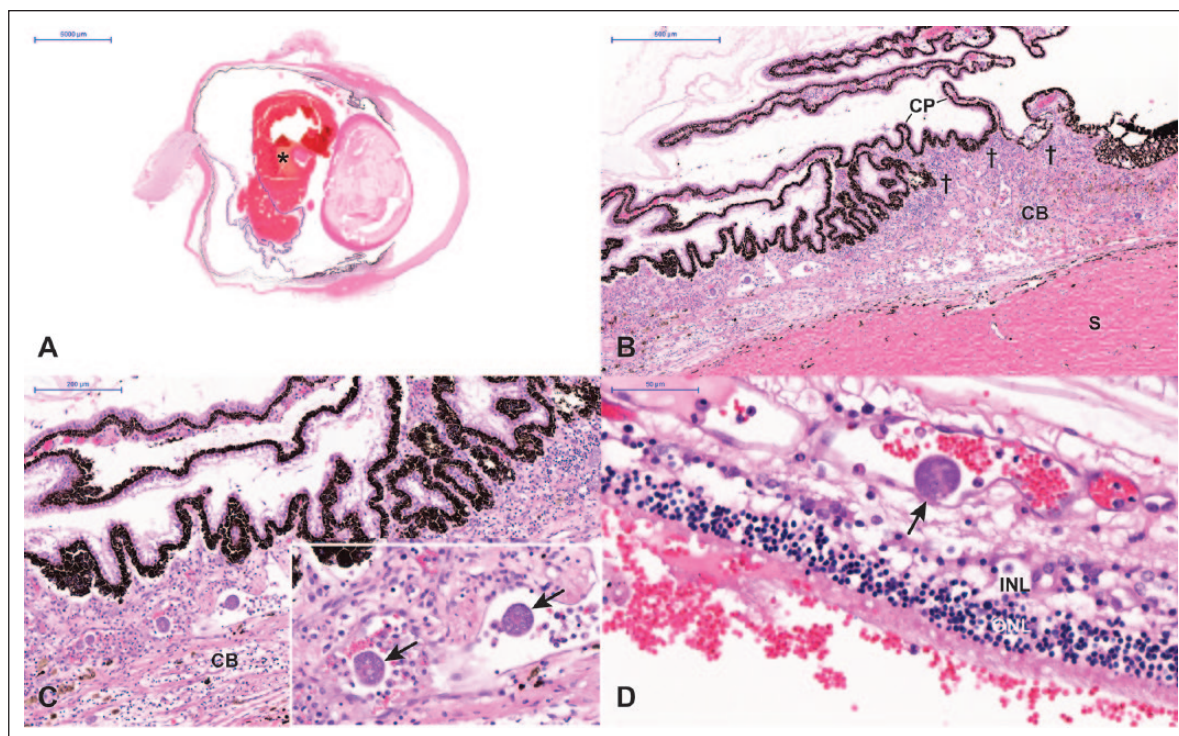


Figure 1 Representative photomicrographs of ocular histopathologic findings in a 5-month-old male intact domestic shorthair cat (cat 1). (a) Sub-gross image of the globe, highlighting vitreal hemorrhage (*) associated with a pathologic retinal detachment. (b) Mixed inflammatory infiltrate affecting the ciliary body and ciliary processes (†). (c) Schizont-laden macrophages (inset, arrows) within ciliary body blood vessels. (d) Schizont-laden macrophage within a retinal blood vessel (arrow). Hematoxylin and eosin

CB = ciliary body; CP = ciliary processes; INL = inner nuclear layer of the retina; ONL = outer nuclear layer of the retina; S = sclera

antibody, feline leukemia antigen and parvovirus antigen testing were negative. Hematology, chemistry and viral testing were performed at the primary care veterinary clinic using point-of-care analyzers and test kits; evaluation of a blood smear was not conducted.

Owing to the grave prognosis for survival, humane euthanasia was performed and the cat was submitted to the Kansas State University Veterinary Diagnostic Laboratory (KSU VDL) for gross necropsy. Gross examination revealed fair body condition and mild post-mortem autolysis. The gingiva, mucous membranes and internal fat stores were diffusely pale to light yellow. Episcleral vessel injection was present in both eyes. The lung lobes had multiple, 3–10 mm diameter parenchymal hemorrhages at the pleural and cut surfaces. The spleen and mesenteric lymph nodes were dark red and enlarged. There were no significant gross lesions in other areas of the body.

Histologic evaluation revealed similar abnormalities in all sampled areas. The pulmonary vessels and alveolar capillaries, mesenteric lymph node cortical and medullary vessels and sinuses, splenic red pulp vessels and sinuses, and the blood vessels and vascular spaces within the brain, liver, heart, pancreas, kidneys and gastrointestinal tract contained large macrophages laden with protozoal schizonts. Macrophages were noted to marginate along vascular endothelium or fill vessel

lumens. Cells contained either multiple, irregularly round, developing schizonts with many large, vesiculate nuclei or mature schizonts with 1–3 μm round, lightly basophilic uninucleate merozoites.

Microscopic evaluation of the eyes demonstrated macrophages laden with schizonts diffusely distributed throughout the uveal tract and within retinal blood vessels (Figure 1). The vitreous humor was expanded by moderate amounts of hemorrhage (Figure 1a). The ciliary body of the anterior uveal tract was the area most heavily infiltrated by schizont-laden macrophages (Figure 1b, c), but protozoal organisms were identified within macrophages in all areas of the uveal tract. The retina was pathologically detached and subretinal hemorrhage was present (Figure 1d). No other ocular lesions were noted.

Gross and microscopic findings were characteristic of cytauxzoonosis due to *Cytauxzoon felis* infection. Infection was additionally confirmed by identifying *C felis* schizonts within macrophages from splenic impression smears.

Case 2

A 1-year-old male neutered DSH cat from southwestern Missouri was evaluated by its veterinarian because of the sudden onset of lethargy and anorexia. Five other cats in the household were reported to have

died of unknown causes over the prior 2 years. The vaccine history for this cat was not provided.

The cat was febrile upon presentation, with a body temperature of 40°C (104°F). Empirical treatment with oral antibiotics and anti-inflammatory medications was initiated, but no diagnostic testing was performed. After an initial period of improvement, the cat deteriorated and died naturally approximately 4 days after the onset of illness. The cat was submitted to KSU VDL for gross necropsy. Gross examination revealed fair body condition and moderate-to-severe post-mortem autolysis. The sclera and visceral adipose tissue were diffusely light yellow. The thoracic cavity and pericardial sac contained moderate amounts of serosanguineous fluid. Approximately 50% of the lung parenchyma had a mottled appearance with multifocal coalescing, irregular, pale and red areas ranging in size from 5–10 mm. The spleen was dark red and enlarged.

Histologic evaluation revealed similar abnormalities in all sampled areas. As reported in cat 1, blood vessels of affected tissues contained large macrophages laden with protozoal schizonts. Microscopic evaluation of the eyes revealed schizont-laden macrophages within the uveal tract and retinal blood vessels, with the ciliary body identified as the most heavily affected area. Vitreal hemorrhage, subretinal hemorrhage and retinal detachment were again noted. Based on these findings, cytauxzoonosis was confirmed as the cause of death.

Case 3

A 1.5-year-old female spayed DSH cat from north-eastern Kansas was submitted to KSU VDL for gross necropsy after sudden death. The cat lived outdoors, and was the sixth cat on the property to die within the previous year. The owner-reported clinical signs included rapid development of anorexia and hindlimb paresis, followed by death within 1–2 days. The cat had been vaccinated for rabies within the previous year, but no other vaccine history was provided.

Gross examination revealed good body condition and mild post-mortem autolysis. The mucous membranes and nictitating membrane conjunctiva were diffusely pale and yellow. The thoracic cavity contained a mild amount of serosanguineous fluid. The lungs were firm and did not collapse upon opening the thorax, and all lung lobes contained multifocal petechial hemorrhages. The spleen was diffusely black.

As reported in cats 1 and 2, histologic evaluation revealed similar abnormalities in all sampled areas, with affected tissues containing large macrophages laden with protozoal schizonts. Microscopic evaluation of the eyes revealed schizont-laden macrophages within the uveal tract and retinal blood vessels, most prominently within the ciliary body. Vitreal hemorrhage, as well as subretinal hemorrhage and retinal detachment, were again identified. Cytauxzoonosis was confirmed as the cause of death.

Discussion

Cytauxzoon felis is a hemoprotozoan parasite transmitted by the bite of an infected tick. Recognized vectors are the American dog tick (*Dermacentor variabilis*) and the lone star tick (*Amblyomma americanum*).^{1–3} Bobcats (*Lynx rufus*) are the natural reservoir host; the infection is thought to be self-limiting in this species, with affected animals developing a carrier state after recovery.^{4,5} *C felis* is an important emerging infectious disease of domestic cats in the USA owing to the severe, often fatal, illness that develops after infection.^{2,6} The disease has not been reported outside wild and domestic felids. The life cycle of *C felis* is complex, and two distinct tissue forms exist: an erythrocyte phase, called a piroplasm, and a tissue phase within macrophages, called a schizont.⁷ The schizont phase is responsible for clinical disease, beginning approximately 2 weeks after a bite from an infected tick.^{1,8} Parasite-laden macrophages rapidly cause partial or total occlusion of blood vessels, leading to vascular obstruction and organ failure.^{9,10}

To our knowledge, this is the first report of cytauxzoonosis with ocular involvement. From the late 1970s, there have been several case series and single case reports of the disease;^{6,9,11–15} however, descriptions of clinically or histologically confirmed ocular lesions do not exist. Reported ophthalmic clinical signs are limited, and generally attributable to non-specific signs of malaise, such as elevated nictitating membranes.^{16,17} Conjunctival hyperemia and episcleral vessel injection have been reported in one cat.¹⁷ Likewise, in our report, cat 1 was noted to have episcleral vessel injection on gross post-mortem examination. Our report is the first to describe schizonts identified within the blood vessels of the uveal tract and retina. Though clinical ophthalmic examination was not possible in these cases, the histologic presence of vitreal hemorrhage, subretinal hemorrhage and retinal detachment indicates that abnormalities would be readily observable with an examination of the ocular fundus.

Given the highly vascular nature of the uveal tract, ocular involvement in cytauxzoonosis is not surprising. Extrapolating from clinical observations in other parts of the body, we speculate that a constellation of clinical signs referable to the anemia, thrombocytopenia and disseminated intravascular coagulation that occur in affected cats would develop in the uveal tract.^{9,12} Specific ocular clinical signs associated with hemorrhagic diathesis due to microvascular obstruction (hemorrhagic panuveitis) would be expected, including hyphema, hemorrhages within the iris stroma, vitreal hemorrhages (histologically identified in this report) and retinal hemorrhages. Hemorrhage of the choroid or subretinal effusion of fluid due to hypoproteinemia could lead to retinal detachment, which was also identified in this report. These examples of ocular lesions can be present in tick-borne infections of dogs, where

diseases such as monocytic ehrlichiosis cause uveitis with intraocular hemorrhage due to coagulopathy, vasculitis or both.^{18,19} Vascular obstruction characteristic of the schizont phase of *C felis* would likely lead to retinal and choroidal ischemia, causing irreversible damage to the neurosensory retina. It is expected that, as in other causes of infectious uveitis, individual cats would exhibit ocular clinical signs of varying magnitude. Cats with cytauxzoonosis can be presented in a significantly obtunded state or experience acute death; therefore, thorough ophthalmic examination may be overlooked or impossible as efforts are focused on supportive therapy. This may explain why no reports of ocular involvement in cytauxzoonosis exist to date; significant ocular clinical signs and blindness may not be easily recognized in a cat with altered mentation and other neurologic deficits. In addition, the time frame and severity of invasion of parasitized macrophages in the uvea is unknown. This may be relevant to the appearance of ocular lesions in affected cats. Future efforts should focus on identifying affected cats and performing complete ophthalmic examinations, so that ante-mortem confirmation of our hypotheses on the ocular lesions of cytauxzoonosis may be confirmed.

Historically, the survival rate for cats infected with *C felis* has been very low, with mortality approaching 100%. In the largest retrospective study of 34 naturally infected cats, the mortality rate was 94%; 32 cats died or were euthanized owing to rapid clinical deterioration.⁹ Despite the guarded prognosis in cases of cytauxzoonosis, there are reports of survivors, as well as asymptomatic carriers.^{13,15,20–22} Efforts are being made to investigate antiprotozoal treatment options to increase survival rates.^{16,23–25} One study reported a successful outcome in five cats treated with diminazene aceturate, an antiprotozoal veterinary drug used for the treatment of babesiosis and trypanosomiasis.²³ The drug was used in conjunction with intensive supportive care and anticoagulant therapy to prevent disseminated intravascular coagulation in that report. In a more recent prospective study, cats treated with a combination of atovaquone and azithromycin were more likely to survive to discharge when compared with cats treated with imidocarb.¹⁶ Sixty percent of cats ($n = 32/53$) receiving the combination protocol survived, while only 26% of cats ($n = 7/27$) receiving imidocarb survived. However, overall mortality rate remained high at approximately 51% (41/80), and other factors, including estimated parasitemia, were considered impactful to prognosis.¹⁶

Identifying differences in *C felis* strain pathogenicity and developing tests to identify various strains,^{20,21,26–28} or vaccines against the protozoan,²⁹ may likewise influence survival. This highlights the importance of documenting the presence of ocular involvement in affected cats. Because of the complications (eg, blindness,

glaucoma, phthisis bulbi) that may be associated with ocular clinical signs of cytauxzoonosis, symptomatic treatment of active uveitis is warranted to increase the quality of life for surviving cats.

Conclusions

This is the first description of cytauxzoonosis affecting the eyes in three infected cats. Based on the known clinical course of disease in other organ systems, the ocular histologic findings in these cases and the well recognized ophthalmic clinical signs present with other tick-borne infectious diseases in small animals, we postulate hemorrhagic panuveitis of varying severity as the most likely clinical presentation in affected cats. Complete ophthalmic examination is warranted in all cases of suspected or confirmed cytauxzoonosis, and *C felis* should be considered as a differential diagnosis for infectious uveitis, especially when external ocular or intraocular hemorrhage is a feature. Prospective gathering of data from clinical ophthalmic examination of affected cats is necessary to confirm the specific ocular manifestations of cytauxzoonosis.

Despite the high mortality rate with this disease, survival is expected to improve with new antiprotozoal and other treatment developments. Identifying and managing ocular manifestations of cytauxzoonosis is important so that the potentially blinding complications that may be associated with ocular involvement can be minimized.

Author note Presented in abstract form at the 47th Annual American College of Veterinary Ophthalmologists' Meeting, Monterey, CA, USA.

Conflict of interest The authors declared no potential conflicts of interest with respect to the research, authorship, and/or publication of this article.

Funding The authors received no financial support for the research, authorship, and/or publication of this article.

References

- 1 Reichard MV, Edwards AC, Meinkoth JH, et al. **Confirmation of *Amblyomma americanum* (Acari: Ixodidae) as a vector for *Cytauxzoon felis* (Piroplasmorida: Theileriidae) to domestic cats.** *J Med Entomol* 2010; 47: 890–896.
- 2 Blouin EF, Kocan AA, Glenn BL, et al. **Transmission of *Cytauxzoon felis* Kier, 1979 from bobcats, *Felis rufus* (Schreber), to domestic cats by *Dermacentor variabilis* (Say).** *J Wildl Dis* 1984; 20: 241–242.
- 3 Shock BC, Murphy SM, Patton LL, et al. **Distribution and prevalence of *Cytauxzoon felis* in bobcats (*Lynx rufus*), the natural reservoir, and other wild felids in thirteen states.** *Vet Parasitol* 2011; 175: 325–330.
- 4 Blouin EF, Kocan AA, Kocan KM, et al. **Evidence of a limited schizogonous cycle for *Cytauxzoon felis* in bobcats following exposure to infected ticks.** *J Wildl Dis* 1987; 23: 499–501.

- 5 Cowell RL, Fox JC, Panciera RJ, et al. **Detection of anticytauxzoon antibodies in cats infected with a *Cytauxzoon* organism from bobcats.** *Vet Parasitol* 1988; 28: 43–52.
- 6 Wagner JE. **A fatal cytauxzoonosis-like disease in cats.** *J Am Vet Med Assoc* 1976; 168: 585–588.
- 7 Meinkoth JH and Kocan AA. **Feline cytauxzoonosis.** *Vet Clin North Am Small Anim Pract* 2005; 35: 89–101.
- 8 Reichard MV, Meinkoth JH, Edwards AC, et al. **Transmission of *Cytauxzoon felis* to a domestic cat by *Amblyomma americanum*.** *Vet Parasitol* 2009; 161: 110–115.
- 9 Birkenheuer AJ, Le JA, Valenzisi AM, et al. ***Cytauxzoon felis* infection in cats in the mid-Atlantic states: 34 cases (1998–2004).** *J Am Vet Med Assoc* 2006; 228: 568–571.
- 10 Jackson CB and Fisher T. **Fatal cytauxzoonosis in a Kentucky cat (*Felis domesticus*).** *Vet Parasitol* 2006; 139: 192–195.
- 11 Glenn BL and Stair EL. **Cytauxzoonosis in domestic cats: report of two cases in Oklahoma, with a review and discussion of the disease.** *J Am Vet Med Assoc* 1984; 184: 822–825.
- 12 Hoover JP, Walker DB and Hedges JD. **Cytauxzoonosis in cats: eight cases (1985–1992).** *J Am Vet Med Assoc* 1994; 205: 455–460.
- 13 Walker DB and Cowell RL. **Survival of a domestic cat with naturally acquired cytauxzoonosis.** *J Am Vet Med Assoc* 1995; 206: 1363–1365.
- 14 Miller J and Davis CD. **Increasing frequency of feline cytauxzoonosis cases diagnosed in western Kentucky from 2001 to 2011.** *Vet Parasitol* 2013; 198: 205–208.
- 15 Meinkoth J, Kocan AA, Whitworth L, et al. **Cats surviving natural infection with *Cytauxzoon felis*: 18 cases (1997–1998).** *J Vet Intern Med* 2000; 14: 521–525.
- 16 Cohn LA, Birkenheuer AJ, Bruncker JD, et al. **Efficacy of atovaquone and azithromycin or imidocarb dipropionate in cats with acute cytauxzoonosis.** *J Vet Intern Med* 2011; 25: 55–60.
- 17 Meier HT and Moore LE. **Feline cytauxzoonosis: a case report and literature review.** *J Am Anim Hosp Assoc* 2000; 36: 493–496.
- 18 Komnenou AA, Mylonakis ME, Kouti V, et al. **Ocular manifestations of natural canine monocytic ehrlichiosis (*Ehrlichia canis*): a retrospective study of 90 cases.** *Vet Ophthalmol* 2007; 10: 137–142.
- 19 Leiva M, Naranjo C and Pena MT. **Ocular signs of canine monocytic ehrlichiosis: a retrospective study in dogs from Barcelona, Spain.** *Vet Ophthalmol* 2005; 8: 387–393.
- 20 Haber MD, Tucker MD, Marr HS, et al. **The detection of *Cytauxzoon felis* in apparently healthy free-roaming cats in the USA.** *Vet Parasitol* 2007; 146: 316–320.
- 21 Brown HM, Latimer KS, Erikson LE, et al. **Detection of persistent *Cytauxzoon felis* infection by polymerase chain reaction in three asymptomatic domestic cats.** *J Vet Diagn Invest* 2008; 20: 485–488.
- 22 Brown HM, Lockhart JM, Latimer KS, et al. **Identification and genetic characterization of *Cytauxzoon felis* in asymptomatic domestic cats and bobcats.** *Vet Parasitol* 2010; 172: 311–316.
- 23 Greene CE, Latimer K, Hopper E, et al. **Administration of diminazene aceturate or imidocarb dipropionate for treatment of cytauxzoonosis in cats.** *J Am Vet Med Assoc* 1999; 215: 497–500.
- 24 Reichard MV, Thomas JE, Arther RG, et al. **Efficacy of an imidacloprid 10%/flumethrin 4.5% collar (Seresto(R), Bayer) for preventing the transmission of *Cytauxzoon felis* to domestic cats by *Amblyomma americanum*.** *Parasitol Res* 2013; 112 Suppl 1: 11–20.
- 25 Motzel SL and Wagner JE. **Treatment of experimentally induced cytauxzoonosis in cats with parvaquone and buparvaquone.** *Vet Parasitol* 1990; 35: 131–138.
- 26 Brown HM, Berghaus RD, Latimer KS, et al. **Genetic variability of *Cytauxzoon felis* from 88 infected domestic cats in Arkansas and Georgia.** *J Vet Diagn Invest* 2009; 21: 59–63.
- 27 Brown HM, Modaresi SM, Cook JL, et al. **Genetic variability of archived *Cytauxzoon felis* histologic specimens from domestic cats in Georgia, 1995–2007.** *J Vet Diagn Invest* 2009; 21: 493–498.
- 28 Shock BC, Birkenheuer AJ, Patton LL, et al. **Variation in the ITS-1 and ITS-2 rRNA genomic regions of *Cytauxzoon felis* from bobcats and pumas in the eastern United States and comparison with sequences from domestic cats.** *Vet Parasitol* 2012; 190: 29–35.
- 29 Tarigo JL, Scholl EH, Mc KBD, et al. **A novel candidate vaccine for cytauxzoonosis inferred from comparative apicomplexan genomics.** *PLoS One* 2013; 8: e71233. DOI: 10.1371/journal.pone.0071233.