



Visceral Gout in a Rough Legged Hawk (*Buteo lagopus*)

Authors: Murnane, Robert D., and Garner, Michael M.

Source: Journal of Wildlife Diseases, 23(3) : 515-517

Published By: Wildlife Disease Association

URL: <https://doi.org/10.7589/0090-3558-23.3.515>

Visceral Gout in a Rough Legged Hawk (*Buteo lagopus*)

Robert D. Murnane and Michael M. Garner, Department of Veterinary Microbiology and Pathology, and Washington Animal Disease Diagnostic Laboratory, Washington State University, Pullman, Washington 99164, USA

ABSTRACT: Visceral gout is reported for the first time in a rough legged hawk (*Buteo lagopus*). Urate crystals were present on the pericardium, thoracic and abdominal air sacs, and the ventral surface of the liver. The liver and spleen also had urate crystals throughout the parenchyma. There was no indication of articular or renal involvement. The immediate cause of death in this hawk was not identified, but appeared to result from multiple factors, including the visceral gout.

Key words: *Buteo lagopus*, rough legged hawk, Falconiformes, visceral gout, case report.

On 7 June 1986, an adult female rough legged hawk (*Buteo lagopus*) was presented to the College of Veterinary Medicine, Washington State University. The bird had been observed flying awkwardly for only short distances at low altitude and was easily captured. Initial radiographic findings included a fracture of the left distal radius and ulna forming a malunion with considerable callus. The wing maintained a 35° varus deformity at the fracture site. The bird was thin, but the results of a complete blood count (CBC) were within normal limits. Surgery to correct the fractured wing was performed on 19 June. Recovery from anesthesia was uneventful. Following surgery, the hawk became anorexic, and regurgitated all food when it was force fed. On 22 June, the hawk was moribund and unresponsive to fluid and corticosteroid treatment. Attempts at resuscitation were unsuccessful.

At necropsy, the fracture of the left wing was well stabilized although an open wound was present at the carpus. The bird was still moderately well muscled despite post-surgical anorexia. Internally, fine white flakes of urate crystals were adherent to the pericardium and completely obscured

the heart (Fig. 1). The urates extended into the pericardial sac, and less dense deposits were observed on thoracic air sacs, the ventral surface of the liver and cranial abdominal air sacs. The liver and spleen had diffusely scattered pinpoint white foci on their surfaces and throughout their parenchyma. Immediately inside the thoracic inlet on the right was a 10 × 5 × 2 mm firm green foreign body. The mass was loosely attached to surrounding structures and unassociated with significant exudate. All other organ systems including kidneys, ureters, and the musculoskeletal system were grossly normal. Body fat was considered adequate.

Histologically, the liver and spleen had 30–200 µm radiating, stellate, lightly basophilic, crystals throughout (Fig. 2). Parenchymal tissue surrounding these foci had some pyknotic and degenerating cells plus an occasional macrophage or lymphocyte, but no other inflammatory infiltrate. A section of liver transferred from 10% buffered formalin to 100% ethanol and stained by DeGalantha's method (DeGalantha, 1935) was multifocally positive for urate crystals. Urate crystals are soluble in formalin. Thus, the stain was only multifocally positive and crystals were not visible on surfaces of the heart or liver after routine processing. A few scattered degenerated renal tubules had basophilic birefringent mineralized material within lumina, but the remainder of the kidneys were histologically normal.

The thoracic foreign body consisted of a large central area of hemorrhage surrounded by a thin layer of histiocytes and small lymphoid aggregates. Numerous small pieces of plant material were present

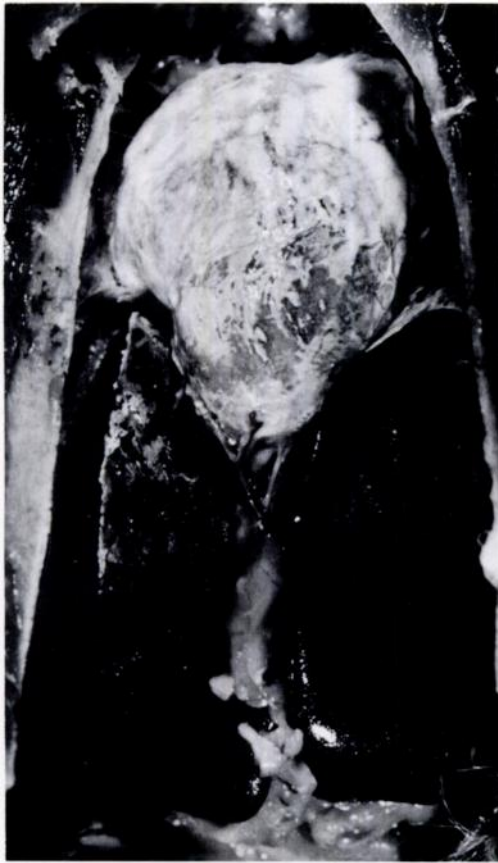

FIGURE 1. White, adherent, flake-like urate crystals on pericardium, air sacs and surface of liver. Note diffuse pinpoint white foci on liver.

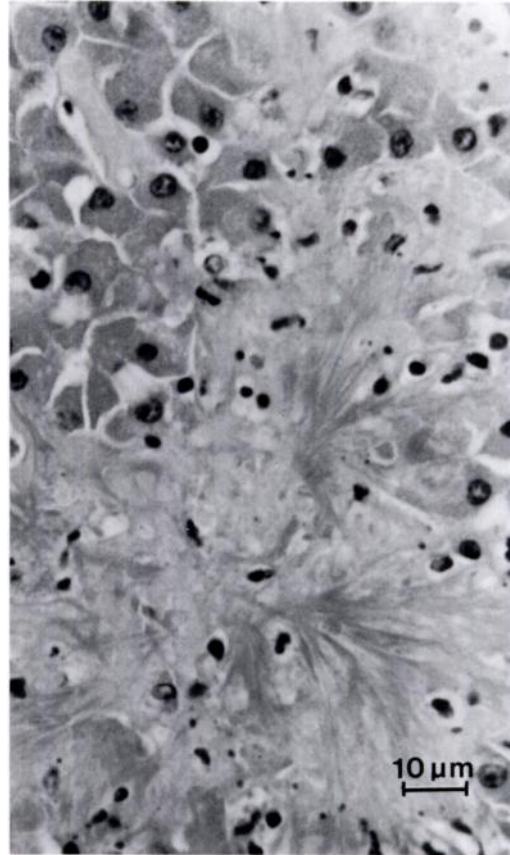


FIGURE 2. Radiating stellate urate crystals in liver parenchyma. Hematoxylin and eosin.

at the periphery of the hemorrhage. This old foreign body granuloma was apparently only an incidental finding. A section of pectoral muscle had a 3×7 mm area of swollen and vacuolated myocytes with intercellular edema and a moderate heterophilic and mononuclear infiltrate consistent with a diagnosis of capture myositis.

Visceral gout is described in a Cooper's hawk (*Accipiter cooperii*) (Ward and Slaughter, 1968). Other authors claim that it is common in birds of prey (Cooper, 1978; Halliwell, 1978), but specific cases are not cited. The association of visceral gout with articular gout is unclear, and they may occur together or independently (Knox, 1980; Hasholt and Petrak, 1982).

Visceral gout is most often associated with severe renal urate deposits (Arnall and Keymer, 1975; Halliwell, 1978; Knox, 1980; Jones and Hunt, 1983), but as indicated in the present case, this is not a ubiquitous finding (Siller, 1959; Hasholt and Petrak, 1982).

The etiology of visceral gout is obscure. Proposed causes, based upon studies in chickens, include hypovitaminosis A, excessive dietary protein or imbalanced dietary amino acids, renal disease, and stress (Siller, 1959; Ward and Slaughter, 1968; Arnall and Keymer, 1975; Bush and Montali, 1977; Halliwell, 1978; Knox, 1980; Hasholt and Petrak, 1982; Jones and Hunt, 1983). If present, clinical signs are usually nonspecific unless there is severe renal in-

involvement and there are signs attributable to renal failure (Siller, 1959; Arnall and Keymer, 1975; Cooper, 1978; Halliwell, 1978; Knox, 1980; Hasholt and Petrak, 1982; Jones and Hunt, 1983). The significance of visceral gout is unclear; some authors report that it is fatal (Siller, 1959; Arnall and Keymer, 1975) whereas others believe that it may or may not cause clinical signs (Halliwell, 1978; Hasholt and Petrak, 1982).

In the present case, the kidneys appeared normal. The hawk was not starving based upon the amount of body fat, the lack of severe pectoral muscle atrophy and the normal CBC. We feel that the extent of urate deposition was enough to cause partial dysfunction of the spleen and liver. Death was probably due to a combination of wing fracture, visceral gout, myositis, surgical stress, postsurgical depression and anorexia. Visceral urate deposition was considered a primary event without renal involvement in this hawk.

The authors wish to extend sincere thanks to Charles W. Leathers and David J. Prieur for review of the manuscript, and Vicki Herrington and the Washington Animal Disease Diagnostic Histology Laboratory for technical assistance.

LITERATURE CITED

- ARNALL, L., AND I. F. KEYMER. 1975. Bird diseases. T.F.H. Publications Inc., Neptune City, New Jersey, pp. 261-263.
- BUSH, M., AND R. J. MONTALI. 1977. Principles of zoological animal medicine. *Veterinary Scope* 21: 9-23.
- COOPER, J. E. 1978. Veterinary aspects of captive birds of prey. Standfast Press, Saul, Gloucestershire, England, pp. 131, 166.
- DEGALANTHA, E. 1935. Silver stain for urates. *American Journal of Clinical Pathology* 5: 165-166.
- HALLIWELL, W. H. 1978. Toxic and metabolic conditions in birds of prey. In *Zoo and wild animal medicine*, M. E. Fowler (ed.). W. B. Saunders Co., Philadelphia, Pennsylvania, pp. 283-284.
- HASHOLT, J., AND M. L. PETRAK. 1982. Gout. In *Diseases of cage and aviary birds*, M. L. Petrak (ed.), 2nd ed. Lea and Febiger, Philadelphia, Pennsylvania, pp. 639-645.
- JONES, T. C., AND R. D. HUNT. 1983. Veterinary pathology, 5th ed. Lea and Febiger, Philadelphia, Pennsylvania, pp. 70-72.
- KNOX, D. W. 1980. Gout in reptiles and birds, with observations on a comparable syndrome in man. In *The comparative pathology of zoo animals*, R. J. Montali and G. Migaki (eds.). Smithsonian Institution Press, Washington, D.C., pp. 137-141.
- SILLER, W. G. 1959. Avian nephritis and visceral gout. *Laboratory Investigation* 8: 1304-1318.
- WARD, F. P., AND L. J. SLAUGHTER. 1968. Visceral gout in a captive Cooper's hawk. *Bulletin of the Wildlife Disease Association* 4: 91-93.

Received for publication 6 October 1986.