



Fatal Neonatal Toxoplasmosis in a Bobcat (*Lynx rufus*)

Authors: Dubey, J. P., Quinn, W. J., and Weinandy, D.

Source: Journal of Wildlife Diseases, 23(2) : 324-327

Published By: Wildlife Disease Association

URL: <https://doi.org/10.7589/0090-3558-23.2.324>

Fatal Neonatal Toxoplasmosis in a Bobcat (*Lynx rufus*)

J. P. Dubey, Protozoan Diseases Laboratory, Animal Parasitology Institute, U.S. Department of Agriculture, Agricultural Research Service, Beltsville, Maryland 20705, USA; **W. J. Quinn**, The Diagnostic Laboratory, Box 997, Department of Livestock-Animal Health Division, State of Montana, Bozeman, Montana 59771, USA; and **D. Weinandy**, Mission Valley Veterinary Clinic, P.O. Box 158, Ronan, Montana 59864, USA

ABSTRACT: *Toxoplasma gondii* was found in tissues of a captive 1-week-old bobcat (*Lynx rufus*) that died of myocarditis, hepatitis and encephalitis. Although infection is common in wild Felidae, clinical toxoplasmosis is rarely seen. In this case, the infection was apparently congenitally acquired.

Key words: Toxoplasmosis, *Toxoplasma gondii*, bobcat, *Lynx rufus*, congenital infection.

Toxoplasma gondii is one of the most common parasites of warm blooded animals. Felidae, both domestic and wild, are pivotal in the epidemiology of toxoplasmosis because they are the only hosts capable of shedding oocysts (Miller et al., 1972). The bobcat (*Lynx rufus*) is also known to shed *T. gondii* oocysts (Miller et al., 1972). Although *T. gondii* antibody has been found in sera of bobcats, there is no published report of clinical toxoplasmosis in this host (Dubey, 1986). Herein, we report a fatal case of toxoplasmosis in a newborn bobcat.

On 31 July 1985, the carcass of a 1-wk-old male bobcat was submitted to the Diagnostic Laboratory, Montana Department of Livestock, at Bozeman for diagnosis. Grossly, the lungs were diffusely dark red and edematous. The stomach was distended with milk curd. Other lesions were not found.

Portions of brain, lung, kidney, small and large intestines, liver, spleen, and heart were fixed in 10% buffered neutral formalin, embedded in paraffin, sectioned at 5 μ m, and stained with hematoxylin and eosin (H&E) or periodic acid Schiff (PAS) and hematoxylin.

Microscopically, the most severe lesions

were seen in the liver (Fig. 1), heart (Fig. 2), and brain (Fig. 3). Multifocal hepatic necrosis involving approximately one-third of the liver was noted. These necrotic foci were randomly distributed in hepatic lobules and were characterized by hepatocytes with intensely eosinophilic cytoplasm and loss of nuclei. The portal areas were infiltrated by lymphocytes and neutrophils. A few tachyzoites were seen in hepatocytes (Fig. 1). There were multiple foci of necrosis and inflammation in the heart. These foci contained both lymphocytes and neutrophils. Several groups of tachyzoites were seen within myocardial fibers, not necessarily within the areas of lesions. Zoites in myocardial fibers stained specifically for *T. gondii* antibody by the peroxidase-antiperoxidase method (Conley et al., 1981). Multiple foci of gliosis were scattered throughout the sections of cerebrum, cerebellum and the medulla oblongata. Several *T. gondii* cysts were seen in the cerebellum (Fig. 3).

Mild lesions were observed in sections of lungs and spleen. The pulmonary alveoli contained moderate amounts of blood, small aggregates of fibrin and swollen macrophages. A few tachyzoites were observed in the lesions. A few small necrotic foci were noted in the spleen.

The lesions described above were from one of three kittens (second litter) born in captivity in a 2-yr-old female (No. 1). Its two litter mates had also died during the first week after birth, but they were not necropsied. The female had previously given birth to a litter of three; two of which had died the day of birth, but they were

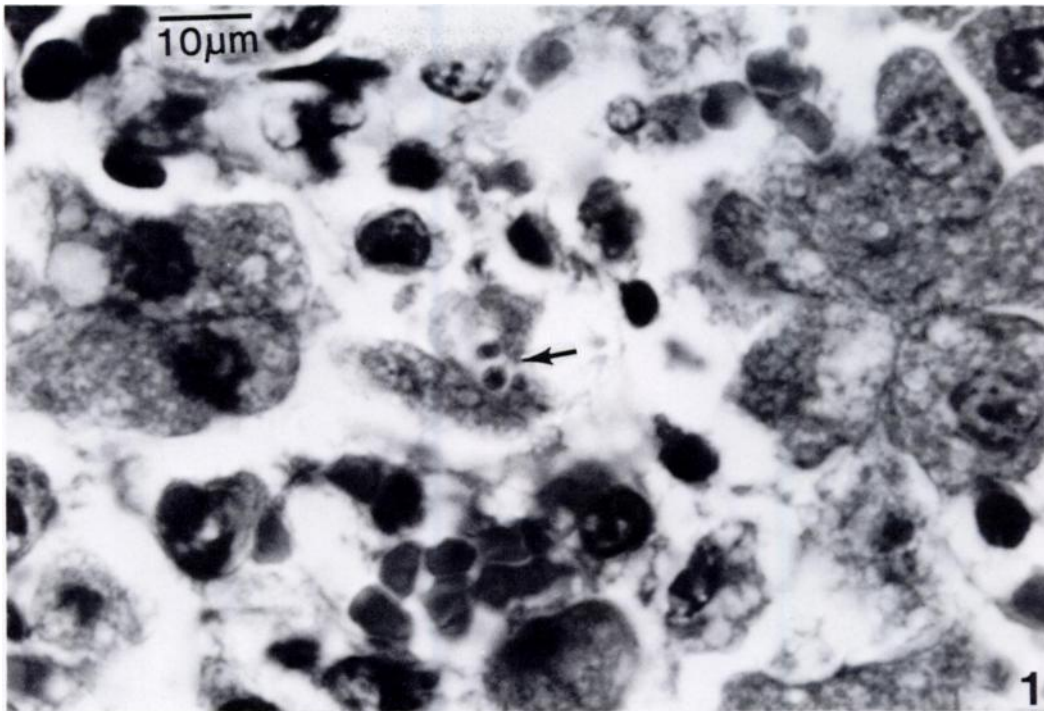


FIGURE 1. Newborn bobcat's liver with two *T. gondii* tachyzoites within an hepatocyte (arrow). H&E.



FIGURE 2. Myocardium of bobcat showing necrosis of myocardial fibers, infiltrations of leukocytes, and a group of *T. gondii* tachyzoites (arrow). H&E. Inset shows a group of tachyzoites within a myofiber. H&E.

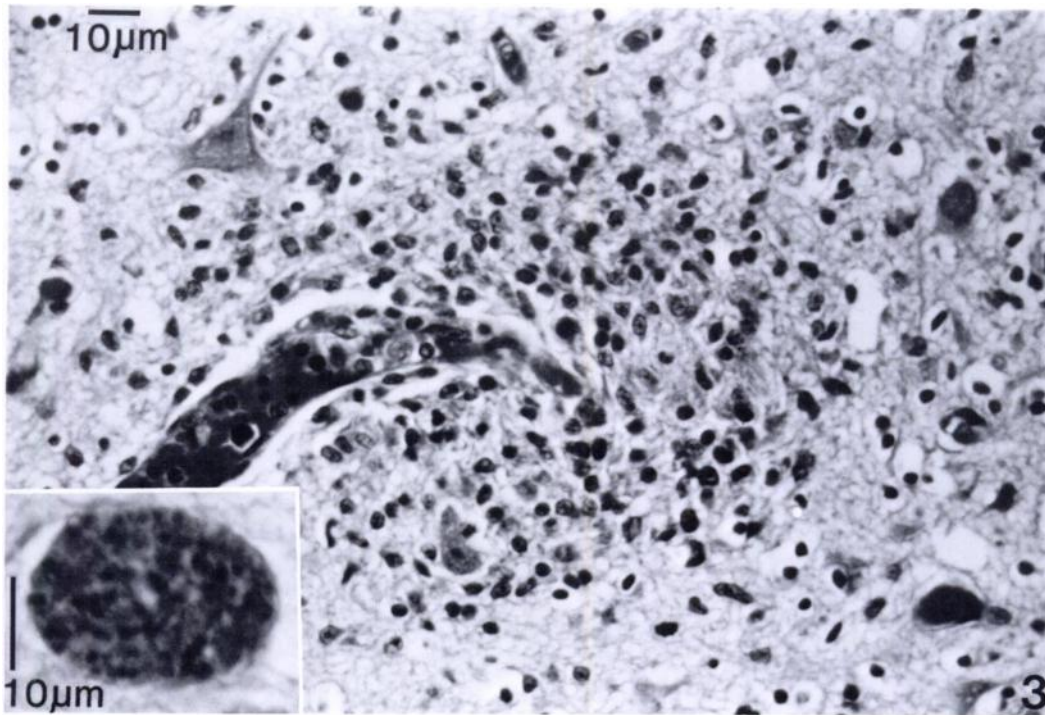


FIGURE 3. Medulla oblongata of bobcat showing perivascular gliosis. H&E. Inset shows a *T. gondii* tissue cyst. H&E.

not necropsied. The third kitten (No. 4 from the first litter) was removed on the day of birth and was bottle fed.

The female bobcat was from a farm in Ronan, Montana. The farmer has 30 other bobcats, a few mountain lions (*Felis concolor*) and numerous domestic mink. The bobcats were raised for pelts and for sale to other farmers. The bobcats were housed in wire pens, raised about 0.5 m from the ground and were given a diet of mink ration, 65% of diet (degutted chickens, ocean fish and cereal), and horsemeat. The horsemeat (unfrozen or frozen) constituted about 35% of the diet. The mink were housed in a separate building and were clinically normal. The female bobcat probably acquired *T. gondii* infection by ingesting horsemeat and chickens since *T. gondii* tissue cysts have been found in horsemeat (Al-Khalidi and Dubey, 1979; Dubey, 1985) and chickens (Jacobs and Melton, 1966).

In January 1986, blood samples were obtained from four bobcats at the owner's farm. These samples were from the female (No. 1), surviving kitten (No. 4, 4-yr-old), and two other at random (No. 2, male 18-yr-old; No. 3, female 3-yr-old). Serum samples were examined for *T. gondii* antibody at the Animal Parasitology Institute, Beltsville, Maryland using the microagglutination test (Dubey and Desmonts, 1987). *Toxoplasma gondii* antibody titers of the bobcats were 1:16 (No. 1 and 4), 1:25,600 (No. 2) and 1:256 (No. 3). From the serologic data it is not possible to judge either the source of infection or the duration of infection in any of the bobcats.

Although *T. gondii* infection is common in domestic and wild Felidae (Dubey, 1986) clinical toxoplasmosis is rarely seen. The most severe form of toxoplasmosis in Felidae was reported in congenitally infected kittens born to a domestic cat (Dub-

ey and Johnstone, 1982). The age of the bobcat, the widespread lesions and the findings of well developed tissue cysts in the brain suggest the bobcat was congenitally infected.

The authors thank Dr. F. K. Conley, Stanford University Medical Center, Stanford, California for performing the immunohistochemical staining for *T. gondii*.

LITERATURE CITED

- AL-KHALIDI, N. W., AND J. P. DUBEY. 1979. Prevalence of *Toxoplasma gondii* infection in horses. *The Journal of Parasitology* 65: 331-334.
- CONLEY, F. K., K. A. JENKINS, AND J. S. REMINGTON. 1981. *Toxoplasma gondii* infection of the central nervous system. Use of the peroxidase-anti-peroxidase method to demonstrate *Toxoplasma* in formalin fixed, paraffin embedded tissue sections. *Human Pathology* 58: 690-698.
- DUBEY, J. P. 1985. Persistence of encysted *Toxoplasma gondii* in equids fed oocysts. *American Journal of Veterinary Research* 46: 1753-1754.
- . 1986. Toxoplasmosis in cats. *Feline Practice* 16: 12-26, 44-45.
- , AND G. DESMONTS. 1987. Serological responses of equids fed *Toxoplasma gondii* oocysts. *Equine Veterinary Journal*. In press.
- , AND I. JOHNSTONE. 1982. Fatal neonatal toxoplasmosis in cats. *Journal of American Animal Hospital Association* 18: 671-678.
- JACOBS, L., AND M. L. MELTON. 1966. Toxoplasmosis in chickens. *The Journal of Parasitology* 52: 1158-1162.
- MILLER, N. L., J. K. FRENKEL, AND J. P. DUBEY. 1972. Oral infections with *Toxoplasma* cysts and oocysts in felines, other mammals, and in birds. *The Journal of Parasitology* 58: 928-937.

Received for publication 11 August 1986.