



Bacterial Endocarditis in Opossums 1

Authors: LaPLANTE, E. S., and BURRELL, R. G.

Source: Bulletin of the Wildlife Disease Association, 2(1) : 10-12

Published By: Wildlife Disease Association

URL: <https://doi.org/10.7589/0090-3558-2.1.10>

Bacterial Endocarditis in Opossums¹

E. S. LaPLANTE AND R. G. BURRELL

*Departments of Surgery and Microbiology,
West Virginia University, School of Medicine,
Morgantown, West Virginia*

Received for publication 13 September 1965

In recent years the opossum (*Didelphys virginiana*) has become more widely employed as a research animal partly because of their unique gestational period. Only 13 days of intrauterine development are required before birth. The succeeding eight weeks of extrauterine development in the marsupial pouch permits extended observations and even manipulations of what are essentially embryos. Opossums have been used recently for the study of caloric intake regulation (Maller *et al.*, 1965, Proc. Soc. Exp. Biol. and Med. 118: 275 - 277), of feigned sleep or "playing 'possum" (Norton *et al.*, 1964, Nature 204: 162 - 163), and for antibody production in embryos (Kalmutz, 1962, Nature, 193: 851 - 853 and La Via *et al.*, 1963, Science, 140: 1219 - 1220).

Our laboratories have been obtaining and raising opossums for the study of acquired immunologic tolerance. Although methods of care and prevention of disease in these animals have been published (Moore and Bodian, 1940, Anat. Rec., 76: 319 - 327 and Krupp

and Quillin, 1964, Laboratory Animal Care, 14: 189 - 194), we have encountered certain problems which apparently have not been reported previously.

Over 60 opossums have been studied for periods ranging from one week to seven months duration. Occasionally an animal died from unexpected causes not associated with the experimental procedure. In ten such deaths a thorough necropsy indicated that three died from bacterial endocarditis, one from pyelonephritis, three from peritonitis due to perforated intestine, and three from unknown causes.

Since the incidence of bacterial endocarditis appeared unusually high, this disease was studied in greater detail. One case, animal number 12, which was examined within an hour following death, had a marked degree of pulmonary edema. The heart contained an extensive verrucous lesion, "off-white" in color and very firm in consistency, which involved the mitral valve (Figure 1). The mitral valve orifice was reduced to a fraction of the normal cross sec-

¹This investigation was supported by a National Institute of Health General Research Support Grant 5 S01 FR-5433-04.

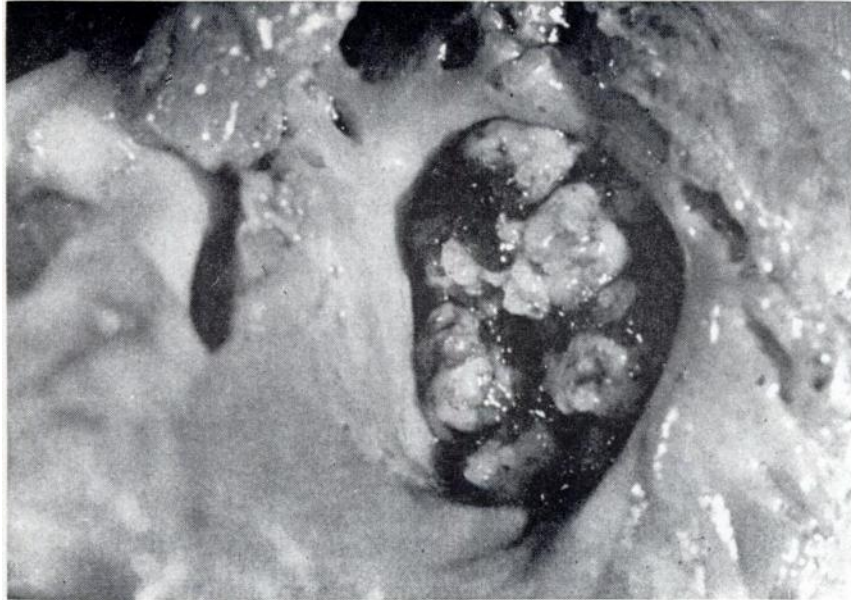

Figure 1. *Mitral valve showing typical vegetative lesion of subacute bacterial endocarditis.*

tional area due to the extensive involvement of the valve leaflets. The annulus and immediately adjacent valvular tissue was grossly free of pathology.

Microscopic examination of tissue sections, stained with hematoxylin and eosin, confirmed the impressions suggested by the gross appearance. The pulmonary alveoli contained large quantities of light pink staining material—compatible with edema fluid, while the mitral valve showed bacteria-laden vegetations with enmeshed strands of fibrin (Figure 2). The vegetations were wide based and involved both

surfaces of the leaflet. Scattered acute and chronic inflammatory cells were located within the substance of the leaflets and annulus. The pathology of the other two animals showed similar changes although not as extensive.

Material from the vegetative lesion from this case, was cultured on rabbit blood agar medium. Within 48 hours at 37° C, numerous colonies of alpha hemolytic *Streptococcus viridans* were noted. The organism's morphology was confirmed microscopically not only from isolated colonies, but also by direct smear from the lesion.

DISCUSSION AND CONCLUSIONS

Although all of these animals were in captivity at the time of death, they had all been captured as adults from the wild. Therefore, it is assumed that the conditions described here represent natural diseases. At first the diet of these animals consisted of canned dog meat, fruits, eggs and healthy laboratory rats that were sacrificed for this purpose. The latter served as a source of calcium from bones. It was believed that the perforated intestines and the subsequent peritonitis resulted from small punctures made by these bones. Currently, the dead rats have been

replaced by bone meal and no deaths from this cause have occurred since this substitution.

The unusual incidence of bacterial endocarditis was of particular interest. An unresolved question concerning the predisposing cause to this condition was whether the endocarditis was related to previously damaged or congenitally abnormal heart tissues, or to a unique anatomic feature of the opossum heart. Since the condition appeared to be common in the animals that we examined, it is suggested that the opossum might serve as an experimental model for the study of bacterial endocarditis.

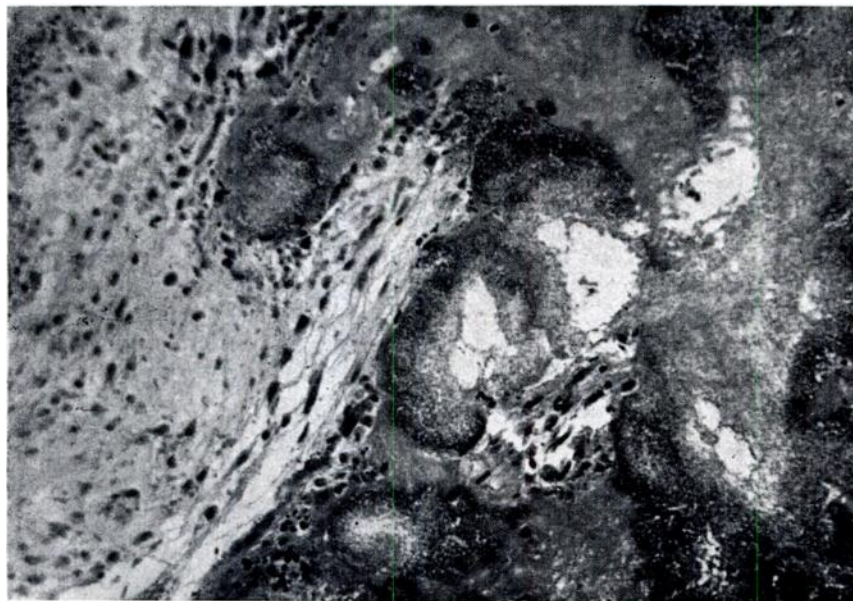


Figure 2. *Hematoxylin and eosin preparation of lesion shown in Figure 1. Note numerous cocci enmeshed in fibrin.*