



Mycobacterium avium SEROTYPE 1 INFECTION IN A SANDHILL CRANE (*Grus canadensis*)

Authors: THOEN, CHARLES O., HIMES, ELMER M., and BARRETT, RICHARD E.

Source: Journal of Wildlife Diseases, 13(1) : 40-42

Published By: Wildlife Disease Association

URL: <https://doi.org/10.7589/0090-3558-13.1.40>

Mycobacterium avium SEROTYPE 1 INFECTION IN A SANDHILL CRANE (*Grus canadensis*)

CHARLES O. THOEN, ELMER M. HIMES and RICHARD E. BARRETT,
United States Department of Agriculture, Animal and Plant Health Inspection Services,
Veterinary Services, P.O. Box 70, Ames, Iowa 50010, USA

Abstract: Tuberculous lesions were observed in the liver of an adult sandhill crane (*Grus canadensis*); *Mycobacterium avium* serotype 1 was isolated. Chickens inoculated intravenously with the culture had granulomas in the liver and spleen at necropsy 62 days after inoculation.

INTRODUCTION

Tuberculosis has been reported in certain free-flying birds in the United States and other countries.^{1-5,10} The importance of these wild birds in the transmission of *Mycobacterium avium* to nonhuman primates, domestic animals and man has been discussed;^{1,9,15} however, no definitive studies have been made to elucidate the role of birds in the spread of avian tuberculosis.

This report describes histopathologic and mycobacteriologic examinations on tissues of a sandhill crane (*Grus canadensis*) from which *M. avium* serotype 1 was isolated and the pathogenicity of this microorganism for chickens.

CASE REPORT

An adult sandhill crane was killed during open hunting season in September, 1973, near Palmer, Alaska. Grossly visible tuberculosis-like lesions measuring up to 1 cm were observed in the liver. Liver specimens from the crane were collected in 10% formalin and in saturated sodium borate solution. Paraffin sections of formalin-fixed tissue were stained with hematoxylin and eosin for histopathologic examination.

Microscopically, the granulomas contained caseous necrotic centers encapsulated by a thick wall of fibrous connective tissue with monocytes and epitheli-

oid cells (Figure 1). A zone of epithelioid cells and vacuolar structures, some with clear yellow fluid that appeared to be lipid droplets, was within the fibrous capsule and approximately the same thickness as the capsule. Numerous microscopic granulomas were observed surrounding or adjacent to the larger tubercles.

Mycobacteriologic examination was made of the liver collected in sodium borate. The tissue was treated with 2% NaOH and media were inoculated as described previously.¹⁶ Inoculated cultures were incubated at 37 C and observed for growth at weekly intervals for 8 weeks. Nonchromogenic slowly-growing acid-fast bacilli were isolated and subsequently were identified as *M. avium* serotype 1.^{9,16}

Pathogenicity tests were made in each of four 12-week-old, tuberculin-negative, white leghorn-cross pullets. The inoculum was prepared from a 10-day subculture of the *M. avium* serotype 1 in Dubos liquid medium with oleic acid complex. The cells were harvested by centrifugation at 1200 x g for 20 min, weighed and suspended in Butterfield's buffer (pH 7.2). Four chickens were inoculated intravenously; two were each given 0.01 mg (wet wgt) and two others were each given 0.1 mg of the inoculum. Tuberculin tests were made 60 days after inoculation using 0.05 ml avian OT[®] intra-

® Avian Old Tuberculin, US Department of Agriculture, Ames, Iowa.

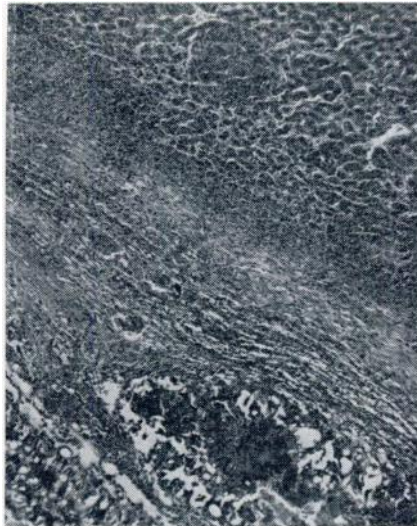


FIGURE 1. Section of liver with tuberculous granulomas from a sandhill crane. A portion of fibrous connective tissue capsule with monocytes and epithelioid cells is shown. Hematoxylin and eosin 100 X.

dermally in the left wattle; positive responses (induration) were observed at 48 hr. The chickens were killed 62 days after inoculation; grossly visible lesions (1-2 mm in diameter) were observed in the liver and spleen of each of the four chickens. Microscopic examination of sections of liver and spleen stained with hematoxylin and eosin revealed the presence of well-defined focal granulomas. Replicate sections were stained with auramine-O;⁹ numerous acid-fast bacilli were seen in the granulomas.

DISCUSSION

Tuberculosis in a sandhill crane provides some evidence that this migratory bird may be of epizootologic importance

Acknowledgment

The authors acknowledge the technical assistance of the Mycobacteriology and General Pathology Staffs, Veterinary Services Laboratories, APHIS, U.S. Department of Agriculture.

in the transmission of *M. avium* serotype 1 infections to chickens, cattle and swine. In one state, South Dakota, *M. avium* serotype 1 was more commonly isolated from tuberculous swine than was *M. avium* serotype 2.⁸ Some flyways of migratory birds are in the midwestern area of the country as are the resting grounds for these birds during their movements in the spring and fall.

Serologic identification of *M. avium* is important in obtaining information on the epidemiology of avian tuberculosis in wild birds.⁹ In a study of ducks in a wild fowl reserve in England, *M. avium* serotype 1 was isolated, whereas in chickens and other birds, serotype 2 was more frequently found.¹⁰ Further studies are needed on other migratory birds to determine the prevalence of tuberculosis in these waterfowl and other species.

The economic importance of *M. avium* serotype 1 infections in exotic birds maintained in zoos has been emphasized.⁷ No information is available on the prevalence of tuberculosis in migratory birds in the United States; however, if resting grounds are contaminated, the disease may be widespread because the organisms are relatively resistant to environmental conditions.^{11,14}

Recently *M. avium* serotype 3 was isolated from a white-headed tree duck being imported into the United States from Africa.¹² This serotype has not been reported for native or migratory wild birds in the United States; it should be emphasized that reports on tuberculosis in free-flying birds have not included serologic identification on the acid-fast isolates. The development of a simplified test using microtiter plates provides a rapid method for serotyping *M. avium* isolates.¹³ This accurate and inexpensive procedure may be readily conducted in most clinical microbiology laboratories.

LITERATURE CITED

1. BICKFORD, A. A., G. H. ELLIS and H. E. MOSES. 1966. Epizootiology of tuberculosis in starlings. *J. Am. vet. med. Ass.* 149: 312-318.
2. CHALQUEST, R. R. and T. MATSUOKA. 1962. Tuberculosis in a wild duck. *Wildl. Dis.* 25: 3.
3. COOPER, J. E., L. KARSTAD and E. BOUGHTON. 1975. Tuberculosis in lesser flamingos in Kenya. *J. Wildl. Dis.* 11: 32-36.
4. FELDMAN, W. H. 1938. *Avian Tuberculosis Infections*. Williams and Wilkins Co., Baltimore, Maryland.
5. KARLSON, A. G. 1975. Tuberculosis In: *Isolation of Avian Pathogens*. pp. 99-108. S. B. Hitchner, C. H. Dommermuth, H. G. Purchase and J. E. Williams (Eds.) *Am. Ass. Avian Pathologists*. Texas A & M University, College Station, Texas.
6. MITCHELL, M. D., I. H. HUFF, C. O. THOEN, E. M. HIMES and J. W. HOWDER. 1975. Swine tuberculosis in South Dakota. *J. Am. vet. med. Ass.* 167: 152-153.
7. MONTALI, R. J., M. BUSH, C. O. THOEN and E. SMITH. 1976. *Mycobacterium avium* serotype 1 infection in captive exotic birds. *J. Am. vet. med. Ass.* 269: 920-927.
8. MOTE, R. F., R. L. MUHM and D. C. GIGSTAD. 1975. A staining method using acridine orange and auramine-0 for fungi and mycobacteria in bovine tissue. *Stain Tech.* 50: 5-9.
9. SCHAEFER, W. B. 1967. Serologic identification of the atypical mycobacteria and its value in epidemiologic studies. *Am. Rev. Respirat. Dis.* 96: 115-118.
10. ———, J. V. BEER, N. A. WOOD, E. BOUGHTON, P. A. JENKINS and J. MARKS. 1973. A bacteriological study of endemic tuberculosis in birds. *J. Hyg. Camb.* 71: 549-557.
11. SCHLIESSER, T. and A. WEBER. 1973. Untersuchungen uber die Tenazität von Mykobakterien der Gruppe III nach in Sagemehleinstreu. *Zentr. Veterinaermed B* 20: 710-714.
12. THOEN, C. O., E. M. HIMES and J. H. CAMPBELL. 1976. Isolation of *Mycobacterium avium* serotype 3 from a white-headed tree duck. *Avian Dis.* 20: 587-592.
13. ———, J. L. JARNAGIN and M. L. CHAMPION. 1975. Micromethod for serotyping strains of *Mycobacterium avium*. *J. Clin. Microbiol.* 1: 469-471.
14. ——— and A. G. KARLSON. 1975. Tuberculosis In: *Diseases of Swine*, Fourth Edition, H. W. Dunne and A. D. Leman (Eds.) pp. 712-729. Iowa State Univ. Press, Ames, Iowa.
15. ———. 1978. The Genus *Mycobacterium* In: *Veterinary Microbiology*, Eighth Edition, R. A. Packer, C. J. Mare and I. A. Merchant (Eds.) Iowa State Univ. Press, Ames, Iowa (In Press).
16. USDA, APHIS, Veterinary Services Laboratories. 1974. *Laboratory Methods in Veterinary Mycobacteriology*, Revised Edition, Ames, Iowa.

Received for publication 24 May 1976