



---

## **Revisions of Anatomical Descriptions of the Pharyngeal Jaw Apparatus in Moray Eels of the Family Muraenidae (Teleostei: Anguilliformes)**

Author: Johnson, G. David

Source: Copeia, 107(2) : 341-357

Published By: The American Society of Ichthyologists and Herpetologists

URL: <https://doi.org/10.1643/CI-19-211>

# Revisions of Anatomical Descriptions of the Pharyngeal Jaw Apparatus in Moray Eels of the Family Muraenidae (Teleostei: Anguilliformes)

G. David Johnson<sup>1</sup>

**Fishes of the family Muraenidae (moray eels) comprise two subfamilies of highly specialized benthic forms. As first documented and described in two earlier papers, morays have a highly specialized raptorial feeding apparatus in which they move their upper pharyngeal jaws forward into the oral cavity to grasp prey and transport it back into the esophagus. Here I revisit the descriptive aspects of the second paper and compare them to my own investigations of the topographic anatomy of this apparatus. Regrettably, my observations of the relevant anatomical details and terminology differ markedly from those presented in that paper. Accordingly, I describe and illustrate my observations, compare them to previous descriptions, and discuss possible functional implications. In contrast to the earlier paper, I offer detailed argumentation and justification for my terminology and identification of relevant gill-arch muscles in muraenids. Based on my re-interpretation of the topographic anatomy of the pharyngeal musculature, three conspicuously different anatomical mechanisms of pharyngeal jaw protrusion and retraction are identified.**

*The original muscle terminology used in earlier descriptions of the origination and insertion sites of the muscles thought to move the pharyngeal jaws in morays has generated much confusion.*

—Mehta and Wainwright (2008: 614)

*In morphology there is no such thing as insignificant detail; each observation, no matter how trifling, may carry the germ of an explanation for others of much greater consequence.*

—Emile Baudelot (1868: 84, translated from the French)

**T**HE basal teleost clade Elopomorpha contains a diversity of forms ranging from generalized, silvery, strongly scaled fishes such as tarpons and ladyfishes to very elongate fishes with relatively smooth skin. Although monophyly of this clade has sometimes been questioned (e.g., Filleul and Lavoué, 2001), the presence of a leptocephalus, i.e., a highly specialized larval form with many unique features (Hulet, 1978; Smith, 1984), convincingly corroborates it. Monophyly has also been suggested based on molecular studies (most recently reviewed in Betancur-R et al., 2017). The largest elopomorph order, Anguilliformes (true eels), comprises over 975 species in 20 families and approximately 156 genera (Fricke et al., 2019). The most recent morphological and molecular evidence supports the monophyly of the order, although family delineations remain unsettled (Johnson et al., 2012; Chen et al., 2014). Eels occupy diverse habitats, ranging from shallow water to deep shelf, slope and meso- and bathypelagic realms and are accordingly morphologically diverse. All have elongate bodies and lack pelvic fins, which, for the benthic forms, facilitates their frequent occupation of small spaces or burrowing. Perhaps the most specialized of the benthic forms are members of the Muraenidae (moray eels), a family whose monophyly has never been questioned (Nelson, 1966, 1967; Smith, 1984; Johnson et al., 2012). As the third most species-rich anguilliform family (213 species; Fricke et al., 2019), morays occur worldwide in relatively warm shallow to moderately deep waters and are particularly prevalent in shallow-water rock and coral reef habitats.

In seminal studies on the comparative gill-arch skeleton and muscles of several families of anguilliforms, Nelson (1966, 1967) described the extreme reduction of the gill

arches of morays and proposed that their pharyngeal jaws and the attached muscles enable them to transport relatively large prey a considerable distance from the jaws into the esophagus. He also recognized two muraenid subfamilies, Uropterygiinae and Muraeninae, based on distinct modification of the gill arches. This remarkable ability was not considered further until Mehta and Wainwright (2007a) documented it using high-speed video and videofluoroscopy. That paper, published in *Nature*, received considerable press, and this striking feeding specialization of moray eels, termed raptorial feeding by the authors, has justifiably been widely incorporated into texts, online media, and classrooms internationally. Mehta and Wainwright (2008), henceforth M&W, was essentially a follow-up expansion of the 2007a paper, wherein details of the relevant anatomy were further explored, described, and illustrated with one goal being to clarify and provide a unifying terminology for the gill-arch muscles of muraenid eels. Recently, while studying the extraordinary deep-sea telescope fish *Gigantura indica* (Konstantinidis and Johnson, 2016), I discovered that it has a remarkably similar, though seemingly more extreme, raptorial feeding mechanism involving similar reduction of the dorsal gill-arch elements, loss of all but one of the ventral elements, and origin of presumed protractor muscles far forward on the ventral surface of the braincase. As I began the planned work on *Gigantura*, I wanted to compare the configuration of the apparatus in *Gigantura* with that of muraenids as described by M&W. After reading and studying their descriptions and drawings in detail, I realized that my observations of the relevant anatomical details differ markedly from theirs, which led to the current study. I conclude that five of seven muscles described were misidentified. The purpose of this paper is to describe and illustrate my observations and compare them to those of M&W and Nelson (1967), henceforth Nelson. I also discuss possible functional implications.

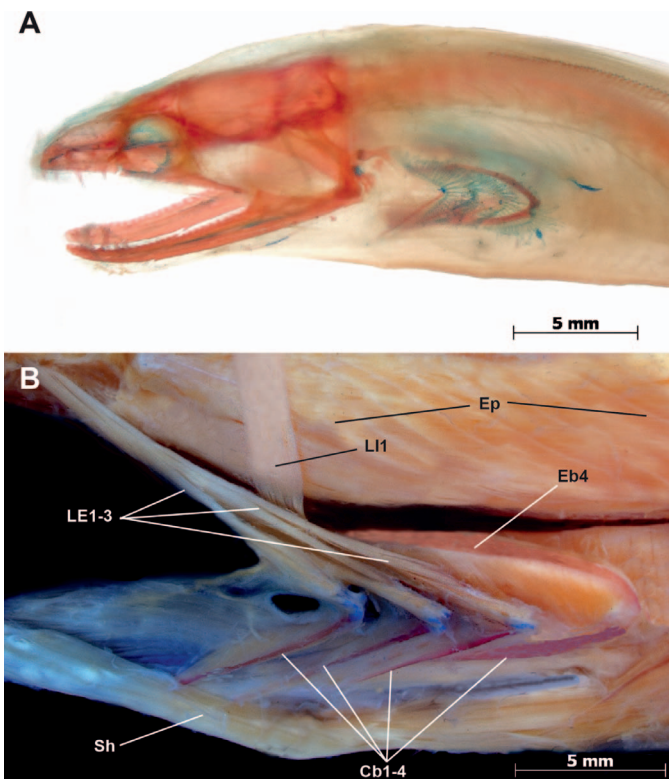
## MATERIALS AND METHODS

Specimens of all ten genera and one subgenus of muraenines and three of four uropterygiine genera were double stained following the methods of Springer and Johnson (2004), henceforth S&J. In many, the gill arches were fully removed

<sup>1</sup> Division of Fishes, National Museum of Natural History, Smithsonian Institution, P.O. Box 37012 MRC 159, Washington, D.C. 20013-7012; Email: johnsond@si.edu.

Submitted: 25 March 2019. Accepted: 22 April 2019. Associate Editor: W. L. Smith.

© 2019 by the American Society of Ichthyologists and Herpetologists DOI: 10.1643/CI-19-211 Published online: 25 June 2019



**Fig. 1.** (A) *Gymnothorax buroensis*, USNM 141541, 170 mm, left lateral view of head of cleared and stained specimen showing posterior position of gill arches. (B) *Muraena lentiginosa*, USNM 318298, 210 mm, left lateral view of gill arches *in situ*, showing external levators and first internal levator; second internal levator occluded. Cb, ceratobranchial; Eb, epibranchial; Ep, epaxialis; LE, levator externus; LI, levator internus; Sh, sternohyoideus.

and variously dissected (destructively in some), but in some, they were studied and photographed *in situ* for comparison to the drawings of M&W. Representatives of seven non-muraenid anguilliform families, including the three universally recognized as basal to the other 17, were partially dissected to identify the origin of the first internal levator muscle (LI1) within the epaxialis. Muscle terminology follows S&J, and I discuss my reasons for accepting or rejecting other previously proposed terminology. Photographs were taken with a Zeiss Axiocam attached to a Zeiss SteREO Discovery V12. These are composite images prepared with the Zeiss AxioVision software to increase the depth of field. This study was carried out under Smithsonian Animal Care and Use Committee (ACUC) approval to G. David Johnson (ACUC #2017-12). Guidelines for laboratory activities with fishes established by the American Fisheries Society (<https://www.asih.org/sites/default/files/documents/publications/asf-guidelines-use-of-fishes-in-research-2013.pdf>) were followed for all laboratory activities, including euthanasia with tricaine methane sulfate (MS-222). The studies involved no endangered or protected species. All but one specimen were from preexisting alcohol-preserved collections. The exceptional specimen (*Gymnothorax* (*Neomuraena*) *saxicola*, USNM 443784) was purchased through the aquarium trade, euthanized, and then fixed in formalin and preserved in 70% ethanol for dissection.

**Abbreviations.**—AD4—adductor dorsalis 4; Cb—ceratobranchial, 1–4 as numbered; DR—dorsal retractor; Eb—epibranchial, 1–4 as numbered; Ep—epaxialis; HR—hypaxial

retractor; Hy—hypaxialis; LE—levator externus, 1–4 as numbered; LI—levator internus, 1–4 as numbered; LPT—lower pharyngeal toothplate; OD4—obliquus dorsalis 4; Pb—pharyngobranchial, 2–4 as numbered; Pcl—pharyngocleithralis; PP—protractor pectoralis; RC—rectus communis; RecD—rectus dorsalis; Sh—sternohyoideus; SO—sphincter oesophagi; Sph—subpharyngealis; UPT—upper pharyngeal toothplate; VR—ventral retractor.

## RESULTS

I emphasize the dorsal gill-arch elements, which are more complex and critically important to raptorial feeding, and their extrinsic musculature (with the exception of the intrinsic adductor dorsalis four), as these are responsible for the extensive movements of the pharyngeal jaws. I also describe and discuss the role of the sternohyoideus, a muscle not directly associated with the gill arches. My observations and photographic illustrations of the subfamily Muraeninae (Figs. 1–7) are based primarily on several species of *Muraena*, although I did confirm my observations in the nine other muraenine genera, and the few differences I found within muraenines (the most substantial being in a subgenus of *Gymnothorax*, *Neomuraena*) are described. My observations on uropterygiines (Figs. 8–10) are given in a separate section below.

## MURAENINAE

### Gill-arch skeleton

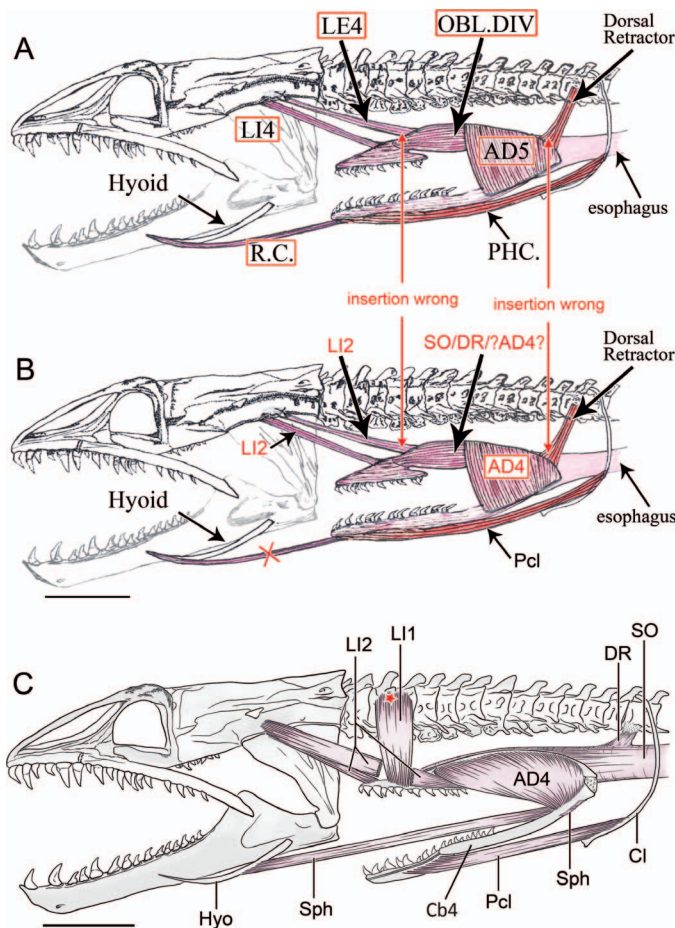
Figures 1–4

The pharyngeal apparatus of muraenid eels is notably reduced compared to most teleosts, including other anguilliform eels (see Nelson, 1966: figs. 41–44). There are no hypobranchials or basibranchials. There are four epibranchials and ceratobranchials, the first three of which are relatively thin and delicate and apparently serve only to support the gill filaments. The fifth ceratobranchial (Cb5) is absent, and the rod-like fourth ceratobranchial (Cb4) supports the lower pharyngeal toothplate (LPT), which is usually supported by Cb5. The fourth epibranchial (Eb4) is robust and rod-like and, as described and illustrated by M&W (fig. 4) and illustrated by Nelson (1966: figs. 43–44), articulates at its anterior end with the medial surface of a dorsal process (“horn-shaped process” of M&W) on the single toothed element in the dorsal complex, the large, elongate upper pharyngeal toothplate (UPT).

### Extrinsic gill-arch muscles

**External levators (LE).**—(Fig. 1B) There are three relatively thin external levators (LE1–3). As with levators in most teleosts, they have a common origin along with the internal levators on the occipito/otic region of the braincase and insert on their respective epibranchials. A fourth external levator occurs in only four species placed in the subgenus *Neomuraena* (not illustrated). As is typical for LE4, it originates together with the other levators but bypasses UPT medially to insert on the dorsal surface of Eb4 near its articulation with Cb4 as is the case in uropterygiines.

**Internal levators (LI).**—(Figs. 2C, 3–5, 7, 10) There are two internal levators (LI1–2). Levator internus 1 (LI1) originates in the epaxialis directly above UPT and inserts on the anterior portion of its dorsal surface (Figs. 1B, 2C, 3–5, 7). It is identified as such as follows. Most pre-acanthomorphs have



**Fig. 2.** A and B based on figure 6B of Mehta and Wainwright (2008), modified. Red arrows point to indicated insertion points with which I disagree. (A) Red boxes indicate muscle identifications with which I disagree. (B) Muscles with my revised identifications in red letters. (C) Muscles redrawn based on my observations of *Muraena lentiginosa*, USNM 318298, epaxialis removed to match A and B, thus actual origin of LI (red star) within it is not shown; note origin of Sph on posterolateral surface of Cb4. AD, adductor dorsalis (?AD4? indicates the possibility that muscle as drawn could include part of AD4); Cb4, fourth ceratobranchial; Cl, cleithrum; DR, dorsal retractor; Hyo, hyoid (ceratohyal); LE, levator externus; LI, levator internus; OBL.DIV, obliquus dorsalis; Pcl (=PHC. in panel A), pharyngocleithralis; R.C., rectus communis; SO, sphincter oesophagi; Sph, subpharyngealis. X indicates that there is no distinct muscle equivalent to the R.C. shown in A.

three internal levators, the most posterior being the third, which is lost at the level of Ctenosquamata (*sensu* Rosen, 1973) concomitant with the loss of the fifth upper pharyngeal toothplate (UP5; Johnson, 1992). UP5 is also absent in several pre-ctenosquamate clades. A third internal levator (LI3) has been lost independently in Anguilliformes, where there is also no UP5. Identity of the two internal levators of most eels is obvious, as one (LI1) inserts on Pb2 (second pharyngobranchial) and the other (LI2) on Pb3. Nelson (349) noted briefly that in *Conger* LI1 extends between the fascia of the trunk and Pb2, and, because he only discussed differences between *Conger* and the other families he described, the implication is that this also characterizes those other families. I agree, and I know of no group of teleosts outside anguilliforms in which an internal levator originates from the epaxial musculature rather than the braincase. S&J and Springer and Johnson (2015) did not consider the point of origin of internal or external levators. However, I have

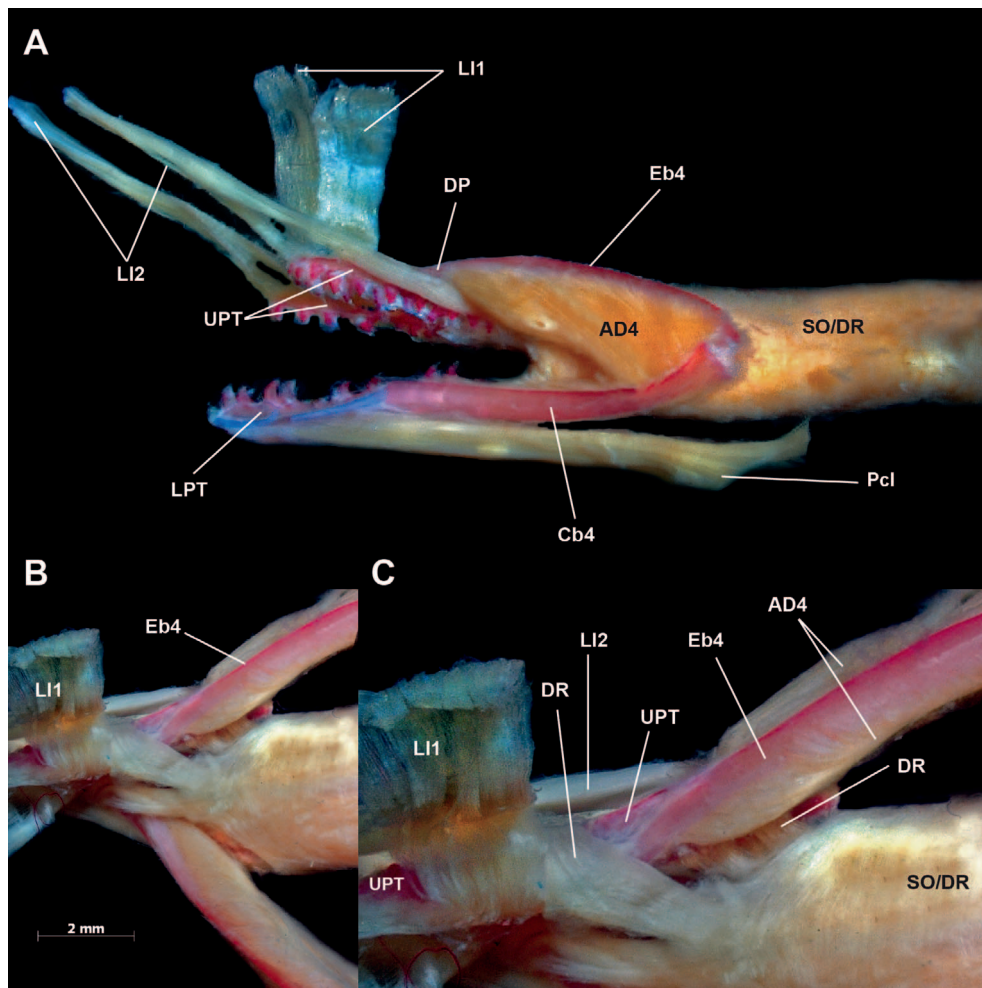
confirmed the origin of LI1 to be as Nelson described it for *Conger* (from the epaxialis) in anguillids, muraenids, ophichthids, and chlopsids, and I illustrate it for muraenines in Figures 1B and 7. I have not examined the condition in all anguilliform families, but I can confirm that it exhibits the primitive state (origin on the braincase) in protanguillids and synphobranchids. Additionally, when LI1 originates in the epaxialis, it is broad and strap-like vs. roughly cylindrical (e.g., in Springer and Johnson, 2015, compare LI1 in figs. 4, 5 of *Conger* and *Anguilla* to that in figs. 2, 8 of *Protanguilla* and *Synphobranchus*).

Levator internus 2 (LI2) originates on the occipito/otic region of the braincase together with the external levators and gives rise to two separate sections, which are continuous at their origin. The anterior section inserts on the dorsomedial surface of the anterior end of UPT and the posterior section on the dorsolateral surface of its posterior end (Figs. 2C, 3A, 4, 5). Muraenids have no separate Pb2, the normal insertion site of LI1, but because the third muscle bundle inserting on UPT is very broad and strap-like and originates in the epaxial musculature, it is readily identifiable as Nelson's LI1. Thus, the remaining two muscle bundles are most parsimoniously interpreted as subdivisions of LI2, a condition unique among eels to the Muraeninae. The four species currently placed in the subgenus *Neomuraena* (not illustrated) are exceptional in having an undivided LI2.

**Dorsal retractor (DR).**—(Figs. 2C, 3–6) Nelson (362) reported the presence of both dorsal and ventral retractors (DR, VR) in all eels (wherein the latter are unique among teleosts), essentially continuations of the inner longitudinal muscle layer of the sphincter oesophagi (SO) muscle fibers. These extend anteriorly from the esophageal wall and attach to the posteriormost portion of UPT (DR) and that of LPT (VR), which is associated with the fourth ceratobranchial (Cb4; Fig. 5). Posterior to the attachments of the retractors, the outer transverse or circular esophageal muscle layer surrounds the longitudinal layer. Nelson observed that only in muraenines does a portion of the dorsal retractor attach to the vertebral column, and he and others (e.g., Winterbottom, 1974; Springer and Johnson, 2015) have made clear that this muscle is not equivalent to Rosen's (1973) retractor dorsalis (a synapomorphy of neoteleosts, Rosen, 1973; Johnson, 1992), which also originates on anterior vertebrae but is largely outside the sphincter oesophagi (see also S&J). My observations of the dorsal retractor of muraenines agree with Nelson's and indicate that its attachment to the vertebral column ranges from robust direct muscular attachment (e.g., in *Gymnomuraena*, Fig. 6) to connective tissue suspension in other muraenine genera, except *Rhinomuraena*, where I found it lacking. As reported by Nelson and M&W, all uropterygiines also lack this attachment.

**Recti dorsales (RecD).**—These are the muscles Nelson called obliquii inferiores (see Winterbottom, 1974: 259 and S&J: 26). They connect adjacent epibranchials. As described by Nelson (table 2, fig. 11) muraenines have RecD1-3 and uropterygiines have only RD2-3. M&W did not mention these muscles, and they are not illustrated or discussed further here.

**Subpharyngealis (Sph).**—(Figs. 1, 2C, 7) As described and illustrated by Nelson (358, fig. 10), the ventral muscles of muraenine eels primarily comprise numerous subdivisions (Nelson's interbranchial attractors) of the subpharyngealis.



**Fig. 3.** *Muraena lentiginosa*, USNM 318298, 290 mm. (A) Slightly oblique left lateral view of fourth gill arch (first three removed) and associated musculature removed from body, sphincter oesophagi (SO/DR) intact; note two branches of LI2 and their insertion points on UPT. (B, C) Dorsal views of anterior ends of fourth epibranchials (C, close up of right side) deflected laterally to show that DR does not insert on them, but instead on UPT. AD, adductor dorsalis; Cb, ceratobranchial; DP, dorsal process of UPT; DR, dorsal retractor; Eb, epibranchial; LI, levator internus; LPT, lower pharyngeal toothplate; Pcl, pharyngocleithralis; SO/DR, sphincter oesophagi/dorsal retractor; UPT, upper pharyngeal toothplate. (Subpharyngealis not shown.)

These are represented by fan-like arrays of muscle fibers lying dorsal to the ventral-arch elements connecting adjacent ceratobranchials, some of which extend forward to insert on the hyoid arch (by which he apparently meant specifically ceratohyal) These muscles are unusual in that they lie dorsal to the skeletal elements of the ventral arches (see Nelson: 249 and Springer and Johnson, 2015: 615). The most robust of these subdivisions originates on the dorsal surface of Cb4 near its articulation with Eb4 (Fig. 7C).

#### Intrinsic gill-arch muscle

**Adductor dorsalis 4 (AD4).**—(Figs. 2–4, 7C) Adductor dorsalis 4 is a large ovoid to triangular muscle that originates on the dorsal surface of the posterior quarter of Cb4 and inserts along the ventral surface of most of the length of Eb4 with some fibers continuing onto the lateral surface of the dorsal process of UPT.

#### Sternohyoideus (Sh)

Figure 7A, B


The sternohyoideus, not part of the gill-arch musculature, is described here because of its obvious activity during pharyngeal jaw movement (see Functional Summary). It is an elongate muscle originating primarily along the lateral surface of the hypaxialis and inserting along the ceratohyal (Eagderi, 2010: figs. 6.13c, 6.16c). In most teleosts and other eels, it inserts on the urohyal, which is lacking in muraenids.

#### UROPTERYGIINAE

Figures 8–10

The gill-arch skeleton of uropterygiines comprises the same elements in the same configuration as that of muraenines, with some minor differences. As described by M&W, uropterygiines lack a dorsal process on UPT, and thus the connection to the fourth epibranchial is dorsal rather than medial. M&W also reiterated Nelson's observations that LPT lacks a lateral groove for insertion of the pharyngocleithralis, and the fourth ceratobranchial attaches to its ventral rather than lateral side. In addition, some uropterygiines have first and second hypobranchials (Nelson, M&W).

The extrinsic gill-arch muscles of uropterygiines differ from muraenines in several ways. As illustrated by Nelson (fig. 9) and noted by M&W, the first three external levators are reduced, and there are no longitudinal fibers of the sphincter oesophagi attached to the vertebral column. There are in addition three significant differences. First, unlike muraenines, with the exception of *Neomuraena* (see above), there is an LE4, originating on the braincase with the other levators and inserting on the posterior end of EB4. Second, LI2 comprises only a single bundle that inserts on the anterior end of UPT. Finally, the most striking difference is the presence of an additional dorsal retractor that finds its origin in the hypaxial musculature in the region of the extremely reduced cleithrum (Figs. 9, 10). This is a relatively large oblong to trapezoidal muscle that tapers anteriorly to insert by a strap-like tendon on the fourth epibranchial near its



**Fig. 4.** *Muraena lentiginosa*, USNM 318298, 210 mm. (A) Left lateral view of left fourth gill arch and associated musculature, removed from body, circular fibers of SO removed to expose longitudinal fibers of DR; anterior section of LI2 occluded by posterior section. (B) Medial view of A; posterior section of LI2 exposed dorsal and ventral to anterior section. AD, adductor dorsalis; Cb, ceratobranchial; DP, dorsal process of UPT; DR, dorsal retractor; Eb, epibranchial; LI, levator internus; LPT, lower pharyngeal toothplate; UPT, upper pharyngeal toothplate.

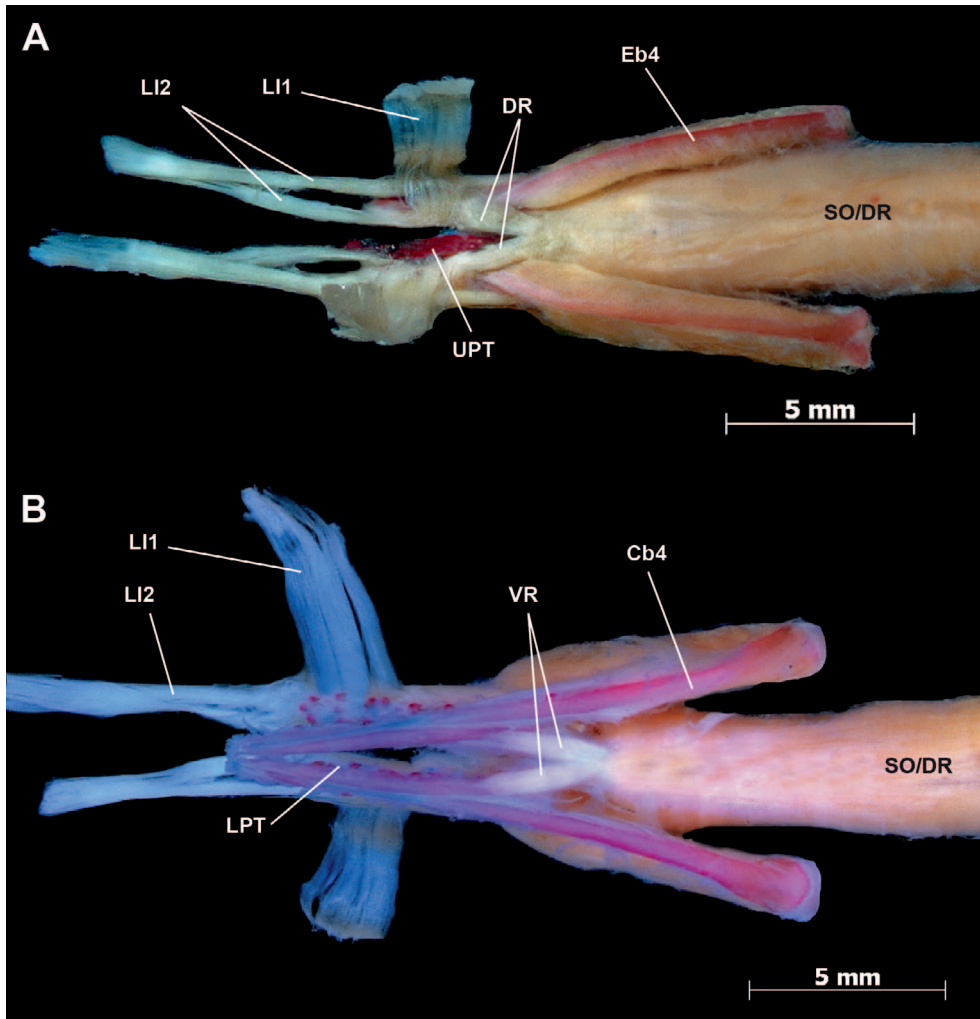
articulation with the fourth ceratobranchial. I term this muscle hypaxial retractor (HR). In lateral view, this large muscle is well hidden medial to the pharyngocleithralis, sternohyoideus, and particularly the anteriormost portion of the hypaxialis.

## DISCUSSION

There are numerous discrepancies between the anatomical details and terminology presented by M&W and my own. These include identity of bony and muscular components (homologies), terminology, reports of presence or absence of elements and attachment (insertion and origin) sites. Comparative anatomy is founded in anatomical accuracy and appropriate argumentation for identity/homology conclusions. Accordingly, below, I present the descriptions of M&W (in quotes), compare them to my own, and discuss the reasons for my conclusions. Disagreements with Nelson's observations or terminology are also discussed. Finally, I consider the potential functional implications of these differences with regard to mechanics of movement.

According to M&W (609), "Synonyms for moray gill arch and pharyngeal muscles were compiled from the literature and identified following Winterbottom (1974)." However, the only indication that they comparatively evaluated the previously proposed terminology is their table 1 (609), in which they listed the seven presumably relevant terms of Winterbottom (1974), hereafter Winterbottom, in the left column and those of Nelson in the right. Adding to the confusion is the statement in the legend of that table, "Muscle terminology adopted from Winterbottom (1974) and Springer & Johnson (2004)." With no comparative discussion, it is unclear what role each of these papers played in M&W's study when adopting the referenced muscle

terminology. S&J fully described their methodology in which gill arches are carefully removed and stained with alcian blue and ethanol-alizarin solution so that the skeletal elements and respective muscular associations can be clearly discerned. The advantages of this bone-staining procedure for myology was initially advocated by Springer and Johnson (2000), and it has become the standard for such work (e.g., Datovo and Bockmann, 2010; Datovo and Vari, 2013; Datovo et al., 2014; Springer and Johnson, 2015). If Mehta and Wainwright carefully consulted S&J, it is unclear why they did not follow the procedure, and I believe the accuracy of their anatomical descriptions would have benefitted substantially from its use. My comparative evaluation of Winterbottom, Nelson, S&J, and my own observations with M&W's table 1 leads me to conclude that four of the five dorsal muscles listed in the left column are misidentified (Fig. 1), and more perplexingly, as noted by Nelson (tables 1, 2), do not occur in muraenine eels (Table 1), and one is homologized incorrectly. Of the two ventral muscles listed in the left column, one is not as described and homologized incorrectly (the other is misspelled and the usage attributed to Winterbottom is incorrect). Furthermore, and most importantly, there is no indication of how the correspondence between Winterbottom's and Nelson's terminologies was determined. As an example of the confusion this creates, M&W equate the obliquus dorsalis of Winterbottom with the obliquus superior of Nelson, despite the fact that Nelson reported that muscle to be absent in muraenids. Such discrepancies are particularly troublesome because, as my observations indicate, Nelson's description of the dorsal gill-arch muscle complex (some terminology aside) is more accurate than that of M&W, though I am not in complete agreement with every aspect of it.



**Fig. 5.** *Muraena lentiginosa*, USNM 318298, 290 mm. (A) Dorsal view of fourth gill arches and associated musculature, removed from body, SO/DR intact, showing anterior extension of DR to insert on UPT. (B) Ventral view of A showing insertion of VR on LPT, pharyngocleithrals removed. Cb, ceratobranchial; DR, dorsal retractor; Eb, epibranchial; LI, levator internus; LPT, lower pharyngeal toothplate; SO/DR, sphincter oesophagi/dorsal retractor; UPT, upper pharyngeal toothplate; VR, ventral retractor.

As M&W (605) stated, the purposes of their study were “first to provide a general description of the anatomy of the moray pharyngeal jaw apparatus” and second, to “provide a detailed analysis of protraction and retraction of the pharyngeal jaws during transport.” In doing so, they (608–

609) maintained that “There has been some confusion pertaining to gill arch muscle terminology, in addition to which muscles are responsible for moving the moray pharyngeal jaw apparatus” and said (605) they were offering “a unifying terminology for some of the branchial muscles underlying this important behavior pattern, following Winterbottom (1974).” Inaccuracies in anatomical details and absence of any explanation of how this unifying terminology was ascertained seem only to have engendered confusion. My purpose here is to alleviate the confusion, bring accuracy to the descriptive details and clarify the terminology of the pharyngeal apparatus of muraenid eels. Below I address specific statements by M&W.

## MURAENINAE

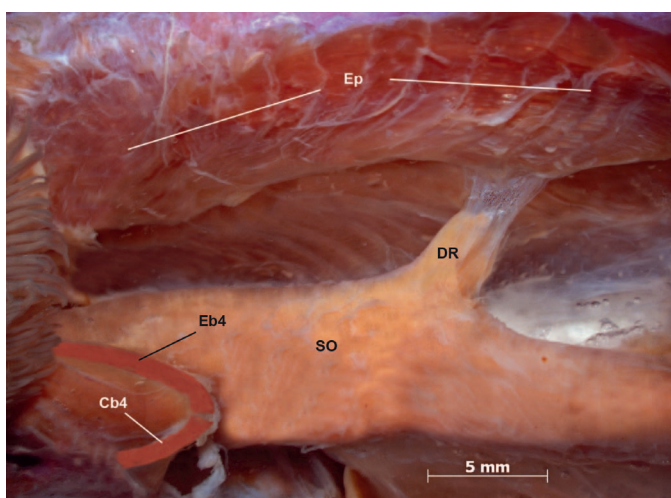
### Gill-arch skeleton

Figures 1–4

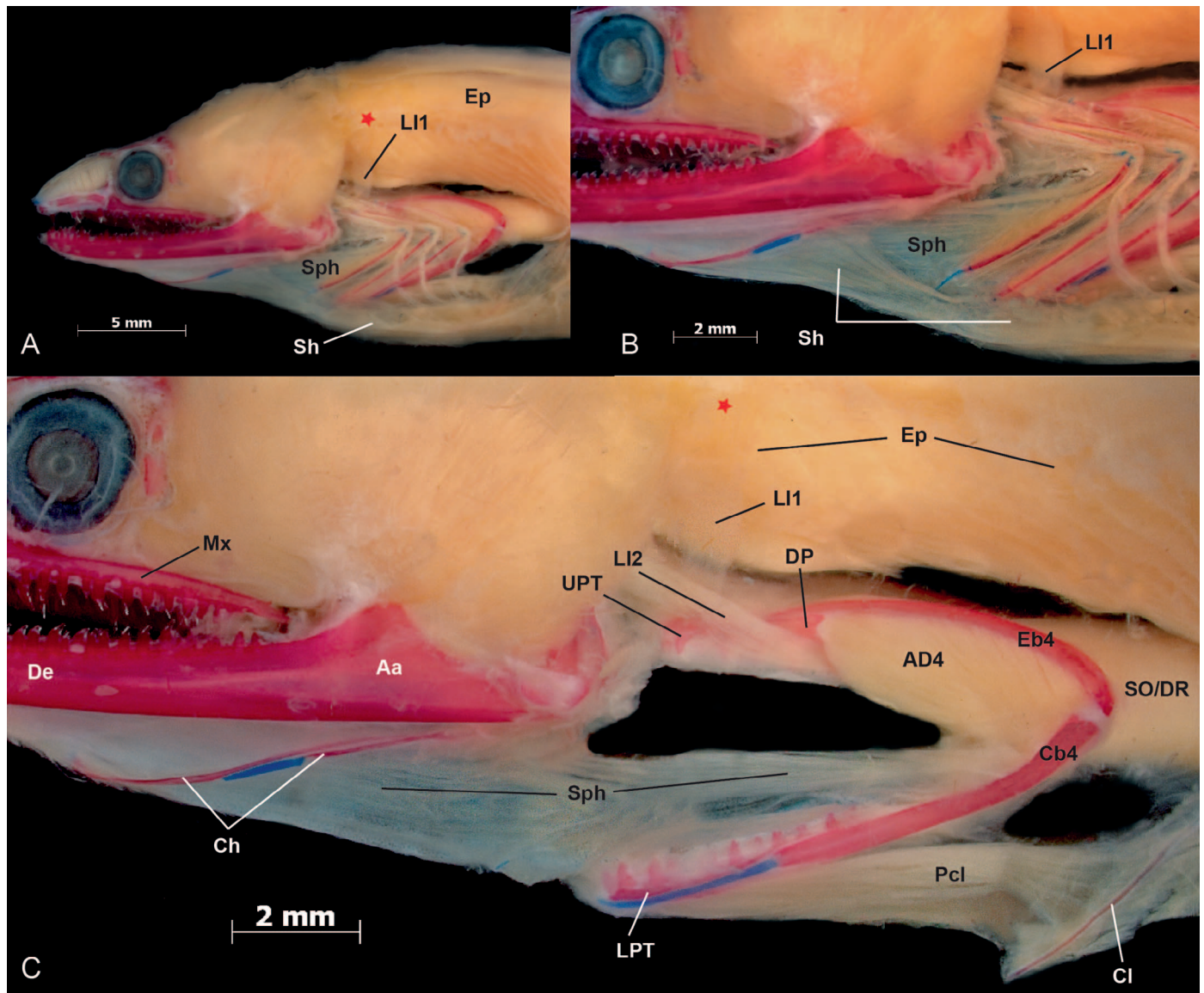
#### Fourth pharyngobranchial (Pb4).—

“The most anterior portion of the fourth epibranchial is connected to the center of a well-developed fourth pharyngobranchial bone, which is endowed with two rows of 14–16 sharply recurved teeth.” (M&W: 606)

The distinction between the fourth pharyngobranchial and the fourth upper pharyngeal toothplate was clarified by Nelson (1968: 489–491), and as shown by Nelson (1966),



**Fig. 6.** *Muraena retifera*, ANSP 103574, 165 mm. Left lateral view of tendinous attachment of DR to vertebral column (covered by epaxialis) as it exits SO. Cb, ceratobranchial; DR, dorsal retractor; Eb, epibranchial; Ep, epaxialis; SO, sphincter oesophagi.



**Fig. 7.** *Muraena argus*, USNM 318316, 250 mm. Left lateral view, gill arches *in situ*. (A) Entire gill arches exposed, sternohyoideus intact. (B) Close up of A. (C) First three arches and sternohyoideus removed, pharyngocleithralis exposed. Note absence of well-defined muscle bundle from anterior tip of LPT to hyoid and presence of fan-like subpharyngealis (Sph). Aa, anguloarticular; AD, adductor dorsalis; Cb, ceratobranchial; Ch, anterior and posterior ceratohyal; Cl, cleithrum; De, dentary; DP, dorsal process of UPT; Eb, epibranchial; Ep, epaxialis; LI, levator internus; LPT, lower pharyngeal toothplate; Mx, maxilla; Pcl, pharyngocleithralis; Sh, sternohyoideus; SO/DR, sphincter oesophagi/dorsal retractor; Sph, subpharyngealis; UPT, upper pharyngeal toothplate. Red star marks origin of LI1 within epaxialis.

there is no fourth pharyngobranchial (a cartilaginous element) in anguilliform eels. The precise composition of the toothed element in muraenids is difficult to determine without ontogenetic evidence (currently not available for muraenids) but most likely includes elements of the second and third pharyngobranchials and associated toothplate and possibly the fourth upper pharyngeal toothplate. Fusion of adjacent pharyngobranchial elements is not common but has been demonstrated in some stomiiform fishes (Schnell and Johnson, 2012). Nelson referred to it as UP3-4, noting (Nelson, 1966: table 1) that the two elements were “probably fused.” Given the uncertainty without ontogeny, I refer to it as the upper pharyngeal toothplate (UPT). As described by M&W, the anterior end of Eb4 articulates with the medial surface of a dorsal flange at about the mid-length of UPT. Posteroventrally, Eb4 articulates with the posterodorsal end of Cb4.

### Extrinsic gill-arch muscles

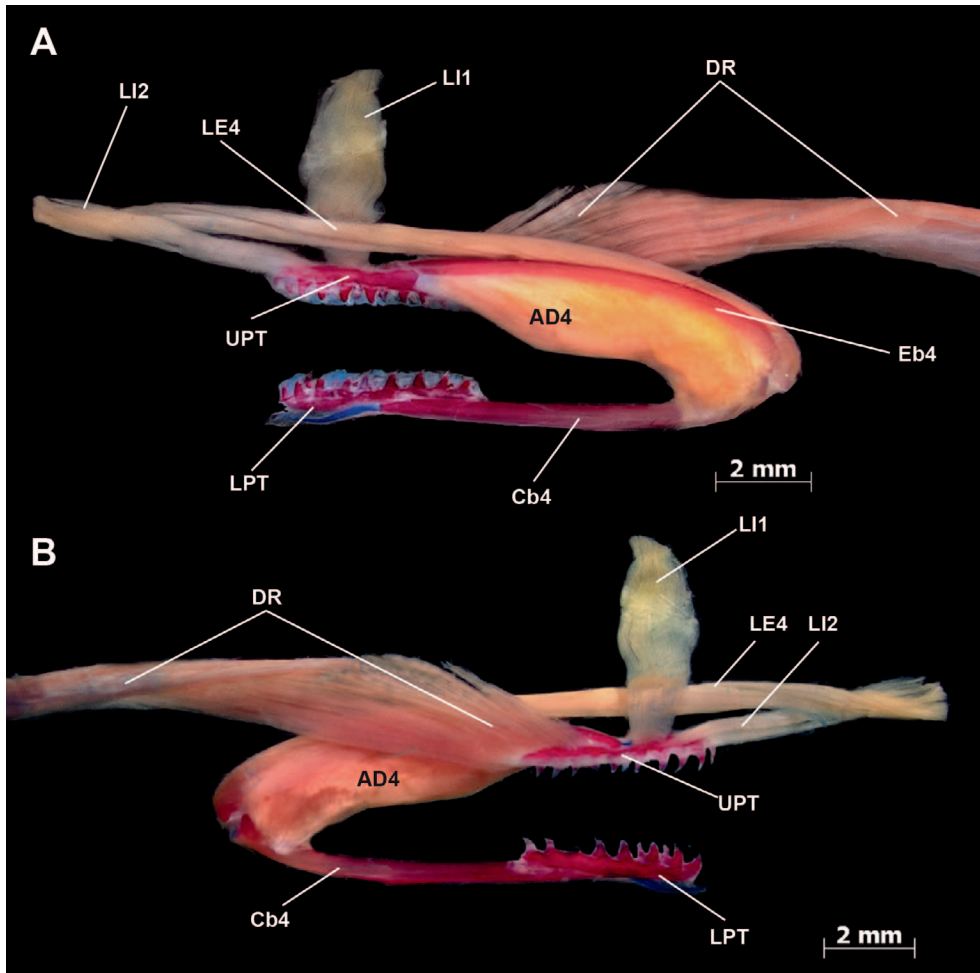
#### Internal levators.—(Figs. 3–5)

“In muraenines, four external levators are present (1–4)” and “have their sites of insertion on the dorsal surface of the corresponding epibranchials (1–4). The external levators converge to form a single bundle of muscle fibers just below the origination site on the parasphenoid.” (M&W: 610)

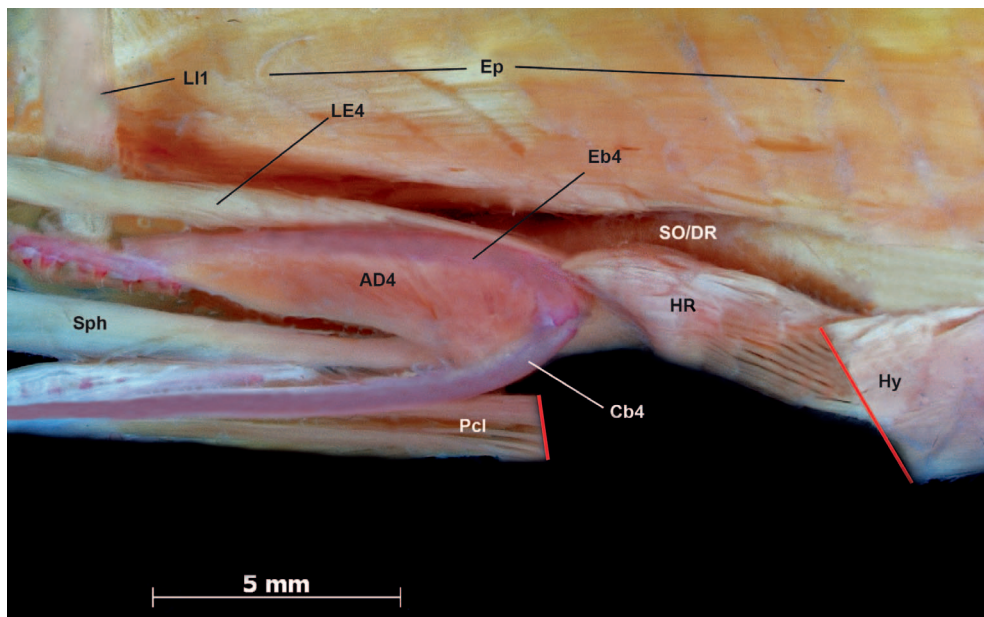
“Levator externus 4, the longest, runs dorsally along the epibranchial bone and inserts on the posterior portion of the dorsal side of the fourth epibranchial.” (M&W: 609–610)

Whereas the first three external levators insert as described by M&W, none of them originate on the parasphenoid (but rather on the occipito/otic region of the cranium; also see

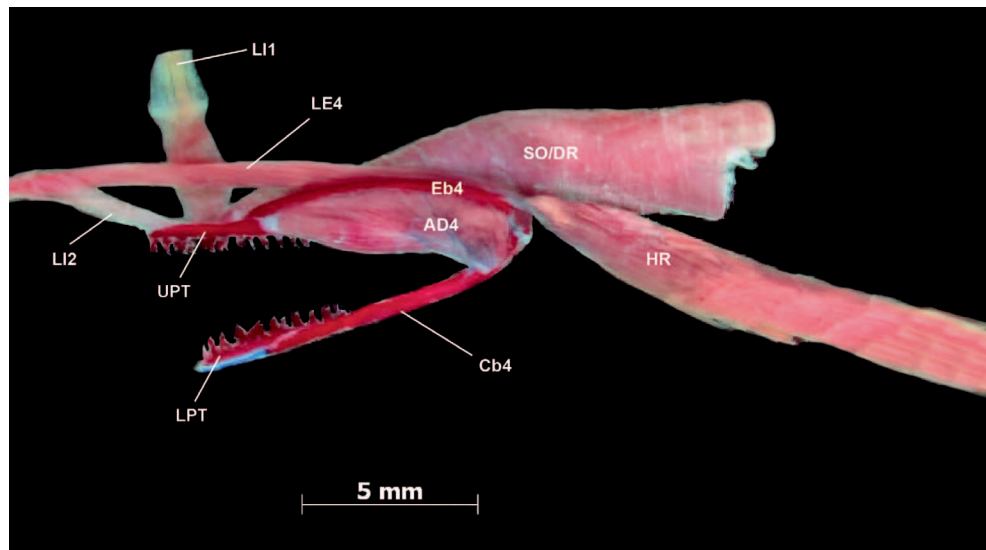




**Fig. 8.** *Uropterygius alboguttatus*, USNM 338657, 350 mm. (A) Left lateral view of left fourth gill arch and associated musculature, removed from body, circular fibers of SO removed to expose longitudinal fibers of DR, hypaxial retractor removed. (B) Medial view of A. Note insertion of single branch of LI2 on anterior end of UPT and posterior insertion point of LE4 near Eb4-Cb4 articulation. AD, adductor dorsalis; Cb, ceratobranchial; DR, dorsal retractor; Eb, epibranchial; LE levator externus; LI, levator internus; LPT, lower pharyngeal toothplate; UPT, upper pharyngeal toothplate.



**Fig. 9.** *Uropterygius alboguttatus*, USNM 338657, 310 mm. Left lateral view of left fourth gill arch and associated musculature *in situ*, posterior end of pharyngocleithralis and anterior end of hypaxialis excised at red lines to expose hypaxial retractor; LE4 passes medial to the insertion of HR to insert more posteriorly (see also Fig. 10). AD, adductor dorsalis; Cb, ceratobranchial; Eb, epibranchial; Ep, epaxialis; HR, hypaxial retractor; Hy, hypaxialis; LE levator externus; LI, levator internus; Pcl, pharyngocleithralis; SO/DR, sphincter oesophagi/dorsal retractor; Sph, subpharyngealis.



**Fig. 10.** *Uropterygius alboguttatus*, USNM 338657, 340 mm. Left lateral view of left fourth gill arch and associated musculature, removed from body. Note insertion of hypaxial retractor on Eb4. AD, adductor dorsalis; Cb, ceratobranchial; DR, dorsal retractor; Eb, epibranchial; HR, hypaxial retractor; LE levator externus; LI, levator internus; LPT, lower pharyngeal toothplate; SO/DR, sphincter oesophagi/dorsal retractor; UPT, upper pharyngeal toothplate.

Eagderi, 2010), and the putative fourth (considered here to be the posterior subdivision of LI2) has no association with the fourth epibranchial and inserts instead on the dorsal surface of the posterior portion of the upper pharyngeal toothplate. As noted above in Results, the four species of the subgenus *Neomuraena* (not examined by M&W) are exceptional in having an LE4 and an undivided LI2. According to M&W (table 1), LE4 is the muscle that Nelson called protractor posterior, and they stated, “The levator externus 4 is an important dorsal protractor. We presume that elongation of the levator externus 4 resulted in the synonym protractor posterior (Nelson, 1967).” However, Nelson (table 2, fig. 11) reported that the posterior protractor (his PP) is absent in muraenines. Nelson reported PP to be present only in uropterygiines, though I see no reason not to call that muscle in uropterygiines LE4 (Fig. 8A, B), which is also present in other non-muraenine eels (e.g., see Springer and Johnson, 2015). Nelson did report and illustrate a second internal levator (LI2, not mentioned by M&W), that would be the correct identity of the muscle labeled external levator 4 by M&W, given its insertion on UPT. As discussed above

(see levator internus 2 in Results), I consider this the posterior subdivision of LI2 (see Figs. 2–5).

“There is a single internal branchial levator, levator internus 4, that originates from the posterior part of the parasphenoid just behind the bundle of levator externi and inserts on the dorsal side of the fourth pharyngo-branchial just anterior to the Pb4/Eb4 joint.” (M&W: 610, shown correctly inserting on UPT in their fig. 4, mistakenly labeled there as LI1 but described in the legend as LI4, where it is said to insert on Eb4).

There is no fourth internal levator in any actinopterygian, and there is no reason that the muscle identified as LI4 by M&W should not be considered equivalent to Nelson’s internal levator 2, given its insertion on UPT. Muraenines are unique among eels in having three separate muscle bundles inserting on UPT (LI1 and two sections of LI2), identified by Nelson as internal levators 1 and 2 and the protractor medialis. Muraenids have no separate Pb2, the normal insertion site of LI1, but because one of these muscles is broad and strap-like and originates in the epaxial

**Table 1.** Modified from Table 1 of Mehta and Wainwright (M&W, 2008) first two columns. First column: black bold—muscles identified by M&W (following Winterbottom, 1967 terminology) that do not occur in muraenines. Second column: red bold—terminology of Nelson with which I disagree; green bold—muscle never reported by Nelson (1967). Third column: revised identifications and terminology based on Springer and Johnson (S&J, 2004, 2015).

Terminology adopted by M&W (Winterbottom)	Synonyms as per M&W (Nelson)	Revised terminology (S&J, 2004, 2015)
	Dorsal muscles of the 4 <sup>th</sup> gill arch element	
<b>Levator externus 4</b>	<b>Protractor posterior</b>	Levator internus 2
<b>Internal levator 4</b>	<b>Protractor medialis</b>	Levator internus 2
<b>Obliquus dorsalis</b>	Obliquus inferior, superior	Sphincter oesophagi/dorsal retractor/?adductor 4?
<b>Adductor 5</b>	Obliquus posterior	Adductor 4
Dorsal retractor	<b>Lateral retractor</b>	Dorsal retractor
	Ventral muscles of the 4 <sup>th</sup> gill arch element	
Pharyngocleithralis (sic)	Pharyngocleavicularis	Pharyngocleithralis
<b>Rectus communis</b>	Ventral retractor	Subpharyngealis

musculature, it is readily identifiable as LI1 (see Internal levators section in Results). M&W did not report, and therefore I presume that they did not see, the prominent strap-like LI1 and instead identified the two sections of LI2 as LI4 and LE4 (LI1 appears only once in M&W, in their fig. 4, where, as mentioned above, it appears that it was mislabeled). Moreover, LI2 originates on the occipito/otic region of the braincase (see also Eagderi, 2010: 103) and not on the parasphenoid as they indicated. M&W identified the anterior branch of LI2 as the “fourth internal levator” concluding that it is the muscle that Nelson called “protractor medialis.” Because actinopterygians have no fourth internal levator (see S&J and Springer and Johnson, 2015), there is no justification for that surmise. Consequently, that muscle should be considered equivalent to Nelson’s internal levator 2, given its insertion on UPT. Nelson (358, fig. 11) described four muscles inserting on UPT. As discussed below, I was unable to find one of these, his protractor lateralis (LP). Of the remaining three, one is LI1, and he identified one of the other two as levator internus 2 (LI2) and called the other protractor medialis (his MP) with no explanation. His LI2 inserts on UPT posteriorly and his MP inserts on UPT anteriorly. Because these muscle bundles are continuous at their origin together with the external levators of the occipito/otic region of the braincase, it is most parsimonious to interpret them as subdivisions of the second internal levator (LI2), and I am unable to explain why Nelson chose to call the anterior one protractor medialis. This posterior division inserts on the dorsolateral side of the posterior end of UPT and the anterior one on the dorsomedial side of its anterior end (Figs. 2C, 3A, 4). For other instances of subdivided internal levators see S&J (46, 58, pls. 46, 49) and Stiassny (1996: 407, fig. 1).

The unusual origin of LI1 in the epaxialis deserves further attention. I have confirmed this origin of LI1 to be as Nelson (349) described for *Conger* in anguillids, muraenids, ophichthids and chlopsids. Among the other anguilliform families I have examined, I found that it exhibits the primitive state (origin on the braincase) in protanguillids and synphobranchids. Previous studies (e.g., Johnson et al., 2012; Tang and Fielitz, 2013) placed those two families as sequential sister taxa to all remaining anguilliforms. Pending investigation of the origin of LI1 in all eel families, I propose that the distribution of its unique origin from the epaxialis should be further investigated as a potential morphological synapomorphy for a yet-to-be-determined clade of derived eels, one that excludes at least *Protanguilla* and the synphobranchids.

Summarizing, M&W did not refer to the two traditionally known muscles that Nelson illustrated and labeled as LI1 and LI2. Nelson (table 2, fig. 11) listed and illustrated in muraenines (*Gymnothorax*) four “protractor” muscles, two internal levators, a protractor medialis, and a “protractor lateralis.” As discussed above, there are only two dorsal “protractor” muscles—LI1 originating in the epaxialis and LI2 consisting of two sections with a common origin on the braincase. The fourth muscle, the “protractor lateralis” (LP) Nelson (358) described as “extending between UP3-4 and the ventral part of the hyoid arch (attaching there in common with the ventral muscles LA1 (adductor lateralis 1), OAL-2 (attractores obliqui),” the latter of which Nelson recognized as subdivisions of the subpharyngealis, a sheet of longitudinal fibers dorsal to the ventral arch elements. I was unable to locate Nelson’s protractor lateralis or understand it from his illustration. Winterbottom also appears to have been confused by it, listing the muscle as questionably a synonym of an internal levator. This is the only fundamental point about

muraenines in which I disagree with Nelson—the difference in my UPT and his UPT3-4 is not significant, as I agree that there could have been fusion of the two elements. As for his protractor medialis, I used a parsimony argument to postulate that it is most likely to be a subdivision of LI2, thus there is no need to give it a separate name. Nelson apparently did not see the hypaxial retractor in uropterygiines (see below). I agree with his descriptions of LE4 and LI2 there, but again, I cannot explain why he decided to rename them as protractor posterior and protractor medialis, respectively.

#### *Dorsal retractor (DR)*.—(Figs. 2–6)

“In muraenines, there is a very elongate bundle of muscle fibers that runs from the posterior part of the fourth epibranchial to the ventral side of the vertebral column and attaches onto the 10th and 14th vertebrae. We call this muscle the dorsal retractor.” (M&W: 610)

According to M&W, this is the muscle that Nelson called lateral retractor. However, Nelson made no mention of a lateral retractor, and, in fact, he also called this muscle dorsal retractor (his table 2 and fig. 11) and accurately described it as inserting on UPT (his UP3-4). Contrary to M&W, the dorsal retractor in muraenines completely bypasses the fourth epibranchial to insert on the upper pharyngeal toothplate, as does the retractor dorsalis in neoteleosts. M&W (see above) apparently misidentified the anterior portion of the dorsal retractor as the obliquus dorsalis (OD4/OBL.DIV). Their (fig. 1) diagrammatic depiction of the dorsal retractor as fully exposed and separate from the sphincter oesophagi, as is the retractor dorsalis of neoteleosts, is inaccurate; DR only emerges from the sphincter oesophagi directly below its attachment to the vertebral column (Fig. 6). It is more accurately depicted in the diagrammatic sequence in their figure 9, except that in A of that figure it is not attached to the vertebral column.

#### *Subpharyngealis (Sph)*.—(Figs. 2C, 7)

“The rectus communis, which connects the hyoid arch to the anteroventral margin of the fourth ceratobranchials, protracts the lower pharyngeal jaw.” (M&W: 614)

“Contraction of the rectus communis produces a bulge in the ventral side of the skull directly posterior to the position of the hyoid.” (M&W: 612)

The rectus communis is an intrinsic muscle of the ventral gill arches. It lies ventral to the ventral gill-arch elements and has no association with the ceratohyal (the “hyoid” of M&W and Nelson). As described by Nelson and S&J, when present in eels it extends from the proximal end of Cb4 to one or more hypobranchials. I concur with Nelson (Table 1) that there is no rectus communis in muraenids. There are, in fact, no hypobranchials in muraenines and no more than two in uropterygiines (Nelson, 1966: table 1, figs. 41–44). M&W (table 1) inexplicably equated the rectus communis with Nelson’s ventral retractor, a muscle described above under dorsal retractor and illustrated in Figure 4, because, as they proposed, it serves to move the pharyngeal jaws forward into the oral cavity. Thus, this muscle is a **protractor**, not a **retractor**. I can find no distinct, well-defined muscle bundle extending between the ceratohyal and the anteroventral margin of the lower pharyngeal toothplate (as described by

M&W: 613) or fourth ceratobranchial in muraenines. I have not examined very large specimens, and it is possible, though unlikely, that there is an ontogenetic component to the muscle M&W described. Unfortunately, no sizes or collection numbers were given for the specimens they examined.

The major muscle bundle in this region inserting on the ceratohyal is the sternohyoideus, but it originates posteriorly in the hypaxialis near the cleithrum, not on the lower pharyngeal toothplate and thus could not function to protract the pharyngeal jaws. However, as described above, there is a fan-like array of muscle fibers extending from the dorsal surface of the posterior portions of two or three ceratobranchials to the anterior and posterior ceratohyals. These lie dorsal to the ventral arch elements and represent Nelson's (fig. 10) subdivisions of the subpharyngealis (Figs. 7, 9; see also Springer and Johnson, 2015). As Nelson (362) described it, "Its position is distinctive, being internal to the skeletal elements rather than external as are the obliqui and recti. Probably the ventral musculature shifted from a relatively external to a relatively internal position with the reduction and loss of basibranchials. In any event, it assumed a sheetlike form, gradually encroaching upon the gill slits, which in the more advanced eels (e.g., the muraenids) are reduced to small round openings."

### Intrinsic gill-arch muscles

#### *Obliquus dorsalis (OD/OBL.DIV).*—(Fig. 2A)

"The obliquus dorsalis, which medially spans the joint between the fourth epibranchial and the fourth pharyngobranchial is well developed." (M&W: 610)

M&W (table 1) equated this muscle to Nelson's obliquus inferior and superior. However, Nelson (table 2) reported those muscles to be absent in muraenids, and, in any case, the inferior obliqui only interconnect epibranchials. As reported by Nelson there are no obliqui dorsales in muraenids. The muscle bundle labeled as such by M&W (OBL.DIV, fig. 2A) is actually the anterior continuation of the sphincter oesophagi/dorsal retractor (SO/DR in Figs. 3–6). M&W apparently did not see that continuity, which has possible implications for their functional interpretation. Although they illustrate this as separate from AD4 (their AD5), it is also possible that they misinterpreted the anterior portion of that muscle as part of their obliquus dorsalis (see Fig. 2B and below).

#### *Adductor dorsalis 4 (AD4).*—(Figs. 2–4, 7C)

"Adductor 5 is a very large muscle that originates on the posteromedial face of the fourth epibranchial and connects to the posterodorsal end of the fourth ceratobranchial." (M&W: 610)

M&W (table 1) equated this muscle to Nelson's obliquus posterior even though Nelson (table 2) reported this muscle as absent in muraenids. Adductors attach the epibranchials to the ceratobranchials of their corresponding arches, except, as described by S&J, "Ad5 attaches Cb5 variously to one or more of the following: Cb4, AC4, Eb4, or Eb5." As reported by Nelson (1966: table 1), Cb5 is absent in muraenids (lower pharyngeal toothplate 5 having been transferred to Cb4). Accordingly, the large adductor attaching dorsally to the fourth epibranchial attaches ventrally to the fourth ceratobranchial (as described by M&W) and is adductor 4, not

adductor 5. Nelson (tables 1–2, fig. 11) correctly reported AD5 (Fig. 2, Table 1) absent and AD4 present in muraenids. A very small portion of the fibers of AD4 bypass Eb4 to insert on the dorsal process of UPT.

### UROPTERYGIINAE

#### Figures 8–10

"There is no dorsal retractor that spans the posterior portion of the epibranchial and the vertebral column, suggesting that retraction of the jaws is accomplished primarily by the esophagus and the pharyngocleithralis [sic]." (M&W: 614)

M&W seem to have misinterpreted Nelson's terminology for the dorsal retractor (DR), stating that it is only present in muraenine eels. As Nelson reported, "Dorsal and ventral paired retractor muscles are present in all of the eels examined. In most forms they are only partly distinct subdivisions of the inner longitudinal muscle layer of the anterior esophagus. In eels of the subfamily Muraeninae, they acquire an attachment to the vertebral column." Thus, Nelson's dorsal retractor (comprising the longitudinal fibers of the sphincter oesophagi) is present in all eels (see also Springer and Johnson, 2015: 598). The distinction is that in muraenines these fibers emerge from the outer circular fibers of the sphincter oesophagi posteriorly to attach to the vertebral column, and in uropterygiines they do not.

"As in the muraenine condition, there is a single internal branchial levator, levator internus 4, that originates from the posterior part of the parasphenoid and inserts on the dorsal side of the fourth pharyngobranchial just anterior to the Pb4/Eb4 joint." (M&W: 613)

As described above, there is no fourth internal levator in any actinopterygian. This muscle is LI2, which, unlike in most muraenines, is represented by a single bundle in uropterygiines.

As in muraenines, uropterygiines have two internal levators. LI1 (overlooked by M&W) originates in the epaxialis and inserts on the anterior one-third of the dorsal surface of UPT. LI2 is represented by a single bundle (there are two in muraenines) that originates on the occipito/otic region of the braincase and inserts on the anterior end of UPT. I concur with Nelson's (fig. 9) interpretation of the insertion of these two muscles but not with his labeling of LI2 as the "protractor medialis" (his MP).

M&W did not recognize a major difference between muraenines and uropterygiines because they described muraenines as having LE4, an **external** levator that inserts on Eb4. Because that muscle actually inserts on UPT in muraenines, it is an **internal** levator. Ironically, uropterygiines have the muscle (LE4) M&W incorrectly attributed to muraenines. Nelson (table 2, 359, fig. 9) described and illustrated this muscle correctly, though he called it protractor posterior (his PP) rather than LE4.

The most conspicuous unrecognized difference between uropterygiines and muraenines is the presence of an additional muscle. Posterior to the gill-arch skeleton, a large oblong to trapezoidal muscle (first identified herein and described as hypaxial retractor, HR) originates within the hypaxialis in the vicinity of the cleithrum and inserts by a short tendon on the fourth epibranchial just above its articulation with the fourth ceratobranchial (Figs. 9, 10).

## FUNCTIONAL MECHANICS

I have no disagreements with M&W's descriptions of the movements of the muraenine pharyngeal apparatus, which they unambiguously documented with videofluoroscopy and high-speed video. As they showed, the anterior portion of the pharyngeal tooth plates can extend into the oral cavity to a point just below the middle of the orbit and be forcibly retracted to their resting position. However, given the inaccuracies in the anatomical details, the specific mechanics that effect these movements should be revisited.

Below are statements from M&W addressing the mechanics of pharyngeal jaw protrusion and retraction that I believe require reconsideration in light of the revised anatomical details. Problematic terms and/or insertion sites are bolded. Any proposed functional explanations are necessarily speculative.

### Muraeninae

"The attachment of the **levator externus 4 at a posterior (distal) location on the fourth epibranchial** facilitates the extreme jaw protraction distance observed in morays. Contraction of the **levator externus 4** pulls the **posterior portion of the epibranchial** toward its origin on the neurocranium" (M&W: 614) "The **upper pharyngobranchial and fourth epibranchial are protracted anterior to the origin of the levator externus 4**, resulting in the pharyngeal jaws protruding into the oral cavity." (M&W: 613, legend of fig. 9).

Because the muscle identified as LE4 is actually a posterior branch of LI2 and inserts on UPT rather than a posterior location on Eb4, protraction of the upper pharyngeal elements into the oral cavity is not facilitated by a direct pull on the posterior end of Eb4 (*Neomuraena* is exceptional). According to figures 1b and 4b and the supplemental videos of Mehta and Wainwright (2007a) and 7c of M&W, UPT is protruded forward to a point where its anterior half is directly below the orbit. Because the internal levators originate well posterior to the orbit and insert on UPT rather than the much more posterior end of Eb4 (Figs. 1, 7), their contraction can hardly explain such an extreme anterior extension of UPT. When UPT is positioned below the orbit, the insertions of both internal levators will necessarily be well forward of their point of origin on the braincase (see Mehta and Wainwright, 2007a: fig. 4b). The extreme anterior extension of UPT in muraenines is clearly documented in the videos, but the explanation for exactly how this is accomplished given by M&W should be reevaluated.

"As the upper pharyngobranchial is protracted further into the oral cavity, contraction of the **fourth levator internus** and **obliquus dorsalis dorsally rotate the upper pharyngobranchial at the Pb4/Eb4 joint.**" (M&W: 613) "Contraction of the **levator internus 4 positions the recurved teeth in an open orientation for ensnaring prey.**" (M&W: 614)

The muscle inserting on UPT that M&W called LI4 is instead the anterior branch of LI2. The inappropriate terminology does not affect the mechanics; however, there are actually two sections of LI2, one inserting anterodorsally and one posterodorsally on UPT. Accordingly, any rotation of UPT by the two muscles is probably more complex than

described by M&W. It would seem that the anterior branch would rotate UPT upward, whereas the posterior branch would rotate it downward. As for the obliquus dorsalis, it does not exist, so could have no role in rotating UPT.

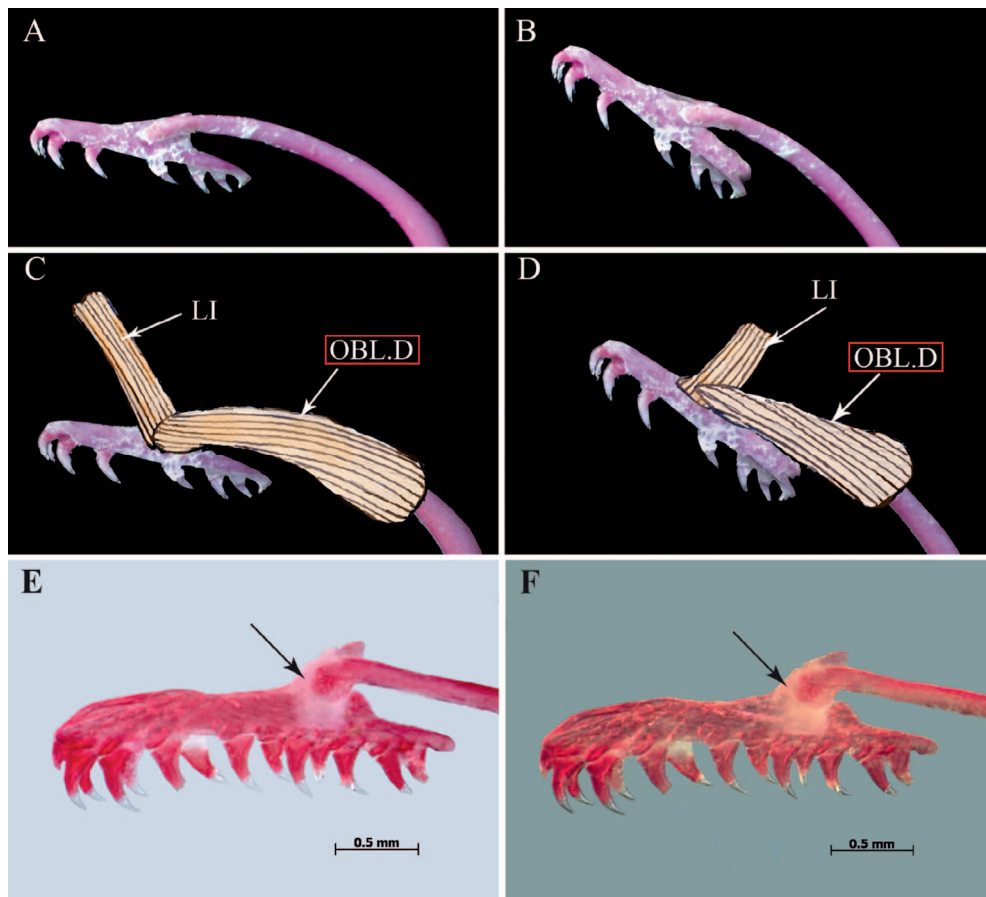
"In muraenines, there is a very elongate bundle of muscle fibers that runs from the posterior part of the **fourth epibranchial** to the ventral side of the vertebral column and attaches onto the 10th and 14th vertebrae. We call this muscle the dorsal retractor." (M&W: 610) "Contraction of the dorsal retractor retracts the upper pharyngeal jaw...." (M&W: 613)

The dorsal retractor actually inserts on UPT and thus retracts UPT by pulling backward on that element rather than Eb4. If DR inserted on Eb4 to retract UPT (the prey capture implement), the connection between those two elements would need to be very firm to prevent their separation during retraction. In the scenario of M&W, the UPT/Eb4 connection would be reinforced by the obliquus dorsalis 4, but there is no OD4. I was initially puzzled by this, because the only other reference to the UPT/Eb4 joint is to its flexibility, and their figure 4B, C (reproduced here in Fig. 11B, C) shows no connective tissue reinforcing it. Nonetheless, I accept that the movements described by M&W do occur. As shown in Figure 11E, F, there is indeed a strong connective tissue (ligamentous) bond between these two elements, this tissue apparently having been scraped off in M&W's figure and not discussed by them.

"The **rectus communis**, which connects the hyoid arch to the anteroventral margin of the fourth ceratobranchials, protracts the lower pharyngeal jaw." (M&W: 614) "Contraction of the **rectus communis** produces a bulge in the ventral side of the skull directly posterior to the position of the hyoid." (M&W: 612)

My observations agree with those of Nelson (348, table 1) that there is no rectus communis in muraenines. This is not surprising, as there are no hypobranchials, on which they typically insert. I surmise (as did Nelson: 363) that the muscle mass responsible for retracting the lower pharyngeal jaws consists of subdivisions of the subpharyngealis (particularly the larger one of the fourth arch), which originate on the posterior ends of ceratobranchials and terminate on the anterior and posterior ceratohyals (the "hyoid" or "hyoid arch" of Nelson and M&W). These muscles lie dorsal to the skeletal elements of the ventral arches (including the LPT), and the bulge in the ventral side of the skull described by M&W could presumably be produced by ventral depression of the anterior tip of LPT as the lower ceratobranchials are pulled forward from their posterior portions. Such a bulge would not result if the main protractive force originated at the tip of LPT.

Although I agree that this muscle plays an important role in protraction of the LPT, this would require that a substantial force be applied against the very thin ceratohyal, about which Mehta and Wainwright (2007b: 501) said, "the slender hyoid bar does not seem able to withstand the forces necessary to depress the ventral region of the buccal cavity....". I am not suggesting that an equivalent force is required to protract the pharyngeal jaws, but wonder why M&W did not refer to this potential conundrum. The role of this very slender ceratohyal in protraction of the pharyngeal jaws is discussed further in Functional Summary.



**Fig. 11.** Photographs of left medial view of alizarin-stained bone showing association between UPT and EB4. (A–D) *Muraena retifera*, with muscles and connective tissue removed, from figure 4 of Mehta and Wainwright (2008). (C, D) Muscles drawn in—modified, red boxes indicate misidentification of oblique dorsalis—there is no major muscle spanning the joint between Eb4 and UPT. Given the angle and point of insertion, the element labeled LI1 is probably LI1, a muscle otherwise not recognized, illustrated, or discussed by M&W. (E, F) *Gymnothorax pindae*, USNM 443783, 200 mm, arrows point to the strong connective tissue that binds the two elements together. LI, levator internus; OBL.D, oblique dorsalis.

Also missing from M&W's (612–613) Functional Interpretation is the action of the prominent, sling-like LI1 that originates in the epaxialis directly above UPT and inserts on the anterior portion of its dorsal surface midway along its length. This muscle, not seen or described by M&W, is unique among teleosts to several eel families. It undoubtedly plays a role in the mechanics of pharyngeal jaw movements in muraenid eels, and without it the scenario is incomplete. Because its resting position is directly above UPT, speculation on its role in protraction/retraction is challenging. One thing seems clear—it could not play the usual protractive role of an internal levator. Does it assist in widening the pharyngeal gape, retracting UPT, both, or have some other function?

### Uropterygiinae

“There is no dorsal retractor that spans the posterior portion of the epibranchial and the vertebral column, suggesting that retraction of the jaws is accomplished primarily by the esophagus and the pharyngocleithralis [sic].” (M&W: 614)

As described by Nelson, all eels have a dorsal retractor, but only in muraenines does it attach posteriorly to the vertebral column. This anchoring of DR posteriorly undoubtedly strengthens the retraction force of this muscle, and this makes sense for muraenines, given the exceptional protraction and retraction kinematics described by M&W. Because non-muraenid eels are not known to move the pharyngeal jaws in this extreme fashion, the lack of attachment of DR to the vertebral column seems reasonable. As M&W noted (614), both the esophagus and the pharyngocleithralis are

involved in pharyngeal-jaw retraction, but it seems that the longitudinal fibers of the sphincter oesophagi would not be as effective in extensive retraction of the UPT in uropterygiines as they are in muraenines without being anchored to the vertebral column. However, in uropterygiines retraction is further facilitated by the presence of an additional retractor (my hypaxial retractor, HR), not previously described, which, because of its more ventral position and insertion on the posterior end of Eb4, might function to retract the upper pharyngeal toothplate in a somewhat more ventral direction than the dorsal retractor of muraenines. In that case it would seem that it might tend to open the gape of the pharyngeal jaws wider at a time when it should be closing. It will be interesting to see what detailed functional analyses can tell us about the two quite different retraction mechanisms in muraenines and uropterygiines.

As for protraction, the insertion of an LE4 on the posterior end of Eb4 suggests that UPT could extend even farther into the oral cavity than in muraenines. Unfortunately, Mehta and Wainwright never had access to live uropterygiines to watch them feed. The same would seem to apply to *Neomuraena*, and perhaps future studies can address protraction in these taxa.

### Functional summary

Contrary to M&W, I suggest that there are three distinct mechanisms of protraction and retraction of the upper pharyngeal jaws involving dorsal gill-arch muscles in Muraenidae (the role of LI1 in all three remains unclear):

Muraeninae (except *Neomuraena*): Protraction is achieved by contraction of the two sections of LI2, which originate on

the occipito/otic region of the braincase and insert on the anterior and posterior ends of UPT, although this cannot fully explain its extreme protraction to a point ventral to the orbit documented by M&W. Retraction is achieved by contraction of the dorsal retractor, which originates on the vertebral column and inserts on UPT. *Rhinomuraena* is exceptional in that the dorsal retractor does not originate on the vertebral column.

*Neomuraena*: Protraction is achieved by contraction of LI2 and LE4, both of which originate on the occipito/otic region of the braincase. The former inserts on the anterior end of UPT, and the latter inserts on the posterior end of Eb4. Retraction is achieved as in Muraeninae. This anatomical distinction warrants consideration of elevation of the subgenus *Neomuraena* (Girard, 1859) to generic status. It is otherwise diagnosed by having three vs. four infraorbitals and comprises four species restricted to the western Atlantic (Böhlke et al., 1989).

Uropterygiinae: Protraction is achieved by contraction of LI2 and LE4 as in *Neomuraena*. Unlike muraenines, the dorsal retractor has no attachment to the vertebral column, but its effectiveness in retraction is augmented by contraction of the hypaxial retractor (HR), which originates in the hypaxialis and inserts on the posterior end of Eb4.

### Sternohyoideus

As documented and discussed by M&W, ventral flexion of the neurocranium in muraenids is an integral part of pharyngeal protraction. Their figure 7, based on videos, clearly shows that this occurs in the protraction phase. It is also obvious that there is considerable contraction along the horizontal axis (compare the position of the opercular opening in fig. 7A, D with the protraction phases, B–D). Exactly how this is accomplished is not entirely clear, but I suggest that it must involve the epaxialis, hypaxialis, and sternohyoideus. In their paper on biting in morays, Mehta and Wainwright (2007b: 500–501) found that feeding morays rely on directly biting prey rather than capturing it with suction, noting that the cleithrum and hyoid arch (by which they meant ceratohyal) are thin and flexible and that the latter does not seem strong enough to withstand strong forces such as that necessary to depress the ventral region of the oral cavity. Despite the obvious weakness of the ceratohyal, M&W proposed that it can withstand a force strong enough to protract the lower pharyngeal jaws, and I agree, though the muscle involved is the subpharyngealis, not the rectus communis. They also stated (498) that “The sternohyoideus is small compared to other teleosts and the fibers appear continuous with the hypaxialis.” The primary subject of their comparison was *Anguilla*, but they provided no quantification of the sternohyoideus mass, nor any comparative illustrations. Eagderi (2010) illustrated the sternohyoideus of several eels, including *Anguilla* and two muraenids, *Gymnothorax* (fig. 6.13c) and *Anarchias* (fig. 6.16c). Comparison of that of *Anguilla* (fig. 4.9d) with that of the two morays shows that the sternohyoideus is deeper posteriorly in the former, but also substantially shorter. It is undoubtedly more robust in *Anguilla* than in muraenids, but there are two additional notable differences.

First, as noted by Mehta and Wainwright (2007b: 498), unlike *Anguilla* and other eels, the muraenid sternohyoideus is essentially an extension of the hypaxialis and has little or no attachment to the extremely thin cleithrum. A more striking and undoubtedly functionally significant morpho-

logical difference is the absence of the urohyal, its normal site of attachment, in muraenids. The urohyal is not strictly part of the hyoid arch but an unpaired sesamoid ossification of the anterior tendon of the sternohyoideus (Arratia and Schultze, 1990). In most teleosts, it attaches by two short ligaments to the ventral hypophyals. Because eels lack hypophyals, the sternohyoideus attaches to the anterior tip of the anterior ceratohyals. Accordingly, contraction of the sternohyoideus generates a median posteroventral pull on the ceratohyals where they attach to the ventral gill arches, which are then also pulled in that direction. Absence of the urohyal in morays was not mentioned by Mehta and Wainwright (2007b), and their figure 1 confusingly labels both the urohyal in *Anguilla* and the anterior ceratohyals in the two morays “UH,” presumably urohyal, though the abbreviation of that given in the legend is “U.” Absence of the urohyal is, in fact, a unique apomorphy of muraenid eels, and would seem to be a critical feature in their feeding mechanics not considered by Mehta and Wainwright (2007b) or M&W. Unlike other eels, in the absence of the urohyal, the sternohyoideus inserts along the length of each ceratohyal (Fig. 7A, B; Eagderi, 2010: figs. 6.13c, 6.16c), and because the median elements of the ventral arches are absent those bones have no median point of attachment. Thus the effect of contraction of the sternohyoideus must be quite different. This muscle is often continuous posteriorly with the hypaxialis (Winterbottom, e.g., *Elops*, fig. 27), and its more extensive origin there in morays would not necessarily weaken its ability to retract the anteroventral elements of the head. However, its insertion on the reduced and free ceratohyals would certainly affect the way in which it does this compared to other eels. Documentation of horizontal contraction of this region by M&W is irrefutable, but further investigation is needed to identify the precise mechanics involved. Because contraction of the internal levators cannot alone explain the extreme protrusion of UPT (particularly in muraenines), understanding the role of the sternohyoideus (and subpharyngealis) is paramount.

### CONCLUSIONS

In a seminal contribution to our knowledge of moray eel feeding, Mehta and Wainwright (2007a) used high-speed video to demonstrate the extraordinary ability of muraenid eels to grasp and transport prey items a relatively long distance from the oral cavity into the esophagus, a feeding mode previously unknown among teleosts. The discovery of this exceptional feeding specialization and the descriptive anatomy supporting it received considerable press and has been widely incorporated into texts, online media, and classrooms internationally. A review article in *Nature* pointed to the importance of the fact that the authors backed up their exciting video observations with a detailed study of the relevant anatomy. M&W subsequently provided an even more detailed anatomical and functional description of the pharyngeal apparatus and its movements and promised to offer a unifying terminology for the muscles involved in protraction and retraction of the pharyngeal jaws in order to clarify purported confusion of the terminology used in earlier descriptions. As I have shown, most of the earlier descriptive details were accurate, and instead, I disagree with much of the anatomical description and terminology presented by M&W, suggesting, among other things, the need for the relevant

mechanical details to be reevaluated. It is my hope that my efforts will bring accuracy and clarification to the situation and be viewed in a positive light. Nonetheless, in view of the widespread acceptance of the accuracy of M&W's work, there is perhaps a cautionary message here for students and professionals alike. What matters most in comparative anatomy and systematics is examining and describing the specimens as carefully and in as much detail as possible. This is the most enduring contribution we make, and without a deep commitment to it what follows is irrevocably diminished. Accordingly, it remains critical for comparative (and functional) morphologists to be certain that their descriptions are as accurate as possible and that their homology argumentation is explicitly articulated. Peer reviewers and editors should require nothing less.

#### MATERIAL EXAMINED

The material used in this study is deposited in the following institutions: Academy of Natural Sciences (ANSP), National Museum of Natural History (USNM), Natural History Museum and Institute, Chiba, Japan (CBM). Measurements are given as total lengths (TL). All but three (cleared and stained, CS) are dissected double-stained specimens in 70% ethanol.

#### ANGUILLIDAE

*Anguilla marmorata*: USNM 191271, 200 mm.

*A. rostrata*: USNM 190998, 290 mm.

#### CHLOPSIDAE

*Kaupichthys diodontus*: USNM 141258, 105 mm.

#### CONGRIDAE

*Conger cinereus*: USNM 164209, 290 mm.

#### MURAENIDAE

##### Muraeninae

*Echidna nebulosa*: USNM 210919, 265 mm.

*E. polyzona*: USNM 380533, 175 mm.

*Enchelycore bayeri*: USNM 389575, 340 mm.

*Enchelynassa canina*: USNM 424097, 320 mm.

*Gymnomuraena zebra*: USNM 108847, 485 mm.

*Gymnothorax buroensis*: USNM 141541, 170 mm, CS.

*G. (Neomuraena) maderensis*: USNM 414867, 340 mm.

*G. margaritophorus*: USNM 337991, 210 mm.

*G. miliaris*: USNM 198756, 280 mm.

*G. (Neomuraena) nigromarginatus*: USNM 158738, 480 mm.

*G. (Neomuraena) ocellatus*: USNM 158957, 410 mm.

*G. pindae*: USNM 443783, 200 mm, CS.

*G. (Neomuraena) saxicola*: USNM 158720, 460 mm; USNM 443784, 365 mm.

*G. unicolor*: USNM 142975, 290 mm.

*G. zonipectis*: USNM 404563, 170 mm, CS.

*Monopenchelys acuta*: USNM 312842, 150 mm.

*Muraena argus*: USNM 318316, 250 mm.

*M. lentiginosa*: USNM 167919, 160 mm; USNM 318298, 170 mm, 210 mm, 290 mm.

*M. pavonia*: USNM 274346, 275 mm.

*M. retifera*: ANSP 103574, 165 mm; ANSP 107090, 360 mm; UF 77353, 420 mm.

*Pseudechidna brummeri*: USNM 377847, 590 mm.

*Rhinomuraena quaesita*: USNM 338049, 730 mm.

*Strophidon sathete*: USNM 217007, 620 mm; USNM 439115, 620 mm.

#### Uropterygiinae

*Anarchias seychellensis*: USNM 258981, 210 mm.

*Scuticaria tigrinus*: USNM 312866, 420 mm.

*Uropterygius alboguttatus*: USNM 338657, 310 mm, 340 mm, 350 mm.

*U. macrocephalus*: USNM 332404, 280 mm, USNM 352349, 240 mm.

*U. xanthopterus*: USNM 141656, 320 mm.

#### OPHICHTHIDAE

*Pisodonophis cancrivorus*: USNM 102489, 495 mm.

#### PROTANGUILLIDAE

*Protanguilla palau*: CBM 12279, 72 mm.

#### SIMENCHELYIDAE

*Simenchelys parasiticus*: USNM 031727, 180 mm.

#### SYNAPHOBRANCHIDAE

*Synaphobranchus affinis*: USNM 391167, 145 mm.

#### ACKNOWLEDGMENTS

W. D. Anderson, C. C. Baldwin, B. B. Collette, A. Datovo, V. Espindola, H. W. Greene, M. L. Habegger, P. Konstantinidis, R. W. McDiarmid, M. Pastana, N. Schnell, J. P. C. B. da Silva, W. F. Smith-Vaniz, and V. G. Springer read and provided valuable comments on all or parts of earlier drafts. R. Britz and W. E. Bemis offered valuable suggestions on parts of a later version. R. H. Robins, L. M. Page, M. H. Sabaj, and K. W.



Conway provided specimens. I also thank the entire staff of the NMNH fish collection for valuable assistance in selecting and transporting specimens. K. Murphy and J. Clayton were particularly helpful, and J. P. C. B. da Silva, M. Pastana, and V. Espindola provided valuable technical assistance and advice. A. Nonaka assisted in preparation of all illustrations and measurement of specimens. I especially want to express my sincere appreciation to R. Mehta, who was graciously cooperative and helpful throughout the course of my study and provided high-resolution versions of two of her published figures (see Figs. 2 and 11). She also provided valuable critical review of the manuscript as did Peter Wainwright, who also offered his own functional perspective on a couple of issues. In his role as Chief-Executive Editor of *Journal of Morphology*, Matthias Starck devoted considerable time and effort to handling submission and revisions of the manuscript. The manuscript benefitted substantially from comments and interactive argumentation with these three individuals and another reviewer, Kevin Conway. The costs of this study were funded in part by The Herbert R. and Evelyn Axelrod Chair for Systematic Ichthyology at NMNH.

#### LITERATURE CITED

- Arratia, G., and H-P. Schultze. 1990. The urohyal: development and homology within Osteichthyan. *Journal of Morphology* 203:247–282.
- Baudelot, E. 1868. Considérations relatives a la pièce scapulaire des silures. *Bulletin de la Société Sciences Naturelles de Strasbourg* 12:83–84.
- Betancur-R, R., E. O. Wiley, G. Arratia, A. Acero, N. Bailly, M. Miya, G. Lecointre, and G. Ortí. 2017. Phylogenetic classification of bony fishes. *BMC Evolutionary Biology* 17: 162.
- Böhlke, E. B., J. E. McCosker, and J. E. Böhlke. 1989. Family Muraenidae, p. 104–206. *In: Fishes of the Western North Atlantic*. E. B. Böhlke (ed.). Sears Foundation Marine Research, New Haven, Connecticut.
- Chen, J. N., J. A. López, S. Lavoué, M. Miya, and W. J. Chen. 2014. Phylogeny of the Elopomorpha (Teleostei): evidence from six nuclear and mitochondrial markers. *Molecular Phylogenetics and Evolution* 70:152–161.
- Datovo, A., and F. A. Bockmann. 2010. Dorsolateral head muscles of the catfish families Nematogenyidae and Trichomycteridae (Siluriformes: Loricarioidei): comparative anatomy and phylogenetic analysis. *Neotropical Ichthyology* 8:193–246.
- Datovo, A., M. C. de Pinna, and G. D. Johnson. 2014. The infrabranchial musculature and its bearing on the phylogeny of percomorph fishes (Osteichthyes: Teleostei). *PLoS ONE* 9:1–20.
- Datovo, A., and R. P. Vari. 2013. The adductor mandibulae muscle complex in lower teleostean fishes (Osteichthyes: Actinopterygii): comparative anatomy, synonymy, and phylogenetic implications. *Zoological Journal of the Linnean Society* 171:554–622.
- Eagderi, S. 2010. Structural diversity in the cranial musculoskeletal system in Anguilliformes: an evolutionary-morphological study. Unpubl. Ph.D. thesis, Ghent University, Ghent, Belgium.
- Filleul, A., and S. Lavoué. 2001. Basal teleosts and the question of elopomorph monophyly. *Morphological and molecular approaches*. *Comptes Rendus Academy of Sciences, Life Sciences* 324:393–399.
- Fricke, R., W. N. Eschmeyer, and R. van der Laan (Eds.). 2019. *Eschmeyer's Catalog of Fishes: Genera, Species, References*. California Academy of Sciences, San Francisco. <http://researcharchive.calacademy.org/research/ichthyology/catalog/fishcatmain.asp>
- Girard, C. 1859. Ichthyology. United States and Mexican Boundary Surveys. 2(2):1–85.
- Hulet, W. H. 1978. Structure and functional development of the eel leptocephalus *Ariosoma balearicum* (De La Roche, 1809). *Philosophical Transactions of the Royal Society of London. Series B, Biological Sciences* 282:107–138.
- Johnson, G. D. 1992. Monophyly of the euteleostean clades: Neoteleostei, Eurypterygii, and Ctenosquamata. *Copeia* 1992:8–25.
- Johnson, G. D., H. Ida, J. Sakaue, T. Sado, T. Asahida, and M. Miya. 2012. A 'living fossil' eel (Anguilliformes: Protanguillidae, fam. nov.) from an undersea cave in Palau. *Proceedings of the Royal Society Biology* 279:934–943.
- Konstantinidis, P., and G. D. Johnson. 2016. Osteology of the telescopefishes of the genus *Gigantura* (Brauer, 1901), Teleostei: Aulopiformes. *Zoological Journal of the Linnean Society London* 179:338–353.
- Mehta, R. S., and P. C. Wainwright. 2007a. Raptorial pharyngeal jaws help moray eels swallow large prey. *Nature* 449:79–82.
- Mehta, R. S., and P. C. Wainwright. 2007b. Biting releases constraints on moray eel feeding kinematics. *Journal of Experimental Biology* 210:495–504.
- Mehta, R. S., and P. C. Wainwright. 2008. Functional morphology of the pharyngeal jaw apparatus in moray eels. *Journal of Morphology* 269:604–619.
- Nelson, G. J. 1966. Gill arches of teleostean fishes of the order Anguilliformes. *Pacific Science* 20:391–408.
- Nelson, G. J. 1967. Branchial muscles in representatives of five eel families. *Pacific Science* 21:348–363.
- Nelson, G. J. 1968. Gill arches and the phylogeny of fishes: with notes on the classification of vertebrates. *Bulletin of the American Museum of Natural History* 141:477–552.
- Rosen, D. E. 1973. Interrelationships of higher euteleostean fishes. *Zoological Journal of the Linnean Society London* 53:397–513.
- Schnell, N., and G. D. Johnson. 2012. Ontogenetic fusion of the third and fourth pharyngobranchial in barbeled dragonfishes (Stomiidae, Teleostei) with a revision of the identity of the single posterior upper pharyngeal toothplate. *Copeia* 2012:394–407.
- Smith, D. G. 1984. Elopiformes. Notacanthiformes and Anguilliformes: relationships, p. 94–102. *In: Ontogeny and Systematics of Fishes*. H. G. Moser, W. J. Richards, D. M. Cohen, M. P. Fahay, A. W. Kendall, Jr., and S. L. Richardson (eds.). American Society of Ichthyologists and Herpetologists, Special Publication 1, Allen Press, Lawrence, Kansas.
- Springer, V. G., and G. D. Johnson. 2000. Use and advantages of ethanol solution of alizarin red S dye for staining bone in fishes. *Copeia* 2000:300–301.
- Springer, V. G., and G. D. Johnson. 2004. Study of the dorsal gill-arch musculature of teleostome fishes, with special reference to the Actinopterygii. *Bulletin of the Biological Society of Washington* 11:1–260.
- Springer, V. G., and G. D. Johnson. 2015. The gill-arch musculature of *Protanguilla*, the morphologically most primitive eel (Teleostei: Anguilliformes), compared with that of other putatively primitive extant eels and other elopomorphs. *Copeia* 103:595–620.

- Stiassny, M. L. J.** 1996. Basal ctenosquamate relationships and interrelationships of the myctophiform (scopelomorph) fishes, p. 405–426. *In*: Interrelationships of Fishes. M. L. J. Stiassny, L. R. Parenti, and G. D. Johnson (eds.). Academic Press, San Diego, California.
- Tang, K., and C. Fielitz.** 2013. Phylogeny of moray eels (Anguilliformes: Muraenidae), with a revised classification of true eels (Teleostei: Elopomorpha: Anguilliformes). *Mitochondrial DNA* 24:55–66.
- Winterbottom, R.** 1974. A descriptive synonymy of the striated muscles of the Teleostei. *Proceedings of the Academy of Natural Sciences of Philadelphia* 25:225–317.