



First description of oesophageal melanoma in a cat and palliative treatment by endoscopic argon plasma coagulation laser

Authors: Ferriani, Riccardo, Pagano, Teresa Bruna, and Bottero, Enrico

Source: Journal of Feline Medicine and Surgery Open Reports, 10(2)

Published By: SAGE Publishing

URL: <https://doi.org/10.1177/20551169241277076>



First description of oesophageal melanoma in a cat and palliative treatment by endoscopic argon plasma coagulation laser

Journal of Feline Medicine and Surgery Open Reports
1–7

© The Author(s) 2024

Article reuse guidelines:

sagepub.com/journals-permissions

DOI: 10.1177/20551169241277076

journals.sagepub.com/home/jfmsopenreports

This paper was handled and processed by the European Editorial Office (ISFM) for publication in *JFMS Open Reports*



Riccardo Ferriani^{1,2} , Teresa Bruna Pagano³ and Enrico Bottero^{1,2,3}

Abstract

Case summary An 11-year-old castrated male domestic shorthair cat presented with chronic regurgitation and weight loss. Despite a 2-month history of weight loss, regurgitation intensified over 4 weeks, occurring with every food intake, even on a semi-liquid diet. Physical examination revealed thinness and dehydration, and a focal oval mass was noted in the middle mediastinum on thoracic radiography. Oesophagoscopy identified a 6 cm neof ormation almost completely obstructing the oesophageal lumen. Biopsies were taken and histopathology, positivity to melanoma triple cocktail and PNL-2 by immunohistochemistry led to the diagnosis of melanocytic neoplasm. Palliative debulking with argon plasma coagulation (APC) was performed, significantly improving the cat's quality of life for 2 months. The cat survived for 107 days after diagnosis.

Relevance and novel information This case report describes the first report of melanocytic neoplasia originating from the oesophageal mucosa in a cat. In cats, melanomas outside the eyes are exceedingly rare and oesophageal neoplasms are exceptionally rare in veterinary medicine, particularly melanomas. The diagnosis relied on positive immunohistochemistry markers aligning with previous research. Treatment with APC emerged as a novel, potentially palliative approach, successfully alleviating regurgitation for 3 months. This underscores APC's potential in feline oesophageal neoplasia palliative care, which deserves further investigation in a broader feline cohort to confirm its efficacy. Overall, this report provides valuable insights into the diagnosis and treatment of oesophageal melanoma in cats.

Keywords: Regurgitation; non-ocular melanoma; argon plasma coagulation; palliative

Accepted: 6 August 2024

Case description

An 11-year-old castrated male domestic shorthair cat was referred for worsening chronic regurgitation and weight loss. The cat had a 2-month history of weight loss and had begun regurgitating 4 weeks prior to referral. According to the owner's report, the patient regurgitated with each food intake, even on a semi-liquid diet. On general examination, the cat was thin (body condition score of 2/5), weighing 4 kg, and was estimated to be 5% dehydrated. A small subcutaneous mass (previously diagnosed as a lipoma by cytology) was present in the ventral abdominal region.

Complete blood cell count and serum biochemical analyses were unremarkable. Thoracic radiography revealed a focal oval area of soft tissue radiopacity in the dorsal portion of the middle mediastinum, dorsal to the cardiac area

¹Associazione Professionale Endovet, Rome, Italy

²Ospedale Veterinario San Francesco, Milano, Italy

³MyLav Laboratorio La Vallonea Passirana di Rho, Rho, Italy

Corresponding author:

Riccardo Ferriani DVM, Associazione Professionale Endovet, Via Amedeo d'Aosta 7, Rome 20129, Italy
Email: riccardo.ferriani@libero.it



Creative Commons Non Commercial CC BY-NC: This article is distributed under the terms of the Creative Commons

Attribution-NonCommercial 4.0 License (<https://creativecommons.org/licenses/by-nc/4.0/>) which permits non-commercial use, reproduction and distribution of the work without further permission provided the original work is attributed as specified on the SAGE and Open Access pages (<https://us.sagepub.com/en-us/nam/open-access-at-sage>).

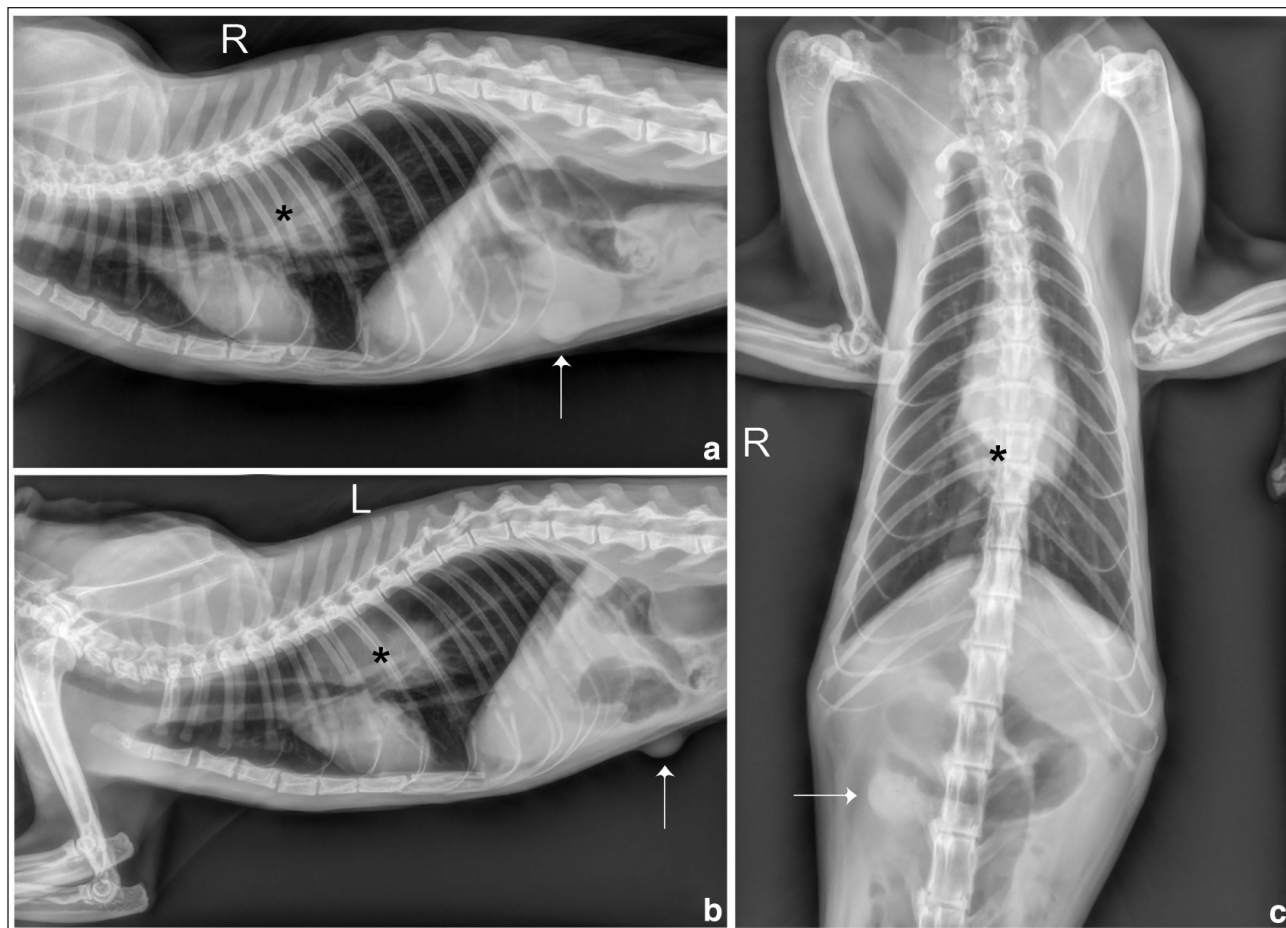


Figure 1 (a) Right laterolateral (LL) projection, (b) left LL projection and (c) ventrodorsal (VD) projection. Neof ormation in the mid-dorsal mediastinum, at the level of the oesophageal projection showing soft tissue radiopacity. There is a slight impression and ventral displacement of the cardiac silhouette and tracheal bifurcation, with thickening of the mediastinal profile in the VD projection (c). The neof ormation is marked by a black asterisk in each projection. Soft tissue neof ormation in the mid-right abdominal wall (indicated by a white arrow in each projection) is consistent with the already known lipoma

(Figure 1). Differential diagnoses included oesophageal neoplasm or oesophageal foreign body; or less likely differential diagnoses were tracheobronchial lymphadenopathy or neoplasm of the thoracic hypoaxial muscles.

After premedication with methadone 0.2 mg/kg IM and dexmedetomidine 3 µg/kg, general anaesthesia was induced with intravenous propofol and maintained with isoflurane for an oesophagoscopy (EG-L580N; Fujinon), which revealed a lesion 10 cm from the upper oesophageal sphincter, almost completely obstructing the oesophageal lumen (Figure 2). The extension of the mass was estimated to be 6 cm in length, and leaving 1 cm of free oesophageal lumen preventing the progression of the endoscope over the stricture (Figure 2a,b). Several biopsy samples were taken. The histological examination was consistent with a non-differentiated neoplasia and revealed a neoplastic population arranged in a sheet-like pattern with sparse fibrovascular stroma. The cells were round and exhibited wide eosinophilic cytoplasm, sometimes vacuolated, and

central or paracentral round nuclei, occasionally with a prominent central nucleolus (Figure 3a). On immunohistochemistry, neoplastic cells were diffusely positive to melanoma triple cocktail (MTC) (Figure 3b) and PLN-2 (Figure 3c), and negative to pancytokeratin monoclonal antibodies, confirming a melanocytic neoplasia. A CT scan was recommended to investigate the extension of the neoplasia and to possibly plan radiotherapy, but the owner temporarily chose not to proceed with further investigations.

To improve the patient's quality of life, a palliative debulking treatment of the neoplasia with argon plasma coagulation (APC) laser (ERBOTOM ICC 350; AMCO) was performed.

After anaesthetising the cat with the same protocol described above and positioning it on its left side, operative endoscopy was performed. With the tip of the endoscope placed in front of the neof ormation, the APC circumferential-fire probe was brought out of

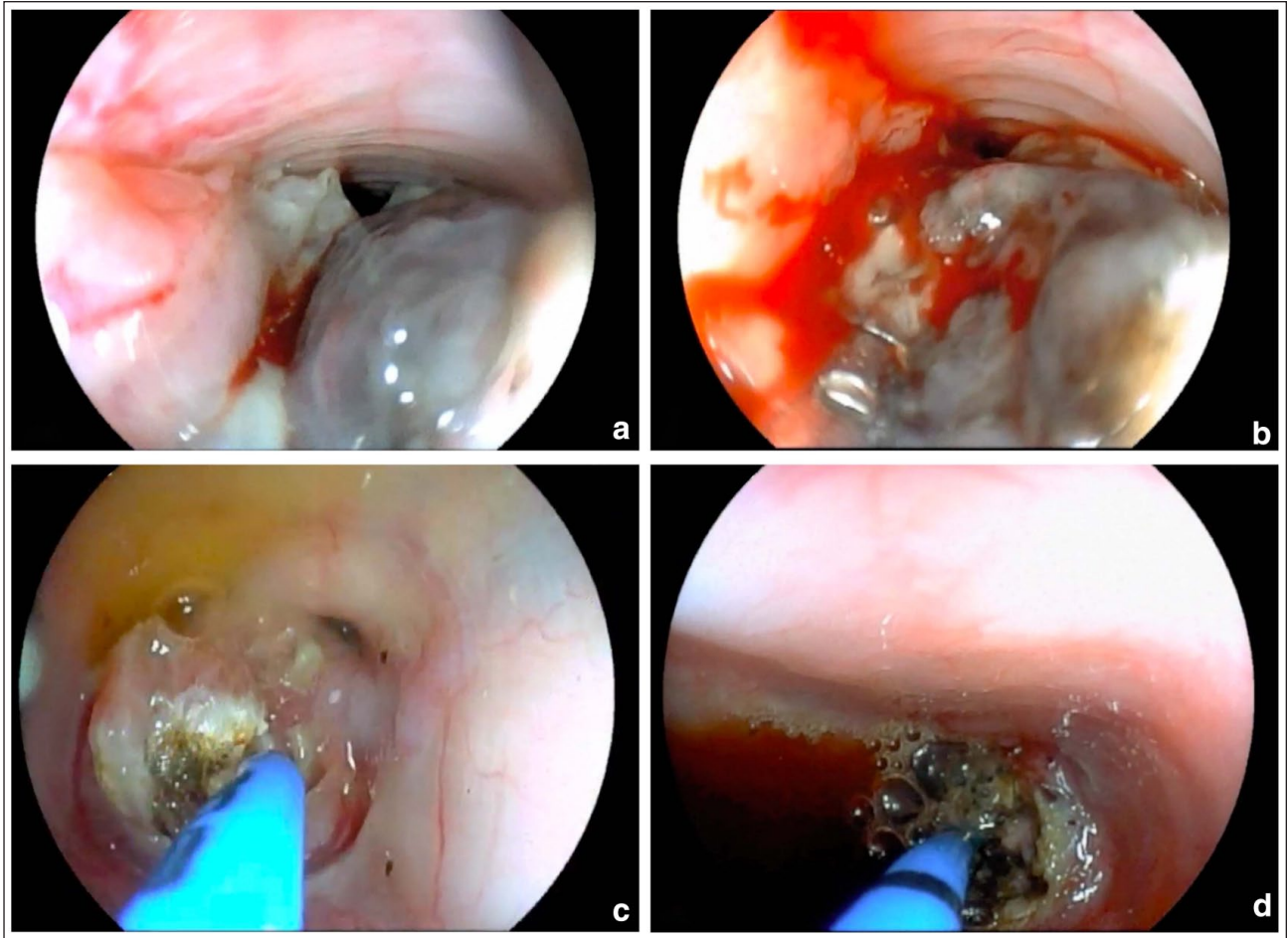


Figure 2 The oesophagoscopy revealed (a) the presence of a pigmented neoplasm located 10 cm from the upper oesophageal sphincter, (b) bleeding after sampling for histopathology. (c,d) Operative endoscopy with argon plasma coagulation was performed and pictures show the coagulation process

the working channel and used both in direct contact and at 2–4 mm from the lesion and haemostasis and cauterisation were performed (Figure 2c,d). APC was utilised at an argon flow rate of 1 l/min and high frequency power of 50–60 W with the spray coagulation mode as previously described.¹ It was applied in bursts of 0.5–2 s until the entire surface of the neoplasm appeared as a coagulum. Subsequently, the burned tissue was removed using a coaxial forceps inserted alongside the endoscope and manoeuvred under direct vision. The technique, previously described for the removal of nasal polyposis in dogs,² was alternated with washings using NaCl 0.9%, released through the working channel of the endoscope, followed by subsequent suctioning with an aspirator connected to the endoscope. The procedure lasted a total of 80 mins, and despite incomplete tumour removal, the oesophageal lumen was freed from the obstruction for at least three-quarters of its diameter, allowing the endoscope to enter the caudal oesophageal portion, granting

access to the stomach. No immediate medical complications were registered. The day after the procedure, the cat ate heartily without regurgitation. A medical therapy consisting of amoxicillin–clavulanic acid (12.5 mg/kg PO q12h) for 10 days and prednisolone (0.5 mg/kg PO q24h) for 5 days was administered.

Two months later, the cat was referred because of the recurrence of regurgitation and the presence of an extensive, firm and unpainful subcutaneous mass in the left thoracic paravertebral area. A CT scan was then performed, confirming the presence of an expansive round sharp-edged, asymmetric and concentric (7.3 × 4.4 × 3.9 cm) oesophageal neoplasm. A second round, eccentric and asymmetric neoplasm of 2 mm diameter was reported in between the thickness of the cranial portion of the oesophageal wall. A third oval-shaped neoplasm (7 × 5.8 × 4.4 cm) was detected in the paravertebral soft tissues of the left cranial lumbar region. This lesion likely pertained to longissimus lumborum muscles,

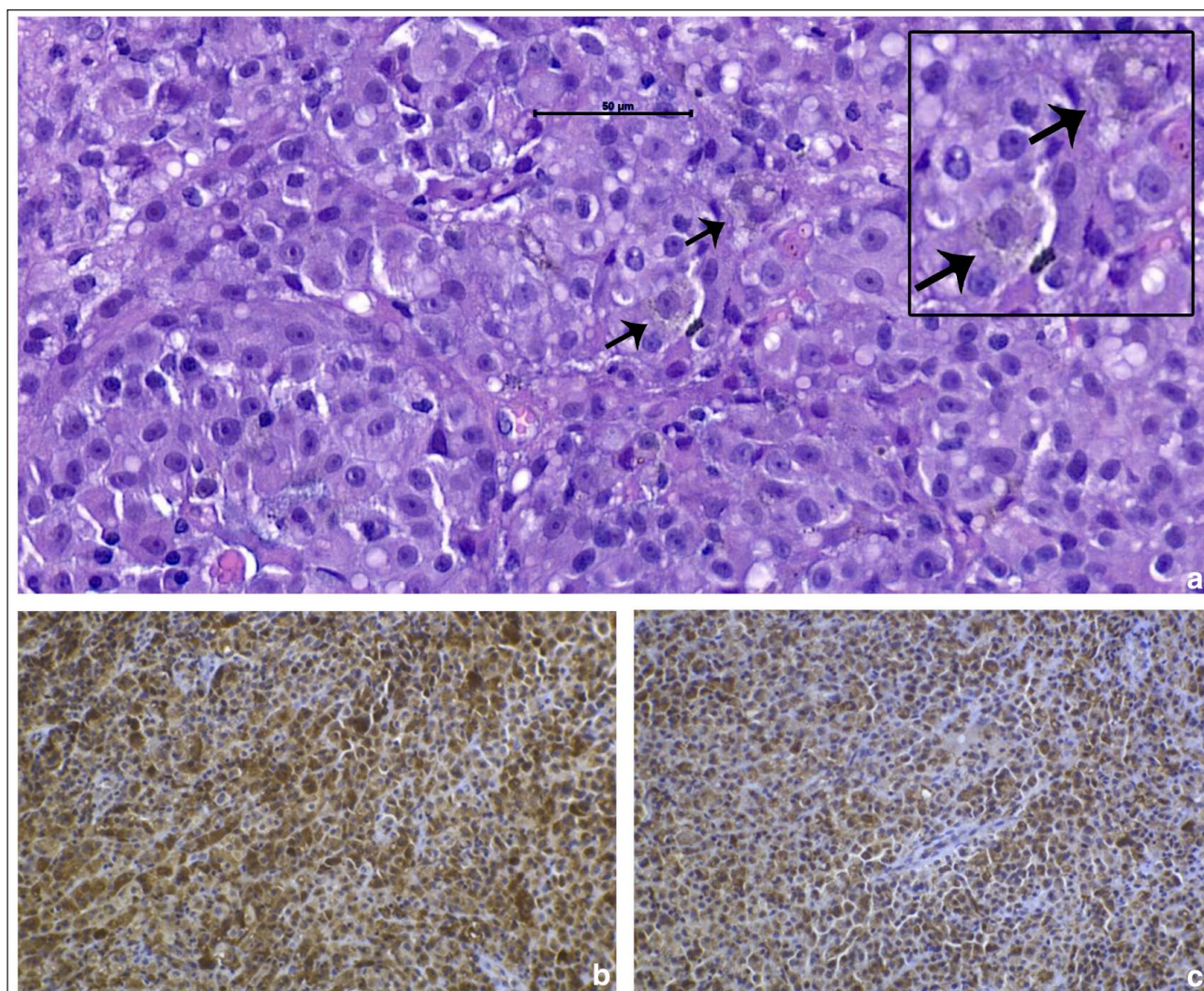


Figure 3 (a) Round to globose neoplastic cells with pale/vacuolised cytoplasm and round nuclei with one central nucleolus. Note rare pigmented cells (arrows). The inset outlined in black shows a magnified detail of the two cells marked with arrows. Haematoxylin and eosin, $\times 40$. Immunohistochemistry shows neoplastic cells displaying a diffuse, cytoplasmatic positivity to (b) melanoma triple cocktail and (c) PNL-2 markers

extending from T12 to L5. A fourth lesion ($4.3 \times 3.3 \times 2$ cm) was identified in the left ventrolateral abdominothoracic wall (Figure 4).

Fine-needle aspirations from all lesions revealed rounded and cuboidal cells in which the cytoplasm occasionally contained fine blackish granulations, obscuring nuclear details consistent with recurrent of oesophageal neoplasia and metastases. The owner declined further treatment, and the cat's condition progressively worsened leading to euthanasia 107 days after the diagnosis.

Discussion

This case report describes the occurrence of melanocytic neoplasia of the oesophageal mucosa in a cat. Oesophageal neoplasias are very rare in veterinary medicine, accounting for less than 0.5% of all neoplasms in dogs

and cats.³ Feline oesophageal cancer is typically characterised by squamous cell carcinoma, usually in cats aged over 7 years and often in non-purebred individuals.⁴⁻⁷

In the veterinary literature, clinical signs associated with oesophageal tumours are often insidious and non-specific.⁶ Our cat presented with chronic regurgitation and weight loss, which is consistent with signs frequently reported, while signs such as vomiting, dysphagia, hypotension, or fever and tachypnoea related to aspiration pneumonia, or rarely bradycardia, are also reported.⁴⁻⁷

The suspicion of melanocytic neoplasia arose from the round aspect of the cells with central nuclei while the definitive diagnosis of melanocytic neoplasia was reached thanks to positive immunohistochemistry markers MTC and PNL-2. This is in line with a study by

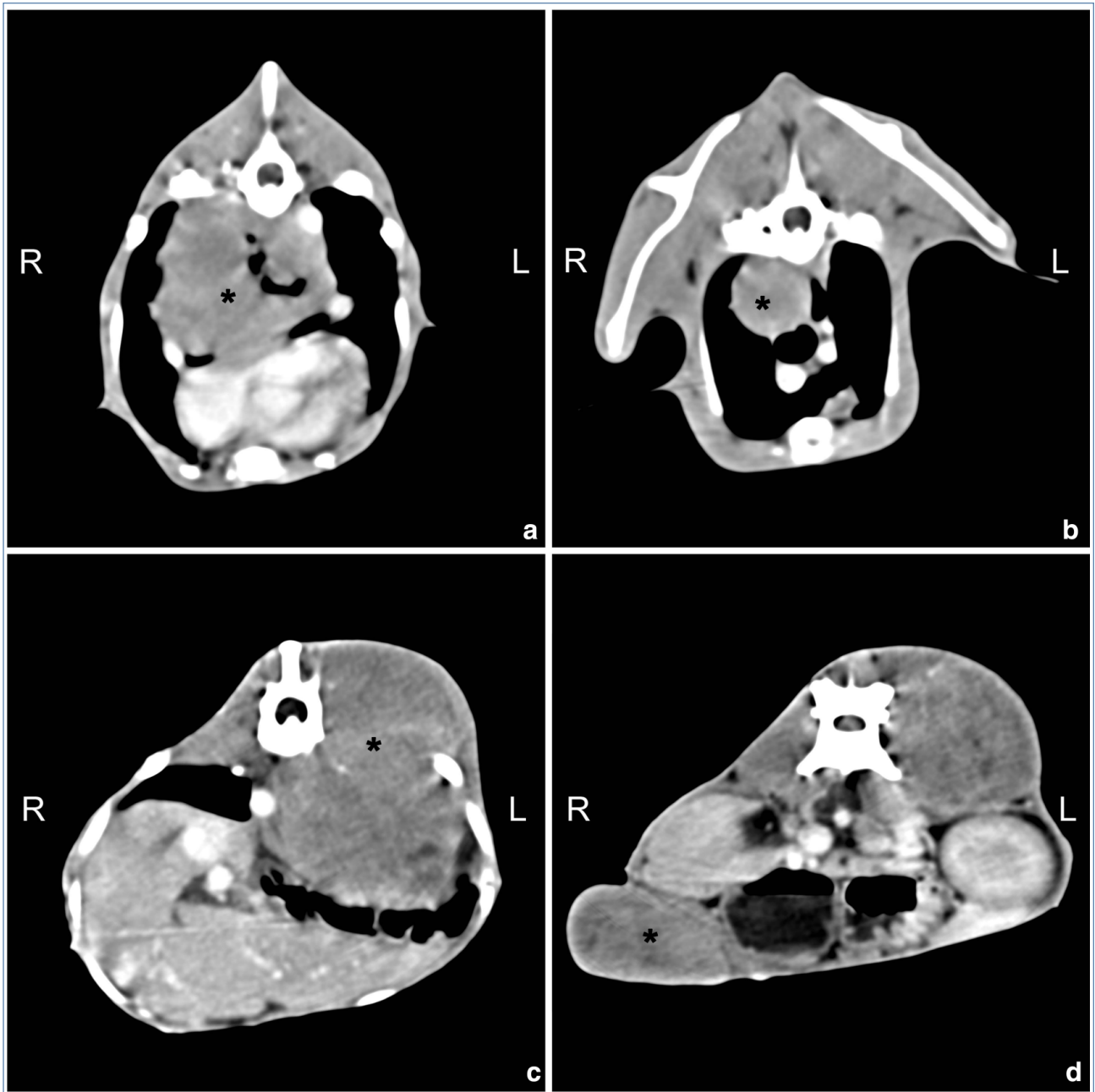


Figure 4 Images obtained through post-contrast-enhanced CT are presented. (a) Expansive, asymmetric, concentric and obliterating oesophageal neoplasia; (b) round, eccentric and asymmetric neof ormation of the cranial portion of the oesophageal wall; (c) expansive heterogeneous round lesion of the paravertebral soft tissues; (d) neof ormation of the left ventrolateral abdominothoracic wall. Each neof ormation is marked by a black asterisk in each image.

Pittaway et al,⁸ where these stainings were established as sensitive markers for feline non-ocular melanocytic neoplasms. Melanomas are uncommon tumours across species and they usually manifest in the skin, mucosal surfaces, eyes or leptomeninges;⁹ intraocular melanoma is more prevalent in cats.^{9–11} Nevertheless, feline melanomas outside the eyes are exceedingly rare. A

retrospective study from 1991 to 1999 identified only 23 non-ocular feline melanomas.¹² Furthermore, a recent retrospective study described the presentation of feline oral melanoma in 20 cats between 2014 and 2022.¹³ To the best of our knowledge, this is the first case report of primary oesophageal melanoma in a cat. The age of the

patient aligned with the mean age of non-ocular melanomas in cats, which is approximately 11–14 years.^{9,13}

In the present case, despite the absence of advanced diagnostic studies at the time of diagnosis, we hypothesised that the oesophagus was the primary site of the lesion. This hypothesis was based on the cat's presentation with regurgitation, the lack of pulmonary or soft tissue involvement observed in the initial chest radiographs and the absence of subcutaneous or ocular masses (except for the lipoma) during the initial physical examination. Three metastases were identified in the CT examination, consistent with previous reports, indicating aggressive local behaviour and high dissemination risk in cats with non-ocular melanomas.^{8,9} The cat in the present report survived 107 days from diagnosis, while a median survival of 83 days has been reported in a study among cats with melanocytic tumours in the oral cavity, lips or nose.⁸

Primary malignant melanoma of the oesophagus (PMME) is an extraordinarily rare entity in humans, comprising only 0.1–0.2% of all malignant oesophageal tumours and 0.5% of all non-cutaneous melanomas, with an estimated yearly incidence of 3.6 cases per million.¹⁴ In human medicine, surgical treatment is the primary option for PMME, with subtotal oesophago-gastrostomy performed in 77.6% of patients in one study.¹⁴ Non-surgical approaches may be considered owing to factors such as patients being in an extremely poor condition, unresectable tumours or the presence of distant metastases.¹⁴

Surgery and radiation therapy have traditionally been the main treatments for malignant melanoma in dogs and cats, though no gold standard therapy exists.¹² Other described therapeutic approaches include radiation therapy, surgery combined with chemotherapy, radiation therapy coupled with chemotherapy¹² or, in one case, electrochemotherapy.¹⁵ In addition, a xerogenic human tyrosinase DNA vaccine was explored for treating feline melanoma in one study.¹⁶

In the present case, the decision was made to pursue treatment with APC to enhance the cat's quality of life owing to the owners' non-acceptance of other available options. Laser therapy is commonly employed in human medicine, with National Comprehensive Cancer Network guidelines recommending palliative therapy for patients with unresectable oesophageal or gastric cancer.¹⁷ APC is locally applied to the tumour surface, utilising ionised argon gas for a non-contact thermal technique that delivers a monopolar high-frequency current, effectively coagulating tissue.¹⁸ The benefits of APC include limited tissue penetration depth, uniform coagulation, and minimal smoke or vapour production, making it suitable for diffuse bleeding, tumours and adenomatous tissue treatment.¹⁹ In a study

involving 83 individuals with inoperable oesophageal or cardia carcinoma, APC achieved adequate oesophageal lumen recanalisation in 58% with one treatment session, 26% required two treatments and the treatment failed in 16%.²⁰ After treatment, patients were allowed to resume fluid and normal food intake either on the same evening or the next morning.²⁰ Notably, the present patient experienced a rapid return to effective eating post-debulking, proving that treatment with this method could be crucial in alleviating signs, especially in instances of regurgitation.

Although we observed no adverse effects, reported complications in humans are oesophageal perforation with an incidence of 1–2%,²⁰ oro-oesophageal stricture, bleeding, chest pain, dysphagia and odynophagia.¹⁸ A limitation of APC in human applications is its suitability only for thin tumours since APC has a limited coagulation penetration depth of a few millimetres.²¹ In the present, the large size of the neoplasm and difficulty in discerning the border between the neoplasm and the oesophageal wall necessitated a partial debulking. This procedure aimed at facilitating food transit rather than complete tumour removal.

APC application in dogs has been seldom documented and has not been reported in cats, likely due to the 2.3 mm size of the circumferential-fire probe, which limits its use to large endoscopes. However, in the present case, the patient's size and the oesophageal localisation permitted its use. Notably, successful applications in dogs include treating medical refractory colorectal polyps in a neutered miniature Dachshund,¹ managing gastric polyps in two dogs²² and treating angiodysplasia in another dog.¹⁹

To the best of our knowledge, this report is the first to describe the use of endoscopic-assisted APC for palliative treatment of oesophageal melanoma in a cat. Because of the limited literature, both the APC setting and mode of use, as well as the operating technique, were developed by the authors. This study's limitation lies in the potential impact of these unique parameters on results. In the present case, APC effectively alleviated regurgitation for 3 months, suggesting its potential for inclusion in the palliative treatment arsenal for feline oesophageal neoplasia. Further evaluation in a larger feline cohort is necessary to ascertain efficacy, however.

Conclusions

Melanoma should be listed in the differential diagnoses of oesophageal neoplasia. Palliative endoscopic debulking with APC therapy appears to be a safe option, enhancing the quality of life for affected patients.

Acknowledgements The authors would like to thank Dr Giovanni Pastorino for his help in radiographic and CT

interpretation. We appreciate the technical laboratory assistance of Filippo Arena.

Conflict of interest The authors declared no potential conflicts of interest with respect to the research, authorship, and/or publication of this article.

Funding The authors received no financial support for the research, authorship, and/or publication of this article.

Ethical approval The work described in this manuscript involved the use of non-experimental (owned or unowned) animals. Established internationally recognised high standards ('best practice') of veterinary clinical care for the individual patient were always followed and/or this work involved the use of cadavers. Ethical approval from a committee was therefore not specifically required for publication in *JFMS Open Reports*. Although not required, where ethical approval was still obtained, it is stated in the manuscript.

Informed consent Informed consent (verbal or written) was obtained from the owner or legal custodian of all animal(s) described in this work (experimental or non-experimental animals, including cadavers, tissues and samples) for all procedure(s) undertaken (prospective or retrospective studies). No animals or people are identifiable within this publication, and therefore additional informed consent for publication was not required.

ORCID iD Riccardo Ferriani  <https://orcid.org/0000-0002-8862-5317>

References

- 1 Tsukamoto A, Ohno K, Irie M, et al. **A case of canine multiple inflammatory colorectal polyps treated by endoscopic polypectomy and argon plasma coagulation.** *J Vet Med Sci* 2012; 74: 503–506.
- 2 Bottero E, Mussi E, Raponi F, et al. **Diagnosis and outcome of nasal polyposis in 23 dogs treated medically or by endoscopic debridement.** *Can Vet J* 2021; 62: 736–742.
- 3 Amsellem PM and Farese JP. **Esophageal tumors.** In: Vail DM, Thamm DH and Liptak JM (eds). *Withrow and MacEwen's small animal clinical oncology*. 6th ed. Edinburgh: Elsevier, 2020, pp 449–451.
- 4 Gualtieri M, Monzeglio MG and Giancamillo MD. **Oesophageal squamous cell carcinoma in two cats.** *J Small Anim Pract* 1999; 40: 79–83.
- 5 Berube D, Scott-Moncrieff JC, Rohleder J, et al. **Primary esophageal squamous cell carcinoma in a cat.** *J Am Anim Hosp Assoc* 2009; 45: 291–295.
- 6 Frowde PE, Battersby IA, Whitley NT, et al. **Oesophageal disease in 33 cats.** *J Feline Med Surg* 2011; 13: 564–569.
- 7 Denooux P, Hugonnard M and Krafft E. **Primary oesophageal squamous cell carcinoma in a cat with bradycardia and ionised hypercalcaemia.** *Vet Rec Case Rep* 2019; 7 DOI: 10.1136/vetreccr-2019-000849.
- 8 Pittaway R, Dobromylskyj MJ, Erles K, et al. **Nonocular melanocytic neoplasia in cats: characterization and proposal of a histologic classification scheme to more accurately predict clinical outcome.** *Vet Pathol* 2019; 56: 868–877.
- 9 Van Der Weyden L, Brenn T, Patton EE, et al. **Spontaneously occurring melanoma in animals and their relevance to human melanoma.** *J Pathol* 2020; 252: 4–21.
- 10 Kayes D and Blacklock B. **Feline uveal melanoma review: our current understanding and recent research advances.** *Vet Sci* 2022; 9: 46.
- 11 Grahn B. **Feline glaucoma.** *Vet Clin North Am Small Anim Pract* 2023; 53: 367–387.
- 12 Luna LD, Higginbotham ML, Henry CJ, et al. **Feline non-ocular melanoma: a retrospective study of 23 cases (1991–1999).** *J Feline Med Surg* 2000; 2: 173–181.
- 13 Briggs A, Bell C and Greenfield B. **Feline oral melanoma—a retrospective study in 20 cats and case report.** *J Vet Dent* 2023; 40: 347–357.
- 14 Wang X, Kong Y, Chi Z, et al. **Primary malignant melanoma of the esophagus: a retrospective analysis of clinical features, management, and survival of 76 patients.** *Thorax Cancer* 2019; 10: 950–956.
- 15 Little A and Macfarlane M. **Electrochemotherapy as a treatment option for feline nasal melanoma.** *JFMS Open Rep* 2022; 8. DOI: 10.1177/20551169221074231.
- 16 Sarbu L, Kitchell BE and Bergman PJ. **Safety of administering the canine melanoma DNA vaccine (Oncept) to cats with malignant melanoma – a retrospective study.** *J Feline Med Surg* 2017; 19: 224–230.
- 17 Halpern AL and McCarter MD. **Palliative management of gastric and esophageal cancer.** *Surg Clin North Am* 2019; 99: 555–569.
- 18 Dumot J and Greenwald B. **Argon plasma coagulation, bipolar cautery, and cryotherapy: ABC's of ablative techniques.** *Endoscopy* 2008; 40: 1026–1032.
- 19 Harris AN, Armentano RA, Torres AR, et al. **Use of endoscopic-assisted argon plasma coagulation for the treatment of colonic vascular ectasia (angiodyplasia) in an adult dog.** *J Am Vet Med Assoc* 2016; 248: 526–531.
- 20 Heindorff H, Wøjdemann M and Bisg T. **Endoscopic palliation of inoperable cancer of the oesophagus or cardia by argon electrocoagulation.** *Scand J Gastroenterol* 1998; 33: 21–23.
- 21 Mocanu A, Bârla R, Hoara P, et al. **Endoscopic palliation of advanced esophageal cancer.** *J Med Life* 2015; 8: 193–201.
- 22 Teshima T, Matsumoto H, Michishita M, et al. **Multiple inflammatory gastric polyps treated by endoscopic polypectomy with argon plasma coagulation in a dog.** *J Small Anim Pract* 2013; 54: 265–268.