



Use of intranasal povidone-iodine packing in the management of infectious rhinosinusitis in three cats

Authors: Sorrentino, Paul J, and MacArthur, Sandra L

Source: Journal of Feline Medicine and Surgery Open Reports, 10(2)

Published By: SAGE Publishing

URL: <https://doi.org/10.1177/20551169241275303>



Use of intranasal povidone-iodine packing in the management of infectious rhinosinusitis in three cats

Paul J Sorrentino and Sandra L MacArthur

Journal of Feline Medicine and Surgery Open Reports
1–6

© The Author(s) 2024

Article reuse guidelines:

sagepub.com/journals-permissions

DOI: 10.1177/20551169241275303

journals.sagepub.com/home/jfmsopenreports

This paper was handled and processed by the American Editorial Office (AAFP) for publication in *JFMS Open Reports*



Abstract

Case series summary Described are three cats diagnosed with rhinosinusitis secondary to *Mycobacterium bouchedurhonense*, *Aspergillus* species and *Alternaria* species, respectively. Medical records were retrospectively reviewed to identify cats with decreased nasal airflow and mucopurulent discharge that failed to improve on antibiotic therapy of 3 months or longer duration. Surgical debridement was followed by nasal packing using 5% povidone-iodine saturated umbilical tape, which was replaced at 24 h postoperatively. At 48 h postoperatively, the rhinotomy site was closed. Systemic therapy continued in the postoperative period. All cases were minimally responsive to previous medical management. History, signalment, clinical signs, diagnostic findings, treatment, and short- and long-term outcomes were retrieved. All cats were middle-aged with outdoor access and had clinical signs that commenced during the summer months. CT revealed turbinate destruction and soft tissue densities within the nasal passages. The otic apparatuses and calvaria were intact in all cats before surgery. A repeat CT examination revealed an improvement of the proliferative tissue identified in preoperative imaging in all cases. All cats achieved successful interruption of nasal discharge and restoration of nasal airflow with follow-up times of up to 16 months postoperatively.

Relevance and novel information To the authors' knowledge, this is the first report of the use of intranasal povidone-iodine packing in cats for the management of infectious rhinosinusitis. Surgical debridement and intranasal packing in addition to systemic therapy were successful in restoring nasal airflow and resolving nasal discharge in all cats with long-term follow-up.

Keywords: Nasal-packing; chronic rhinosinusitis; mycotic rhinosinusitis; sinonasal infection

Accepted: 30 July 2024

Introduction

Chronic and recurrent sinonasal disease in cats is clinically challenging to treat and the disease pathogenesis is not well understood. Despite a comprehensive diagnostic investigation, an etiology is rarely reported in cases of sneezing and nasal discharge among cats.^{1,2} Reports of invasive fungal rhinosinusitis exist; however, localized disease appears to be largely dependent on the host's immune response and the specific virulence of the infecting agent.^{3–9} The purpose of this retrospective case series was to describe the short- and long-term therapeutic outcome of three cats with infectious rhinosinusitis that were treated with surgical debridement and intranasal povidone iodine packing.

Case series description

Case 1

An 11-year-old spayed female domestic shorthair cat, weighing 4.3 kg, was presented for an acutely progressive dorsal nasal swelling, sneezing and congestion. On initial examination, the cat had a 3 cm raised swelling of the dorsal nasal subcutaneous tissues, head aversion,

Capital Veterinary Specialists, Tallahassee, FL, USA

Corresponding author:

Sandra L MacArthur DVM, Capital Veterinary Specialists LLC, 1615 Mahan Center Boulevard, Tallahassee, FL 32308, USA
Email: pjsorrenti@aol.com



Creative Commons Non Commercial CC BY-NC: This article is distributed under the terms of the Creative Commons

Attribution-NonCommercial 4.0 License (<https://creativecommons.org/licenses/by-nc/4.0/>) which permits non-commercial use, reproduction and distribution of the work without further permission provided the original work is attributed as specified on the SAGE and Open Access pages (<https://us.sagepub.com/en-us/nam/open-access-at-sage>).

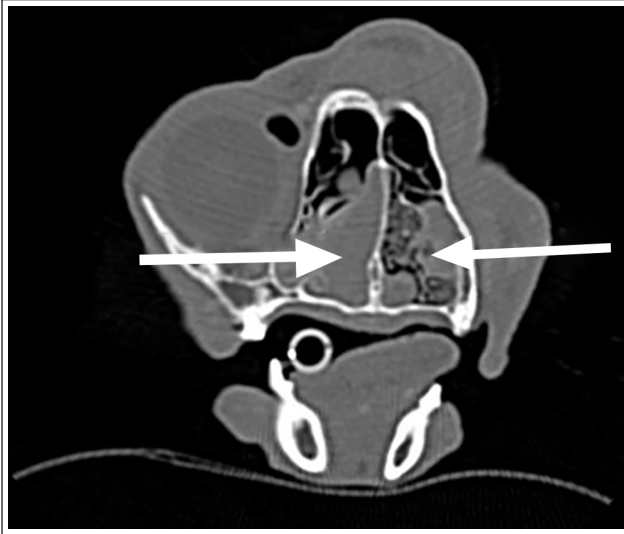


Figure 1 Transverse plane, postcontrast CT image of an 11-year-old spayed female domestic shorthair cat (case 1) with severe swelling of the dorsal nasal subcutaneous tissues, severe mucopurulent nasal discharge and decreased nasal airflow bilaterally. Note the bilateral proliferative tissue within the caudodorsal aspect of the nasal cavities (arrows). This tissue extends to the rostral aspect of the right nasal cavity and appears occluded. The maxillary, nasal and incisive bones are lytic

severe mucopurulent nasal discharge and decreased nasal airflow bilaterally. A CT examination depicted bilateral proliferative tissue within the caudodorsal aspect of the nasal cavities and in the right frontal sinus. Lysis along the dorsal aspect of the mid-nasal cavities to include the maxillary bone was present. The patient was placed on clarithromycin (16 mg/kg PO q12h for 3 months), pradofloxacin (7 mg/kg PO q24h for 3 months) and doxycycline (7 mg/kg PO q12h for 3 months). *Mycobacterium bovedurhonnense* was identified by 16S rDNA sequencing. The patient was placed on moxifloxacin (13 mg/kg PO q24h for 30 days) and then subsequently presumed lost to follow-up. At a recheck, 6 months after initiating moxifloxacin therapy, no appreciable clinical response was observed. On physical examination, the patient had persistent dorsal nasal subcutaneous swelling with ulceration of the overlying skin in addition to exhibiting episodes of dyspnea. A CT examination (Figure 1) revealed a destructive process with soft tissue proliferation and complete occlusion of the right side of the nasal cavity. A dorsal rhinotomy was performed via a midline skin incision made beginning at the rostral end of the nasal bone and extending caudally to the point parallel to the zygomatic processes of the frontal bone. The frontal sinus was accessed by caudodorsal extension of the osteotomy. The surgical site was debrided and curettaged (Figure 2). The site was lavaged and an intranasal povidone-iodine 5% packing was placed and closed

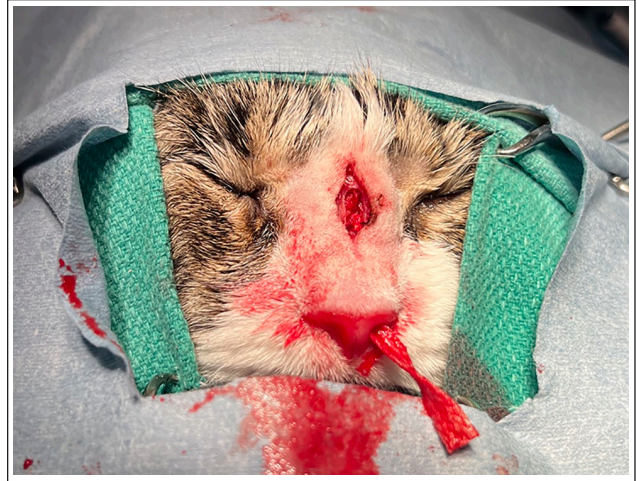

Figure 2 Intraoperative image of debridement before placement of first nasal packing in case 3

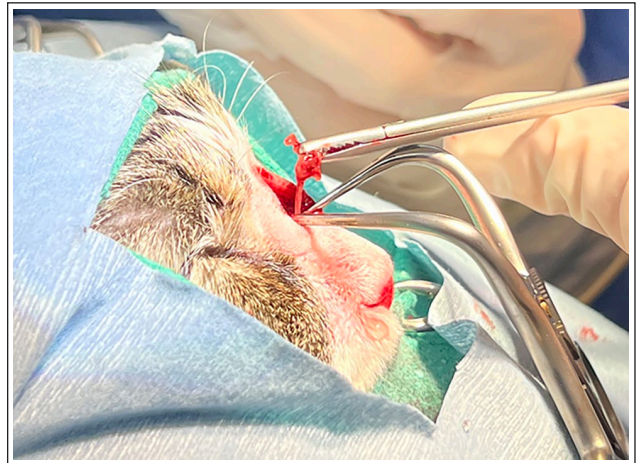


Figure 3 Intraoperative image of nasal packing in place before temporary closure of rhinotomy site in case 3

routinely (Figure 3). The ends of the umbilical tape exiting the nostril were sutured to the muzzle. The packing was replaced at 24 h postoperatively under general anesthesia. At 48 h postoperatively, the packing was removed, at which point the rhinotomy site was closed. At a routine recheck 4 weeks postoperatively, the patient demonstrated equal airflow bilaterally with resolution of nasal discharge. Antibiotic nebulization (amikacin 50 mg/5 ml) was prescribed for 60 days based on susceptibility testing. The cat had nasal swelling consistent with suspected recurrent *M bovedurhonnense* infection; however, no nasal discharge was noted at 8 weeks postoperatively. During a recheck 9 months postoperatively, the cat had absent nasal discharge with unchanged nasal swelling. Antibiotic injectable therapy (meropenem 9.3 mg/kg SC q12h for 10 days) was introduced. The patient was subsequently lost to follow-up.

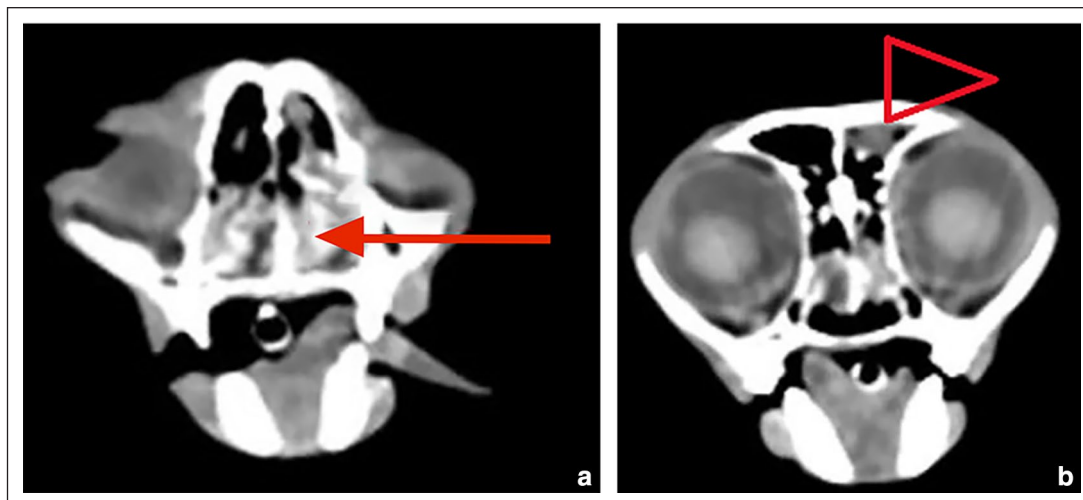


Figure 4 (a) Transverse plane, postcontrast CT image of a 9-year-old spayed female domestic shorthair cat (case 2) with contrast enhancement of the nasal turbinates and fluid accumulation extending to the frontal and sphenoid sinuses (arrow). (b) Transverse plane, postcontrast CT image 3 months postoperatively. Note the proliferative soft tissue attenuating material within the right frontal sinus that likely represented redistribution of aspergillosis and progressive right sinusitis (arrowhead)

Case 2

A 9-year-old spayed female domestic shorthair cat, weighing 3.7 kg, was presented for sneezing and nasal discharge. On initial examination, the cat had moderate mucopurulent nasal discharge and decreased nasal airflow bilaterally. A CT examination (Figure 4a) revealed contrast enhancement of the nasal turbinates and fluid accumulation extending into the sphenoid and frontal sinuses indicative of non-destructive rhinosinusitis. Rhinoscopy was performed, which revealed the presence of moderate diffuse rhinitis with irregular turbinates and fibrinonecrotic tissue. Histopathology revealed extensive fungal plaques with morphology indicative of *Aspergillus* species. The cat was also positive for *Mycoplasma felis* on PCR. The cat underwent a dorsal rhinotomy and placement of intranasal packing in the same manner as case 1. The cat was prescribed fluconazole (4 mg/kg PO q24h for 12 weeks) and terbinafine (24 mg/kg PO q12h for 12 weeks), robenacoxib (6 mg PO q24h for 3 days), cefovecin sodium (8 mg/kg SC) and buprenorphine (0.02 mg/kg TM q8–12h for 1 week). At 3 weeks postoperatively, the previously described nasal discharge had resolved and equal airflow bilaterally was observed. A CT examination (Figure 4b) was performed 3 months postoperatively at the conclusion of oral antifungal therapy. CT examination revealed mixed lysis and proliferation of nasal cavities improved from pre operative imaging. Imaging of the right frontal sinus depicted progression of proliferative soft tissue attenuating material, which likely represented redistribution of aspergillosis and progressive right sinusitis. No clinical signs were observed; oral antifungal therapy was

extended for a further 6 weeks (for a total duration of 18 weeks) given the imaging findings. At 6 months postoperatively, the cat remained free of nasal discharge and obstruction to nasal airflow. Each subsequent physical examination at 7, 8, 9, 10 and 12 months postoperatively demonstrated no re-emergence of the cat's sneezing episodes. The cat presented at 16 months postoperatively with no clinical evidence of relapse.

Case 3

A 10-year-old neutered male domestic shorthair cat, weighing 7.7 kg, was presented for intermittent sneezing. At the time of presentation, the cat was a controlled diabetic receiving 2.5 IU of insulin glargine (Lantus; Sanofi-Aventis) every 12h and was asymptomatic for its previously prescribed inflammatory bowel disease managed with budesonide at 0.05 mg/kg q24h. On initial examination, the patient had decreased airflow through the left nostril and mild mucopurulent nasal discharge. Rhinoscopy was performed, which revealed the presence of an infiltrative mass and fibrinonecrotic tissue within the left nasal cavity. A CT examination (Figure 5a) depicted a fusiform mass present in the lateral aspect of the mid to caudal aspect of the left nasal cavity causing severe lysis of the left nasal turbinates and orbital bones. Cytology showed clusters and mats of partially staining, branching and septate, fungal hyphal structures. Rhinoscopic samples retained for histopathology showed fungal hyphae morphologically most consistent with *Aspergillus* species and bacterial culture demonstrated heavy growth of *Staphylococcus pseudintermedius*. The cat was prescribed

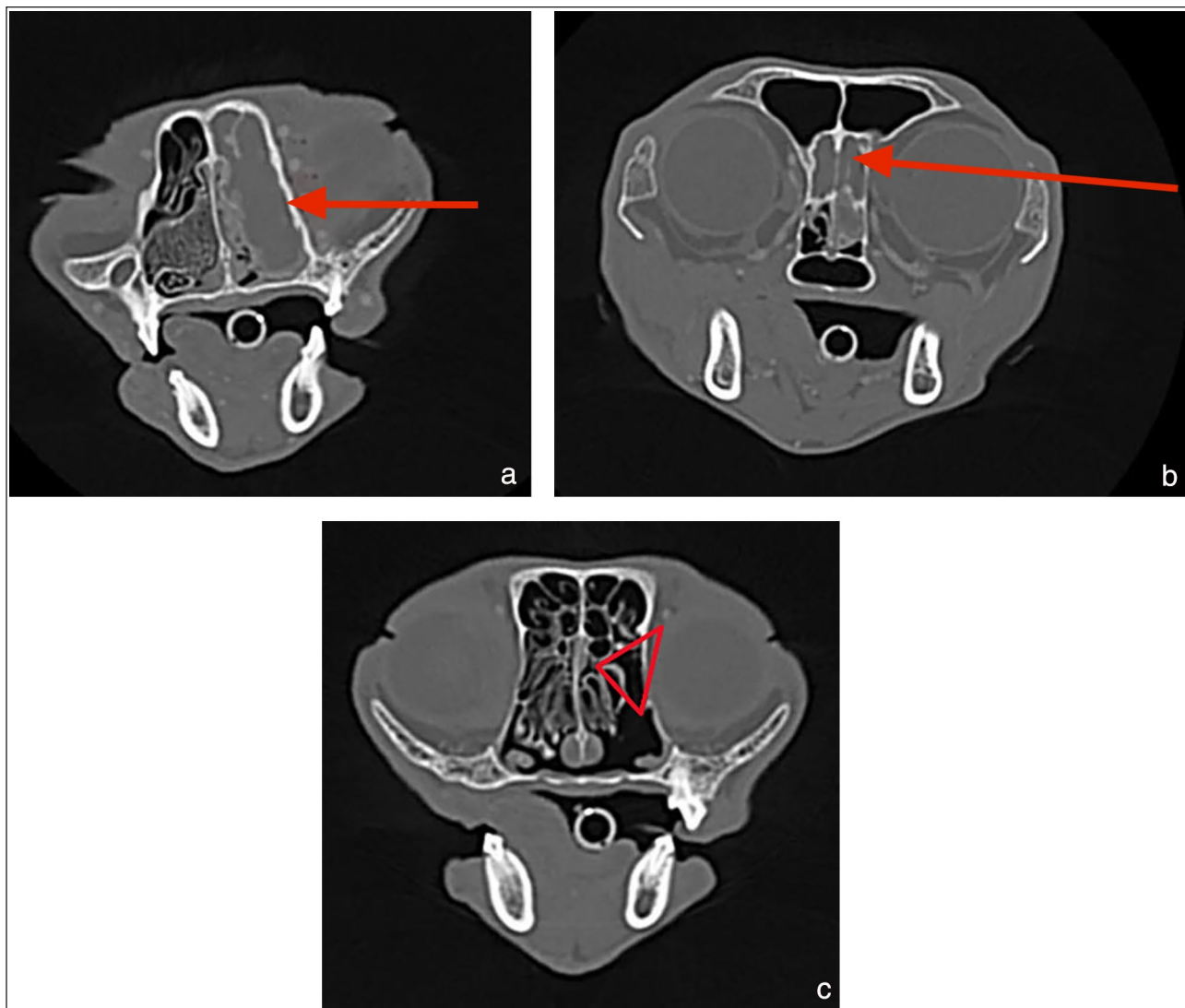


Figure 5 (a) Transverse plane, postcontrast CT image of a 10-year-old neutered male domestic shorthair cat (case 3) with bilateral nasal discharge and decreased nasal airflow through the left nostril. Note the moderately sized mass in the left nasal cavity causing nasal turbinate and orbital bone lysis (thin arrow). (b) Transverse plane, postcontrast CT image of the same case 7 months after initial presentation. Note the severe lysis of the mid left nasal turbinates and left orbital bones and moderately sized, fusiform mass present along the mid to caudal aspect of the left nasal cavity tapering caudally to the level of the ethmoturbinates (thin arrow). (c) Transverse plane, postcontrast CT image of the same case 12 months postoperatively. The previously described soft tissue within the left ethmoturbinates is nearly completely resolved. There is a small amount of soft tissue material along the left ventrolateral aspect of the cribriform plate with focal irregularity and thinning (arrowhead)

fluconazole (6.5 mg/kg PO q24h for 30 days), terbinafine (8 mg/kg PO q24h for 30 days) and initiated clindamycin (10 mg/kg SC q24h for 10 days). The cat underwent a dorsal rhinotomy and placement of intranasal packing in the same manner as cases 1 and 2. *Alternaria* species was identified on fungal culture. The dose of terbinafine (16 mg/kg PO q24h) was increased and the frequency of administration of fluconazole (6.5 mg/kg PO q 12h) was increased. At 2 months postoperatively, the patient demonstrated equal airflow bilaterally with complete resolution of sneezing and

nasal discharge. A recheck CT (Figure 5b) was performed 7 months postoperatively, which revealed resolution of the larger aspect of the previous lesion in the left nasal cavity. Mild cribriform thinning and focal irregularities were now observed. Antifungal therapy was extended for another 6 months, for a total duration of 8 months. At 12 months postoperatively, the cat remained asymptomatic despite the presence of the previously described soft tissue material present along the left ventrolateral aspect of the cribriform plate and adjacent ethmoturbinates (Figure 5c).

Discussion

Current treatment recommendations are centered on a combination of surgical debridement of involved tissues, prolonged use of systemic medications and topical intranasal azole infusion.^{4,8,10–12} Debridement has been shown to be the most effective modality in improving the interface of antimicrobial therapy and host tissue through physical disruption.^{13,14} This technique forces the community to increase metabolic activity for remodeling, thus presenting an ideal window for employing antimicrobial therapy where susceptibility is considered the highest.^{15–18} Intranasal packing allows for prolonged contact with residual disease after debridement thereby offsetting the limitations of variable distribution and retention of topical clotrimazole and enilconazole.¹⁹

This technique aims to mitigate the reported risks of meningoencephalitis in reported cases of intranasal azole infusions.^{20–22} Relapse of infection has been reported in numerous cases of premature withdrawal of systemic therapy as a result of adverse effects, including azole-related hepatotoxicity and adverse neurologic events.^{23,24} In the present case series, all three cats exhibited resolution of nasal discharge and restoration of nasal airflow with a long-term follow-up of 16 months, suggestive that surgical debridement and intranasal packing may have contributed to attenuating turbinate destruction, once antibiotic therapy use had stopped.

The choice of povidone-iodine as an adjunctive treatment procedure was centered on its reported effectiveness in nasal decolonization.^{25–28} The effective broad spectrum of activity against various bacteria, fungi, viruses and protozoa as well as its anti-inflammatory properties makes povidone-iodine a desirable instrument in many clinical domains.^{29,30} Povidone-iodine solution 5% has been formulated to be safe, tolerable and rapidly bactericidal against a variety of aerobic Gram-positive and Gram-negative bacteria, as well as fungi associated with chronic rhinosinusitis.^{27,28}

This case series describes three cats that tolerated the sustained application of 5% povidone-iodine as a nasal antiseptic packing over the course of 2 days. In cases where postoperative CT was available, systemic therapy was extended owing to evidence of redistribution or progression of disease. *Aspergillus* species morphology and *Alternaria* species were detected on histopathology in case 2 and on fungal culture in case 3 where fluconazole was selected and extended after repeat CT. Inappropriate drug selection based on the intrinsic fluconazole resistance of *Aspergillus* and *Alternaria* species may be a reason why there was subclinical progression of disease identified on imaging.^{31,32} A repeat CT examination after an extended course of systemic therapy is recommended to better inform treatment strategies whereby a second intranasal packing procedure could be considered.

The present study is limited by its retrospective design and small sample size. Furthermore, this series did not select for standardization of final diagnoses. The treatments outlined in this case series reflect an alternative to gold-standard treatment with topical antifungal infusion and/or systemic antimicrobial therapies guided by susceptibility testing. This treatment may be suitable in cases where concern for secondary colonizing bacteria and the subsequent chronic inflammatory mucosal changes seen with mixed infections are present. In addition, if a breach in the cribriform plate is identified, the use of 0.9% povidone-iodine may be considered a safe alternative to intranasal azole infusion.³³

These findings reveal preliminary insight into the potential benefits of povidone-iodine packing as an adjunctive microbicidal agent in cats with infectious rhinosinusitis when financial limitations exist or if there is considerable concern for the use of topical antifungal agents.

Conclusions

Surgical debridement and 5% povidone-iodine packing in combination with appropriate systemic antibiotic or antifungal therapy eliminated clinical signs related to intranasal disease for cats with follow-up times of up to 16 months postoperatively. The improvement in subjective wellbeing as described by the pet owners was attributed to restored nasal airflow and resolution of nasal discharge in all cases.

Acknowledgements The authors thank the Internal Medicine Service at Capital Veterinary Specialists: Sofia Morales DVM, DACVIM and the Surgery Service at Capital Veterinary Specialists: Carl T Jehn DVM, MS, DACVS and Kevin A Drygas DVM, DACVS.

Conflict of interest The authors declared no potential conflicts of interest with respect to the research, authorship, and/or publication of this article.

Funding The authors received no financial support for the research, authorship, and/or publication of this article.

Ethical approval The work described in this manuscript involved the use of non-experimental (owned or unowned) animals. Established internationally recognised high standards ('best practice') of veterinary clinical care for the individual patient were always followed and/or this work involved the use of cadavers. Ethical approval from a committee was therefore not specifically required for publication in *JFMS Open Reports*. Although not required, where ethical approval was still obtained, it is stated in the manuscript.

Informed consent Informed consent (verbal or written) was obtained from the owner or legal custodian of all animal(s) described in this work (experimental or non-experimental animals, including cadavers, tissues and samples) for all

procedure(s) undertaken (prospective or retrospective studies). No animals or people are identifiable within this publication, and therefore additional informed consent for publication was not required.

ORCID iD Sandra L MacArthur  <https://orcid.org/0009-0007-6832-7279>

References

- Henderson SM, Bradley K, Day MJ, et al. **Investigation of nasal disease in the cat—a retrospective study of 77 cases.** *J Feline Med Surg* 2004; 6: 245–257.
- Michiels L, Day MJ, Snaps F, et al. **A retrospective study of non-specific rhinitis in 22 cats and the value of nasal cytology and histopathology.** *J Feline Med Surg* 2003; 5: 279–285.
- Lamm CG, Grune SC, Estrada MM, et al. **Granulomatous rhinitis due to *Candida parapsilosis* in a cat.** *J Vet Diagn Invest* 2013; 25: 596–598.
- Barrs VR, van Doorn TM, Houbraken J, et al. ***Aspergillus felis* sp. nov., an emerging agent of invasive aspergillosis in humans, cats, and dogs.** *PLoS One* 2013; 8. DOI: 10.1371/journal.pone.0064871.
- Cormack CA, Donahoe SL, Talbot JJ, et al. **Disseminated invasive aspergillosis caused by *Aspergillus felis* in a cat.** *J Vet Intern Med* 2021; 35: 2395–2400.
- Giordano C, Gianella P, Bo S, et al. **Invasive mould infections of the naso-orbital region of cats: a case involving *Aspergillus fumigatus* and an aetiological review.** *J Feline Med Surg* 2010; 12: 714–723.
- McCormick A, Loeffler J and Ebel F. ***Aspergillus fumigatus*: contours of an opportunistic human pathogen.** *Cell Microbiol* 2010; 12: 1535–1543.
- McLellan GJ, Aquino SM, Mason DR, et al. **Use of posaconazole in the management of invasive orbital aspergillosis in a cat.** *J Am Anim Hosp Assoc* 2006; 42: 302–307.
- Ziglioli V, Panciera DL, LeRoith T, et al. **Invasive *Microsporium canis* causing rhinitis and stomatitis in a cat.** *J Small Anim Pract* 2016; 57: 327–331.
- Whitney BL, Broussard J and Stefanacci JD. **Four cats with fungal rhinitis.** *J Feline Med Surg* 2005; 7: 53–58.
- Tomsa K, Glaus TM, Zimmer C, et al. **Fungal rhinitis and sinusitis in three cats.** *J Am Vet Med Assoc* 2003; 222: 1380–1384, 1365.
- Furrow E and Groman RP. **Intranasal infusion of clotrimazole for the treatment of nasal aspergillosis in two cats.** *J Am Vet Med Assoc* 2009; 235: 1188–1193.
- Williams D, Enoch S, Miller D, et al. **Effect of sharp debridement using curette on recalcitrant nonhealing venous leg ulcers: a concurrently controlled, prospective cohort study.** *Wound Repair Regen* 2005; 13: 131–137.
- Wolcott RD and Rhoads DD. **A study of biofilm-based wound management in subjects with critical limb ischaemia.** *J Wound Care* 2008; 17: 145–148, 150–152, 154–155.
- Stewart PS. **Antimicrobial tolerance in biofilms.** *Microbiol Spectr* 2015; 3. DOI: 10.1128/microbiolspec.MB-0010-2014.
- Stewart PS. **Mechanisms of antibiotic resistance in bacterial biofilms.** *Int J Med Microbiol* 2002; 292: 107–113.
- Stewart PS and Costerton JW. **Antibiotic resistance of bacteria in biofilms.** *Lancet* 2001; 358: 135–138.
- Stewart PS, Grab L and Diemer JA. **Analysis of biocide transport limitation in an artificial biofilm system.** *J Appl Microbiol* 1998; 85: 495–500.
- Sharman M, Lenard Z, Hosgood G, et al. **Clotrimazole and enilconazole distribution within the frontal sinuses and nasal cavity of nine dogs with sinonasal aspergillosis.** *J Small Anim Pract* 2012; 53: 161–167.
- Moore AH. **Use of topical povidone-iodine dressings in the management of mycotic rhinitis in three dogs.** *J Small Anim Pract* 2003; 44: 326–329.
- Peeters D and Clercx C. **Update on canine sinonasal aspergillosis.** *Vet Clin North Am Small Anim Pract* 2007; 37: 901–916, vi.
- Zonderland JL, Störk CK, Saunders JH, et al. **Intranasal infusion of enilconazole for treatment of sinonasal aspergillosis in dogs.** *J Am Vet Med Assoc* 2002; 221: 1421–1425.
- Foy DS and Trepanier LA. **Antifungal treatment of small animal veterinary patients.** *Vet Clin North Am Small Anim Pract* 2010; 40: 1171–1188.
- Quimby JM, Hoffman SB, Duke J, et al. **Adverse neurologic events associated with voriconazole use in 3 cats.** *J Vet Intern Med* 2010; 24: 647–649.
- Seidelman JL, Mantyh CR and Anderson DJ. **Surgical site infection prevention: a review.** *JAMA* 2023; 329: 244–252.
- Hammond EN, Kates AE, Putman-Buehler N, et al. **Quality improvement study on the effectiveness of intranasal povidone-iodine decolonization on surgery patients.** *Infect Prev Pract* 2023; 5. DOI: 10.1016/j.infpip.2023.100274.
- Rezapoor M, Nicholson T, Tabatabaee RM, et al. **Povidone-iodine-based solutions for decolonization of nasal staphylococcus aureus: a randomized, prospective, placebo-controlled study.** *J Arthroplasty* 2017; 32: 2815–2819.
- Phillips M, Rosenberg A, Shopsis B, et al. **Preventing surgical site infections: a randomized, open-label trial of nasal mupirocin ointment and nasal povidone-iodine solution.** *Infect Control Hosp Epidemiol* 2014; 35: 826–832.
- Bigliardi PL, Alsagoff SAL, El-Kafrawi HY, et al. **Povidone iodine in wound healing: a review of current concepts and practices.** *Int J Surg* 2017; 44: 260–268.
- Percival SL, Finnegan S, Donelli G, et al. **Antiseptics for treating infected wounds: efficacy on biofilms and effect of pH.** *Crit Rev Microbiol* 2016; 42: 293–309.
- Leonardelli F, Macedo D, Dudiuk C, et al. ***Aspergillus fumigatus* intrinsic fluconazole resistance is due to the naturally occurring T301I substitution in Cyp51Ap.** *Antimicrob Agents Chemother* 2016; 60: 5420–5426.
- Pujol I, Aguilar C, Gené J, et al. **In vitro antifungal susceptibility of *Alternaria* spp. and *Ulocladium* spp.** *J Antimicrob Chemother* 2000; 46: 337–338.
- Preston TJ, Hosgood GL and Paul A. **Surgical management of refractory nasal aspergillosis using iodine cadexomer dressings in three dogs.** *Aust Vet J* 2016; 94: 405–410.