



---

## **Successful use of a 3D-printed surgical guide to facilitate transiliosacral fixation in a cat with bilateral sacroiliac luxation**

Authors: Scortea, Radu, Reichardt, Fee, Muresan, Cosmin, and Krauß, Maximiljan

Source: Journal of Feline Medicine and Surgery Open Reports, 10(2)

Published By: SAGE Publishing

URL: <https://doi.org/10.1177/20551169241273629>



# Successful use of a 3D-printed surgical guide to facilitate transiliosacral fixation in a cat with bilateral sacroiliac luxation

*Journal of Feline Medicine and Surgery Open Reports*  
1–6

© The Author(s) 2024

Article reuse guidelines:

sagepub.com/journals-permissions

DOI: 10.1177/20551169241273629

journals.sagepub.com/home/jfmsopenreports

This paper was handled and processed by the European Editorial Office (ISFM) for publication in *JFMS Open Reports*



Radu Scortea<sup>1</sup>, Fee Reichardt<sup>1</sup>, Cosmin Muresan<sup>2</sup> and Maximilian Krauß<sup>1</sup>

## Abstract

**Case summary** A 7-year-old male castrated domestic shorthair cat was presented for treatment of a bilateral sacroiliac luxation (SIL). CT was performed and the data were extracted in a stereolithography (STL) file, after which a 3D-printed drill guide (3DPDG) was devised, using computer-aided design (CAD) software, and printed. Using an open surgical approach, the guide was used as an aid for drilling the sacrum. The ilial wings were drilled free-hand later and a transiliosacral pin (TP) was inserted to realign and stabilise the SIL. The cat exhibited an early return to normal limb function and a CT scan performed at the postoperative follow-up showed early signs of bone remodelling at the sacroiliac joint.

**Relevance and novel information** To the authors' knowledge, this is the first report using a 3DPDG for implant placement in the feline sacrum without intraoperative imaging.

**Keywords:** 3D-printed drill guide; sacroiliac fracture/luxation; stereolithography; computer-aided design; transiliosacral pin

**Accepted:** 17 July 2024

## Introduction

Sacroiliac luxation (SIL) in cats represents a component of 16–59.2% of feline pelvic fractures.<sup>1–3</sup> Surgical intervention is recommended for non-ambulatory cases, those with pelvic canal narrowing surpassing 45%, and those presenting with neurological deficits and pain.<sup>4</sup> It consists of fixation techniques, such as placement of a lag screw,<sup>5–7</sup> transsacral screw,<sup>8</sup> transiliosacral lag screw,<sup>9</sup> transsacral screw and nut stabilisation,<sup>10</sup> transiliosacral pin (TP),<sup>11</sup> transiliac pin/bolt/screw internal fixation<sup>12</sup> and transiliosacral toggle suture.<sup>13</sup> The rate of complications associated with implant misplacement is in the range of 12.5%<sup>14</sup> to 16.6%<sup>15</sup> and consists of placement ventral to the sacral body, occupation of the vertebral canal and intervertebral disc, leading to residual lameness<sup>16</sup> and tibial nerve palsy.<sup>17</sup> In cats undergoing open reduction and internal fixation (ORIF), only 34% have landmarks such as the sacral wing notch,<sup>5</sup> and the

optimal drilling angle relative to the sacral wing surface can vary between a maximum of  $107^\circ \pm 6.8^\circ$  and a minimum of  $87^\circ \pm 7.2^\circ$  (optimum  $97^\circ \pm 6.9^\circ$ ).<sup>6</sup> For accurate drilling, employing intraoperative imaging such as fluoroscopy<sup>18</sup> or radiology<sup>7</sup> are recommended. The use of a C-guide can facilitate implant placement, but its application is limited to bilateral SIL.<sup>11</sup>

<sup>1</sup>Department of Surgery, Tierklinik Düsseldorf, Düsseldorf, Germany

<sup>2</sup>Department of Surgery, Anaesthesia and Intensive Care, University of Agricultural Sciences and Veterinary Medicine Cluj-Napoca, Cluj-Napoca, Romania

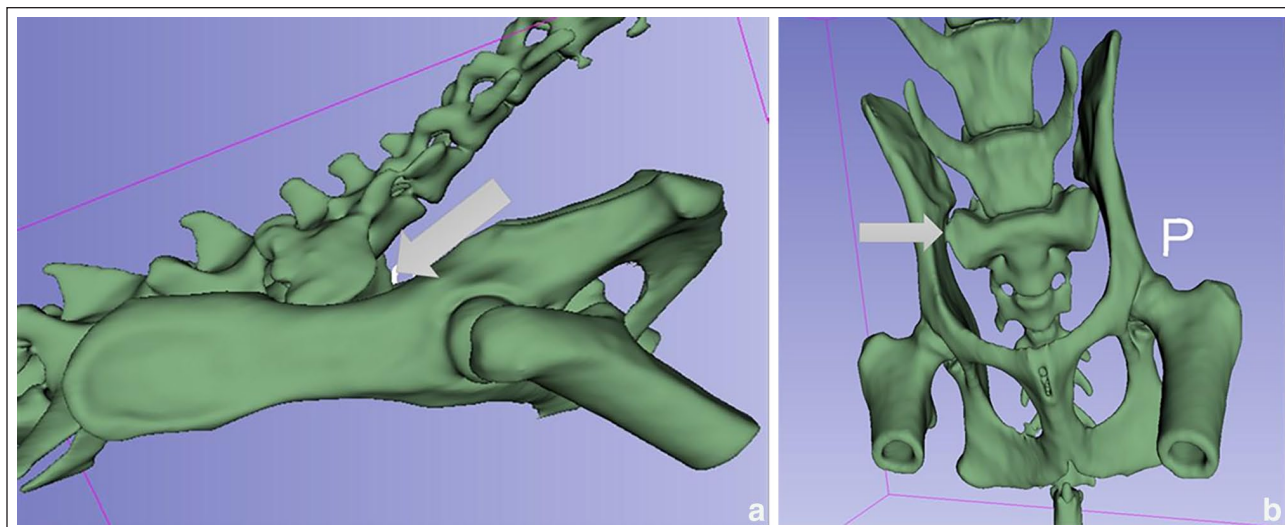
### Corresponding author:

Radu Scortea DVM, Cert AVP, MRCVS, Tierklinik Düsseldorf GmbH, Münsterstraße 359, Düsseldorf, 40470, Germany  
Email: radu\_scortea@yahoo.co.uk



Creative Commons Non Commercial CC BY-NC: This article is distributed under the terms of the Creative Commons

Attribution-NonCommercial 4.0 License (<https://creativecommons.org/licenses/by-nc/4.0/>) which permits non-commercial use, reproduction and distribution of the work without further permission provided the original work is attributed as specified on the SAGE and Open Access pages (<https://us.sagepub.com/en-us/nam/open-access-at-sage>).



**Figure 1** (a) 3D reconstruction of the pelvis and sacrum, showing bilateral ventral sacroiliac luxation (grey arrow) and (b) 3D reconstruction of the pelvis and sacrum, showing bilateral caudal sacroiliac luxation (grey arrow)

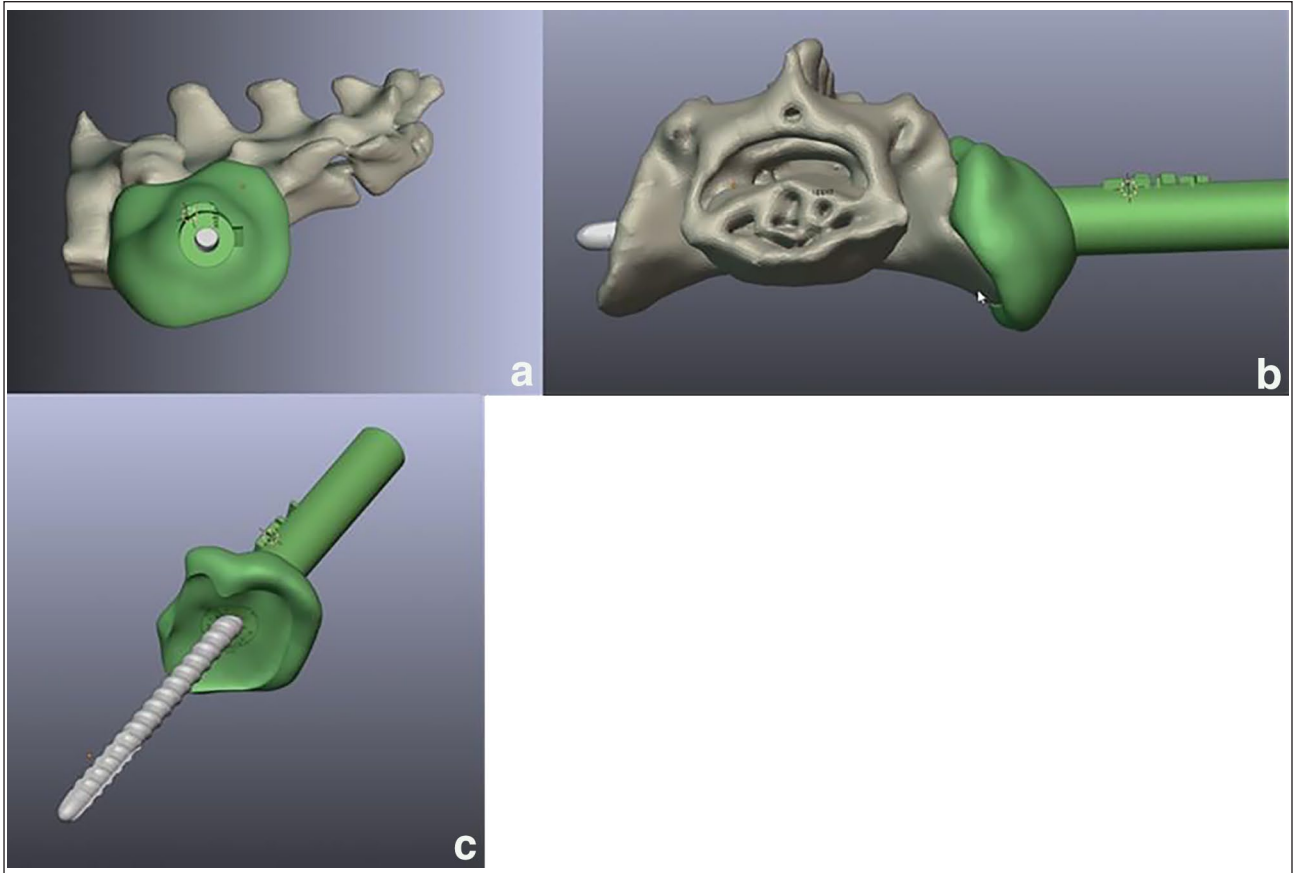
Despite a recent cadaveric study in dogs<sup>19</sup> that introduced the use of 3D-printed drill guides (3DPDGs) for SIL, this technique has not been previously reported in cats and has yet to be documented clinically in either species. This case report presents the use of 3DPDG for TP placement in a cat and compares implant placement with virtual planning.

### Case description

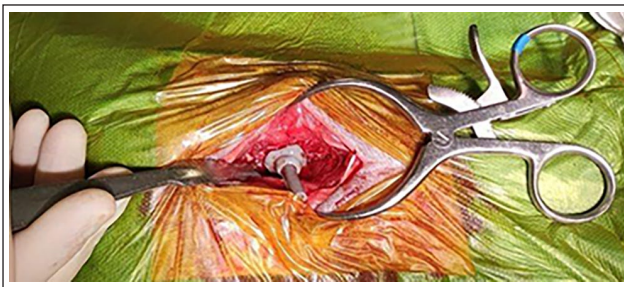A 7-year-old castrated male domestic shorthair cat was presented for evaluation after falling from the fifth floor. Abdominal and thoracic focused assessment with ultrasonography for trauma and tracking detected no abnormalities. However, thoracic radiographs, performed awake once stable, revealed evidence of bilateral pulmonary contusions. The patient was non-ambulatory. Neurological examination revealed the presence of voluntary movement but poor spinal reflexes to both pelvic limbs, where the left seemed to be more affected. Pain and instability of the mandible and sacroiliac joints (SJs) were noted on palpation. Serum biochemistry was unremarkable. Haematology revealed marked anaemia, with a haematocrit of 15.1%, which dropped to 10% the next day. The cat underwent hemodynamic stabilisation, which included a preoperative homologous blood transfusion. Analgesia consisted of methadone 0.1–0.3 mg/kg IV (Comfortan; Dechra) every 4–6 h, given according to the Glasgow Feline Composite Measure Pain Scale, and meloxicam 0.1 mg/kg IV (Metacam; Boehringer Ingelheim), at initial administration and followed by 0.05 mg/kg daily. On the third day of hospitalisation, a CT scan of the head and pelvis was performed under sedation, confirming the presence of a bilateral SIL (Figure 1) and a mandibular symphyseal fracture.

The digital imaging and communications in medicine (DICOMS) of the patient's pelvis were imported to an open-source software platform (3D Slicer, <https://www.slicer.org>) where a stereolithography (STL) object of the sacrum was created, exported and transferred to a computer-aided design (CAD) software (Blenderfidental, <https://www.blenderfidental.com>). A guide with a length of 27 mm and a layer thickness of 4 mm was built to align with the articular surface of the sacrum (Figure 2). A safe corridor path was created to fit a 2.0 mm diameter implant with a drill guide diameter of 1.8 mm. The guide and the sacrum STL files were transferred to the printer software and printed in a biocompatible and autoclavable resin (Dental Ortho Model; Phrozen) using a 3D printer (Phrozen Mighty 4K; Phrozen).

The cat was premedicated with methadone 0.2 mg/kg IV and medetomidine 0.005 mg/kg IV (Dorbene; Zoetis) and anaesthesia was induced with alfaxalone (Alfaxan; Zoetis) given intravenously to the desired effect and maintained with a mixture of isoflurane (IsoFlo; Zoetis) vaporised in 100% oxygen. The patient was positioned in sternal recumbency using a conforming, deflatable bean bag for stability. A bilateral dorsal approach was made over the cranial dorsal iliac spines. Incisions were made at the caudal point of the iliac crest and extended along the ilium's dorsal surface, sparing the cranial gluteal neurovascular structures. The sacrocaudalis and middle gluteal muscles were retracted, and using a Hohmann retractor, the sacrum and right iliac wing were exposed for better visualisation of the right SJ, followed by thorough debridement of the sacrum's articular surface and removal of residual soft tissues. Using the 3DPDG (Figure 3), a bicortical screw hole was drilled across the sacrum with a 1.8 mm drill bit, ensuring guide stability with



**Figure 2** Virtual planning of the sacral model and 3D guide in computer-aided design software, shown in (a) right lateral and (b) axial views, and (c) an additional view of the 3D guide. The angle of the corridor in relation to the articular surface of the sacrum was  $106^\circ$  on the dorsal plane and  $107^\circ$  on the transverse plane



**Figure 3** Intraoperative image illustrating the placement of the 3D-printed drill guide on the sacrum

manual compression. The iliac wings were elevated, and drilled free-hand from medial to lateral, aiming for the centre of the visualised medial articular surface. A smooth orthopaedic pin (Imex; Veterinary) with a diameter of 2.0 mm was then inserted through the iliac pilot hole, across the sacrum and, finally, through the contralateral iliac wing. After reducing the SJ, the pin's exposed ends were bent and trimmed to secure the fixation. The wounds were closed routinely. The symphyseal mandibular fracture was stabilised with cerclage wire

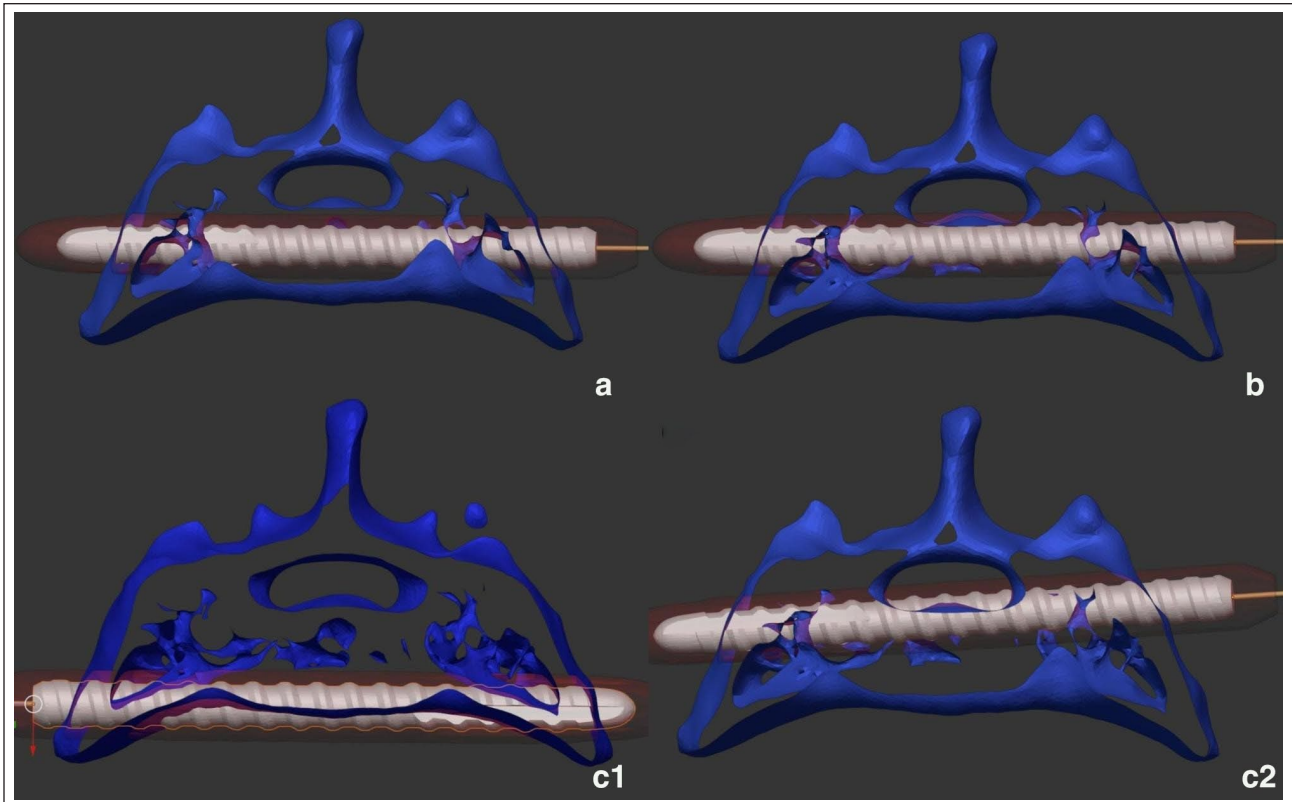
and an oesophagostomy tube was placed to assist in postoperative care. Although a postoperative CT scan was not immediately possible, because of technical constraints, orthogonal radiographs confirmed the successful implant placement and SJ reduction.

The patient remained hospitalised for the next 72h. Postoperatively, there was no deterioration in neurological status, attempting to stand and walk, and the cat was able to urinate voluntarily. Instructions for discharge comprised strict cage rest for the next 6 weeks and administration of meloxicam (0.05 mg/kg PO q24h) for 7 days. The follow-up examination at 6 weeks showed an excellent recovery to ambulatory function and no signs of discomfort or functional deficits (eg, urinary incontinence, spinal reflexes deficits). On this occasion, a CT scan of the pelvis was performed using a 64-slice scanner (SOMATOM Sensation; Siemens Healthcare) with the patient positioned in ventral recumbency, using the following parameters: 120 kV; 200 mAS; and a slice thickness of 0.6 mm. The 3D reconstructions were made using a bone algorithm.

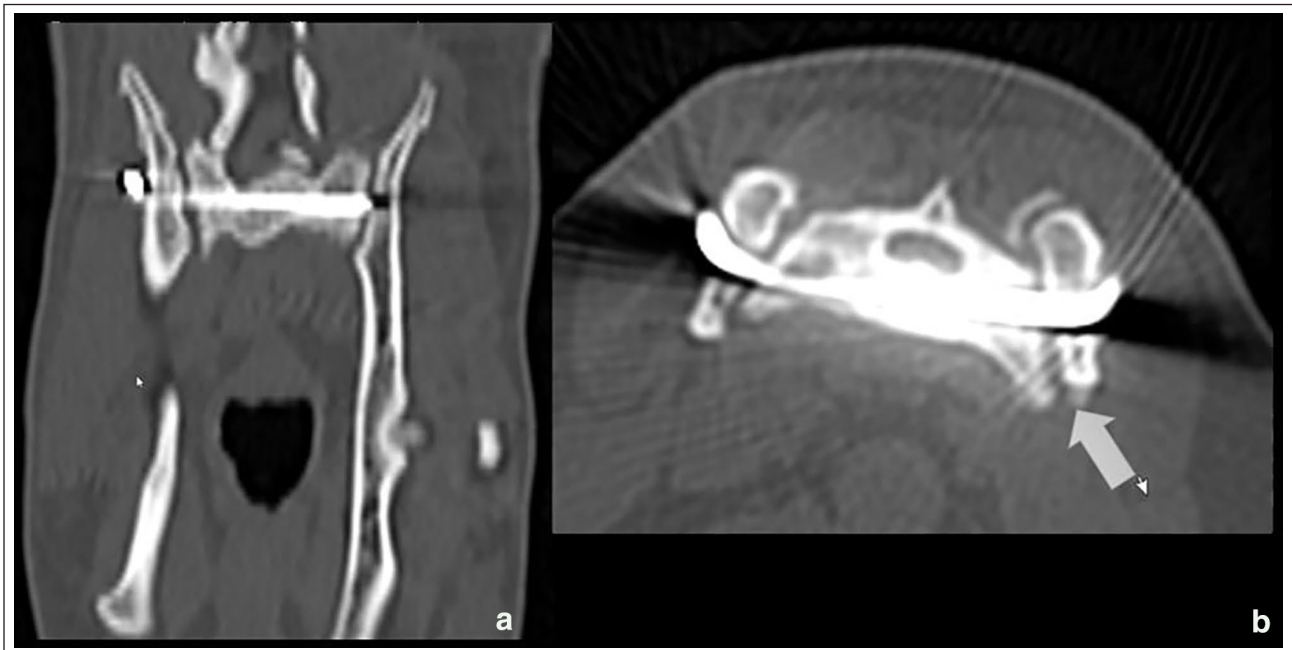
The assessment of implant positioning was graded 'a' on the adapted Gras<sup>20</sup> classification (Figure 4).

Smooth remodelling of the bone margins at the SJ (Figure 5) with a slight dorsal elevation of the left iliac

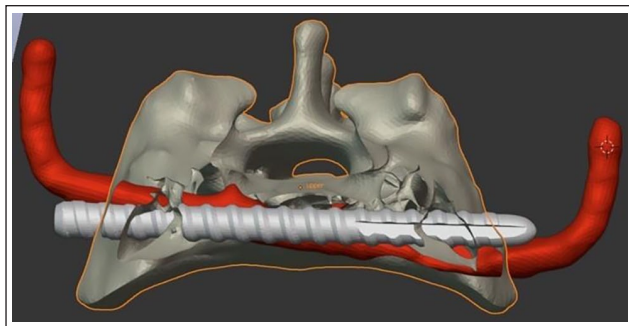




**Figure 4** Gras adapted classification system: (a) secure placement within the cancellous bone; (b) secure placement, with contact to cortical bone structures; (c1) ventral malposition, involving penetration of the cortical bone; and (c2) dorsal malposition, involving penetration of the cortical bone



**Figure 5** Coronal (a) and axial images (b) of the sacroiliac stabilization at the 6-week follow-up, confirming secure placement of the implant in cancellous bone, without any signs of implant loosening. Note the left ilium is slightly misaligned dorsally



**Figure 6** Comparison between the 6-week postoperative implant placement trajectory (red) and virtual implant (grey). The irregular shape of the postoperative implant (red) is due to CT artefacts. The preoperative and postoperative images of the sacrum were precisely aligned for a comprehensive evaluation

wing was also noted. The cerclage wire used for the symphyseal fracture was explanted. A gradual return to regular exercise over 6 weeks was advised.

An STL file was generated in 3D Slicer for the sacrum and the TP based on the postoperative DICOMS and imported into Blenderfodental, where the sacrum was superimposed over the preoperative planning images allowing comparison of the planned and actual implant trajectories. The maximum angular deviation of the screw showed a deviation of  $2.2^\circ$  in the dorsal plane and  $9.5^\circ$  in the transverse plane. The centre of the implant at the sacral entry point, as per preoperative planning, was connected to the centre of the postoperative TP and a line segment was created that permitted the taking of measurements along the x- and y-axis, which revealed a translation of 1.6 mm dorsally at the entry point and 2.4 mm at the exit point caudoventrally (Figure 6).

## Discussion

The goal of surgical treatment for bilateral SIL is to restore anatomical alignment and facilitate early ambulation,<sup>21</sup> with data in favour of the minimally invasive osteosynthesis (MIO) techniques when compared with the traditional (ORIF).<sup>18</sup> To counteract rotational forces at the level of the SJ, the use of multiple implants is advised<sup>11,22</sup> to prevent pin migration. Parslow and Simpson<sup>11</sup> secured the TP by application of either two ilial bone screws or a hemicerclage wire. However, in our case, given the SIL configuration, it was anticipated that a single TP, once compressed, would effectively sustain bilateral reduction by conforming to both iliac wings. This assumption was supported by postoperative CT findings, where secure placement in the cancellous bone and no sign of implant failure were noted. A recent study<sup>15</sup> highlighted the importance of pre- and postoperative CT scanning to accurately plan/assess implant placement and for detecting potential issues such as neural canal penetration, which may not be visible on postoperative radiographs. Comparison of the virtual preoperative implant and

postoperative implant placement revealed some differences at the insertion/exit points and trajectory. This discrepancy may be attributed to suboptimal dissection of the lateral articular surface of the sacrum and ventrally distracted ilial wing, leading to deviation of the 3DPDG dorsally (Figure 3) and improper positioning/compression/holding.

A study reporting the accuracy of sacroiliac reduction with MIO in cats found a mean screw angulation of  $4.5^\circ$  (range  $-16.6^\circ$  to  $6.6^\circ$ ) in the dorsal plane and of  $1.6^\circ$  (range  $-9.7^\circ$  to  $11.7^\circ$ ) in the transverse plane.<sup>15</sup> Our study showed comparable results. Upon comparing our results with those of a cadaveric study by McCarthy et al,<sup>19</sup> our technique showed a start point translation of 1.6 mm and a deviation of  $2.2^\circ$  in dorsal plane, values which are similar to those observed in the 3DPDG group (approximately 2.5 mm and  $3.9^\circ \pm 3.2^\circ$ ). In the transverse plane, it exhibited a deviation of  $9.5^\circ$ , a value that is in the upper limit of this study, showing a mean  $\pm$  SD angle of  $5.1^\circ \pm 5.1^\circ$ ,<sup>19</sup> providing no benefit over traditional techniques (mean  $1.2^\circ \pm 0.6^\circ$ , range  $0.7^\circ$ – $2.1^\circ$ ).<sup>18</sup> Given the narrow  $0.5\text{ cm}^2$  safe corridor of the feline sacrum,<sup>5</sup> there is a potential risk of violating this area during implant placement. Alternatively, consistent results were obtained with MIO using a dedicated novel sacroiliac luxation instrument system, virtually eliminating the staff exposure to radiation.<sup>23</sup> Owing to the limitations of CT scans in accurately reproducing articular surfaces and the persistence of fibrocartilage attached to the sacrum in cases of SJ disruption,<sup>24</sup> it is advisable to conduct a thorough dissection of the lateral articular surface before placing the 3DPDG. Although a larger dissection needed for the use of the 3DPDG may still negatively impact the outcome, this was not seen in the presented case and the intraoperative placement was found to be straightforward, facilitated by the use of the sterilised sacrum print. The decision to use a 2.0 mm TP was made to achieve enhanced compression by bending the pin at a tight  $90^\circ$  at the lateral ilial surface, as recommended in a previous study.<sup>11</sup> However, it is important to note that in cases where patients present with concurrent pelvic fractures, a larger threaded implant should be chosen to provide greater stability.<sup>10</sup> A postoperative CT scan showed that the left ilium was reduced and stabilised slightly more dorsally, resulting in a less-than-ideal alignment of the SJ. Although a specific measurement for an acceptable level of malalignment in feline SIL has not been established, the minor deviation observed did not induce a detrimental outcome, such as lameness or joint pain.

## Conclusions

This case report shows that placement of a TP with the aid of a 3DPDG is feasible and may reduce the risk of dorsal or ventral deviation of the sacral safe corridor. Although this procedure excludes the exposure to

radiation, detailed MIO techniques using fluoroscopy can also completely avoid this risk and appear to provide more consistent results. Craniocaudal deviation, however, was not improved over traditional ORIF techniques without guides and as such, further improvements in the technique are warranted.

**Conflict of interest** The authors declared no potential conflicts of interest with respect to the research, authorship, and/or publication of this article.

**Funding** The authors received no financial support for the research, authorship, and/or publication of this article.

**Ethical approval** The work described in this manuscript involved the use of non-experimental (owned or unowned) animals. Established internationally recognised high standards ('best practice') of veterinary clinical care for the individual patient were always followed and/or this work involved the use of cadavers. Ethical approval from a committee was therefore not specifically required for publication in *JFMS Open Reports*. Although not required, where ethical approval was still obtained, it is stated in the manuscript.

**Informed consent** Informed consent (verbal or written) was obtained from the owner or legal custodian of all animal(s) described in this work (experimental or non-experimental animals, including cadavers, tissues and samples) for all procedure(s) undertaken (prospective or retrospective studies). For any animals or people individually identifiable within this publication, informed consent (verbal or written) for their use in the publication was obtained from the people involved.

**ORCID iD** Radu Scortea  <https://orcid.org/0009-0004-1163-812X>

Maximiljan Krauß  <https://orcid.org/0009-0007-7088-1893>

## References

- 1 Bookbinder PF and Flanders JA. **Characteristics of pelvic fracture in the cat. A 10-year retrospective study.** *Vet Comp Orthop Traumatol* 1992; 5: 122–127.
- 2 Bennett D. **Orthopaedic disease affecting the pelvic region of the cat.** *J Small Anim Pract* 1975; 16: 723–738.
- 3 Anderson A and Coughlan AR. **Sacral fractures in dogs and cats: a classification scheme and review of 51 cases.** *J Small Anim Pract* 1997; 38: 404–409.
- 4 Bird FG and de Vicente F. **Conservative management of sacroiliac luxation fracture in cats: medium- to long-term functional outcome.** *J Feline Med Surg* 2020; 22: 575–581.
- 5 Burger M, Forterre F and Brunnberg L. **Surgical anatomy of the feline sacroiliac joint for lag screw fixation of sacroiliac fracture-luxation.** *Vet Comp Orthop Traumatol* 2004; 17: 146–151.
- 6 Shales CJ, White L and Langley-Hobbs SJ. **Sacroiliac luxation in the cat: defining a safe corridor in the dorsoventral plane for screw insertion in lag fashion.** *Vet Surg* 2009; 38: 343–348.
- 7 Silveira F, Quinn RJ, Adrian AM, et al. **Evaluation of the use of intra-operative radiology for open placement of lag screws for the stabilization of sacroiliac luxation in cats.** *Vet Comp Orthop Traumatol* 2017; 30: 69–74.
- 8 Kaderly RE. **Stabilization of bilateral sacroiliac fracture-luxations in small animals with a single transsacral screw.** *Vet Surg* 1991; 20: 91–96.
- 9 Tomlinson JL, Cook JL, Payne JT, et al. **Closed reduction and lag screw fixation of sacroiliac luxations and fractures.** *Vet Surg* 1999; 28: 188–193.
- 10 Pratesi A, Grierson JM and Moores AP. **Single transsacral screw and nut stabilization of bilateral sacroiliac luxation in 20 cats.** *Vet Comp Orthop Traumatol* 2018; 31: 44–52.
- 11 Parslow A and Simpson DJ. **Bilateral sacroiliac luxation fixation using a single transiliosacral pin: surgical technique and clinical outcomes in eight cats.** *J Small Anim Pract* 2017; 58: 330–336.
- 12 Yap FW, Dunn AL, Farrell M, et al. **Trans-iliac pin/bolt/screw internal fixation for sacroiliac luxation or separation in cats: six cases.** *J Feline Med Surg* 2014; 16: 354–362.
- 13 Froidefond B, Moinard M and Caron A. **Outcomes for 15 cats with bilateral sacroiliac luxation treated with transiliosacral toggle suture repair.** *Vet Surg* 2023; 52: 983–993.
- 14 Shales C, Moores A, Kulendra E, et al. **Stabilization of sacroiliac luxation in 40 cats using screws inserted in lag fashion.** *Vet Surg* 2010; 39: 696–700.
- 15 Wills DJ, Neville-Towle J, Podadera J, et al. **Computed tomographic evaluation of the accuracy of minimally invasive sacroiliac screw fixation in cats.** *Vet Comp Orthop Traumatol* 2022; 35: 119–127.
- 16 Burger M, Forterre F, Waibl H, et al. **Sacroiliac luxation in the cat. Part 2: cases and results.** *Kleintierpraxis* 2005; 50: 287–297.
- 17 Forterre F, Tomek A, Rytz U, et al. **Iatrogenic sciatic nerve injury in eighteen dogs and nine cats (1997–2006).** *Vet Surg* 2007; 36: 464–471.
- 18 Déjardin LM, Marturello DM, Guiot LP, et al. **Comparison of open reduction versus minimally invasive surgical approaches on screw position in canine sacroiliac lag-screw fixation.** *Vet Comp Orthop Traumatol* 2016; 29: 290–297.
- 19 McCarthy DA, Granger LA, Aulakh KS, et al. **Accuracy of a drilling with a custom 3D printed guide or free-hand technique in canine experimental sacroiliac luxations.** *Vet Surg* 2022; 51: 182–190.
- 20 Gras F, Marintschev I, Wilharm A, et al. **2D-fluoroscopic navigated percutaneous screw fixation of pelvic ring injuries – a case series.** *BMC Musculoskelet Disord* 2010; 11. DOI: 10.1186/1471-2474-11-153.
- 21 DeCamp CE. **Principles of pelvic fracture management.** *Semin Vet Med Surg Small Anim* 1992; 7: 63–70.
- 22 Kudnig ST and Fitch RB. **Trans-iliac and transsacral brace fixation of sacral fractures and sacro-iliac luxations (seven cases).** *Vet Comp Orthop Traumatol* 2004; 17: 210–215.
- 23 Déjardin LM, Fauron AH, Guiot LP, et al. **Minimally invasive lag screw fixation of sacroiliac luxation/fracture using a dedicated novel instrument system: apparatus and technique description.** *Vet Surg* 2018; 47: 93–103.
- 24 Evans HE and de Lahunta A (eds). **Hip joint.** In: Miller's anatomy of the dog – e-book. UK: Elsevier Health Sciences, 2012, p 176.