



Subcutaneous ureteral bypass for treatment of proximal ureteral obstruction secondary to retroperitoneal fibrosis after renal transplantation in a cat

Authors: Laminette, Peter J, and Hardie, Robert J

Source: Journal of Feline Medicine and Surgery Open Reports, 10(2)

Published By: SAGE Publishing

URL: <https://doi.org/10.1177/20551169241265244>



Subcutaneous ureteral bypass for treatment of proximal ureteral obstruction secondary to retroperitoneal fibrosis after renal transplantation in a cat

Journal of Feline Medicine and Surgery Open Reports
1–7

© The Author(s) 2024

Article reuse guidelines:

sagepub.com/journals-permissions

DOI: 10.1177/20551169241265244

journals.sagepub.com/home/jfmsopenreports

This paper was handled and processed by the American Editorial Office (AAFP) for publication in *JFMS Open Reports*



Peter J Laminette and Robert J Hardie

Abstract

Case summary A 5.5-year-old male neutered domestic shorthair cat was presented with a 2-year history of progressive chronic kidney disease. Abdominal ultrasonography revealed bilateral chronic renal degeneration, nephrolithiasis, cortical hyperechogenicity and infarction. Left orthotopic renal transplantation was performed using the Synovis vascular coupling system for end-to-end anastomosis of the renal arteries and veins. Two months after transplantation, renal values were elevated, and abdominal ultrasonography revealed hydronephrosis and hydroureter of the transplanted kidney. Fluoroscopic antegrade pyelography identified a proximal ureteral stricture. Proximal neoureterocystostomy was performed and renal values normalized postoperatively. The cat was re-evaluated for acute stranguria and severe azotemia 12 months later. Contrast-enhanced CT revealed severe hydronephrosis of the transplanted kidney, obstruction of the proximal ureter and adhesions to the urinary bladder. Upon exploration, retroperitoneal fibrosis was found covering the transplanted kidney. Given the clinical situation, a subcutaneous ureteral bypass device (SUB) was placed. Clinicopathologic analyses, trough cyclosporine levels, aerobic urine cultures and ultrasonographic evaluations of the transplanted kidney were monitored every 1–3 months. Patency of the SUB was reassessed every 3–6 months. At 15 months after placement, the SUB occluded due to kinking of the cystostomy catheter and was replaced. At 28 months after SUB placement, renal function and clinical status deteriorated, and the cat was euthanized.

Relevance and novel information To the authors' knowledge, this is the first report of a SUB device being used for management of ureteral obstruction in a transplanted kidney in a cat.

Keywords: Renal transplantation; subcutaneous ureteral bypass; vascular coupling; retroperitoneal fibrosis; ureteral obstruction

Accepted: 12 June 2024

Case description

A 5.5-year-old male neutered domestic shorthair cat was referred to the University of Wisconsin-Madison School of Veterinary Medicine for renal transplantation. The cat had a 2-year history of progressive azotemia, elevated urine protein:creatinine ratio (UPC), micro-albuminuria and mild hypertrophic obstructive cardiomyopathy, but no significant clinical signs. The cat was current on all vaccines and feline leukemia virus (FeLV)/feline immunodeficiency virus (FIV)/feline calicivirus

(FCV) and toxoplasmosis titers were negative, and thyroid hormone levels were normal (thyroxine 1.1 µg/dl;

University of Wisconsin-Madison, School of Veterinary Medicine, Department of Surgical Sciences, Madison, WI, USA

Corresponding author:

Robert J Hardie DVM, DACVS, DECVS, University of Wisconsin-Madison, School of Veterinary Medicine, Department of Surgical Sciences, 2015 Linden Drive, Madison, WI 53706, USA
Email: robert.hardie@wisc.edu



Creative Commons Non Commercial CC BY-NC: This article is distributed under the terms of the Creative Commons

Attribution-NonCommercial 4.0 License (<https://creativecommons.org/licenses/by-nc/4.0/>) which permits non-commercial use, reproduction and distribution of the work without further permission provided the original work is attributed as specified on the SAGE and Open Access pages (<https://us.sagepub.com/en-us/nam/open-access-at-sage>).

reference interval [RI] 0.8–4.0). The cat's blood type was A. Prior treatment included calcitriol (12 ng/kg PO q48h), benazepril (1.1 mg/kg PO q24h) and potassium gluconate (1/2 tsp PO q12h).

On physical examination, the cat was alert and responsive with normal vital signs and a grade 3/6 systolic sternal heart murmur. A complete blood count (CBC) and chemistry panel revealed moderate anemia (hematocrit 25%, RI 31–48) and azotemia (blood urea nitrogen [BUN] 100 mg/dl, RI 15–35; creatinine 6.6 mg/dl, RI 0.9–2.3); other findings were normal. Urinalysis revealed isosthenuria (urine specific gravity [USG] 1.010, RI 1.015–1.060) and proteinuria (UPC 0.5, RI <0.5).

Thoracic radiographs were normal, and echocardiography revealed no contraindications to surgery. Abdominal ultrasonography revealed a severely atrophied left kidney (length 2.34 cm) with pyelectasia (0.23 cm). The right kidney was mildly enlarged (length 3.43 cm) with pyelectasia (0.5 cm). There was nephrolithiasis and markedly decreased corticomedullary distinction bilaterally, with no apparent hydronephrosis or ureterolithiasis.

Pre-transplant management

A 9-month-old 5.0 kg male intact domestic shorthair cat was identified as a suitable donor with type A blood and compatible crossmatch. Additional donor screening, including a CBC, chemistry panel, urinalysis, urine culture, abdominal ultrasonography, and FeLV/FIV/FCV and toxoplasmosis titers, was normal. Pre-transplant treatment for the recipient included 0.45% NaCl (constant-rate infusion [CRI] at 2 ml/kg/h IV) supplemented with potassium chloride (40 mEq/l), cefazolin (20 mg/kg IV q8h), prednisolone (0.25 mg/kg PO q12h, starting 24 h before transplantation), cyclosporine microemulsion (Atopica; Novartis) (4 mg/kg PO q12h, starting 12 h before transplantation), calcitriol (6 ng/kg PO q24h) and amoxicillin–clavulanate (13.75 mg/kg PO q12h). The day before surgery, the recipient's packed cell volume (PCV) had decreased to 16%. The cat received a whole blood transfusion (10 ml/kg IV once) from the donor cat.

Donor procedure

Under general anesthesia, the left kidney and ureter, including the ureteral papilla, were removed. The harvested kidney was then flushed and immersed in cold sucrose phosphate buffer solution and surrounded by ice until transplantation.¹ Postoperative management included 0.45% NaCl (CRI at 2 ml/kg/h IV), fentanyl (CRI at 2–5 µg/kg/h IV), ketamine (CRI at 2–10 µg/kg/min IV) and serial bloodwork to monitor PCV/total solids (TS), creatinine and BUN levels.

Recipient procedure

Under general anesthesia, the left kidney was removed and orthotopic transplantation was performed using a

microvascular coupling system (Synovis) for end-to-end anastomosis of the renal artery and vein.^{2,3} A 2.0 mm and 3.0 mm coupler were used for the renal artery and vein, respectively. Neoureterocystostomy was performed via extravesicular ureteral papilla implantation.^{4,5} Immediately after transplantation, the kidney was adequately perfused with normal color, consistency and urine output. Heparin (10 mg/kg SC q8h) was administered immediately after transplantation, and postoperative analgesia was provided by fentanyl (CRI at 3 µg/kg/h IV for 12 h). Dopamine (CRI at 5–10 µg/kg/min IV) and dobutamine (CRI at 2–5 µg/kg/min IV) were continued 6 h after surgery because of hypotension.

Initial outcome

A chemistry panel evaluated 24 h after transplantation revealed a normal creatinine value (2.2 mg/dl, RI 0.9–2.3). Recheck renal ultrasonography was performed 1, 8 and 18 days postoperatively, revealing normal renal perfusion, resistive indices, architecture and size (length 5.0 cm) for the transplanted kidney. Two days postoperatively, the cat's PCV decreased to 15%, requiring a second whole blood transfusion (10 ml/kg IV, once). Trough cyclosporine levels were monitored every 24–48 h, and doses were adjusted to achieve target concentrations of 250–600 ng/ml. A recheck CBC and chemistry panel before discharge revealed an improved hematocrit (30%, RI 31–48) and a normal creatinine value (1.3 mg/dl, RI 0.9–2.3). The cat was discharged 4 weeks after presentation with instructions to recheck renal function, cyclosporine levels and ultrasonographic evaluations of the transplanted kidney periodically. Cyclosporine trough levels were measured lifelong every 2–8 weeks and doses were adjusted as needed to maintain levels within the desired range.

Two-month follow-up

The cat was referred 2 months after transplantation for evaluation of azotemia and hydronephrosis of the transplanted kidney. Ongoing immunosuppression included prednisolone (0.25 mg/kg PO q12h) and cyclosporine (3 mg/kg PO q12h). The physical examination was unremarkable. A chemistry panel revealed marked azotemia (BUN 118 mg/dl, RI 15–35; creatinine 7.2 mg/dl, RI 0.9–2.3). PCV was 28% and TS was 7.8 g/dl. Urinalysis revealed dilute urine (USG 1.013, RI 1.015–1.060) with trace protein. Urine culture revealed no growth.

Abdominal ultrasonography and fluoroscopic antegrade pyelography revealed moderate hydronephrosis and hydronephrosis of the transplanted kidney due to a proximal ureteral stricture (Figure 1). The transplanted kidney measured 6 cm in length (previously 5 cm) with dilation of the renal pelvis (1.5 cm) and ureter (0.37 cm) proximal to the stricture.

To relieve the ureteral obstruction, the ureter was transected immediately proximal to the stricture and reimplanted using an intravesicular mucosal apposition neoureterocystostomy. The resected distal ureter was submitted for histopathology, which revealed marked chronic lymphoplasmacytic ureteritis with circumferential fibrosis. The cat recovered from surgery

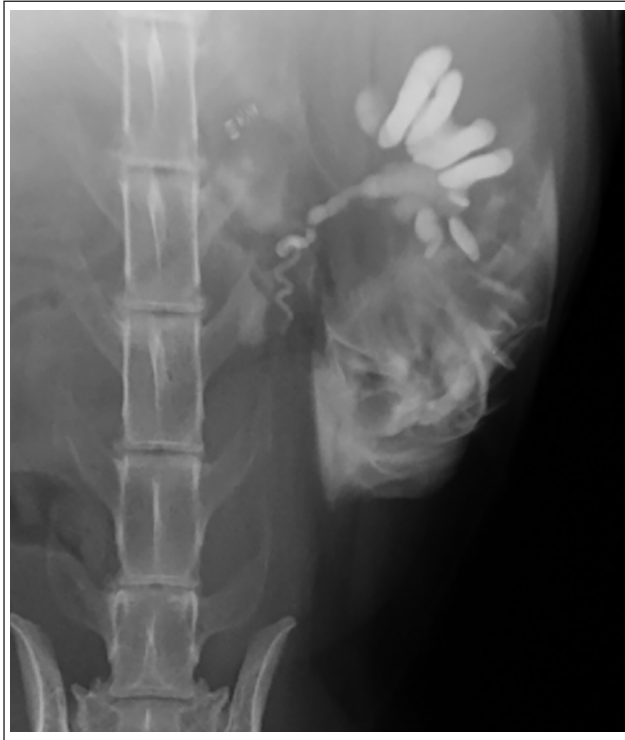

Figure 1 Ultrasound-guided antegrade pyelography of the transplanted left kidney in a 5.5-year-old male neutered domestic shorthair cat that was referred 2 months after transplantation because of acute hydronephrosis and azotemia. Antegrade pyelography revealed obstruction of flow at the level of the L5 vertebral body with no contrast within the urinary bladder. Contrast medium is extravasated into the surrounding caudodorsal tissues after removing the spinal needle from the renal pelvis

and was discharged 9 days after presentation with an improved creatinine value (2.0 mg/dl, RI 0.9–2.3).

Fourteen-month follow-up

The cat was re-examined 14 months after transplantation owing to acute azotemia, stranguria and pollakiuria. Ongoing immunosuppression included prednisolone (0.22 mg/kg PO q12h) and cyclosporine (0.8 mg/kg PO q12h). The physical examination was unremarkable. A chemistry panel revealed marked azotemia (BUN 53 mg/dl, RI 15–35; creatinine 5.5 mg/dl, RI 0.9–2.3). Abdominal ultrasonography (Figure 2) and contrast CT of the abdomen (Figure 3) revealed severe hydronephrosis of the transplanted kidney (length 7.0 cm) with marked dilation of the renal pelvis (3 cm). The apex of the urinary bladder was adhered to the caudal aspect of the kidney and a proximal ureteral obstruction prevented contrast from entering the bladder.

SUB placement

The abdomen was explored and fibrosis surrounding the hilum and proximal ureter of the transplanted kidney made it unfeasible for stent placement or a second ureteral reimplantation (Figure 4). A subcutaneous ureteral bypass device (SUB 2.0; Norfolk Vet Products) was implanted for urinary diversion as previously described, with the exception that the nephrostomy catheter was placed in the cranial pole of the kidney due to the fibrosis overlying the caudal pole.⁶ Intraoperative fluoroscopy confirmed patency of the SUB with no leakage (Figure 5). A 3.5 Fr urethral catheter was placed to measure urine output and minimize bladder expansion in the perioperative period. Urine culture obtained intraoperatively revealed no growth. The cat was discharged 6 days after presentation with improved BUN (31 mg/dl, RI 15–35) and creatinine (2.7 mg/dl, RI 0.9–2.3) values.

SUB follow-up

Renal function and the status of the transplanted kidney were monitored closely with periodic chemistry

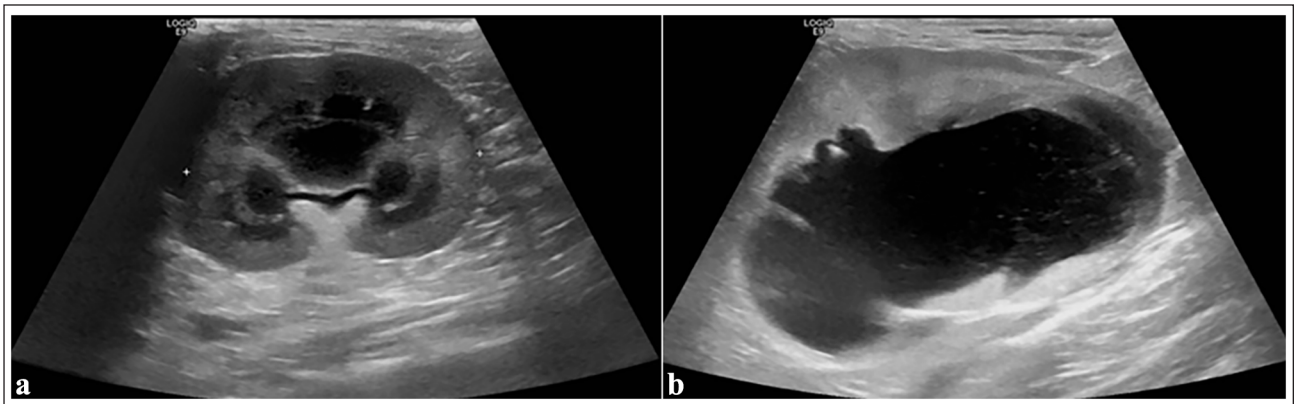


Figure 2 Sagittal ultrasonographic images of the transplanted kidney (a) 24 h and (b) 14 months after transplantation. (b) Note the severe hydronephrosis and loss of renal architecture of the transplanted left kidney due to a proximal ureteral obstruction secondary to retroperitoneal fibrosis

panel, cyclosporine level, urine culture and ultrasonographic evaluations. Patency of the SUB was reassessed every 3–6 months via ultrasonography and the device was flushed with 2% tetrasodium ethylenediaminetetraacetic acid solution.

The cat was re-evaluated 15 months after SUB placement for acute azotemia (BUN 96mg/dl, RI 15–35; creatinine 5.2mg/dl, RI 0.9–2.3). Fluoroscopic pyelography identified marked hydronephrosis of the transplanted kidney and kinking of the distal cystostomy catheter. The entire SUB was replaced (Figure 6), and the azotemia subsequently improved (BUN 70mg/dl, RI 15–35; creatinine 3.3mg/dl, RI 0.9–2.3) before discharge.

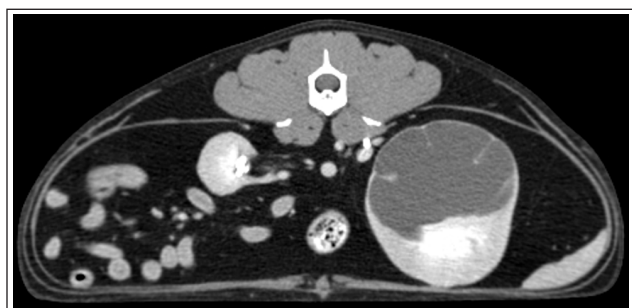

Figure 3 Transverse CT image of the transplanted left kidney 14 months after transplantation. Note the severe hydronephrosis with marked distension of the renal pelvis due to a proximal ureteral obstruction secondary to retroperitoneal fibrosis

At 13 months after replacement of the SUB, the cat declined acutely and was euthanized because of progressive anorexia, weight loss and deterioration in kidney function. The final chemistry panel revealed worsening azotemia (BUN 73mg/dl, RI 15–35; creatinine 5.2mg/dl, RI 0.9–2.3).

Discussion

To the authors' knowledge, this is the first report describing placement of a SUB in a transplanted kidney in a cat. The SUB provided a successful means of urinary diversion despite the presence of severe retroperitoneal fibrosis (RF). RF can be a serious complication after kidney transplantation in cats, often leading to some degree of ureteral obstruction, and has been reported in 7–21% of cases.^{7–9} In humans, this condition is primarily idiopathic, but can be associated with operative trauma, infection, medications, malignant disease or other retroperitoneal insults.^{10,11}

In this cat, histopathology of the resected ureter would suggest an immune-mediated and rejection-type reaction within the layers of the ureter leading to the first obstruction. Subtherapeutic trough cyclosporine levels (233, 227 and 185ng/ml) were recorded on three occasions prior to the first ureteral obstruction (2 months). While cyclosporine levels were not persistently low over that time, insufficient immunosuppression may have contributed to the development of RF. The severity of RF made it impossible to isolate the

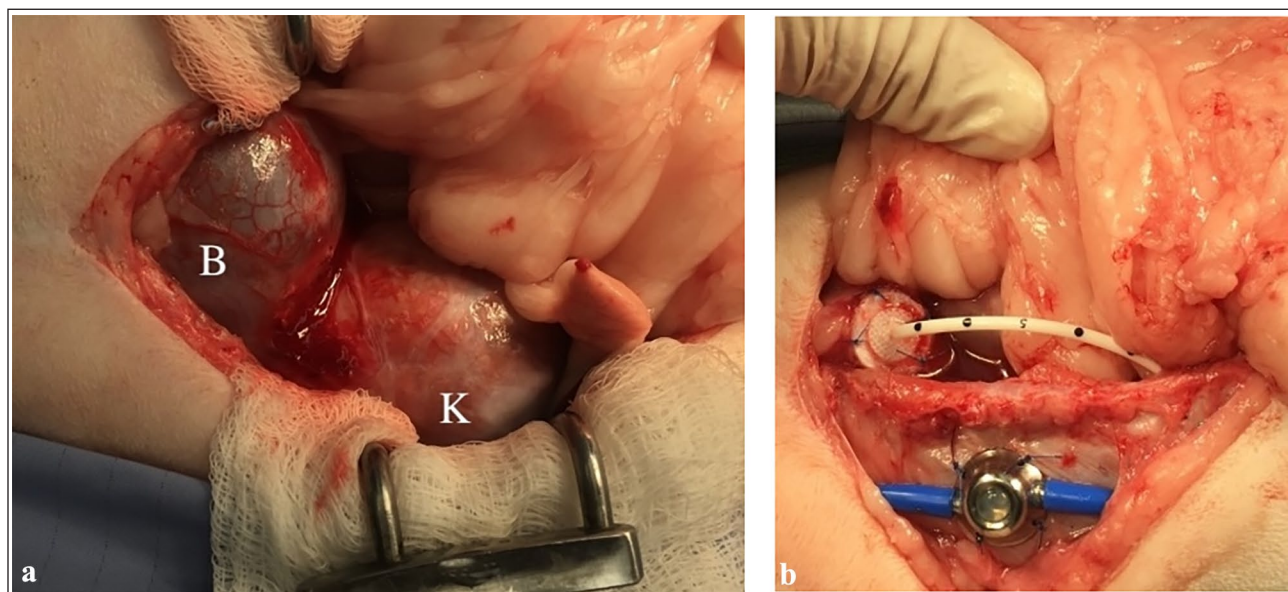


Figure 4 Intraoperative images obtained during placement of the subcutaneous ureteral bypass (SUB) device in the transplanted kidney for treatment of ureteral obstruction: (a) note the retroperitoneal fibrosis and adhesion of the bladder (B) to the caudal pole of the transplanted left kidney (K); (b) image of the SUB device with the nephrostomy and cystostomy catheters tunneling through the abdominal wall and connected to the injection port positioned subcutaneously

ureter and relieve the second ureteral obstruction by ureterolysis or ureteral reimplantation. Other possible options for urinary diversion, including vesicocalicostomy, pyelovesicostomy or nephrocystostomy, were not considered at the time.^{12–15}

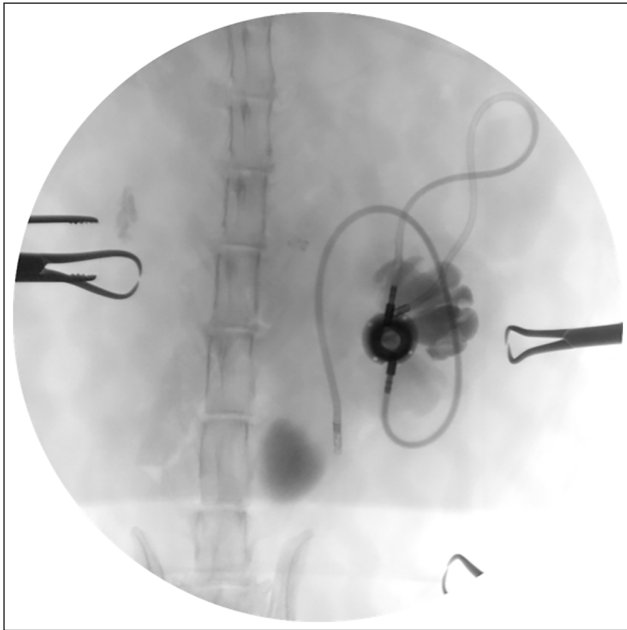


Figure 5 Intraoperative ventrodorsal fluoroscopic image of the subcutaneous ureteral bypass (SUB) device. Injection of contrast medium into the SUB port confirms patency of the nephrostomy and cystostomy catheters before completing the procedure. Note the degree of hydronephrosis in the transplanted kidney

The primary concern with placing a SUB in a transplanted kidney is the potential increased risk of urinary tract or systemic infection due to the immunosuppression required to prevent allograft rejection. Long-term risks of infection with SUB placement in immunosuppressed patients are not well documented; however, chronic urinary tract infections have been reported in up to 8–26% of immune-competent cats that underwent SUB placement for benign ureteral obstruction.^{6,16} Additional experience with a larger population would be required to determine whether urinary tract infections associated with SUB devices are a relative rather than absolute risk in cats after kidney transplantation.

This report is also the first to describe use of the Synovis coupling system for vascular anastomosis of the transplanted kidney. Removal of the severely atrophied, non-functional native left kidney made it possible to use the microvascular coupler in an end-to-end fashion for orthotopic transplantation rather than the typical hand-sutured, end-to-side technique for heterotopic transplantation.³ The coupler system creates an everted anastomosis that, in the human literature, is reported to lead to fewer complications associated with thrombosis and is more efficient than traditional hand-sutured anastomosis.^{17–26} By reducing the technical challenge of vascular anastomosis procedures, use of the coupler system may potentially improve the feasibility and outcomes of renal transplant procedures overall.³

Conclusions

In this case, the SUB provided a successful means for bypassing the ureteral obstruction and the cat maintained a good quality of life for an additional 28 months

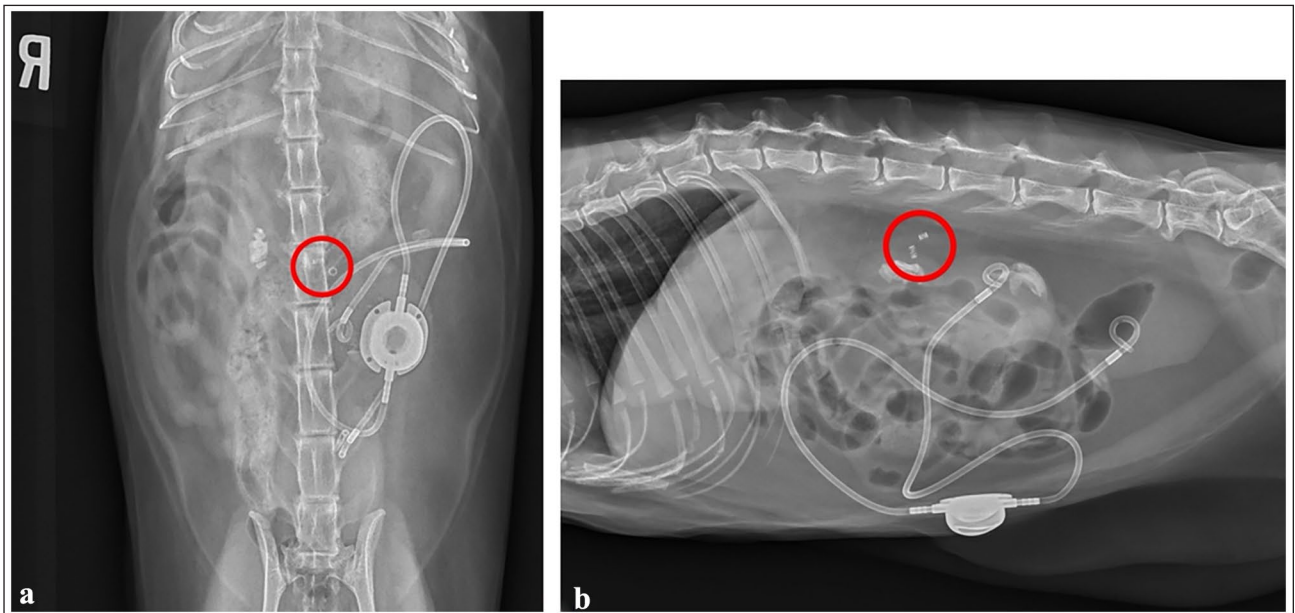


Figure 6 (a) Ventrodorsal and (b) lateral postoperative radiographic views of the abdomen after replacing the previously obstructed subcutaneous ureteral bypass (SUB) device. The revised SUB device is correctly positioned. Note the two metal attenuating coupler devices seen joining the native and transplanted left renal artery and vein (red circles)

(42 months total). The median survival time (MST) for cats after renal transplantation is in the range of 12–21 months, with approximately 40% of cats surviving 3 years.^{27–31} Unfortunately, the multiple episodes of ureteral obstruction likely led to cumulative damage and a shortened lifespan for the transplanted kidney and patient. Overall, the SUB device was effective for urinary diversion and provides a therapeutic option when other conventional techniques for managing ureteral obstruction have failed or are not possible.

Conflict of interest The authors declared no potential conflicts of interest with respect to the research, authorship, and/or publication of this article.

Funding The authors received no financial support for the research, authorship, and/or publication of this article.

Ethical approval The work described in this manuscript involved the use of non-experimental (owned or unowned) animals. Established internationally recognized high standards ('best practice') of veterinary clinical care for the individual patient were always followed and/or this work involved the use of cadavers. Ethical approval from a committee was therefore not specifically required for publication in *JFMS Open Reports*. Although not required, where ethical approval was still obtained, it is stated in the manuscript.

Informed consent Informed consent (verbal or written) was obtained from the owner or legal custodian of all animal(s) described in this work (experimental or non-experimental animals, including cadavers) for all procedure(s) undertaken (prospective or retrospective studies). For any animals or people individually identifiable within this publication, informed consent (verbal or written) for their use in the publication was obtained from the people involved.

References

- 1 Csomos RA, Hardie RJ, Schmiedt CW, et al. **Effect of cold storage on immediate graft function in an experimental model of renal transplantation in cats.** *Am J Vet Res* 2017; 78: 330–339.
- 2 Bernstein L, Gregory CR, Pollard RE, et al. **Comparison of two surgical techniques for renal transplantation in cats.** *Vet Surg* 1999; 28: 417–420.
- 3 Mickelson MA, Hardie RJ, Hespel AM, et al. **Evaluation of a microvascular anastomotic coupler for end-to-side arterial and venous anastomosis for feline renal transplantation.** *Vet Surg* 2021; 50: 213–222.
- 4 Hardie RJ, Schmiedt CW, Phillips L, et al. **Ureteral papilla implantation as a technique for neoureterocystostomy in cats.** *Vet Surg* 2005; 34: 393–398.
- 5 Sutherland BJ, McAnulty JF and Hardie RJ. **Ureteral papilla implantation as a technique for neoureterocystostomy in cats undergoing renal transplantation: 30 cases.** *Vet Surg* 2016; 45: 443–449.
- 6 Berent AC, Weisse CW, Bagley DH, et al. **Use of a subcutaneous ureteral bypass device for treatment of benign ureteral obstruction in cats: 174 ureters in 134 cats (2009–2015).** *J Am Vet Med Assoc* 2018; 253: 1309–1327.
- 7 Byer BJ, Hardie RJ and McAnulty JF. **Retroperitoneal fibrosis as a postoperative complication following renal transplantation in cats.** *J Feline Med Surg* 2022; 24: 304–310.
- 8 Wormser C, Phillips H and Aronson LR. **Retroperitoneal fibrosis in feline renal transplant recipients: 29 cases (1998–2011).** *J Am Vet Med Assoc* 2013; 243: 1580–1585.
- 9 Aronson LR. **Retroperitoneal fibrosis in four cats following renal transplantation.** *J Am Vet Med Assoc* 2002; 221: 984–989.
- 10 Vaglio A, Salvarani C and Buzio C. **Retroperitoneal fibrosis.** *Lancet* 2006; 367: 241–251.
- 11 Mizushima I and Kawano M. **Renal involvement in retroperitoneal fibrosis: prevalence, impact and management challenges.** *Int J Nephrol Renovasc Dis* 2021; 14: 279–289.
- 12 Hardie RJ, Schmiedt CW, Gendron KP, et al. **Evaluation of two nephrocystostomy techniques for ureteral bypass in cats.** *Vet Surg* 2023; 52: 961–971.
- 13 Diaz EC, Susan S, Patel NS, et al. **Laparoscopic-assisted vesicocalicostomy for severe pelvi-ureteral stricture disease.** *JSLS* 2012; 16: 163–165.
- 14 Krocak T, Koulack J and McGregor T. **Management of complicated ureteric strictures after renal transplantation: case series of pyelovesicostomy with Boari flap.** *Transplant Proc* 2015; 47: 1850–1853.
- 15 Higgins MM, Walker JP, and Daily MF, et al. **Open vesicocalicostomy for the management of transplant ureteral stricture.** *Urol Case Rep* 2017; 13: 74–76.
- 16 Wuillemin F, Vachon C, Beauchamp G, et al. **Subcutaneous ureteral bypass device placement in 81 cats with benign ureteral obstruction (2013–2018).** *J Vet Intern Med* 2021; 35: 2778–2786.
- 17 Ardehali B, Morritt AN and Jain A. **Systematic review: anastomotic microvascular device.** *J Plast Reconstr Aesthet Surg* 2014; 67: 752–755.
- 18 Zhang T, Lubek J, Salama A, et al. **Venous anastomoses using microvascular coupler in free flap head and neck reconstruction.** *J Oral Maxillofac Surg* 2012; 70: 992–996.
- 19 Jandali S, Wu LC, Vega SJ, et al. **1000 consecutive venous anastomoses using the microvascular anastomotic coupler in breast reconstruction.** *Plast Reconstr Surg* 2010; 125: 792–798.
- 20 Rozen WM, Whitaker IS and Acosta R. **Venous coupler for free-flap anastomosis: outcomes of 1,000 cases.** *Anticancer Res* 2010; 30: 1293–1294.
- 21 O'Connor EF, Rozen WM, Chowdhry M, et al. **The microvascular anastomotic coupler for venous anastomoses in free flap breast reconstruction improves outcomes.** *Gland Surg* 2016; 5: 88–92.
- 22 Maruccia M, Fatigato G, Elia R, et al. **Microvascular coupler device versus hand-sewn venous anastomosis: a systematic review of the literature and data meta-analysis.** *Microsurgery* 2020; 40: 608–617.
- 23 Kulkarni AR, Mehrara BJ, Pusic AL, et al. **Venous thrombosis in handsewn versus coupled venous anastomoses in 857 consecutive breast free flaps.** *J Reconstr Microsurg* 2016; 32: 178–182.
- 24 Yap LH, Constantinides J and Butler CE. **Venous thrombosis in coupled versus sutured microvascular anastomoses.** *Ann Plast Surg* 2006; 57: 666–669.
- 25 Yuan XP, Gao W, Jiao WH, et al. **Kidney transplantation in diabetic recipients with iliac atherosclerosis:**

- arterial anastomosis with Nakayama's ring pin stapler after endarterectomy. *Int J Urol* 2012; 19: 336–342.
- 26 Ye G, Mo HG, Wang ZH, et al. **Arterial anastomosis without sutures using ring pin stapler for clinical renal transplantation: comparison with suture anastomosis.** *J Urol* 2006; 175: 636–640.
- 27 Schmiedt CW, Holzman G, Schwarz T, et al. **Survival, complications, and analysis of risk factors after renal transplantation in cats.** *Vet Surg* 2008; 37: 683–695.
- 28 Snell W, Aronson L, Phillips H, et al. **Influence of anesthetic variables on short-term and overall survival rates in cats undergoing renal transplantation surgery.** *J Am Vet Med Assoc* 2015; 247: 267–277.
- 29 Mathews KG and Gregory CR. **Renal transplants in cats: 66 cases (1987–1996).** *J Am Vet Med Assoc* 1997; 211: 1432–1436.
- 30 Aronson LR, Kyles AE, Preston A, et al. **Renal transplantation in cats with calcium oxalate urolithiasis: 19 cases (1997–2004).** *J Am Vet Med Assoc* 2006; 228: 743–749.
- 31 Adin CA, Gregory CR, Kyles AE, et al. **Diagnostic predictors of complications and survival after renal transplantation in cats.** *Vet Surg* 2001; 30: 515–521.