



Long-lasting hypoaldosteronism after adrenalectomy in a cat with hyperaldosteronism

Authors: Bouccara, Léa, Dunie-Merigot, Antoine, Poujol, Laure, Blond, Laurent, and Jolivet, Franck

Source: Journal of Feline Medicine and Surgery Open Reports, 10(1)

Published By: SAGE Publishing

URL: <https://doi.org/10.1177/20551169241243012>



Long-lasting hypoaldosteronism after adrenalectomy in a cat with hyperaldosteronism

Léa Bouccara , Antoine Dunie-Merigot, Laure Poujol, Laurent Blond and Franck Jolivet

Journal of Feline Medicine and Surgery Open Reports
1–6

© The Author(s) 2024

Article reuse guidelines:

sagepub.com/journals-permissions

DOI: 10.1177/20551169241243012

journals.sagepub.com/home/jfmsopenreports

This paper was handled and processed by the European Editorial Office (ISFM) for publication in *JFMS Open Reports*



Abstract

Case summary A 10-year-old neutered male domestic shorthair cat was presented with an abdominal mass, associated renal failure, chronic vomiting, anorexia and progressive polyuria/polydipsia lasting for 3 weeks. Clinical examination and initial blood work revealed azotaemia, hypokalaemia and hypertension. Abdominal ultrasound showed an adrenal mass with a diameter of 3 cm near the right kidney. High serum aldosterone suggested primary hyperaldosteronism. Surgery enabled identification of the mass and its excision along with the right adrenal gland. Histologically, carcinoma of the adrenal cortex was diagnosed. Postoperatively, an increase in serum creatinine and potassium, along with a low serum aldosterone, led to a diagnosis of hypoaldosteronism. Mineralocorticoid therapy for 6 months was necessary, resulting in clinical and biological improvement.

Relevance and novel information To our knowledge, this case describes the longest-lasting reported secondary hypoaldosteronism in a cat, after unilateral adrenalectomy for an adrenal carcinoma with hyperaldosteronism.

Keywords: Hypokalaemia; systemic hypertension; endocrinology; surgical management

Accepted: 13 March 2024

Case description

A 10-year-old neutered male domestic shorthair cat was presented for investigation of chronic vomiting, anorexia and progressive polyuria/polydipsia over a period of 3 weeks. The referring veterinarian performed an abdominal ultrasound, which revealed a mass with a diameter of 3 cm near the right kidney.

Physical examination was unremarkable. Given the chronic vomiting, anorexia, polyuria/polydipsia and the abdominal mass, biochemistry, complete blood count (CBC), urine analysis and blood pressure measurement were performed. Biochemistry revealed moderate azotaemia (serum creatinine 234.3 $\mu\text{mol/l}$, reference interval [RI] 70.7–212.2) and hypokalaemia (2.9 mmol/l, RI 3.5–5.8). Urinalysis showed low urine specific gravity (1.012). CBC was unremarkable. The mean systolic blood pressure was over 220 mmHg (RI 80–160) when measured by Doppler sphygmomanometry.

An abdominal ultrasound revealed a right adrenal mass measuring 3.5 cm (Figure 1). The contralateral (left) adrenal gland was below the RI (approximately 0.2 cm in

height, RI 0.35–0.45) (Figure 2). The right kidney was small (2.8 cm, RI 3–4) and irregular. The left kidney was enlarged (5.1 cm).

Given the clinical presentation, biochemistry and abdominal ultrasound findings, a serum aldosterone test was run and was found to be severely elevated (>5000 pmol/l, RI 87–224), which was compatible with primary hyperaldosteronism.

Medical management

The cat received potassium supplementation (4 mEq K/cat PO q12h; K for Cat, MP Labo), spironolactone (2 mg/kg PO q12h; Prilactone Next 10 mg, Ceva) and amlodipine (1.25 mg/cat PO q24h; Amodip, Ceva) for 1 month preoperatively.

Centre Hospitalier Vétérinaire Languedoc, Montpellier, France

Corresponding author:

Léa Bouccara DVM, Centre Hospitalier Vétérinaire Languedoc, 470 rue Favre de Saint-Castor, Montpellier, 34080, France
Email: lea.bouccara@gmail.com



Creative Commons Non Commercial CC BY-NC: This article is distributed under the terms of the Creative Commons

Attribution-NonCommercial 4.0 License (<https://creativecommons.org/licenses/by-nc/4.0/>) which permits non-commercial use, reproduction and distribution of the work without further permission provided the original work is attributed as specified on the SAGE and Open Access pages (<https://us.sagepub.com/en-us/nam/open-access-at-sage>).

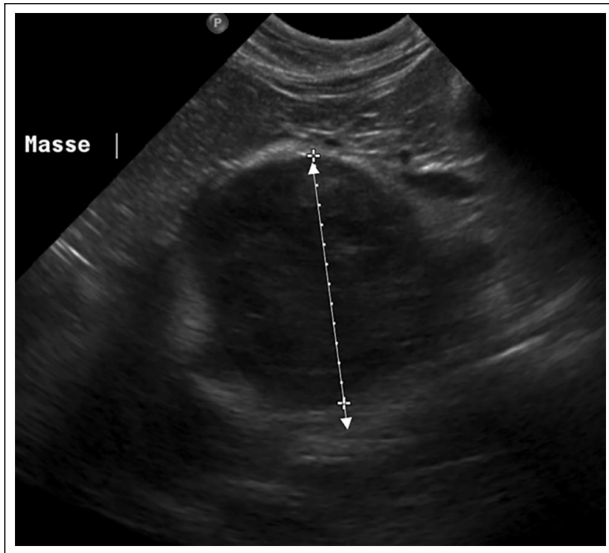


Figure 1 Feline abdominal ultrasound. The double arrow shows a right adrenal mass measuring 3.5 cm

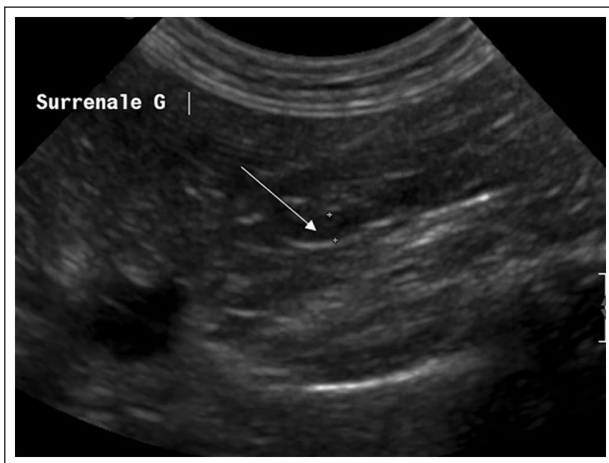


Figure 2 Feline abdominal ultrasound. The arrow shows a small left adrenal gland (approximately 1 cm)

One week after starting medical therapy, serum potassium and blood pressure were within the normal range (4 mmol/l and 150 mmHg, respectively).

Surgical management

Thoracic, abdominal and brain CT were performed before surgery to assess for possible vascular invasion of the adrenal mass and possible lung and/or cerebro meningeal metastasis. The adrenal mass was 5–6 cm in diameter, encompassing the right kidney with adhesions to the caudal vena cava and abdominal aorta (Figures 3 and 4). The cat received enoxaparin (100 UI/kg SC q8h; Lovenox, Sanofi) 48 and 24 h before surgery, as well as on the day of the procedure. Methadone (0.2 mg/kg IV; Comfortan, Dechra),

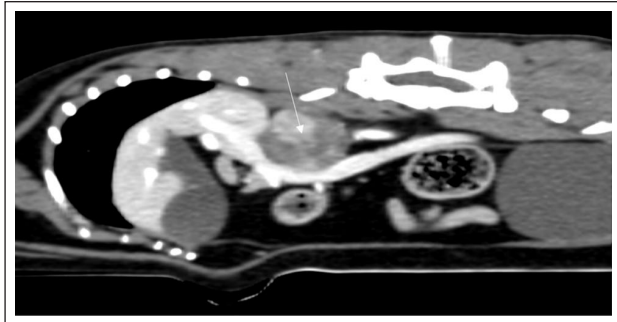


Figure 3 Abdominal CT examination, parasagittal image. The arrow shows a mass measuring 5–6 cm, encompassing the right kidney close to the vena cava and aorta

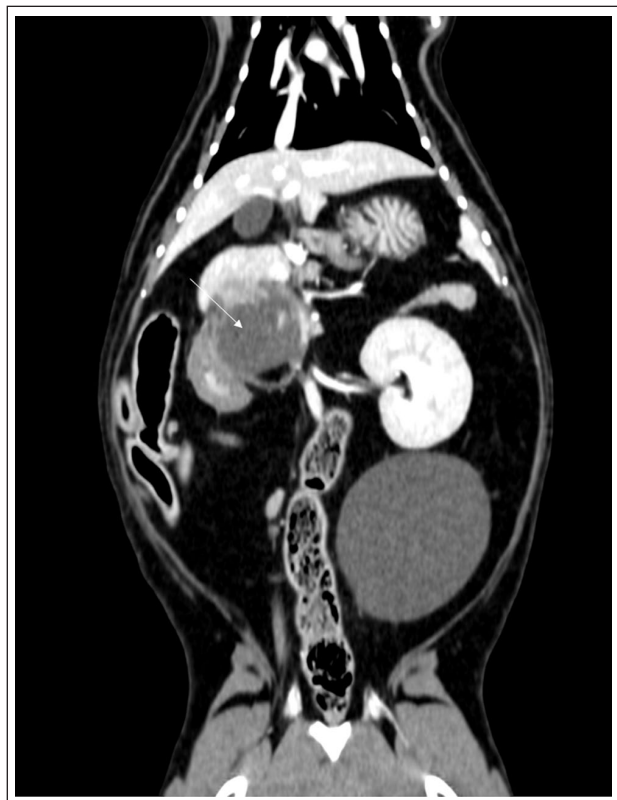


Figure 4 Abdominal CT examination, dorsal image. The arrow shows a mass measuring 5–6 cm, encompassing the right kidney

midazolam (0.3 mg/kg IV; Mylan) and propofol (4 mg/kg IV; Proposure, Axience) followed by isoflurane gas with tracheal intubation were used for the general anaesthesia. A xyphopubic laparotomy allowed visualisation of a right adrenal mass of 5 cm in diameter, firmly attached to the right kidney, caudal venal cava and abdominal aorta.

Soft tissue dissection allowed a monobloc resection of the mass (adrenal gland and right kidney) after ligation of the phrenico-abdominal vein, the renal vein, a branch

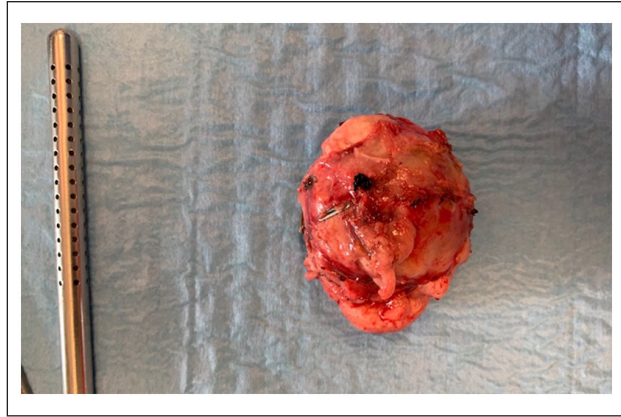


Figure 5 A right adrenal mass after surgery, which measured 5 cm, isolated from the right kidney and vessels

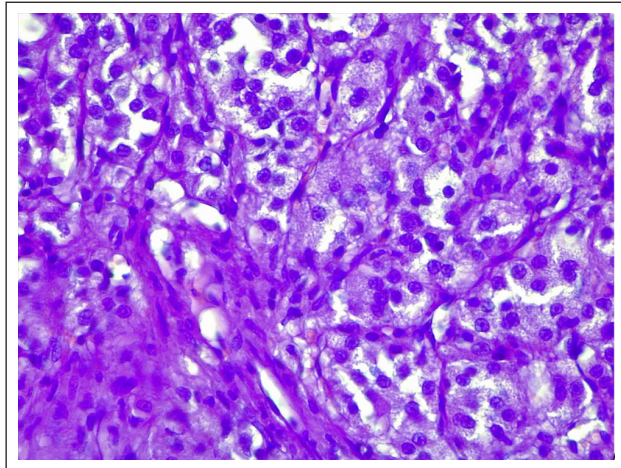


Figure 6 Histological analysis of an adrenal mass at 400 \times magnification reveals infiltration of the renal capsule by a nodular neof ormation that is non-encapsulated and poorly delineated. Tumour proliferation closely mimics the endocrinoid architecture of the corticoadrenal region, with small nests juxtaposed with well-differentiated tumour epithelial cells. These findings strongly suggest corticoadrenal carcinoma

of a right hepatic vein and the renal artery (Figure 5). The mass was dissected off the aorta and vena cava to enable en-bloc resection. The right ureter was ligated and removed. The rest of the laparotomy did not identify any other abnormalities. Histopathological analysis revealed a corticoadrenal carcinoma (LAPVSO) (Figure 6).

Histopathological analysis revealed a cortico-adrenal carcinoma (Laboratoire d'Anatomie Pathologique Vétérinaire du Sud-Ouest [LAPVSO]) (Figure 6).

Buprenorphine (0.02 mg/kg IV q8h; Vetergesic, Ceva) was given for 3 days postoperatively. Twenty-four hours after surgery, the cat became more alert. Electrolytes, serum creatinine and blood pressure had normalised

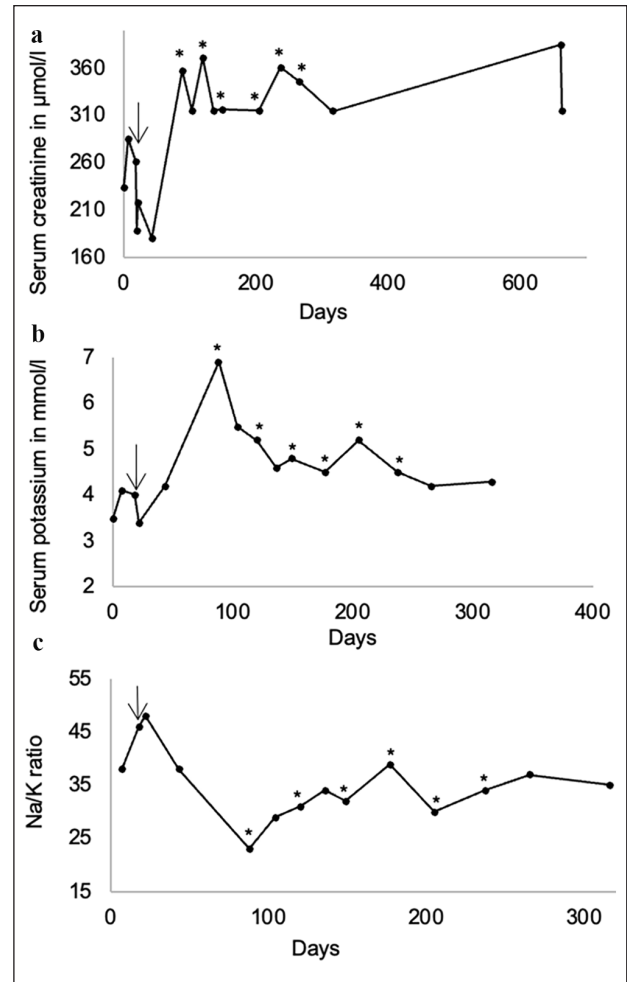


Figure 7 (a) Serum creatinine, (b) serum potassium and (c) Na:k ratio vs time graph. Day 0 is the cat's first presentation; the arrow is on the day of the surgery. The asterisk represents desoxycorticosterone pivalate injections

(Figure 7a,b). Prednisolone (0.5 mg/kg then 0.28 mg/kg PO q24h; Dermipred, Ceva) was also given.

At postoperative day 4, an increase in serum creatinine was observed (218.3 µmol/l) and blood pressure was normal (140 mmHg). At postoperative day 25, the cat was clinically normal, and serum potassium, creatinine and blood pressure were stable (4.2 mmol/l, 180.3 µmol/l and 152 mmHg, respectively) (Figure 7a,b).

At postoperative day 70, the cat vomited three times a week over a period of 10 days and serum creatinine increased (358 µmol/l) (Figure 7a). Serum potassium also increased (6.9 mmol/l), with a low Na:K ratio (23, RI >27) (Figure 7b,c). An adrenocorticotropic hormone (ACTH) stimulation test was performed and a normal response was observed (pre-ACTH cortisol 41.4 nmol/l, post-ACTH cortisol 144.2 nmol/l, RI 40–138). Serum aldosterone was less than 20 pmol/l (RI 87–224), compatible with hypoaldosteronism. Desoxycorticosterone

Table 1 Prednisolone tapering protocol used after surgery (hypoaldosteronism was diagnosed 2 months [70 days] after surgery)

Time after surgery (months)	0	1	2	3	4	5	6
Prednisolone dosage	0.5 mg/kg q24h then 0.28 mg/kg q24h	0.28 mg/kg q24h	0.28 mg/kg q24h	0.19 mg/kg q24h	0.19 mg/kg every other day	0.19 mg/kg twice a week	Stop

pivalate was administered at 1.5 mg/kg SC (Zycortal, Dechra) and glucocorticoid supplementation was continued (prednisolone, 0.28 mg/kg PO q24h; Dermipred, Ceva). At 15 days after injection, normonatremia and normokalaemia, with a normal Na:K ratio of 29, were observed. Serum creatinine had decreased to 315.6 $\mu\text{mol/l}$ but was still elevated. One month later, a second injection of desoxycorticosterone pivalate was administered at the same dosage. Serum creatinine and potassium were 371.3 $\mu\text{mol/l}$ and 5.2 mmol/l, respectively, with an Na:K ratio of 31 (Figure 7) supporting an appropriate dosage interval. The interval between two injections was considered correct. A total of six injections of desoxycorticosterone pivalate were needed, with one injection every 4 weeks. Prednisolone was tapered then stopped 6 months postoperatively (Table 1). At 920 days after diagnosis and 640 days after the last desoxycorticosterone pivalate injection, the cat was clinically normal with serum potassium and sodium within the reference interval (K 4.3 mmol/l, Na 150 mmol/l, Na/K 35) (Figure 7) but persistently elevated creatinine.

Discussion

Of interest in this case is the chronic clinical hypoaldosteronism observed after unilateral adrenalectomy for primary hyperaldosteronism, with a prolonged need for mineralocorticoid supplementation. This emphasises the need for close monitoring not only in the short term, but also the medium to long term.

Secondary hypoaldosteronism developing after adrenalectomy is well described in human medicine, even if it is unusual: only 16% of patients that underwent adrenalectomy developed hypoaldosteronism, and only 5% of them required treatment.¹⁻³ Short-term postoperative hypoaldosteronism has been described in cats but often with low clinical relevance and rarely needing medical supplementation with mineralocorticoids.⁴ If treatment is needed, it is often short-term and usually involves oral fludrocortisone.⁵ However, one recent study mentioned three cases of clinical hypoaldosteronism secondary to adrenalectomy requiring long-term treatment, with one cat treated until its death at 5 months post adrenalectomy.⁶ The proposed pathophysiology for postoperative hypoaldosteronism is suppression of zona glomerulosa cells by the contralateral neoplastic adrenal gland with

failure of these cells to resume function after surgery. The use of preoperative spironolactone could have a protective effect on the juxtaglomerular apparatus by correcting the metabolic disorders caused by excessive aldosterone. It prevents the juxtaglomerular apparatus from being fully suppressed preoperatively and resumes subnormal function postoperatively with an exaggerated release of renin in the early postoperative stage while zona glomerular cell activity is still low.^{3,7} This may explain the late onset of hypoaldosteronism in our case. Hypoaldosteronism might have several consequences, including decreased renal perfusion and progression of kidney disease. Treatment is based on clinical signs, cortisolemia and aldosteronaemia. In our case, the use of mineralocorticoids was necessary, with desoxycorticosterone pivalate. In dogs, a starting dose of 1.5 mg/kg every 28 days is frequently used.⁸⁻¹² Recently, a study on hypoadrenocorticism in cats recommended a higher starting dose of desoxycorticosterone pivalate than in dogs (1.5 mg/kg in dogs vs 2.2 mg/kg in cats) but the doses of desoxycorticosterone pivalate at the end of the follow-up period varied, between 1.3 and 3.0 mg/kg.¹³ In our case, the latter paper had not been published, and we chose the canine dose of 1.5 mg/kg, which proved effective. Low-dose glucocorticoid supplementation was also maintained based on clinical response. Rechecks of blood pressure plus serum electrolytes and creatinine were performed every 2 weeks and then monthly, with the dose of desoxycorticosterone pivalate adjusted accordingly. In our case, glucocorticoid supplementation and mineralocorticoid treatment resulted in rapid clinical and biological improvement. Prednisolone was tapered and then stopped 6 months after surgery. The dose of desoxycorticosterone pivalate was reduced to 1.3 mg/kg 7 months after surgery and then stopped 1 month later. No further administration was necessary, as electrolyte concentrations remained normal and the cat was clinically well.

Aldosterone promotes kaliuresis and increases peripheral vascular resistance.¹⁴ Signs of hypokalaemia and/or systemic hypertension are regularly observed with hyperaldosteronism.¹⁴⁻¹⁶ In cats, persistent weakness due to hypokalaemic polymyopathy is the most common clinical sign, with severe hypertension reported in up to 85% of cases.^{14,15,17-19}

Moderate to marked azotaemia and creatine kinase increased activity may also be observed.²⁰

The gold standard for diagnosing primary hyperaldosteronism is based on the association of clinical signs consistent with hyperaldosteronism, increased basal plasma aldosterone concentration, decreased plasma renin concentration and visualisation of an adrenal tumour.^{21–23}

The use of plasma renin activity (PRA) helps differentiate a primary vs secondary hyperaldosteronism. PRA is below or within the reference intervals for primary hyperaldosteronism, and is increased for hyperaldosteronism secondary to chronic renal disease, heart failure or other conditions that stimulate the renin–angiotensin–aldosterone system.

However, very few laboratories are able to measure plasma renin activity and this was not available in our case. Moreover, in our case, International Renal Interest Society (IRIS) stage 3 chronic kidney disease was suspected and could have led to a difficult interpretation of PRA.

The management of primary hyperaldosteronism in cats starts with the medical management of electrolyte disorders and hypertension using intravenous or oral potassium supplementation and amlodipine.¹⁶ We also chose to add spironolactone as a competitive antagonist of aldosterone. In cats and dogs, medical treatment alone allows an estimated survival time of 7 months to 2.5 years for adenoma or adenocarcinoma of the adrenal gland with hyperaldosteronism.^{19,24}

After medical stabilisation, adrenalectomy remains the treatment of choice in both species and is associated with the resolution of primary hyperaldosteronism and with prolonged median survival in cats with a unilateral adrenal mass.^{14,16,24,25} Survival rates have significantly improved over the past 10 years: (60–80% between 2002 and 2013 vs 97% in 2023).^{19,24,25} In our case, a nephrectomy was performed as well as an adrenalectomy due to the size of the tumour and its adhesion to the right kidney. Perioperative and postoperative complications were not observed in our case, but complications have been reported in 17–47% of cases, including anorexia, vomiting, hyperthermia, abdominal haemorrhage, acute renal failure, sepsis and thromboembolism.^{17,24,25} The management of tumour metastases and thrombi is important, as the presence of thrombi can increase complications.²⁶ Heparin and/or clopidogrel 48–72h preoperatively is recommended; in our case, the cat received enoxaparin 48 h and 24 h before surgery, as well as on the day of the procedure.²⁷ The median postoperative survival is approximately 3.5 years, with our case still alive 2.5 years after surgery.

Conclusions

To our knowledge, this case describes the longest-lasting reported secondary hypoaldosteronism in a cat, after unilateral adrenalectomy for an adrenal carcinoma with hyperaldosteronism. Here, hypoaldosteronism resolved

9 months after surgery and required six injections of desoxycorticosterone pivalate. Although this complication is rare in humans and cats, and most do not need long-term medical management after unilateral adrenalectomy, this case illustrates that some may need careful postoperative monitoring for many months.

Acknowledgements We extend our appreciation to those whose contributions were integral to the development of this case report. The LAPVSO histopathology deserves special acknowledgment for their expertise in analysing the adrenal mass, providing vital histological insights that have enriched the content of this report. We thank Dr Frédérique Degorce-Rubiales for graciously sharing the histology photos, thereby enhancing the visual representation of the case. Her collaboration significantly elevated the quality and depth of our presentation. We would also like to express our gratitude to Dr Sonia Coignet for referring this noteworthy case.

Conflict of interests The authors declared no potential conflicts of interest with respect to the research, authorship, and/or publication of this article.

Funding The authors received no financial support for the research, authorship, and/or publication of this article.

Ethical approval The work described in this manuscript involved the use of non-experimental (owned or unowned) animals. Established internationally recognised high standards ('best practice') of veterinary clinical care for the individual patient were always followed and/or this work involved the use of cadavers. Ethical approval from a committee was therefore not specifically required for publication in *JFMS Open Reports*. Although not required, where ethical approval was still obtained, it is stated in the manuscript.

Informed consent Informed consent (verbal or written) was obtained from the owner or legal custodian of all animal(s) described in this work (experimental or non-experimental animals, including cadavers) for all procedure(s) undertaken (prospective or retrospective studies). No animals or people are identifiable within this publication, and therefore additional informed consent for publication was not required.

ORCID iD Léa Bouccara  <https://orcid.org/0000-0002-1109-6488>

References

- 1 Goncalves JA, Barrros R, Ferreira B, et al. **Severe hypoaldosteronism after unilateral adrenalectomy for primary hyperaldosteronism.** *Endocrine Abstracts* 2017; 49. DOI: 10.1530/endoabs.49.EP30.
- 2 Shrikrishna N, Koko N, Jones E, et al. **Case of prolonged hypoaldosteronism after unilateral adrenalectomy for Conn's syndrome.** *Endocrine Abstracts* 2016; 44. DOI: 10.1530/endoabs.44.EP9.
- 3 Yorke E, Stafford S, Holmes D, et al. **Aldosterone deficiency after unilateral adrenalectomy for Conn's syndrome: a case report and literature review.** *Int J Surg Case Rep* 2015; 7: 141–144.

- 4 Daniel G, Mahony OM, Markovich JE, et al. **Clinical findings, diagnostics and outcome in 33 cats with adrenal neoplasia (2002–2013).** *J Feline Med Surg* 2016; 18: 77–84.
- 5 Niessen SJM. **Hyperaldosteronism in cats.** Proceedings of the World Small Animal Veterinary Association World Congress, Cape Town, South Africa, 16 September 2014.
- 6 Harro CC, Refsal KR, Shaw N, et al. **Retrospective study of aldosterone and progesterone secreting adrenal tumors in 10 cats.** *J Vet Intern Med* 2021; 35: 2159–2166.
- 7 Morimoto S, Takeda R and Murakami M. **Does prolonged pretreatment with large doses of spironolactone hasten a recovery from juxtaglomerular-adrenal suppression in primary aldosteronism?** *J Clin Endocrinol Metab* 1970; 31: 659–664.
- 8 Bates J, Shott S and Schall W. **Lower initial dose desoxycorticosterone pivalate for treatment of canine primary hypoadrenocorticism.** *Aust Vet J* 2013; 91: 77–82.
- 9 Jaffey J, Nurre P, Cannon A, et al. **Desoxycorticosterone pivalate duration of action and individualized dosing intervals in dogs with primary hypoadrenocorticism.** *J Vet Intern Med* 2017; 31: 1649–1657.
- 10 Sieber-Ruckstuhl NS, Reusch CE, Hofer-Inteeworn N, et al. **Evaluation of a low-dose desoxycorticosterone pivalate treatment protocol for long-term management of dogs with primary hypoadrenocorticism.** *J Vet Intern Med* 2019; 33: 1266–1271.
- 11 Münch L, Münch M, Paul H, et al. **Therapy of primary hypoadrenocorticism in dogs with low dose desoxycorticosterone pivalate [in German].** *Tierarztl Prax Ausg K Kleintiere Heimtiere* 2020; 48: 171–175.
- 12 Vincent AM, Okonkowski LK, Brudvig JM, et al. **Low-dose desoxycorticosterone pivalate treatment of hypoadrenocorticism in dogs: a randomized controlled clinical trial.** *J Vet Intern Med* 2021; 35: 1720–1728.
- 13 Sieber-Ruckstuhl NS, Harburger L, Hofer N, et al. **Clinical features and long-term management of cats with primary hypoadrenocorticism using desoxycorticosterone pivalate and prednisolone.** *J Vet Intern Med* 2023; 37: 420–427.
- 14 Kooistra HS. **Primary hyperaldosteronism in cats: an underdiagnosed disorder.** *Vet Clin North Am Small Anim Pract* 2020; 50: 1053–1063.
- 15 Harvey AM and Refsal KR. **Primary hyperaldosteronism.** In: Rand J, Behrend E, Gunn-Moore D, et al. (eds). *Clinical endocrinology of companion animals.* Ames, IA: John Wiley & Sons, 2014, pp 115–127.
- 16 Behrend E. **Non-cortisol-secreting adrenocortical tumors and incidentalomas.** In: Ettinger SJ and Feldman EC (eds). *Textbook of veterinary internal medicine.* St Louis, MO: Elsevier, 2017, pp 1819–1825.
- 17 Ash RA, Harvey AM and Tasker S. **Primary hyperaldosteronism in the cat: a series of 13 cases.** *J Feline Med Surg* 2005; 7: 173–182.
- 18 Fryers A and Elwood C. **Hypokalaemia in a hyperthyroid domestic shorthair cat with adrenal hyperplasia.** *J Feline Med Surg* 2014; 16: 853–857.
- 19 Djajadiningrat-Laanen S, Galac S and Kooistra H. **Primary hyperaldosteronism: expanding the diagnostic net.** *J Feline Med Surg* 2011; 13: 641–650.
- 20 Javadi S, Djajadiningrat-Laanen SC, Kooistra HS, et al. **Primary hyperaldosteronism, a mediator of progressive renal disease in cats.** *Domest Anim Endocrinol* 2005; 28: 85–104.
- 21 Fabrès V, Dumont R, Garcia M, et al. **Evaluation of oral telmisartan administration as a suppression test for diagnosis of primary hyperaldosteronism in cats.** *J Vet Intern Med* 2023; 37: 1341–1347.
- 22 Djajadiningrat-Laanen SC, Galac Boevé MH, et al. **Evaluation of the oral fludrocortisone suppression test for diagnosing primary hyperaldosteronism in cats.** *J Vet Intern Med* 2013; 27: 1493–1499.
- 23 Briscoe K, Barrs VR, Foster DF, et al. **Hyperaldosteronism and hyperprogesteronism in a cat.** *J Feline Med Surg* 2009; 11: 758–762.
- 24 Lo AJ, Holt DE, Brown DC, et al. **Treatment of aldosterone-secreting adrenocortical tumors in cats by unilateral adrenalectomy: 10 cases (2002-2012).** *J Vet Intern Med* 2014; 28: 137–143.
- 25 Del Magno S, Foglia A, Rossanese M, et al. **Surgical findings and outcomes after unilateral adrenalectomy for primary hyperaldosteronism in cats: a multi institutional retrospective study.** *J Feline Med Surg* 2023; 25. DOI: 10.1177/1098612X221135124.
- 26 Adin C and Nelson R. **Adrenal gland.** In: Johnston SA and Tobias K (eds). *Veterinary surgery: small animal.* St Louis, MO: WB Saunders, 2012, pp 2284–2285.
- 27 Hackner S and DiFazio J. **Bleeding and hemostasis.** In: Johnston SA and Tobias K (eds). *Veterinary surgery: small animal.* St Louis, MO: WB Saunders, 2012, pp 124–125.