



Giant splenic myelolipoma in a cat with hyperthyroidism

Authors: Rolph, Kerry E, Vidana, Beatriz, and Field, Elinor

Source: Journal of Feline Medicine and Surgery Open Reports, 8(2)

Published By: SAGE Publishing

URL: <https://doi.org/10.1177/20551169221127889>



Giant splenic myelolipoma in a cat with hyperthyroidism

Kerry E Rolph¹ , Beatriz Vidana² and Elinor Field³

Journal of Feline Medicine and Surgery Open Reports
1–6

© The Author(s) 2022

Article reuse guidelines:

sagepub.com/journals-permissions

DOI: 10.1177/20551169221127889

journals.sagepub.com/home/jfmsopenreports

This paper was handled and processed

by the European Editorial Office (ISFM)

for publication in *JFMS Open Reports*



Abstract

Case summary A 15 shorthair cat presented after having fallen down the stairs. Examination by the referring veterinarian had demonstrated tachycardia and a large abdominal mass. The cat was referred for investigations. Blood tests demonstrated hyperthyroidism. A large, poorly vascularised abdominal mass was identified on ultrasonography. The mass was hyperechoic compared with the normal liver; however, the origin could not be determined. Fine-needle aspirate biopsies of the mass demonstrated extramedullary haematopoiesis. Surgical exploration revealed a 12 cm × 8 cm × 8 cm pale mass arising from the spleen. Histopathology determined this was a giant splenic myelolipoma.

Relevance and novel information Splenic myelolipoma is rarely reported in the domestic cat, with only five cases documented within the literature, and none of these having described giant myelolipoma. Indeed, giant myelolipomas are rarely reported in the human literature and are most commonly adrenal in origin. The pathogenesis of these masses is unclear; there have been several incidences in people with endocrine disorders, and it has been hypothesised that their occurrence may be related to endocrine stimulation. Here we report the first case of giant myelolipoma in a hyperthyroid cat.

Keywords: Splenic myelolipoma; endocrine; hyperthyroidism; syncope; collapse

Accepted: 6 September 2022

Introduction

Myelolipomas are considered a rare, benign variant of adipose tumours, which contain additional haematopoietic elements.¹ They are most commonly small tumours (<5 cm) and incidental findings on post-mortem or ultrasound examination.^{1–3} However, in some instances they can become large and occasionally present with haemorrhagic complications.^{4–7} Giant myelolipomas are masses measuring >10 cm.⁸ In humans, myelolipomas are reported to occur predominantly within the adrenal gland, with occasional reports of extra-adrenal myelolipoma.³ To date, the human medical literature contains only four cases of myelolipoma occurring in the spleen.^{5,9–11} The pathogenesis of myelolipoma formation has been debated; postulated mechanisms for the formation of these masses include metaplasia of reticuloendothelial cells within the adrenal glands (due to stress, infection, trauma or embolism of bone marrow cells) or abnormalities in endocrine function, most frequently increased levels of adrenocorticotrophic hormone (ACTH), or potentially *MEN1* dysregulation.¹

There are no reports of adrenal myelolipoma in cats. However, there are occasional reports of hepatic myelolipomas.^{7,12–18} Several of these have been associated with peritoneopericardial diaphragmatic hernias.^{12,15,18} Splenic myelolipomas have been reported in dogs^{19–22} and in the cheetah.^{23,24} There are two cases of splenic myelolipoma reported within the domestic cat literature,^{6,25} and a further three cases noted in large case series reporting ultrasonographic findings or surgical outcomes.^{26–28}

¹Center for Integrative Mammalian Research, Ross University School of Veterinary Medicine, Basseterre, St Kitts, West Indies

²Faculty of Health Sciences, Bristol Veterinary School, University of Bristol, Bristol, UK

³Highcroft Veterinary Referrals, Bristol, UK

Corresponding author:

Kerry E Rolph BVM&S, Cert VC, PhD, FANZCVS (Feline Chapter), DipECVIM-Ca, FRCVS, Center for Integrative Mammalian Research, Ross University School of Veterinary Medicine, P.O. Box 334, Basseterre, St Kitts, West Indies
Email: krolph@rossvet.edu.kn



Creative Commons Non Commercial CC BY-NC: This article is distributed under the terms of the Creative Commons

Attribution-NonCommercial 4.0 License (<https://creativecommons.org/licenses/by-nc/4.0/>) which permits non-commercial use, reproduction and distribution of the work without further permission provided the original work is attributed as specified on the SAGE and Open Access pages (<https://us.sagepub.com/en-us/nam/open-access-at-sage>).

To date, these reports have not documented any endocrine abnormalities within the affected cases. Furthermore, where reported, the majority of the splenic tumours have been small (0.5 cm and 2 cm, respectively),²⁵ with only one large (9.5 cm)⁶ and no giant splenic myelolipoma having been reported.

Case description

A 15-year-old female neutered cat presented to the referring veterinarian for a suspected syncopal episode. Prior to this episode the cat had been well; it was not receiving any medications or supplements, and did not have any significant previous illnesses. It had been rehomed as an adult cat and, at that time, had one fixed dilated pupil, with no pupillary light reflex or menace. The owner reported that on the day of presentation, she had heard a noise as if 'someone' had fallen down the stairs; on investigation, the cat was found collapsed at the foot of the stairway. Initially, it had been unsteady on its feet but started walking soon after. In addition, there was a recent history of weight loss and diarrhoea. The cat was reported to be eating normally and was otherwise well.

Physical examination revealed a good body condition (body condition score 4/9), with some prominence of the dorsal spinous processes, leading to the suspicion of recent weight loss. Hydration status appeared normal. Mucous membranes were pink and capillary refill time was <2 s. All palpable lymph nodes were unremarkable. There was a slightly increased respiratory effort, with a mild expiratory wheeze. The respiratory rate was 36 breaths per minute. Heart rate was increased at 280 beats per minute, with synchronous, good-quality pulses and no abnormalities on auscultation. Abdominal palpation demonstrated a large abdominal mass, which prevented the palpation of other abdominal structures.

The cat was admitted to the hospital. Doppler blood pressure assessment revealed a systolic blood pressure of 130 mmHg. Routine haematology did not demonstrate any significant abnormalities. Prothrombin time and activated partial thromboplastin time were within normal limits (7 s and 12 s, respectively). Serum biochemistry demonstrated a mild decrease in urea (5.7 mmol/l; reference interval [RI] 6.1–12.5); elevated alkaline phosphatase (101 U/l; RI 11–67); elevated alanine transaminase (221 U/l; RI 18–77); elevated bilirubin (18.8 µmol/l; RI 0–10); decreased albumin (25.7 g/l; RI 26–42); normal globulin (39.2 g/l; RI 19–46); and elevated total thyroxine (157.6 nmol/l; RI 7.5–55). In-house feline leukaemia virus/feline immunodeficiency virus testing was negative. Ultrasonography demonstrated a large, homogeneous mass filling most of the abdominal cavity. The cat appeared uncomfortable when the abdomen was compressed and therefore only a cursory ultrasonographic examination was permitted. The origin of the mass could not be ascertained. Some apparently normal hepatic

parenchyma was visible; the mass was hyperechoic in comparison to this. In addition, the gastric wall and urinary bladder were visualised, and reported to be normal. There was no free fluid visualised. Fine-needle aspirates were obtained, which demonstrated extramedullary haematopoiesis but no other abnormalities.

The cat was blood typed (type B) and anaesthetised for surgery. A midline coeliotomy was performed. On inspection of the abdomen, a large (12 × 8 × 8 cm) splenic mass was identified. The liver also appeared mildly mottled on inspection. A splenectomy was performed (Figure 1) routinely using a combination of electrosurgery (Ligasure; Covidien) and suture ligation with polydioxanone (PDS; Ethicon). A liver biopsy was taken and closure was routine. Surgery was uneventful, with minimal bleeding. Methadone was administered preoperatively and continued for 24 h postoperatively, prior to switching to buprenorphine. In addition, the cat was maintained on intravenous fluids, and eye lubricant (Lacri-lube) was administered every 4 h (as per hospital policy). One day postoperatively the cat developed a 2 mm punctate ulcer in its left eye and therefore famciclovir was added to the treatment plan for suspected herpesvirus recrudescence. The cat was discharged that evening with oral buprenorphine to be applied to the mucous membranes, and famciclovir. The splenic mass and liver biopsy were submitted for histopathology. The mass was identified as a myelolipoma and consisted of an unencapsulated, moderately cellular mass composed of sheets of mature adipocytes admixed with myeloid and erythroid haematopoietic cells in various stages of maturation on a scant fibrovascular stroma (Figure 2). Both progenitor and precursor cells were observed and included nucleated erythrocytes, blasts and megakaryocytes, and mature red blood cells admixed with small amounts of eosinophilic proteinaceous fluid and golden-to-brown pigment (Figure 3). Cellular atypia was minimal and mitotic figures were extremely rare (≤ 1 per 2.37 mm²). The mass was well demarcated with a sharp distinction between the neoplastic tissue and the normal splenic parenchyma (Figure 4).

The liver biopsy demonstrated a minimal-to-mild periportal lymphoplasmacytic infiltration consistent with mild lymphoplasmacytic cholangitis. This histopathological change was considered an incidental finding.

A recheck appointment was arranged 1 week after discharge. At this time the owner felt that the cat was clinically normal. It was started on medical management for hyperthyroidism. The liver parameters were reassessed after stabilisation of the hyperthyroidism, and had returned to normal. Therefore, no medications were administered for the mild lymphoplasmacytic cholangitis.

Over the following 3 years the cat was seen regularly for rechecks of the hyperthyroidism. During this time it

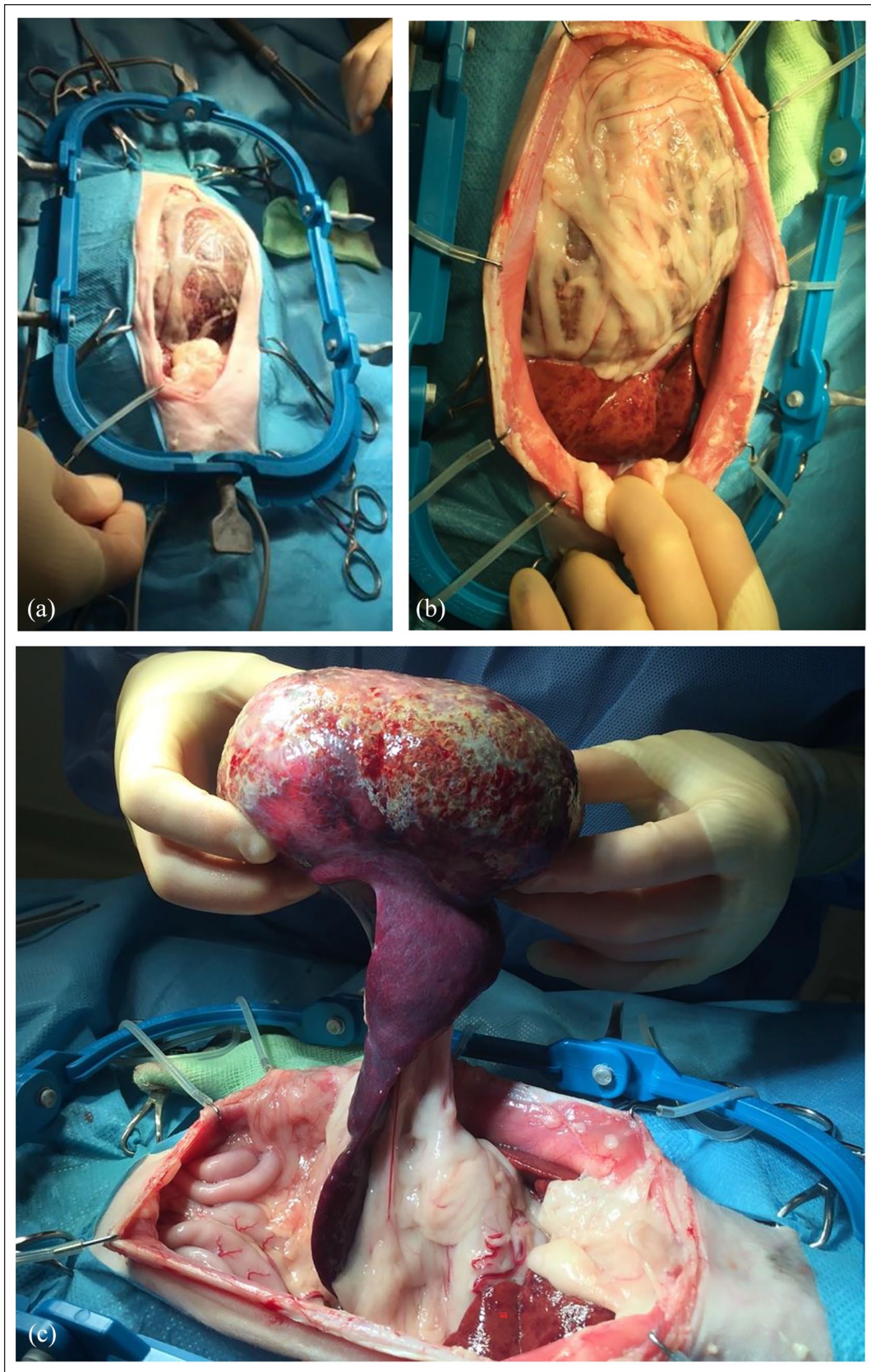


Figure 1 Surgical removal of the giant myelolipoma. (a,b) A large mass in situ compressing other intra-abdominal structures is shown. The mottling of the hepatic parenchyma can be appreciated. (c) The 12 × 8 × 8 cm mass arising from the ventral pole of the spleen is shown. The normal-appearing spleen can be seen below

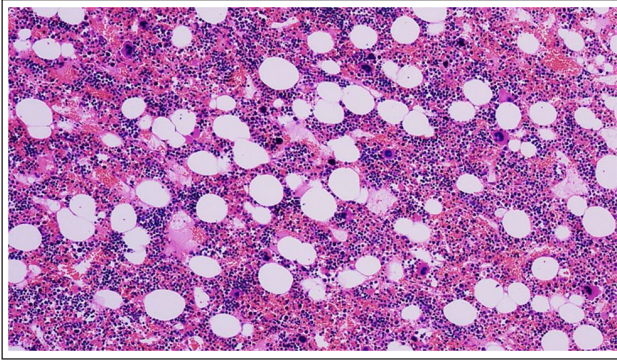


Figure 2 Splenic mass. Myelolipoma composed of adipocytes and hematopoietic cells on a scant fibrovascular stroma (haematoxylin and eosin, $\times 10$ power field)

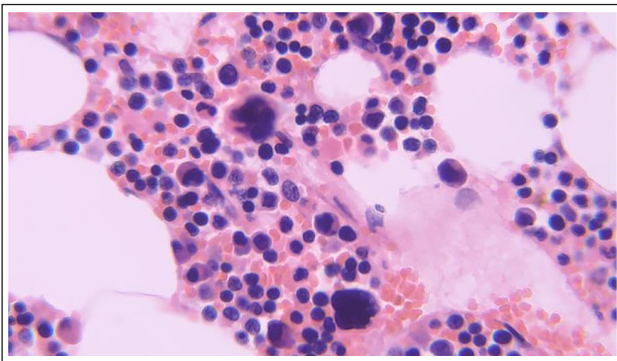


Figure 3 Detailed image of cells comprising the neoplasm. Adipocytes, erythroid and myeloid precursors, including megakaryocytes, blasts and mature erythrocytes admixed with eosinophilic proteinaceous material (haematoxylin and eosin, $\times 60$ power field)

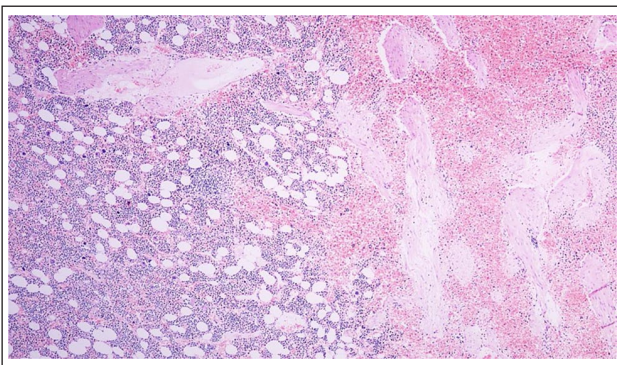


Figure 4 Clear demarcation between normal splenic parenchyma (right side of image) and neoplastic cell population (left side of image; haematoxylin and eosin, $\times 4$ power field)

developed hypertension, which was managed with amlodipine, and International Renal Interest Society stage 2 chronic kidney disease. The cat also demonstrated hindlimb lameness, thought to be due to osteoarthritis, and had intermittent episodes of diarrhoea. It

was euthanased 3 years after the diagnosis of splenic myelolipoma; there was no suggestion of further masses.

Discussion

There are few reports of myelolipoma occurring within the domestic cat, and the majority of these report masses within the liver.^{7,12–18,25} However, there are some references within diagnostic imaging texts which suggest that they are subclinical, small, static lesions, identified as incidental findings on ultrasonography.² The pathogenesis of myelolipomas is unknown. It has been suggested that the lesions originate from metaplastic transformation of a resident cell population. Some myelolipomas grow to reach large sizes, such as the neoplasia observed in this case, and behave like a neoplasm. In contrast, some myelolipomas are small and multiple, and considered metaplastic or hamartomatous.^{29–31} This report documents the first giant myelolipoma in the spleen of a cat. These benign masses can lead to complications associated with size or haemorrhage.^{6,7,12,15,17,18} There are two previous reports of haemoabdomen occurring in cats with myelolipomas.^{6,7} One of these was a mass within the liver,⁷ whereas the other case had two large myelolipomas identified within the spleen (4.5 cm and 9.5 cm, respectively).⁶ In the case reported here, there were no suggestions of haemorrhage (no free fluid within the abdominal cavity; despite a low serum albumin, globulin and haematocrit were normal). It was unclear why the cat had initially fallen down the stairs but, in light of the above findings, it was suspected that this was a vagal event.

Splenectomy is well tolerated in the cat. In one report the median survival time post-splenectomy was 197 days (range 2–1959); however, of the 19 cats included in that report 16 underwent surgery for malignant mass removal (10 cats had a mast cell tumour, four had haemangiosarcoma and two had lymphoma).²⁶ There was a single case with myelolipoma included; that cat was still alive at the time of publication, with a survival (to that time) of 339 days.²⁶

Whether or not the hyperthyroid status of the cat played a role in the development of the myelolipoma is unknown. This type of mass has been associated with several endocrine disorders in humans, but the pathogenesis remains undetermined. In the cheetah, their presence has been proposed to be a marker of chronic illness/stress, and hepatic myelolipoma has previously been reported in a cat with concurrent metastatic cholangiocarcinoma.^{12,24} Hyperthyroidism is known to alter fat metabolism and increase sympathetic drive.^{32,33} The endogenous ACTH levels in cats with hyperthyroidism have not been reported, but it has been demonstrated that in-hospital cortisol levels are higher than in non-hyperthyroid controls.³⁴ However, whether this is simply an in-hospital phenomenon due to heightened sympathetic sensitivity or a long-term complication is yet to

be determined.³⁴ The cat in this report was not treated for hyperthyroidism prior to surgical removal of the mass. Total thyroxine was mildly elevated, and the mass was considered to pose a greater risk to health than the mild hyperthyroidism.

Conclusions

Splenic diseases in the cat are not commonly reported. This report highlights the importance of considering potential benign lesions when a large abdominal mass is palpated. Splenectomy is well tolerated by cats, and in this case, where a giant splenic myelolipoma was identified, removal was curative, with the cat surviving 3 years postoperatively.

Conflict of interest The authors declared no potential conflicts of interest with respect to the research, authorship, and/or publication of this article.

Funding The authors received financial support for the publication of this article from Center for Integrative Mammalian Research, Ross University School of Veterinary Medicine.

Ethical approval The work described in this manuscript involved the use of non-experimental (owned or unowned) animals. Established internationally recognised high standards ('best practice') of veterinary clinical care for the individual patient were always followed and/or this work involved the use of cadavers. Ethical approval from a committee was therefore not specifically required for publication in *JFMS Open Reports*. Although not required, where ethical approval was still obtained, it is stated in the manuscript.

Informed consent Informed consent (verbal or written) was obtained from the owner or legal custodian of all animal(s) described in this work (experimental or non-experimental animals, including cadavers) for all procedure(s) undertaken (prospective or retrospective studies). For any animals or people individually identifiable within this publication, informed consent (verbal or written) for their use in the publication was obtained from the people involved.

ORCID iD Kerry E Rolph  <https://orcid.org/0000-0002-4660-5676>

References

- Calissendorff J, Juhlin CC, Sundin A, et al. **Adrenal myelolipomas.** *Lancet Diabetes Endocrinol* 2021; 11: 767–775.
- Griffin S. **Feline abdominal ultrasonography: What's normal? What's abnormal? The spleen.** *J Feline Med Surg* 2021; 23: 241–255.
- Decmann Á, Perge P, Tóth M, et al. **Adrenal myelolipoma: a comprehensive review.** *Endocrine* 2018; 59: 7–15.
- Liu H-P, Chang W-Y, Chien S-T, et al. **Intra-abdominal bleeding with hemorrhagic shock: a case of adrenal myelolipoma and review of literature.** *BMC Surg* 2017; 17: 74. DOI: 10.1186/s12893-017-0270-6.
- Nitz JA, Huckleby J, Hwang EH, et al. **Symptomatic extra-adrenal myelolipoma in the spleen.** *Case Rep Surg* 2020; 2020: 8839178. DOI: 10.1155/2020/8839178.
- Thomas RM and Fishetti AJ. **What is your diagnosis?** *J Am Vet Med Assoc* 2012; 241: 881–883.
- Haak CE, Zumbo B, Allen J, et al. **Nontraumatic hemo-abdomen and pancytopenia secondary to myelolipoma in a cat.** *J Vet Emerg Crit Care* 2022; 32: 260–266.
- Tinozzi FP, Morone G, Cali B, et al. **Laparoscopic adrenalectomy for a giant adrenal myelolipoma: a case report.** *Int J Surg Case Rep* 2022; 90: 106678. DOI: 10.1016/j.ijscr.2021.106678.
- Wood WG, Restivo TE, Axelsson KL, et al. **Myelolipoma in the spleen: a rare discovery of extra-adrenal hematopoietic tissue.** *J Surg Case Rep* 2013; 2013: rjt007. DOI: 10.1093/jscr/rjt007.
- Cina SJ, Gordon BM and Curry NS. **Ectopic adrenal myelolipoma presenting as a splenic mass.** *Arch Pathol Lab Med* 1995; 119: 561–563.
- Zeng Y, Ma Q, Lin L, et al. **Giant myelolipoma in the spleen: a rare case report and literature review.** *Int J Surg Pathol* 2016; 24: 177–180.
- Barge P, Sebastián-Marcos P, Martínez M, et al. **Cholangiocarcinoma and hepatic myelolipoma incarcerated in a peritoneopericardial diaphragmatic hernia with pulmonary metastasis and carcinomatosis in a cat.** *J Feline Med Surg Open Rep* 2019; 5. DOI: 10.1177/2055116919835081.
- Gourley IM, Popp JA and Park RD. **Myelolipomas of the liver in a domestic cat.** *J Am Vet Med Assoc* 1971; 158: 2053–2057.
- Ikede BO and Downey RS. **Multiple hepatic myelolipomas in a cat.** *Can Vet J* 1972; 13: 160–163.
- Lee N, Choi J and Yoon J. **Diagnostic imaging features of hepatic myelolipoma incarcerated in a peritoneopericardial diaphragmatic hernia in a cat.** *J Vet Sci* 2022; 23: e42. DOI: 10.4142/jvs.21289.
- McCaw DL, da Silva Curiel JM and Shaw DP. **Hepatic myelolipomas in a cat.** *J Am Vet Med Assoc* 1990; 197: 243–244.
- Schuh JC. **Hepatic nodular myelolipomatosis (myelolipomas) associated with a peritoneo-pericardial diaphragmatic hernia in a cat.** *J Comp Pathol* 1987; 97: 231–235.
- Wouda RM, Chalkley MD, Fraser AR, et al. **Hepatic myelolipoma incarcerated in a peritoneopericardial diaphragmatic hernia in a cat.** *Aust Vet J* 2010; 88: 231–235.
- Carrillo JD, Boza S, Soler M, et al. **What is your diagnosis? Splenic myelolipoma.** *J Am Vet Med Assoc* 2012; 240: 375–376.
- Schwarz LA, Penninck DG and Gliatto J. **Canine splenic myelolipomas.** *J Vet Radiol Ultrasound* 2001; 42: 347–348.
- Zimmer MA and Stair EL. **Splenic myelolipomas in two dogs.** *Vet Pathol* 1983; 20: 637–638.
- Hughes JR, Johnson VS and Genain MA. **CT characteristics of primary splenic torsion in eight dogs.** *Vet Radiol Ultrasound* 2020; 61: 161–168.
- Cardy RH and Bostrom RE. **Multiple splenic myelolipomas in a cheetah (*Acinonyx jubatus*).** *Vet Pathol* 1978; 15: 556–558.
- Munson L, Nesbit JW, Meltzer DG, et al. **Diseases of captive cheetahs (*Acinonyx jubatus jubatus*) in South Africa:**

- a 20-year retrospective survey. *J Zoo Wildl Med* 1999; 30: 342–347.
- 25 Sander CH and Langham RF. **Myelolipoma of the spleen in a cat.** *J Am Vet Med Assoc* 1972; 160: 1101–1103.
- 26 Gordon SSN, McClaran JK, Bergman PJ, et al. **Outcome following splenectomy in cats.** *J Feline Med Surg* 2010; 12: 256–261.
- 27 Reese SL, Zekas LJ, Iazbik C, et al. **Effect of sevoflurane anesthesia and blood donation on the sonographic appearance of the spleen in 60 healthy cats.** *Vet Radiol Ultrasound* 2013; 54: 168–175.
- 28 Spangler WL and Culbertson MR. **Prevalence and type of splenic disease in cats: 455 cases (1985–1991).** *J Am Vet Med Assoc* 1992; 201: 773–776.
- 29 Kleinschmidt LM, Langan JN, Warneke MR, et al. **Retrospective review of the prevalence of myelolipoma in Goeldi's monkeys (*Callimico goeldii*).** *J Zool Wildl Med* 2015; 46: 273–278.
- 30 Valli VE, Bienzle D and Meuten DJ. **Tumors of the hemolymphatic systems.** In: Meuten DJ (ed). *Tumors in domestic animals*. 5th ed. Ames, IA: Wiley-Blackwell, 2017, pp 317–318.
- 31 Cullen JM and Stalker MJ. **Liver and biliary system.** In: Maxie MG (ed). *Jubb, Kennedy, and Palmer's pathology of domestic animals*. 6th ed. St Louis, MO: Elsevier, 2016, pp 350–351.
- 32 Peterson ME, Kintzer PP, Cavanagh PG, et al. **Feline hyperthyroidism: pretreatment clinical and laboratory evaluation of 131 cases.** *J Am Vet Med Assoc* 1983; 183: 103–110.
- 33 Teixeira PFDS, Dos Santos PB and Pazos-Moura CC. **The role of thyroid hormone in metabolism and metabolic syndrome.** *Ther Adv Endocrinol Metab* 2020; 13. DOI: 10.1177/2042018820917869.
- 34 Ramspott S, Hartmann K, Sauter-Louis C, et al. **Adrenal function in cats with hyperthyroidism.** *J Feline Med Surg* 2012; 14: 262–266.