



---

## **New findings associated with presumptive systemic lupus erythematosus in a kitten**

Authors: Huvé, Romain, Fontaine, Pascal, Blais, Marie-Claude, and Conversy, Bérénice

Source: Journal of Feline Medicine and Surgery Open Reports, 6(2)

Published By: SAGE Publishing

URL: <https://doi.org/10.1177/2055116920979271>



# New findings associated with presumptive systemic lupus erythematosus in a kitten

Romain Huvé<sup>ID</sup>, Pascal Fontaine, Marie-Claude Blais and Bérénice Conversy

*Journal of Feline Medicine and Surgery Open Reports*  
1–9

© The Author(s) 2020

Article reuse guidelines:

sagepub.com/journals-permissions

DOI: 10.1177/2055116920979271

journals.sagepub.com/home/jfmsopenreports

This paper was handled and processed by the American Editorial Office (AAFP) for publication in *JFMS Open Reports*



## Abstract

**Case summary** An 8-month-old neutered male domestic shorthair kitten was examined for anorexia, lethargy and palatine ulcers. Systemic lupus erythematosus (SLE) was suspected based on a positive antinuclear antibody (ANA) titer and six manifestations of autoimmunity: fever, paronychia, oral ulcers, proteinuria, thrombocytopenia and leukopenia. Mastocytosis was observed on the blood smear. Although the clinical presentation of this case meets the classification criteria for SLE in humans, tick-borne disease and histopathology evaluation of the oral and cutaneous lesions would have been necessary to support a definite diagnosis of SLE. Baseline ANA titration was performed in two laboratories with conflicting results, which may reflect substrate differences used for the titration, but a false-positive result cannot be excluded. The cat received prednisolone and all clinical and laboratory abnormalities resolved after two months of treatment. Subsequent ANA titers remained positive and were not correlated to the patient's clinical progression.

**Relevance and novel information** This report describes new findings associated with a presumptive diagnosis of SLE in a kitten, highlighting that SLE may not be ruled out even in young cats and may be associated with mastocytosis. ANA titration is part of the initial diagnostic work-up of SLE but is a non-specific test and discrepancies can be observed between laboratories. The titration of more specific antibodies such as those used in humans would be helpful to diagnose SLE. ANA titration may not correlate with clinical activity of SLE; hence, the interest of an ANA titer follow-up to establish disease control warrants further investigation.

**Keywords:** Systemic lupus erythematosus; mast cells; antinuclear antibodies; vasculitis

**Accepted:** 12 November 2020

## Introduction

Pathogenic autoantibodies are the primary cause of tissue damage in patients with systemic lupus erythematosus (SLE). The production of these antibodies arises by means of complex mechanisms involving every key facet of the immune system.<sup>1</sup> Immune complexes, autoantibodies, autoreactive lymphocytes, dendritic cells and local factors are all involved in clinical manifestations of SLE.<sup>2</sup> In veterinary medicine, the diagnosis is still based on the 1982 revised American College of Rheumatology criteria,<sup>3,4</sup> adapted for dogs and cats.<sup>5</sup> To be diagnosed with SLE, dogs or cats need to have any combination of four or more of 10 criteria, which are: arthritis, renal disorder, cutaneous lesions, oral ulcers, hematologic disorder, serositis, neurologic disorders, polymyositis or myocarditis, abnormal antinuclear

antibodies (ANA) titer and immunologic disorder.<sup>5</sup> However, the classification criteria for SLE has recently been updated in human medicine. Henceforth, classification criteria for SLE include positive ANA at least once as an obligatory entry criterion followed by additive weighted criteria (from 2 to 10) grouped in seven clinical (constitutional, hematologic, neuropsychiatric, mucocutaneous, serosal, musculoskeletal, renal) and

Department of Clinical Sciences, Faculty of Veterinary Medicine, University of Montréal, Saint-Hyacinthe, QC, Canada

### Corresponding author:

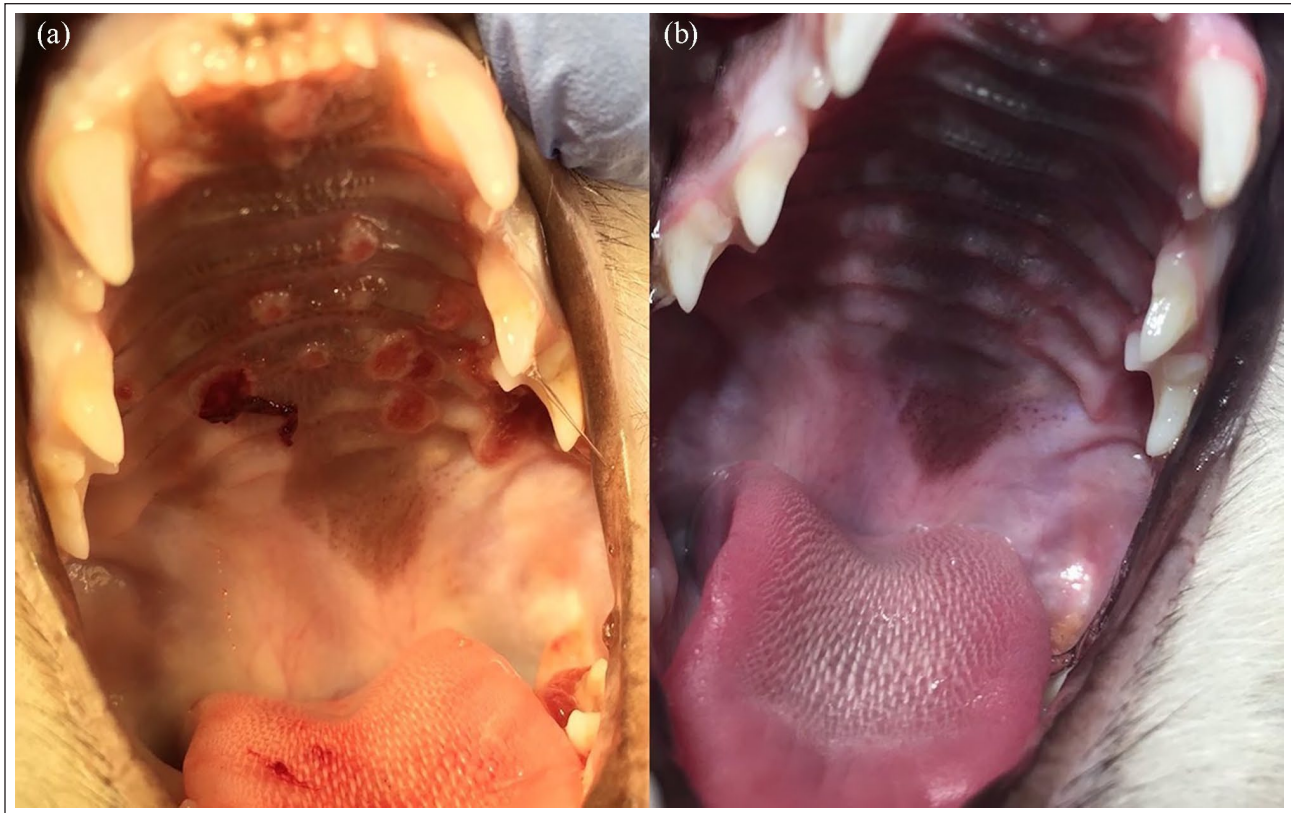
Romain Huvé DVM, DES, MSc, ACVIM (SAIM), Centre Vétérinaire DMV-Sud, 1655 Boulevard des Promenades, Saint-Hubert, QC J3Y 5K2, Canada

Email: rhuve@centredmv.com



Creative Commons Non Commercial CC BY-NC: This article is distributed under the terms of the Creative Commons

Attribution-NonCommercial 4.0 License (<https://creativecommons.org/licenses/by-nc/4.0/>) which permits non-commercial use, reproduction and distribution of the work without further permission provided the original work is attributed as specified on the SAGE and Open Access pages (<https://us.sagepub.com/en-us/nam/open-access-at-sage>).



**Figure 1** Oral ulcers at (a) admission and (b) 1 week after discharge

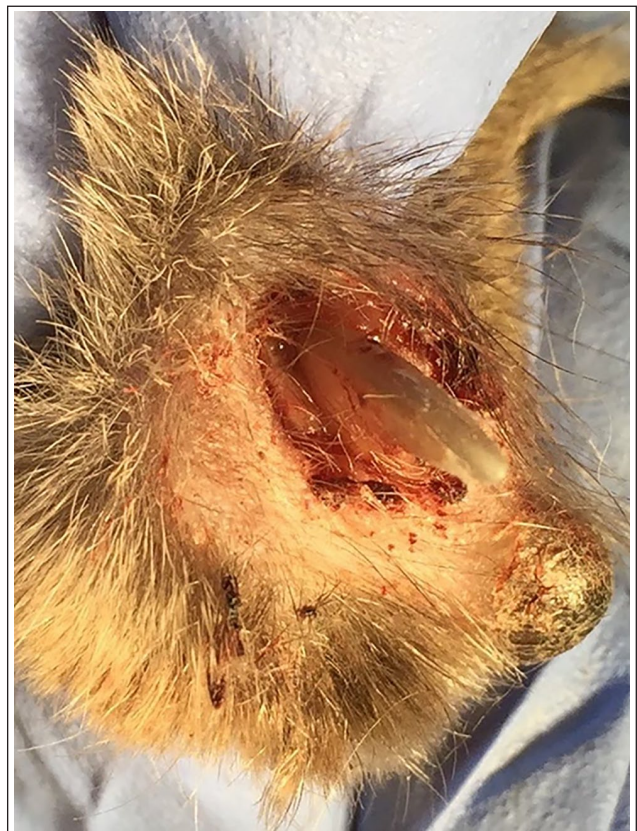three immunologic (antiphospholipid antibodies, complement proteins, SLE-specific antibodies) domains. Patients accumulating  $\geq 10$  points are classified as having SLE.<sup>6</sup> To our knowledge, this classification has yet to be adapted for dogs and cats.

We report a presumptive case of SLE in a kitten with abnormalities not previously described.

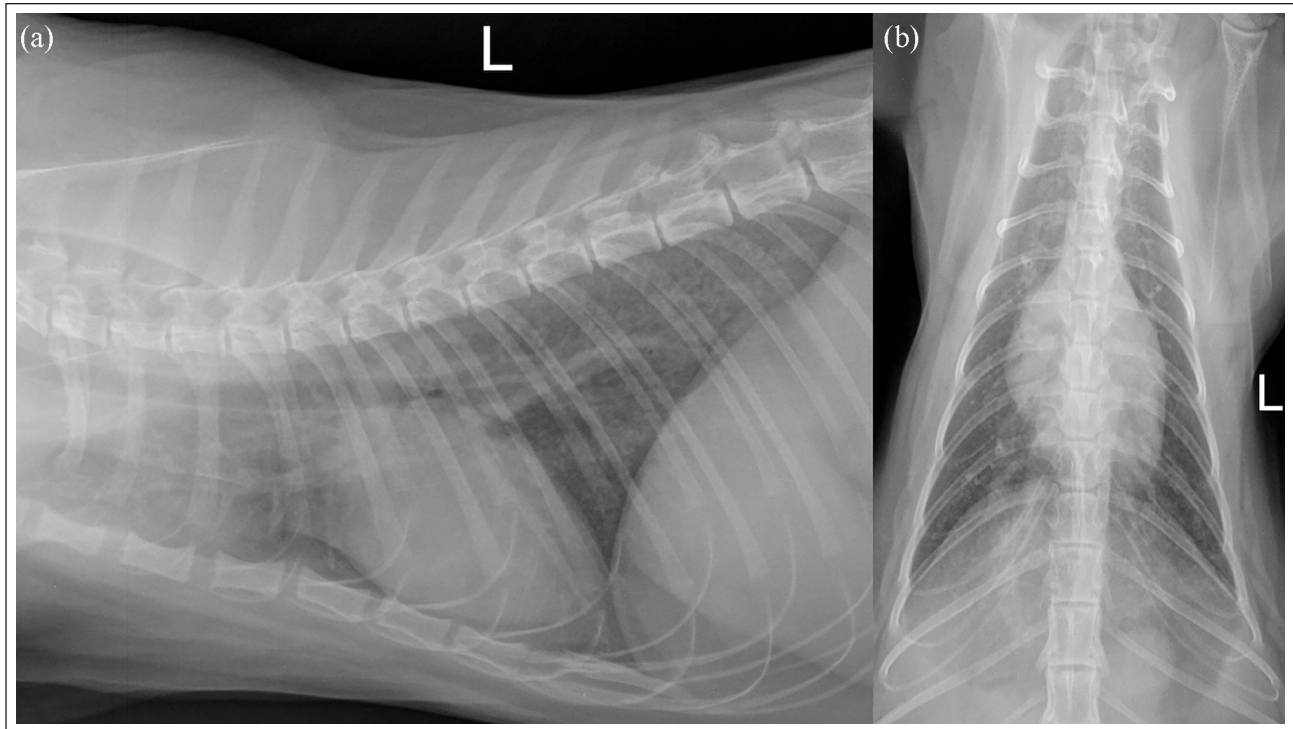
### Case description

An 8-month-old neutered male domestic shorthair kitten was referred with a 5-day history of progressive anorexia, lethargy and palatine ulcers. The cat was vaccinated 2 and 3 months before the onset of clinical signs but had not been dewormed and was currently receiving no medication. No fleas or ticks were observed by the owners or during the physical examination. The cat lived strictly indoors and no possible trauma was reported.

Physical examination revealed fever (39.7°C), pale mucous membranes, peripheral lymphadenomegaly (notably both submandibular lymph nodes [3 × 5 cm] and both prescapular lymph nodes [5 × 8 cm]), multiple palatine ulcers (Figure 1) and paronychia of the third digit of the left hindlimb, which was associated with a brownish exudate (Figure 2). A board-certified dermatologist examined the animal and either a fungal infection or SLE were highly suspected as a cause for the mucosal and cutaneous lesions. Skin biopsies and cultures were recommended but declined by owner.



**Figure 2** Paronychia at admission



**Figure 3** Thoracic radiographs of the kitten showing a moderate diffuse interstitial pattern worse in the caudodorsal region with a slight reticulated texture. Left (a) lateral and (b) dorsoventral views

Hematologic abnormalities included a mild non-regenerative normocytic normochromic anemia (hematocrit 0.25 l/l; reference interval [RI] 0.28–0.471/l with no aggregate reticulocytes), mild thrombocytopenia confirmed on blood smear evaluation ( $100 \times 10^9/l$ ; RI 156–626  $\times 10^9/l$ ), leukopenia ( $5.74 \times 10^9/l$ ; RI 6.30–19.60  $\times 10^9/l$  [ADVIA 120]), a toxogram (Döhle bodies in more than half the neutrophils), rare reactive lymphocytes and mastocytosis (one mastocyte on the blood smear). No morulae were visualized. A saline agglutination test was negative. Biochemical abnormalities included hypoalbuminemia (17.7 g/dl; RI 26–39 g/l) and hyperglobulinemia (51.1 g/dL; RI 29–47 g/l [Beckman DxC 600]). Urinalysis revealed a normal urine specific gravity (>1.060) with an inactive urinary sediment. The urine protein:creatinine ratio (UP:CR) was significantly increased (6.6; RI 0–0.4).

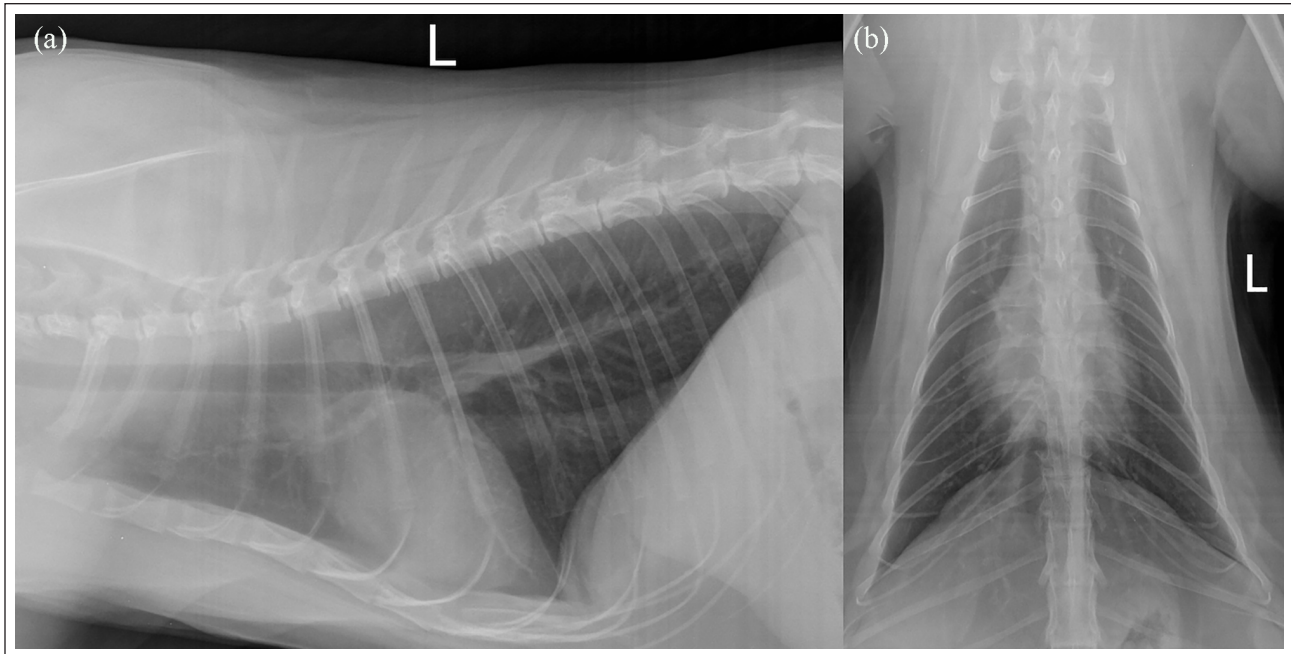
PCR testing for *Chlamydia* species, feline herpesvirus-1, *Mycoplasma* species and feline calicivirus on an oropharyngeal swab were negative. Brush cytology of palatine ulcers revealed septic suppurative inflammation without evidence of atypical cells. Cytologic examination of submandibular and prescapular lymph nodes was consistent with reactive lymphoid hyperplasia. In-house feline leukemia virus (FeLV) antigen and feline immunodeficiency virus (FIV) antibody test (Combo Plus FeLV/FIV; IDEXX Laboratories), as well as FeLV PCR assay on whole blood were negative. Considering the owner's financial constraints, the indoor-style living

of the cat and the low prevalence of tick-borne diseases in North America, the latter and bartonellosis were not prioritized and not explored.

Thoracic radiographs revealed a mildly reticulated, moderate diffuse interstitial pulmonary pattern worse in the caudodorsal lung fields; a preferential peribronchial distribution suggested peri-bronchial interstitial lesions, bronchial wall thickening or combination thereof (Figure 3).

On abdominal ultrasound, the liver appeared normal both in size and echogenicity. The spleen was diffusely enlarged but homogeneous. The renal cortices were mildly heterogeneous and hyperechoic with poorly defined hyperechoic streaks perpendicular to the cortex and capsule, representing non-specific changes suggestive of nephritis or glomerulonephritis. The pancreatic parenchyma was diffusely mildly hypoechoic and slightly thickened with irregular margins, supporting a diagnosis of pancreatitis. The hepatic and medial iliac lymph nodes were moderately thickened. These changes were deemed reactive to some systemic inflammatory process. A non-effusive form of feline infectious peritonitis was not excluded but was considered less likely given the absence of detectable nodules on thoracic radiographs and abdominal ultrasound, as well as the absence of neurologic clinical signs.

Coagulation times evaluated prior to fine-needle aspiration were within normal limits (prothrombin time 16s [RI 15–23s]; partial thromboplastin time 97s [RI



**Figure 4** Normal thoracic radiographs of the cat 7 months after discharge. Left (a) lateral and (b) dorsoventral views

70–120s]). Owing to mastocytemia, hepatic, splenic and hepatic and medial iliac lymph nodes cytologic evaluation was conducted. The samples had adequate cellularity and a mast cell tumor was not revealed. Hepatic and medial iliac lymph nodes were reactive.

ANA were titrated and considered negative at a titer of 1:80 in a first laboratory (lab 1), with no available RIs. The same serum was sent to another laboratory (lab 2) as the clinical picture was suggestive of SLE, and considering the variable sensitivity of ANA titration between laboratories. The titer was positive in lab 2 at 1:160 (positive when  $\geq 1:40$ ).

The cat received 8.6 mg/kg doxycycline (Summit Veterinary Pharmacy) q24h for 1 month, 1.2 mg/kg prednisolone (Rafter 8 Products) q24h and 0.6 mg/kg benazepril (Fortekor; Elanco) PO q24h. The prescription for doxycycline was issued for 1 month based on the recommended treatment duration for ehrlichiosis.<sup>7</sup> The owners were also instructed to feed the cat with either wet kibbles or canned food, and given a renewable prescription of buprenorphine (Summit Veterinary Pharmacy), 0.014 mg/kg q8h for 5 days. However, buprenorphine was discontinued thereafter as the cat did not exhibit any discomfort, which was supported by the fact that the cat regained a full appetite and that the oral ulcers had almost healed within a week post-discharge (Figure 1). The peripheral lymphadenomegaly had significantly improved and the paronychia started to heal. Mastocytemia was no longer detected and all hematologic abnormalities were resolved. No changes were made in treatments.

Three weeks after discharge, the oral ulcers were completely healed and there was only mild crusting

of the affected nail bed. UP:CR was normal (0.19; RI 0–1.00) so benazepril was decreased to 0.3 mg/kg PO q24h.

Two months after discharge, the cat was clinically healthy and had an unremarkable physical examination. The paronychia was healed, and no buccal ulcers were noted. Complete blood count and urinalysis revealed no abnormalities. An in-house FeLV/FIV test was repeated and remained negative. Prednisolone (1.2 mg/kg PO q24h) was maintained, but benazepril administration was discontinued.

Three months after discharge and thereafter the cat had no clinical signs and a normal UP:CR (0.07; RI 0–1.00). ANA titer was repeated at lab 2 and remained positive (1:640).

Seven months after discharge, while the cat remained in clinical remission, ANA titer at lab 2 was positive at 1:160. Thoracic radiographs were performed and were within normal limits (Figure 4). Prednisolone was decreased to 0.8 mg/kg PO q24h.

Ten months after discharge, ANA titer remained positive at 1:40. Prednisolone was decreased to 0.5 mg/kg q24h. Thirteen months after discharge, leukopenia recurred ( $1.77 \times 10^9/l$ ; RI  $6.30\text{--}19.60 \times 10^9/l$ ) and ANA titer was positive 1:160. Prednisolone was increased to 0.8 mg/kg q24h until now. At the time of writing, 19 months after the diagnosis, the cat is clinically well, but a slight leukopenia persists ( $2.74 \times 10^9/l$ ; RI  $6.30\text{--}19.60 \times 10^9/l$ ).

## Discussion

To our knowledge, this is the first report to describe a kitten with a presumptive SLE associated with mastocytemia

and radiographic changes compatible with vasculitis, which includes follow-up of ANA titer.

In the present case, the diagnosis of SLE was based on a positive ANA titer as well as six manifestations of autoimmunity: fever, paronychia, oral ulcers, proteinuria, thrombocytopenia and leukopenia. Of these clinical signs, proteinuria, cutaneous lesions and anemia were the most frequent in previously reported cats with SLE (Table 1).<sup>8–20</sup> Anemia was not included in criteria for this cat as an immune-mediated destruction was uncertain. Although not all infectious or corticosteroid-responsive diseases have been investigated in this case, few infectious diseases could result in all the abnormalities observed in this cat. Virulent systemic disease associated with calicivirus could have mimicked some abnormalities observed in this case<sup>21</sup> but is deemed unlikely considering the negative PCR on oropharyngeal swab. Unfortunately, a vasculitis associated with a tick-borne disease was not ruled out, and it is not excluded that the month of doxycycline may have cured this cat. However, this hypothesis is less likely as this cat was a strictly indoor-only cat and lives in North America where the tick-borne disease prevalence is low (*Ehrlichia* species, *Anaplasma phagocytophilum*, *Neorickettsia* species and *Bartonella henselae* species: 0% for indoor cats).<sup>22</sup> In addition, no fleas or ticks were observed on this cat. Finally, a vasculitis associated with *Bartonella* or a tick-borne disease has never been reported in cats, to the best of our knowledge.<sup>23–25</sup> It should also be noted that the doxycycline may have helped to control an immune-mediated disease as this molecule is known to have immunomodulatory effects.<sup>26</sup> Feline infectious peritonitis is very unlikely considering that this cat is still alive, but a screening test such as feline coronavirus antibody titer on blood may have been desirable at the onset of clinical signs. Biopsies from oral ulcers or the nail bed could have helped strengthen our diagnosis of SLE by demonstration of IgG and C3 deposition along the basement membrane using direct immunofluorescence (positive lupus band test), as well as by excluding other autoimmune diseases; however, biopsies are not required for the diagnosis of SLE and observation of cutaneous lesions by a clinician is considered sufficient according to the diagnostic criteria for SLE in humans.<sup>6</sup> Despite this, the absence of the above-mentioned diagnostic procedures makes the diagnosis of SLE in our cat a presumptive one.

The cat presented in this case report is the youngest ever described among cases of SLE already reported, in which the age of diagnosis ranged from 1 to 11.5 years (median 7 years).<sup>8–19</sup> SLE may therefore not be ruled out in a very young cat. Similarly, in humans, approximately 25% of SLE cases appear in the first two decades of life.<sup>27</sup>

Conflicting results were observed with ANA titers measured from the same serum sample sent to two different laboratories. The positive ANA titer was considered reliable because the cat had several manifestations

of autoimmunity consistent with SLE and the screening for FeLV, a known cause of false-positive ANA titer, was negative twice.<sup>15,28</sup> Moreover, the present cat did not show any direct or indirect signs of cholangitis, and did not receive any drugs, also known to cause false-positive ANA titers.<sup>15,28</sup> It is, however, reported that healthy cats may have a positive ANA titer (20% with strong titers: 1:160–1:320);<sup>29</sup> therefore, a false-positive titer in our cat cannot be completely ruled out. With the new classification of lupus in humans,<sup>6</sup> a persistent negative assay of ANA precludes a diagnosis of SLE. Conversely, a persistent false-positive ANA titer with clinical signs consistent with SLE can lead to a false diagnosis of SLE. This scenario cannot be completely ruled out in the current case report, although the cat met the SLE criteria of 1982. Unfortunately, other specific tests available in humans have not been developed for use in feline patients.

The ANA titration at diagnosis was performed by indirect immunofluorescence in both laboratories but using two different substrates: Hep-2 cell lines (lab 1) or rat liver section (lab 2). One of the reasons for the discordant titers may be the nature of the substrate used. Some studies compared the Hep-2 cell line (human epithelial cell cultures) with rat liver section for ANA titration in dogs, with divergent results.<sup>30,31</sup> Other causes that may explain the conflicting ANA results could be microscope performance, evaluator subjectivity or lack of standardized positive control serum.<sup>32–34</sup> Inconsistent results for ANA test may occur between laboratories and further evaluation of these tests to determine their specificity is warranted.

ANA titer has been monitored in our cat at the same laboratory (lab 2). Despite a remission of both clinical and biochemical parameters, the ANA titer increased three months after diagnosis and remained positive after 7, 10 and 13 months. This could be explained by a lack of correlation between clinical signs and ANA titer. Pedersen and Barlough<sup>15</sup> reported that ANA titer appeared useful to monitor SLE activity, but this was not observed in our cat nor in two cats with SLE reported by Scott et al<sup>10</sup> and Vitale et al<sup>17</sup> (Table 2). This is in agreement with what is observed in human medicine where little, if any, data suggest a correlation between ANA titer and the activity of SLE.<sup>35</sup> Therefore, ANA titration may not be an appropriate test to detect relapse when weaning treatments.

The prevalence of mastocytosis in cats varies from 0.05% to 0.33%, and has never been described in healthy cats.<sup>36,37</sup> In a study involving 33 cats with mastocytosis, the associated diagnoses were mast cell tumors (MCTs; confirmed  $n = 22/33$ ; suspected  $n = 3/33$ ), other tumors ( $n = 5/33$ ) and chronic kidney disease ( $n = 3/33$ ).<sup>37</sup> Furthermore, in another study, 14/30 cats (47%) with mastocytosis were found to have a MCT, but 16 (53%) had no definitive diagnosis.<sup>36</sup> For our cat, an MCT was deemed unlikely based on cytologic evaluation of palatine ulcers, lymph nodes, liver and spleen, and because

**Table 1** Prevalence of clinical signs of previously reported cats with systemic lupus erythematosus in decreasing order of frequency

Studies	n	Renal disorders	Cutaneous lesions	Anemia	Polyarthritis	Fever	Lymphadenopathy/ splenomegaly	Oral ulcers	Neurologic disorders	Thrombocytopenia	Leukopenia	Myositis/ myocarditis	APA
Slauson et al. <sup>8</sup>	1	1											
Heise et al. <sup>9</sup>	1	1		1		1	1						
Scott et al. <sup>10</sup>	2	2	2	2	1	2							
Faircloth and Montgomery <sup>11</sup>	1			1	1	1		1					
Scott <sup>12</sup>	5		4			4		1					
Gabbert <sup>13</sup>	1			1		1			1				
Bennett and Nash <sup>14</sup>	2	2		2	2			1	1				
Pedersen and Barlough <sup>15</sup>	11	8	2	3	7	2	3	2	5			1	
Day <sup>16</sup>	1												
Vitale et al. <sup>17</sup>	1		1	1					1				
Lusson et al. <sup>18</sup>	1			1					1				1
Hanna <sup>19</sup>	3	3	3	3	3	3		3				1	
Total (%)	30	17 (57)	12 (40)	12 (40)	12 (40)	12 (40)	8 (27)	7 (23)	6 (20)	4 (13)	3 (10)	2 (7)	1 (3)

APA = antiphospholipid antibodies

**Table 2** Antinuclear antibody (ANA) monitoring of previously reported cats with systemic lupus erythematosus (SLE) and our cat

ANA titration with:	Unknown substrate		Hep-2 cell lines or liver substrate										Liver substrate			
	Case 1 <sup>10</sup>	Case 2 <sup>10</sup>	Case 3 <sup>15</sup>	Case 4 <sup>15</sup>	Case 5 <sup>15</sup>	Case 6 <sup>15</sup>	Case 7 <sup>17</sup>	Hep-2 cell lines substrate		Liver substrate						
Week post-diagnosis	CS	No CS	CS	No CS	CS	No CS	CS	No CS	CS	No CS	CS	No CS	CS	No CS	CS	No CS
0	Pos		Pos		Pos		Pos		Pos		Pos		Pos		Pos	
	1:10		1:40		1:100		1:40		1:40		1:1280		1:160		1:160	
2			Pos		Pos						Pos					
			1:40		1:80						1:320					
4		Pos											Neg*			
		1:10*														
6					Pos											
					1:80											
8		Neg			Pos											
					1:40											
12		Neg			Pos		Pos									Pos
					1:40		1:40									1:640*
16–22					Pos	Neg		Neg						Neg		
					1:10											
24–32				Neg				Neg						Neg*		Pos
																1:160*
40–50						Neg			Neg							Pos
										Neg						1:40*
52																Pos
																1:160
240						Neg										

\*Discrepancy between ANA titer and SLE clinical activity  
CS = clinical signs; Pos = positive; Neg = negative

the cat is still doing well more than a year after the diagnosis. Hence, SLE could reasonably be considered as a part of the shortlist of non-tumoral disease that may be associated with mastocytemia in feline patients but would merit further investigations.

While non-specific, the combination of reticulated texture and diffuse interstitial pulmonary pattern on thoracic radiographs raised suspicion for pneumonitis, microhemorrhages and/or vasculitis. This finding is consistent with SLE, as described in two dogs, but it has never been described in cats. One dog had a multifocal structured interstitial to miliary pattern affecting all lung fields on chest radiographs, and a cytology of bronchoalveolar lavage revealed the presence of a lupus erythematosus cell.<sup>38</sup> On the second dog, a moderate generalized pulmonary interstitial pattern on thoracic radiographs was observed. Lung necropsy revealed general inflammatory infiltration with an interstitial, diffuse, subacute-to-chronic pneumonitis, a chronic peri-bronchiolitis and a chronic peribronchitis.<sup>39</sup> In humans suffering from SLE, diffuse alveolar hemorrhage (DAH) can be observed and is frequently associated with pulmonary capillaritis. Pulmonary

infection remains a differential diagnosis.<sup>40,41</sup> For our cat, thoracic radiographic abnormalities and anemia make DAH associated with capillaritis a possible differential. A bronchoalveolar lavage was not performed and would have been useful to rule out infection. Considering the proteinuria, our cat was put on doxycycline to treat an underlying tick-borne disease, despite a low level of suspicion as previously mentioned. At the same time, the doxycycline may have helped to treat a pulmonary infection; in humans, the risk of pulmonary infection is three times greater in patients with SLE than in the general population.<sup>42</sup> Pancreatitis was also suspected according to abdominal ultrasound and may have resulted from vasculitis as described in humans with SLE.<sup>42</sup>

### Conclusions

This report describes new findings in a presumptive case of SLE, highlighting that the diagnosis may not be ruled out even in young cats and may be associated with mastocytemia. Vasculitis with lung involvement may occur in cats with SLE. ANA titration is part of the initial diagnostic work-up of SLE but is a non-specific



test and discrepancies can be observed between laboratories. A false-positive ANA titer with clinical signs consistent with SLE can lead to a false diagnosis of SLE. The titration of more specific antibodies such as those used in humans (anti-double-stranded DNA and anti-Smith antibody) would therefore be desirable. ANA titration may not be always correlated with clinical activity of SLE; hence, the interest of an ANA titer follow-up to establish disease control warrants further investigation.

**Conflict of interest** The authors declared no potential conflicts of interest with respect to the research, authorship, and/or publication of this article.

**Funding** The authors received no financial support for the research, authorship, and/or publication of this article.

**Ethical approval** This work involved the use of non-experimental animals only (including owned or unowned animals and data from prospective or retrospective studies). Established internationally recognized high standards ('best practice') of individual veterinary clinical patient care were followed. Ethical approval from a committee was therefore not specifically required for publication in *JFMS Open Reports*.

**Informed consent** Informed consent (either verbal or written) was obtained from the owner or legal custodian of all animal(s) described in this work (either experimental or non-experimental animals) for the procedure(s) undertaken (either prospective or retrospective studies). No animals or humans are identifiable within this publication, and therefore additional informed consent for publication was not required.

**ORCID iD** Romain Huvé  <https://orcid.org/0000-0001-7366-0964>

## References

- Rahman A and Isenberg DA. **Systemic lupus erythematosus**. *N Engl J Med* 2008; 358: 929–939.
- Tsokos GC. **Systemic lupus erythematosus**. *N Engl J Med* 2011; 365: 2110–2121.
- Tan EM, Cohen AS, Fries JF, et al. **The 1982 revised criteria for the classification of systemic lupus erythematosus**. *Arthritis Rheum* 1982; 25: 1271–1277.
- Hochberg MC. **Updating the American College of Rheumatology revised criteria for the classification of systemic lupus erythematosus**. *Arthritis Rheum* 1997; 40: 1725.
- Chabanne JL, Fournel C, Rigal D, et al. **Canine systemic lupus erythematosus. II. Diagnosis and treatment**. *Comp Cont Educ Pract Vet* 1999; 21: 402–421.
- Aringer M, Costenbader K, Daikh D, et al. **2019 European League Against Rheumatism/American College of Rheumatology classification criteria for systemic lupus erythematosus**. *Arthritis Rheumatol* 2019; 71: 1400–1412.
- Neer TM, Breitschwerdt EB, Greene RT, et al. **Consensus statement on ehrlichial disease of small animals from the infectious disease study group of the ACVIM**. *American College of Veterinary Internal Medicine*. *J Vet Intern Med* 2002; 16: 309–315.
- Slauson DO, Russell SW and Schechter RD. **Naturally occurring immune-complex glomerulonephritis in the cat**. *J Pathol* 1971; 103: 131–133.
- Heise S, Smith R and Schalm O. **Lupus erythematosus with hemolytic anemia in a cat**. *Feline Practice* 1973; 3: 14–19.
- Scott DW, Haupt KH, Knowlton BF, et al. **A glucocorticoid-responsive dermatitis in cats, resembling systemic lupus erythematosus in man**. *J Am Anim Hosp Assoc* 1979; 15: 157–171.
- Faircloth JC and Montgomery JK. **Systemic lupus erythematosus in a cat presenting with autoimmune hemolytic anemia**. *Feline Practice* 1981; 11: 22–26.
- Scott DW. **Feline dermatology 1979–1982: introspective retrospections**. *J Am Anim Hosp Assoc* 1984; 20: 537–564.
- Gabbert N. **Systemic lupus erythematosus in a cat with thrombocytopenia**. *Vet Med* 1983; 78: 77–79.
- Bennett D and Nash AS. **Feline immune-based polyarthritides: a study of thirty-one cases**. *J Small Anim Pract* 1988; 29: 501–523.
- Pedersen NC and Barlough JE. **Systemic lupus erythematosus in the cat**. *Feline Pract* 1991; 19: 5–13.
- Day MJ. **Diagnostic assessment of the feline immune system, Part 2**. *Feline Pract* 1996; 24: 14–25.
- Vitale CB, Ihrke PJ, Gross TL, et al. **Systemic lupus erythematosus in a cat: fulfillment of the American Rheumatism Association criteria with supportive skin histopathology**. *Vet Dermatol* 1997; 8: 133–138.
- Lusson D, Billiemaz B and Chabanne JL. **Circulating lupus anticoagulant and probable systemic lupus erythematosus in a cat**. *J Feline Med Surg* 1999; 1: 193–196.
- Hanna FY. **Case study: three cats with SLE and erosive polyarthritides**. *Comp Anim* 2013; 18: 256–263.
- Werner LL and Gorman NT. **Immune-mediated disorders of cats**. *Vet Clin North Am Small Anim Pract* 1984; 14: 1039–1064.
- Caringella F, Elia G, Decaro N, et al. **Feline calicivirus infection in cats with virulent systemic disease, Italy**. *Res Vet Sci* 2019; 124: 46–51.
- Hackett TB, Jensen WA, Lehman TL, et al. **Prevalence of DNA of *Mycoplasma haemofelis*, 'Candidatus Mycoplasma haemominutum', *Anaplasma phagocytophilum*, and species of *Bartonella*, *Neorickettsia*, and *Ehrlichia* in cats used as blood donors in the United States**. *J Am Vet Med Assoc* 2006; 229: 700–705.
- Alvarez-Fernandez A, Breitschwerdt EB and Solano-Gallego L. ***Bartonella* infections in cats and dogs including zoonotic aspects**. *Parasit Vectors* 2018; 11: 624. DOI: 10.1186/s13071-018-3152-6.
- Innera M. **Cutaneous vasculitis in small animals**. *Vet Clin North Am Small Anim Pract* 2013; 43: 113–134.
- Little SE. **Ehrlichiosis and anaplasmosis in dogs and cats**. *Vet Clin North Am Small Anim Pract* 2010; 40: 1121–1140.
- Bettenay SV, Mueller RS, Dow K, et al. **Prospective study of the treatment of feline plasmacytic pododermatitis with doxycycline**. *Vet Rec* 2003; 152: 564–566.
- Fish AJ, Blau EB, N Westberg NG, et al. **Systemic lupus erythematosus within the first two decades of life**. *Am J Med* 1977; 62: 99–117.

- 28 Aucoin DP, Peterson ME, Hurvitz AI, et al. **Propylthiouracil-induced immune-mediated disease in the cat.** *J Pharmacol Exp Ther* 1985; 234: 13–18.
- 29 Abrams-Ogg ACG, Lim S, Kocmarek H, et al. **Prevalence of antinuclear and anti-erythrocyte antibodies in healthy cats.** *Vet Clin Pathol* 2018; 47: 51–55.
- 30 Bell SC, Hughes DE, Bennett D, et al. **Analysis and significance of anti-nuclear antibodies in dogs.** *Res Vet Sci* 1997; 62: 83–84.
- 31 Hansson H, Trowald-Wigh G and Karlsson-Parra A. **Detection of antinuclear antibodies by indirect immunofluorescence in dog sera: comparison of rat liver tissue and human epithelial-2 cells as antigenic substrate.** *J Vet Intern Med* 1996; 10: 199–203.
- 32 Pham BN, Albarede S, Guyard A, et al. **Impact of external quality assessment on antinuclear antibody detection performance.** *Lupus* 2005; 14: 113–119.
- 33 Kern P, Kron M and Hiesche K. **Measurement of antinuclear antibodies: assessment of different test systems.** *Clin Diagn Lab Immunol* 2000; 7: 72–78.
- 34 Troy GC, Becker MJ and Greene RT. **Proficiency testing of selected antigen and antibody tests for use in dogs and cats.** *J Am Vet Med Assoc* 1996; 209: 914–917.
- 35 Solomon DH, Kavanaugh AJ, Schur PH, et al. **Evidence-based guidelines for the use of immunologic tests: anti-nuclear antibody testing.** *Arthritis Rheum* 2002; 47: 434–444.
- 36 Skeldon NC, Gerber KL, Wilson RJ, et al. **Mastocytæmia in cats: prevalence, detection and quantification methods, haematological associations and potential implications in 30 cats with mast cell tumours.** *J Feline Med Surg* 2010; 12: 960–966.
- 37 Piviani M, Walton RM and Patel RT. **Significance of mastocytæmia in cats.** *Vet Clin Pathol* 2013; 42: 4–10.
- 38 Black LJ, Hechler AC, Duffy ME, et al. **Presumed lupus erythematosus cells identified in bronchoalveolar lavage fluid from a Mexican Hairless dog.** *Vet Clin Pathol* 2017; 46: 354–359.
- 39 Clercx C, McEntee K, Gilbert S, et al. **Nonresponsive generalized bacterial infection associated with systemic lupus erythematosus in a Beauceron.** *J Am Anim Hosp Assoc* 1999; 35: 224–228.
- 40 Aguilera-Pickens G and Abud-Mendoza C. **Pulmonary manifestations in systemic lupus erythematosus: pleural involvement, acute pneumonitis, chronic interstitial lung disease and diffuse alveolar hemorrhage.** *Reumatol Clin* 2018; 14: 294–300.
- 41 Lopez Velazquez M and Highland KB. **Pulmonary manifestations of systemic lupus erythematosus and Sjogren's syndrome.** *Curr Opin Rheumatol* 2018; 30: 449–464.
- 42 Lalani TA, Kanne JP, Hatfield GA, et al. **Imaging findings in systemic lupus erythematosus.** *Radiographics* 2004; 24: 1069–1086.