



---

## **Multifocal cutaneous non-epitheliotropic B-cell lymphoma in a cat**

Authors: Quintavalla, Fausto, Di Lecce, Rosanna, Carlini, Daniele, Zanfabro, Matteo, and Cantoni, Anna M

Source: Journal of Feline Medicine and Surgery Open Reports, 6(2)

Published By: SAGE Publishing

URL: <https://doi.org/10.1177/2055116920972077>



# Multifocal cutaneous non-epitheliotropic B-cell lymphoma in a cat

Fausto Quintavalla<sup>1</sup>, Rosanna Di Lecce<sup>1</sup>,  
Daniele Carlini<sup>2</sup>, Matteo Zanfabro<sup>1</sup>   
and Anna M Cantoni<sup>1</sup>

*Journal of Feline Medicine and Surgery Open Reports*  
1–7

© The Author(s) 2020

Article reuse guidelines:

sagepub.com/journals-permissions

DOI: 10.1177/2055116920972077

journals.sagepub.com/home/jfmsopenreports

This paper was handled and processed  
by the European Editorial Office (ISFM)  
for publication in *JFMS Open Reports*



## Abstract

**Case summary** Skin tumours are the second-most common form of feline cancer after haematopoietic neoplasms and are often malignant. Cutaneous lymphoma is uncommon in cats and can be classified as epitheliotropic (typically of T-cell origin) or non-epitheliotropic (either of T-cell or B-cell origin). The present study describes a case of multifocal cutaneous non-epitheliotropic B-cell lymphoma. The skin nodules were multiple and variable in size; showed rapid progression; were alopecic and erythematous in appearance and pruritic and ulcerated; and were mostly located on the trunk. Nodule biopsies revealed the presence of uniform medium-to-large round neoplastic cells that infiltrated the dermis and subcutis. The neoplasias were consistent with a round cell cutaneous tumour and did not show evidence of epitheliotropism. Furthermore, immunohistochemical assessments indicated an immunophenotype characterised by round cells with a strong membrane and cytoplasmic positivity for the CD20 antigen, consistent with a lymphocyte of B-cell origin.

**Relevance and novel information** Cutaneous non-epitheliotropic B-cell lymphoma in cats is rare and was previously reported to appear as single dermal and subcutaneous masses that are variable in size and generally develop in the tarsal region. To our knowledge, this is the first report to describe multifocal cutaneous non-epitheliotropic B-cell lymphoma in a cat.

**Keywords:** Lymphoma; B cell; non-epitheliotropic lymphoma; skin tumours

**Accepted:** 14 October 2020

## Introduction

Cancer is a major cause of death in humans and companion animals, and is a frequent disease in domestic cats.<sup>1,2</sup> The skin and soft tissues of cats are the most affected anatomical sites for neoplasias, with a variable incidence of 27–55.7% of all tumour cases,<sup>2–5</sup> and a malignancy rate of over 65%.<sup>2,5</sup> Among malignant neoplasms, tumours of mesenchymal origin were the most common subtype, followed closely by those of epithelial origin.<sup>6</sup> The four most common types of skin tumours in cats are basal cell tumours, mast cell tumours, squamous cell carcinomas and fibrosarcomas.<sup>6–8</sup> Cutaneous/subcutaneous lymphoma is rarely reported (0.2–3% of the tumours in cats) and is generally diagnosed on the basis of cytological and/or histopathological findings.<sup>9,10</sup>

Histopathological assessments can categorise cutaneous lymphoma into two forms, which have been reported to show different biological behaviours:<sup>11</sup> epitheliotropic and non-epitheliotropic. In the epitheliotropic form, malignant lymphocytes may be found within the epidermis and within the follicular hair epithelium. Cats show a rare form of epitheliotropic lymphoma involving the

<sup>1</sup>Department of Veterinary Science, University of Parma, Parma, Italy

<sup>2</sup>'Villa Rosa' Veterinary Clinic, Mantova, Italy

### Corresponding author:

Matteo Zanfabro DVM, University of Parma, Strada del Taglio 10, Parma, PR 43126, Italy  
Email: contact@3dvet.eu



Creative Commons Non Commercial CC BY-NC: This article is distributed under the terms of the Creative Commons

Attribution-NonCommercial 4.0 License (<https://creativecommons.org/licenses/by-nc/4.0/>) which permits non-commercial use, reproduction and distribution of the work without further permission provided the original work is attributed as specified on the SAGE and Open Access pages (<https://us.sagepub.com/en-us/nam/open-access-at-sage>).

gastrointestinal tract (lymphosarcoma) with metastases to the lungs and skeletal muscles.<sup>12</sup> Non-epitheliotropic cutaneous lymphoma affects the dermis and subcutis without involvement of the epidermis.<sup>9,13</sup> Unlike cats, in dogs, primary non-epitheliotropic cutaneous lymphoma is less common than epitheliotropic lymphoma.

Literature on non-epitheliotropic cutaneous lymphoma in cats suggests a predominance of T-cell immunophenotypes.<sup>14</sup> In human B-cell lymphoma, studies have reported a clonally rearranged T-cell receptor, and similar findings were described in feline B-cell lymphoma but not in the canine counterpart.<sup>15,16</sup> The aetiology of non-epitheliotropic lymphoma is unknown, and different causes have been hypothesised, including chronic inflammation, surgery, trauma, metallic orthopaedic implants and viral infection. In humans, Epstein-Barr virus and human T-lymphotropic virus type 1 infection sites have been well documented as potential niduses for B-cell lymphomas.<sup>10,17-19</sup> In dogs with retroviral infection, environmental pollution via contamination with phenoxyacetic acid herbicides, magnetic field exposure, chromosomal abnormalities and immune dysfunction have been hypothesised as possible aetiologies.<sup>20</sup> However, literature reporting the aetiological factors in cats is still poor. Roccabianca et al<sup>10</sup> reported that the persistent inflammation at vaccine injection sites could be one potential cause of the disease. Jegatheeson et al<sup>21</sup> reported a cutaneous non-epitheliotropic T-cell lymphoma that developed at the site of a previous traumatic bone fracture and metal orthopaedic implant.

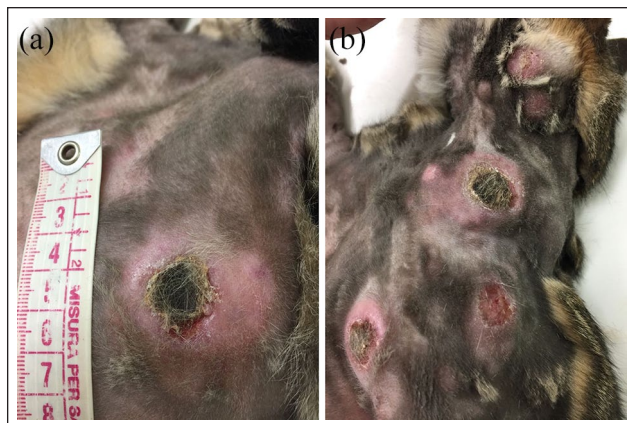Epitheliotropic and non-epitheliotropic forms can have a similar clinical appearance: both are often described as alopecic plaques with erythema, crust or papules, ulcers, usually itchy, warm and pain on palpation. Cutaneous lymphoma is often a fatal neoplastic condition.<sup>22</sup>

The aim of this report was to describe the clinical and pathological findings for a rare case of multifocal cutaneous non-epitheliotropic B-cell lymphoma in a cat.

## Case description

A 10-year-old spayed female domestic shorthair cat, with a body weight of 5.4 kg and receiving regular vaccine prophylaxis, presented with skin nodules that had started to appear 4 months previously. The owner initially noted one small skin nodule about the size of a millet seed behind the left auricle. Subsequently, another nodule appeared in the neck region. Moderate itching was recorded. The owner reported that, within a week, the nodules grew in dimension and number, involving the skin of the dorsal and ventral areas of the cat's abdomen and thorax. At the same time, the patient showed a tendency to isolate itself and dysorexia.

Nearly a month after the skin nodule eruption, the cat was presented for clinical evaluation and pharmacological treatment. Corticosteroids improved the patient's



**Figure 1** (a) A single nodular lesion, 3 cm in diameter, localised on the medial surface of the left thigh, presenting with a scab on the top. (b) Round, nodular lesions, localised in the region of the thorax and abdomen. The cat was first subjected to hair removal, which highlighted the hyperaemic aspect of skin

appetite, mood and behaviour but had no therapeutic effect on the skin lesions. After 10 days from the beginning of the treatment, as reported by the owner, the patient showed swelling of the head and limbs, with the nodules apparently increasing in size. The practitioner decided to obtain a second opinion at the Veterinary Teaching Hospital of the Department of Veterinary Science, University of Parma. The patient had suffered severe ocular infection by *Chlamydomphila felis* at a young age. It showed irreversible anatomical eye damage and vision dysfunction, because of which it preferred to remain indoors. After a house relocation, the cat presented behavioural problems (fear and excitement, associated with micturition disorders), which gradually disappeared.

Clinical examination showed the presence of numerous cutaneous nodules, with diameters ranging from 2 mm to >2 cm and erythematous features, scattered in different body regions (head, neck, thorax, abdomen and distal portion of the limbs). Some of the larger nodules showed ulceration, including a 2 cm scab on the top of a lesion that was very difficult to remove (Figure 1), and purulent material was suspected to be present underneath the surface. Mucocutaneous junction regions were not involved. The presence of pain on nodule palpation necessitated patient sedation to allow a complete and accurate clinical examination. The nodular masses were rounded, smooth, uniform, slightly alopecic and mobile under the skin. Lymph nodes were normal in size and shape, except for the right popliteal nodes, which were slightly increased in size, smooth to touch, not warm, indolent and mobile, compared with the left nodes. Core body temperature was 38.8°C. Blood sampling was performed to obtain the complete blood count and for biochemical assessments and serological ELISA feline leukaemia virus (FeLV) and feline immunodeficiency virus (FIV) tests. Clinical examination

**Table 1** Immunohistochemistry protocol

	Mouse monoclonal anti-CD3 (MOB-422; Diagnostic Biosystems)	Rabbit polyclonal anti-CD20 (PA5-16701; Thermo Fisher Scientific)
Antigen retrieval	Microwave for 15 mins at 400W in EDTA buffer pH 8	Microwave for 15 mins at 400W in 10mM sodium citrate buffer pH 6
Block endogenous peroxidase	3% hydrogen peroxidase for 15 mins	3% hydrogen peroxidase for 15 mins
Block to prevent non-specific antibody binding	BSA 1% antibody dilution buffer	Normal goat serum (SIGMA G-9023; Sigma-Aldrich) 5% for 20mins
Primary antibody	Overnight 4°C, 1:25	Overnight 4°C, 1:400
Detection	<ul style="list-style-type: none"> <li>– Biotinylated goat anti-mouse IgG (BA-9200; Vector Laboratories) 1:200 for 30 mins.</li> <li>– VECTASTAIN Elite ABC-Peroxidase Kit (PK-6100; Vector Laboratories) for 30 mins</li> <li>– DAB peroxidase substrate Kit (SK-4100; Vector Laboratories) for 5 mins</li> </ul>	<ul style="list-style-type: none"> <li>– Biotinylated goat anti-rabbit IgG (BA-1000; Vector Laboratories) 1:200 for 30 mins</li> <li>– VECTASTAIN Elite ABC-Peroxidase Kit (PK-6100; Vector Laboratories) for 30 mins</li> <li>– DAB peroxidase substrate Kit (SK-4100; Vector Laboratories) for 5 mins</li> </ul>
Counterstain	Mayer's haematoxylin solution	Mayer's haematoxylin solution

BSA = bovine serum albumin

was completed with total body radiographic examinations in dorsoventral and laterolateral projections and abdominal ultrasonography.

Fine-needle aspiration (FNA) and two skin nodule biopsies were performed after sedation (using the protocol recommended by Properzi et al).<sup>23</sup> After surgical removal of the scab on the top, a crater-like lesion was evident and no pus was recorded. A swab of the crater-like lesion was obtained in order to investigate the presence of bacteria and fungi. Cytological specimens were stained with May–Grünwald–Giemsa. The biopsy samples of the cutaneous nodules were formalin fixed in 10% neutral buffered formalin and embedded in paraffin. Formalin-fixed paraffin-embedded (FFPE) sections (5µm) were stained with haematoxylin and eosin. FFPE immunohistochemistry (IHC) was performed according to standard IHC methods and antibody producer data sheet information. The antibody panel was mouse monoclonal anti-CD3 (MOB-422; Diagnostic Biosystems) to identify T lymphocytes and rabbit polyclonal anti-CD20 (PA5-16701; Thermo Fisher Scientific) to identify B lymphocytes (Table 1).

Haematological abnormalities included a red blood cell (RBC) count of  $4.79 \times 10^6/\text{ml}$  (reference interval [RI]  $5.00\text{--}10.0 \times 10^6/\text{ml}$ ); a packed cell volume of 26.8% (RI 27.0–47%); a mean cell volume of  $56.00\text{mm}^3$  (RI 40.0–55.0mm<sup>3</sup>); a mean cell haemoglobin of 17.20pg (RI 13.0–17.0pg); a mean cell haemoglobin concentration of 30.71g/dl (RI 31.0–36.0g/dl); and a red cell distribution width of 15.7% (RI 17.0–22%). All other parameters were within the respective RIs. Serum biochemical abnormalities included a total protein content of 4.70g/dl (RI 5.40–8.20g/dl) and total calcium level of 12.00mg/dl (RI 8.0–11.8mg/dl).

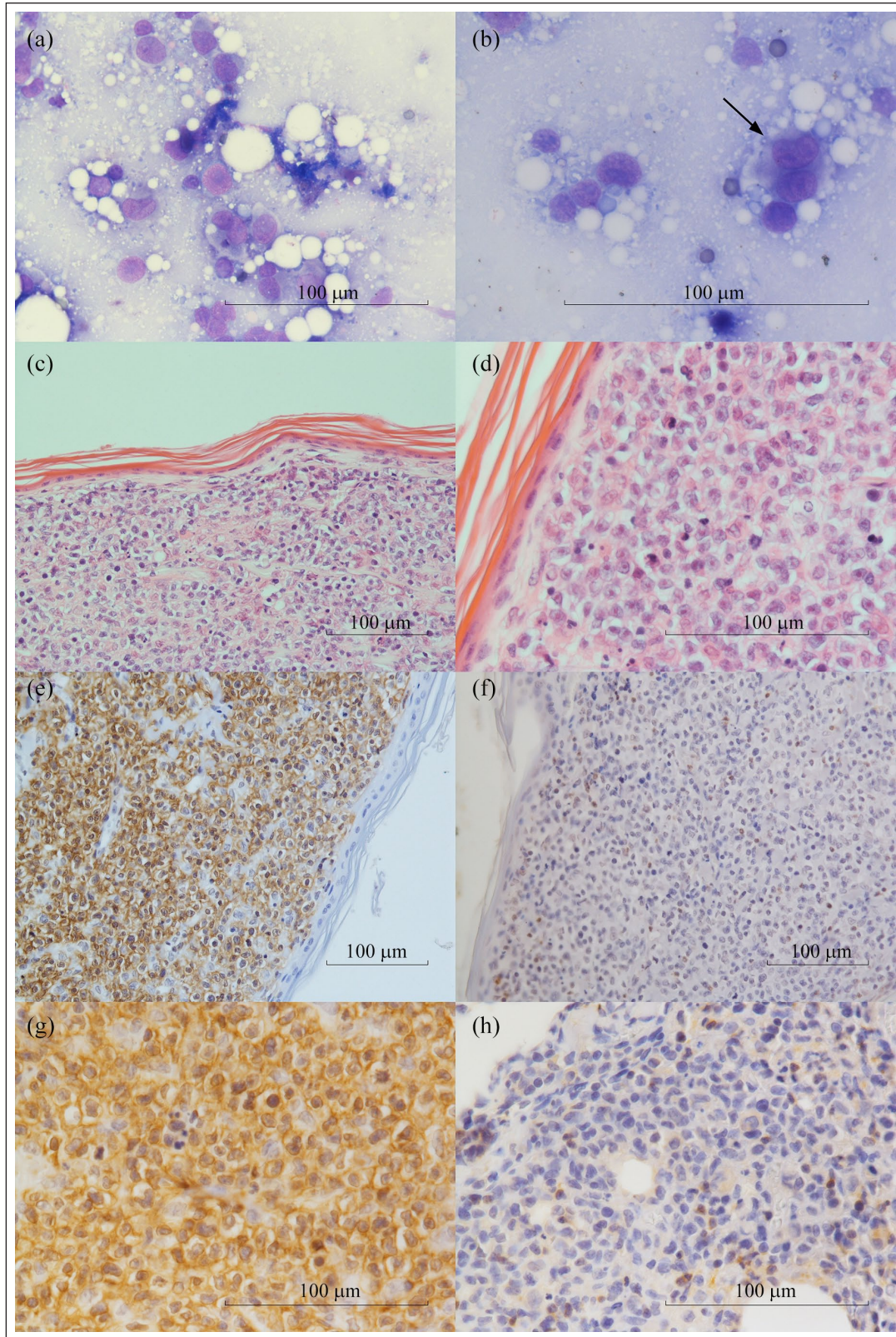
Serum ELISA for FeLV and FIV yielded negative results, and the swab results indicated the presence of *Staphylococcus intermedius*. A culture of hair samples for

dermatophytes was performed and no growth was observed.

The radiographs were negative for macroscopic lesions, and the ultrasonography examination showed a normal renal medulla and cortex. Cytological specimens obtained by FNA revealed a homogeneous cell population characterised by medium-to-large round cells (approximately 30–60µm in diameter), abundant cytoplasm, weakly basophilic staining and occasional microvacuolations. The diameter of the nuclei ranged from 1.5-fold to more than two-fold the size of RBCs, and the nuclei were centrally located, round or cleaved, with occasionally >2 prominent round nucleoli. Anisocytosis and anisokaryosis were moderate. Occasional binucleated cells were observed.

The preliminary diagnosis was malignant round-cell neoplasia with cytological features suggestive of either a lymphoid origin or histiocytic disorders (feline progressive histiocytosis). Histological examination of the biopsy specimens revealed medium-to-large round neoplastic cells, consistent with neoplastic lymphocytes that infiltrated the dermis and subcutis and highly suggestive of a round-cell cutaneous tumour, most likely a lymphoma. No evidence of epitheliotropism was observed. The neoplastic cells showed moderate mitotic activity, with 25 mitotic figures per 10 high-power (×400) fields. Immunohistochemistry confirmed a predominant neoplastic population of round cells with strong membrane and cytoplasmic positivity for the CD20 antigen (B cells); only a few non-neoplastic reactive cells were positive for the CD3 antigen (T cells) (Figure 2). Taken together, these findings indicated a diagnosis of cutaneous non-epitheliotropic B-cell lymphoma with pleomorphic, medium and large cell types.

The owner elected to have the cat euthanased but did not grant authorisation for a necropsy to be performed.



**Figure 2** Feline cutaneous non-epitheliotropic B-cell lymphoma. (a) A population of medium and large round elements has been highlighted, with abundant cytoplasm and a round-to-cleaved nucleus with prominent and irregular nucleolus (May–Grünwald–Giemsa [MGG],  $\times 40$ ). (b) Several binucleated (arrow) cells can be seen (MGG,  $\times 60$ ). (c) Medium and large round neoplastic cells infiltrate extensively the superficial and deep dermis (haematoxylin and eosin [H&E],  $\times 20$ ). (d) There was no evidence of epitheliotropism in the neoplastic cells (H&E,  $\times 40$ ). (e–g) Neoplastic cells show strong positivity to CD20 marker (immunohistochemistry [IHC],  $\times 20$ ,  $\times 40$ ). (f–h) Few cells show positivity to marker CD3 (IHC,  $\times 20$ ,  $\times 40$ )

## Discussion

Cutaneous lymphoma is an uncommon neoplasia in people and animals. While epitheliotropism is rarely observed in cats,<sup>10</sup> cutaneous non-epitheliotropic lymphoma is the most frequent form in cats.<sup>24</sup> Epitheliotropism of the neoplastic lymphocytes results from their expression of specific integrins, which may mediate a direct interaction with keratinocytes.<sup>25</sup> Similar to the findings in other species, cutaneous lymphomas mostly have a T-cell origin,<sup>13,15,26–28</sup> even if they are associated with bone fracture sites,<sup>21</sup> while B-cell tumours are considered extremely rare.<sup>10,29</sup> The aetiology of feline cutaneous non-epitheliotropic lymphoma, as for dogs, is unknown;<sup>20</sup> however, chronic inflammation is thought to be a risk factor for its onset and development.<sup>10,21</sup> Among the hypothesised aetiologies,<sup>20</sup> the role of ultraviolet radiation exposure as a possible explanation for the onset of this specific cutaneous tumour remains a remote possibility, considering the fact that the cat used to live indoors.

For human patients, the World Health Organization–European Organization for the Research and Treatment of Cancer has defined three main subtypes of primary cutaneous B-cell lymphoma based on the cellular morphology: primary cutaneous marginal zone lymphoma; primary cutaneous follicle centre lymphoma; and primary cutaneous large B-cell lymphoma (leg type).<sup>30</sup> The latter, following recent advice, seems to be the more frequently reported form in cats. Typical lesions of non-epitheliotropic lymphoma are characterised by diffuse or nodular growth and are infrequently associated with scaling and itching.<sup>11</sup> Feline cutaneous non-epitheliotropic B-cell lymphoma tends to be located in the tarsal region,<sup>14,31</sup> but it has also been described at vaccine injection sites.<sup>10</sup>

The cellular morphology of cutaneous non-epitheliotropic lymphoma and the mitotic activity are highly variable, and cellular pleomorphism can partially overlap with that reported in dogs.<sup>20</sup> In this case, a multifocal distribution of lesions was predominantly noted on the trunk and abdomen regions, with different stages of lesion evolution associated with general itching. A case report describing a non-epitheliotropic B-cell lymphoma with multiple cutaneous proliferations was reported in a Weimaraner dog with the presence of lymphocytes with atypical spindle-cell morphology.<sup>32</sup>

Feline cutaneous lymphomas are typical in older cats (mean age 11 years),<sup>11</sup> and the patients are usually FeLV seronegative,<sup>13,14,28</sup> as in this case. Even if this finding has not been demonstrated, both circulating FeLV antigen and integrated FeLV provirus have been identified in tumour DNA by PCR.<sup>25</sup> Regarding prevalence with respect to sex and breed, females and European Shorthair cats show the highest odds of developing a tumour in the skin or subcutis.<sup>2,5</sup>

As reported by Neta et al,<sup>11</sup> the masses tend to grow very rapidly in size and number. In dogs, skin lesions

present as small nodules characterised by a slowly progressive development. Dogs often do not show general signs.<sup>24</sup> In this case, blood examinations revealed mild anaemia associated with hypoproteinaemia and a moderate increase in total calcium levels.<sup>33</sup> Malignant hypercalcaemia is less common in cats than in dogs.<sup>34</sup> In cats, this correlation has been reported in the light of the associations with retroviral infection (FeLV), lymphoma and hypercalcaemia,<sup>35</sup> and also in other neoplastic environments,<sup>36</sup> particularly when involving the cutis.<sup>36–38</sup> There is no available literature that allows a comparison of this haematic value between non-epitheliotropic cutaneous lymphoma localised in the tarsal region and the form described in this report. As reported for other neoplastic conditions in cats,<sup>39</sup> in our case report radiographs of the thorax and abdomen were unremarkable, as was the abdominal ultrasound. In dogs, the majority of cutaneous non-epitheliotropic lymphomas exhibit rapid progression and metastasis to draining lymph nodes and subsequent systemic involvement.<sup>20</sup> In cases of feline multifocal cutaneous non-epitheliotropic B-cell lymphoma, metastatic episodes affecting other organs have been reported, particularly in the liver, spleen, jejunum and mesenteric serosa.<sup>29</sup> In cutaneous lymphoma of the tarsus, abdominal ultrasound shows an increase in the number of medial iliac lymph nodes, inguinal lymph nodes, omentum, liver and spleen.<sup>14,31</sup> Cats with extranodal subcutaneous lymphoma show aggressive biological behaviour.<sup>4</sup>

The differential diagnosis for this pathology may indicate Sézary syndrome, a rare end-stage leukaemic variant of cutaneous T-cell lymphoma and cutaneous lymphoid hyperplasia;<sup>40,41</sup> disseminated cutaneous mast-cell tumours;<sup>8</sup> feline skin fragility syndrome;<sup>42</sup> cutaneous lymphosarcoma that could present in association with paraneoplastic syndromes;<sup>37</sup> cutaneous lymphocytosis, a rare benign form characterised by proliferation of T and/or B lymphocytes in the dermis and could be fatal when presenting with visceral involvement;<sup>43,44</sup> and, finally, feline progressive histiocytosis.<sup>45</sup>

Non-epitheliotropic lymphomas affecting the skin are poorly responsive to chemotherapy or radiation therapy.<sup>11</sup> Treatments described for feline cutaneous lymphoma include the use of corticosteroids alone, chemotherapy (CHOP protocol; vincristine and cyclophosphamide), placental lysate, and intravenous and local administration of fibronectin. In this case, the patient showed no dermatological benefits, even with the use of corticosteroids. In cats with epitheliotropic cutaneous lymphosarcoma, corticosteroids do not induce remission,<sup>46</sup> while non-epitheliotropic cutaneous lymphoma shows a transient response to chemotherapy (ie, lomustine), which is associated with a short remission period. The prognosis is poor, with a variable median survival time (MST) from diagnosis<sup>24,28</sup> that is shorter than that in patients with T-cell cutaneous lymphoma,

which show an MST of 10.25 months.<sup>13</sup> Burr et al<sup>14</sup> reported that the average survival period of patients with cutaneous lymphoma of the tarsus was 190 days, highlighting the aggressiveness of this disorder. As reported by Sierra et al,<sup>31</sup> a survival period of 2.1 months (63 days) was achieved using chemotherapy (lomustine and prednisolone). The opposite situation is reported in dogs, where B-lymphocyte tumours are associated a longer survival time than T-lymphocyte tumours.<sup>20</sup> Cunha et al<sup>29</sup> reported a case of a cat with nodules diffusely spread throughout the skin that were compatible with non-epitheliotropic cutaneous lymphoma of B-cell origin, in which the patient underwent systemic antineoplastic therapy and showed clinical remission for a 10-month period after diagnosis.

The choice to not proceed with post-mortem examination, owing to the owner's decision, and the missed popliteal lymph node needle aspiration, made it impossible to identify potential metastasis in the present case.

## Conclusions

In this report, we describe a case of multifocal cutaneous non-epitheliotropic B-cell lymphoma. The primary origin cannot be definitively assigned because of the lack of necroscopic findings. Evidence-based exclusion of other possible sites of origin is impossible. However, no sign of involvement of other structures was found on diagnostic imaging. In our opinion, for these reasons, the primary origin is more likely than metastatic origin. We also think that this form of multifocal cutaneous non-epitheliotropic B-cell lymphoma should be reported as a very rare but possible form of feline cutaneous tumour.

**Acknowledgements** We would like to thank Editage ([www.editage.com](http://www.editage.com)) for English language editing.

**Conflict of interest** The authors declared no potential conflicts of interest with respect to the research, authorship, and/or publication of this article.

**Funding** The authors received no financial support for the research, authorship, and/or publication of this article.

**Ethical approval** This work involved the use of non-experimental animals only (including owned or unowned animals and data from prospective or retrospective studies). Established internationally recognised high standards ('best practise') of individual veterinary clinical patient care were followed. Ethical approval from a committee was therefore not necessarily required.

**Informed consent** Informed consent (either verbal or written) was obtained from the owner or legal custodian of all animal(s) described in this work (either experimental or

non-experimental animals) for the procedure(s) undertaken (either prospective or retrospective studies). For any animals or humans individually identifiable within this publication, informed consent for their use in the publication (verbal or written) was obtained from the people involved.

**ORCID iD** Matteo Zanzabro  <https://orcid.org/0000-0002-4007-9871>

## References

- Graf R, Gruntzig K, Hassig M, et al. **Swiss feline cancer registry: a retrospective study of the occurrence of tumors in cats in Switzerland from 1965 to 2008.** *J Comp Pathol* 2015; 153: 266–277.
- Manuali E, Forte C, Vichi G, et al. **Tumours in European Shorthair cats: a retrospective study of 680 cases.** *J Feline Med Surg.* Epub ahead of print 12 February 2020. DOI: 10.1177/1098612X20905035.
- Vascellari M, Baioni E, Ru G, et al. **Animal tumour registry of two provinces in northern Italy: incidence of spontaneous tumors in dogs and cats.** *BMC Vet Res* 2009; 5: 39. DOI: 10.1186/1746-6148-5-39.
- Meichner K and von Bomhard W. **Patient characteristics, histopathological findings and outcome in 97 cats with extranodal subcutaneous lymphoma (2007–2011).** *Vet Comp Oncol* 2014; 14 Suppl1: 8–20.
- Graf R, Gruntzig K, Boo G, et al. **Swiss feline cancer registry 1965–2008: the influence of sex, breed and age on tumour types and tumour locations.** *J Comp Pathol* 2016; 154: 195–210.
- Ho NT, Smith KC and Dobromylskyj MJ. **Retrospective study of more than 9000 feline cutaneous tumours in the UK: 2006–2013.** *J Feline Med Surg* 2018; 20: 128–134.
- Miller MA, Nelson SL, Turk JR, et al. **Cutaneous neoplasia in 340 cats.** *Vet Pathol* 1991; 28: 389–395.
- Lamm CG, Stern AW, Smith AJ, et al. **Disseminated cutaneous mast cell tumors with epitheliotropism and systemic mastocytosis in a domestic cat.** *J Vet Diagn Invest* 2009; 21: 710–715.
- Moore PF and Olivry T. **Cutaneous lymphomas in companion animals.** *Clin Dermatol* 1994; 12: 499–505.
- Roccabianca P, Avallone G, Rodriguez A, et al. **Cutaneous lymphoma at injection sites: pathological, immunophenotypical, and molecular characterization in 17 cats.** *Vet Pathol* 2016; 53: 823–832.
- Neta M, Naigamwalla D and Bienzle D. **Perforin expression in feline epitheliotropic cutaneous lymphoma.** *J Vet Diagn Invest* 2008; 20: 831–835.
- Kracic MR and Black SS. **Epitheliotropic T-cell gastrointestinal tract lymphosarcoma with metastases to lung and skeletal muscle in a cat.** *J Am Vet Med Assoc* 2000; 216: 524–529.
- Fontaine J, Heimann M and Day MJ. **Cutaneous epitheliotropic T-cell lymphoma in the cat: a review of the literature and five new cases.** *Vet Dermatol* 2011; 22: 454–461.
- Burr HD, Keating JH, Clifford CA, et al. **Cutaneous lymphoma of the tarsus in cats: 23 cases (2000–2012).** *J Am Vet Med Assoc* 2014; 244: 1429–1434.
- Weiss AA, Klopffleisch R and Gruber AD. **T-cell receptor  $\gamma$  chain variable and joining region genes of subgroup 1 are**

- clonally rearranged in feline B- and T-cell lymphoma. *J Comp Pathol* 2011; 144: 123–134.
- 16 Mochizuki H, Nakamura K, Sato H, et al. **GeneScan analysis to detect clonality of T-cell receptor gene rearrangement in feline lymphoid neoplasms.** *Vet Immunol Immunopathol* 2012; 145: 402–409.
  - 17 Wagner M, Rose VA, Linder R, et al. **Human pathogenic virus-associated pseudolymphomas and lymphomas with primary cutaneous manifestation in humans and animals.** *Clin Infect Dis* 1998; 27: 1299–1308.
  - 18 Morand P, Buisson A, Collandre H, et al. **Human herpesvirus 8 and Epstein Barr-virus in a cutaneous B-cell lymphoma and a malignant cell line established from the blood of an AIDS patient.** *Leuk Lymphoma* 1999; 35: 379–387.
  - 19 Bradford PT, Devesa SS, Anderson WF, et al. **Cutaneous lymphoma incidence patterns in the United States: a population-based study of 3884 cases.** *Blood* 2009; 113: 5064–5073.
  - 20 De Bosschere H and Declercq J. **Cutaneous nonepitheliotropic B-cell lymphoma in a Golden retriever.** *Vlams Diergeneeskund Tijdschr* 2008; 77: 315–318.
  - 21 Jegatheeson S, Wayne J and Brockley LK. **Cutaneous non-epitheliotropic T-cell lymphoma associated with a fracture site in a cat.** *JFMS Open Rep* 2018; 4. DOI: 10.1177/2055116918760357.
  - 22 Rook KA. **Canine and feline cutaneous epitheliotropic lymphoma and cutaneous lymphocytosis.** *Vet Clin North Am Small Anim Pract* 2019; 49: 67–81
  - 23 Properzi R, Boschi P and Leonardi F. **Ovarian remnant syndrome after laparoscopic ovariectomy in a cat.** *J Hellen Vet Med Soc* 2018; 69: 1305–1308.
  - 24 Marconato L, Rossi F, Bettini G, et al. **Linfoma.** In: Marconato L and Amadori D (eds). *Oncologia medica veterinaria e comparata*. Vermezzo: Poletto Editore, 2012, pp 759–817.
  - 25 Day MJ. **Immunophenotypic characterization of cutaneous lymphoid neoplasia in the dog and cat.** *J Comp Pathol* 1995; 112: 79–96.
  - 26 Plant JD. **Would you have diagnosed cutaneous epitheliotropic lymphoma in these two cats?** *Vet Med* 1991; 86: 801–806.
  - 27 Tobey JC, Houston DM, Breur GJ, et al. **Cutaneous T-cell lymphoma in a cat.** *J Am Vet Med Assoc* 1994; 204: 606–609.
  - 28 Komori S, Nakamura S, Takahashi K, et al. **Use of lomustine to treat cutaneous nonepitheliotropic lymphoma in a cat.** *J Am Vet Med Assoc* 2005; 226: 237–239.
  - 29 Cunha FM, Silveira LMG, Xavier JG, et al. **Linfoma tegumentar felino: relato de caso.** *Clin Vet* 2010; 15: 68–72.
  - 30 Fink-Puches R, Zenahlik P, Back B, et al. **Primary cutaneous lymphomas: applicability of current classification schemes (European Organization for Research and Treatment of Cancer, World Health Organization) based on clinicopathologic features observed in a large group of patient.** *Blood* 2002; 99: 800–805.
  - 31 Sierra O, Viéra R, Ferreira M, et al. **Cutaneous lymphoma of the tarsus in a cat – case study.** *Rev MVZ Córdoba* 2017; 22: 5747–5754.
  - 32 Witt S, Willeke K, Kohler K, et al. **Non-epitheliotropic B-cell lymphoma with atypical spindle cell morphology in a Weimaraner dog.** *Tierarztl Prax Ausg K Kleintiere Heimtiere* 2018; 46: 119–125.
  - 33 Daniels E and Sakakeeny C. **Hypercalcemia: pathophysiology, clinical signs, and emergent treatment.** *J Am Hosp Assoc* 2015; 51: 291–299.
  - 34 Engelman RW, Tyler RD, Good RA, et al. **Hypercalcemia in cats with feline leukemia virus associated with leukemia-lymphoma.** *Cancer* 1985; 56: 771–781.
  - 35 Kohart NA, Elshafae SM, Breitbach JT, et al. **Animal models of cancer-associated hypercalcemia.** *Vet Sci* 2017; 4: 21.
  - 36 Klausner JS, Bell FW, Hayden DW, et al. **Hypercalcemia in two cats with squamous cell carcinomas.** *J Am Vet Med Assoc* 1990; 196: 103–105.
  - 37 Dust A, Norris AM and Valli VEO. **Cutaneous lymphosarcoma with Ig monoclonal gammopathy serum hyperviscosity and hypercalcemia in a cat.** *Can Vet J* 1982; 23: 235
  - 38 Hauck ML. **Tumors of skin and subcutaneous tissues.** In: Withrow S, Vail DM and Page R (eds). *Withrow & MacEwen's small animal clinical oncology*. St Louis, MO: Elsevier, 2013, pp 305–320.
  - 39 Newton J, de Vicente F, Haugland SP, et al. **Extra-nodal subcutaneous Hodgkin's-like lymphoma and subsequent regression in a cat.** *J Feline Med Surg* 2015; 17: 543–547.
  - 40 Wood C, Almes K, Bagladi-Swanson M, et al. **Sézary syndrome in a cat.** *J Am Anim Hosp Assoc* 2008; 44: 144–148.
  - 41 Snead E, Kerr M and MacDonald V. **Cutaneous lymphoid hyperplasia mimicking cutaneous lymphoma in a hyperthyroid cat.** *Can Vet J* 2013; 54: 974–978.
  - 42 Crosaz O, Vilaplana-Grosso F, Alleaume C, et al. **Skin fragility syndrome in a cat with multicentric follicular lymphoma.** *J Feline Med Surg* 2013; 15: 953–958.
  - 43 Colombo S, Fabbrini F, Corona A, et al. **Linfocitosi cutanea felina: descrizione di tre casi clinici.** *Veterinaria* 2011; 25: 25–31.
  - 44 Pariser MS and Gram DW. **Feline cutaneous lymphocytosis: case report and summary of the literature.** *J Feline Med Surg* 2014; 16: 758–763.
  - 45 Coste M, Prata D, Castiglioni V, et al. **Feline progressive histiocytosis: a retrospective investigation of 26 cases and preliminary study of Ki67 as a prognostic marker.** *J Vet Diagn Invest* 2019; 31: 801–808.
  - 46 Vonderhaar MA and Morrison WB. **Lymphosarcoma.** In: Morrison WB (ed). *Cancer in dogs and cats: medical and surgical management*. Jackson, WY: Teton New media, 2002, pp 641–670.