



---

## **Formation of a meningoencephalocele after removal of a frontal lobe meningioma by transfrontal craniotomy in a cat**

Authors: Günther, Christian, Beckmann, Katrin M, and Steffen, Frank

Source: Journal of Feline Medicine and Surgery Open Reports, 6(2)

Published By: SAGE Publishing

URL: <https://doi.org/10.1177/2055116920957195>



# Formation of a meningoencephalocele after removal of a frontal lobe meningioma by transfrontal craniotomy in a cat

*Journal of Feline Medicine and Surgery Open Reports*  
1–6

© The Author(s) 2020

Article reuse guidelines:

sagepub.com/journals-permissions

DOI: 10.1177/2055116920957195

journals.sagepub.com/home/jfmsopenreports

This paper was handled and processed by the European Editorial Office (ISFM) for publication in *JFMS*



Christian Günther<sup>1</sup> , Katrin M Beckmann<sup>2</sup> and Frank Steffen

## Abstract

**Case summary** A 10-year-old castrated male domestic shorthair cat was referred for surgical treatment of a left-sided frontal lobe meningioma diagnosed by CT. Clinically, the cat had generalised tonic–clonic seizures, which reduced in frequency after treatment was started with prednisolone. After definition of the anatomical landmarks of the feline skull, a bilateral transfrontal craniotomy allowed en bloc removal of the meningioma. While postoperative recovery was uneventful, right-sided proprioceptive deficits were still present 6 months after surgery. MRI detected a probable meningoencephalocele herniating through the surgical bone defect in the frontal sinus. Because of the mild neurological deficits and good quality of life, the meningoencephalocele was not treated. Thirty-one months after meningioma removal the cat was alive without further neurological progression.

**Relevance and novel information** To our knowledge, this is the first report to describe, in detail, the technique of transfrontal craniotomy in cats. Iatrogenic meningoencephalocele is a complication that has not previously been described after meningioma removal in cats, and should be considered as a potential complication after craniotomy.

**Keywords:** Meningioma; craniotomy; meningoencephalocele; complication

**Accepted:** 8 August 2020

## Introduction

Meningioma is the most common intracranial neoplasia in cats.<sup>1–3</sup> Treatment options include medical management, surgical removal, or debulking and irradiation. Survival time differs significantly between treatments. The reported median survival time of surgically treated cats ranges between 22 and 37 months vs 14 months after irradiation and 18 days with medical management.<sup>1,4–6</sup> Thus, surgical removal is the treatment of choice in many cases of feline meningioma unless the tumour location limits a surgical approach.

Various craniotomy procedures in cats have been published.<sup>7–9</sup> Transfrontal craniotomy for removal of neoplasia affecting the olfactory bulb and frontal lobes has been described in dogs.<sup>10,11</sup> Although this approach was mentioned in a large series of cats with meningiomas, a detailed procedural description is lacking.<sup>5</sup> Reported complications of craniotomy include intraventricular tension pneumocephalus, pneumorrhachis,

central blindness, anaemia, aspiration pneumonia and acute renal failure.<sup>1,5,10,11</sup>

Herein, we describe a modified bilateral transfrontal craniotomy procedure for the removal of a frontal lobe meningioma in a cat, and report the development of a nasofrontal meningoencephalocele, a novel complication.

## Case description

A 10-year-old castrated male domestic shorthair cat was referred for surgical removal of a presumed left frontal lobe meningioma detected during CT by the referring veterinary

Clinic of Small Animal Surgery/Neurology, Vetsuisse Faculty, University of Zurich, Zurich, Switzerland

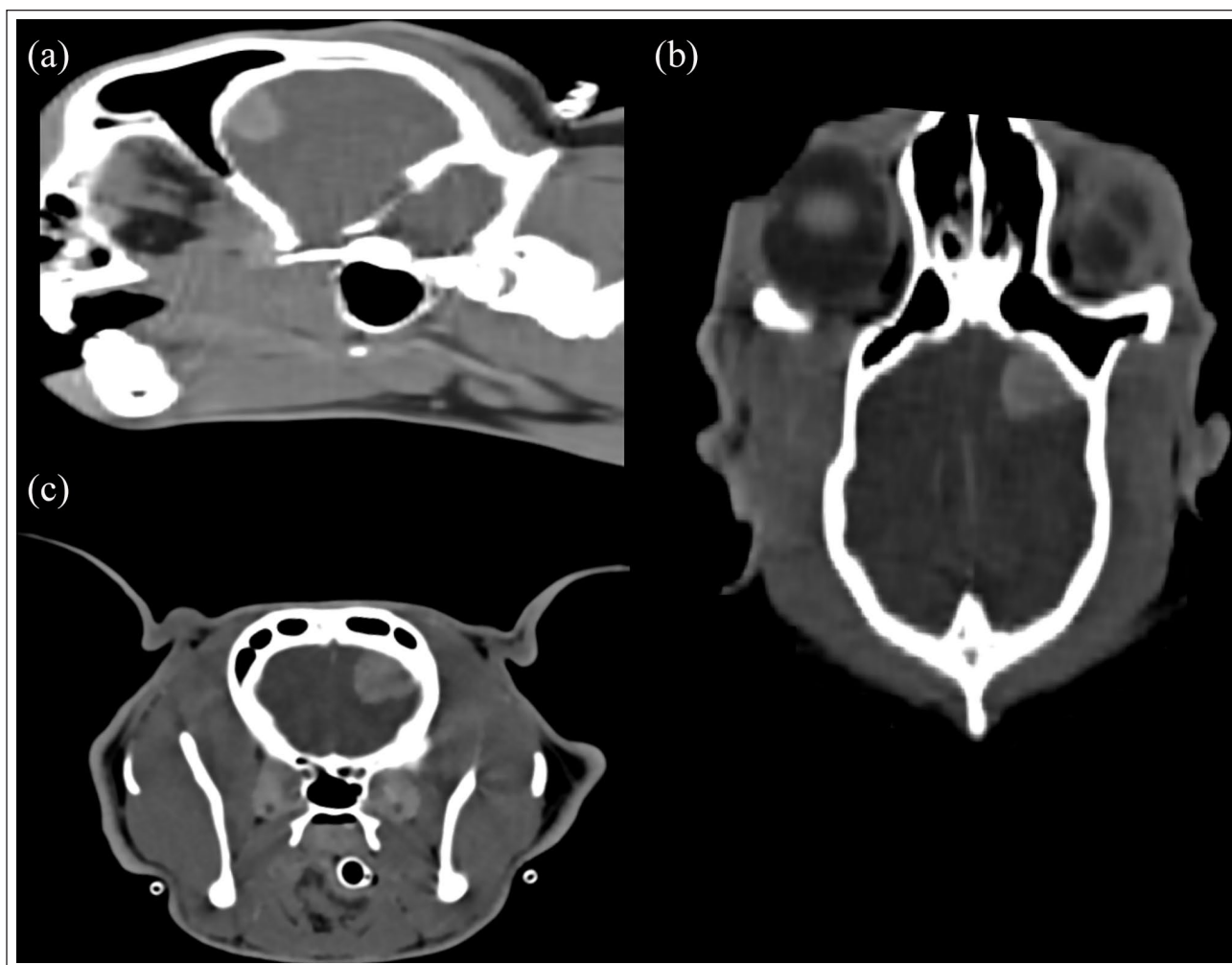
### Corresponding author:

Christian Günther Med Vet, Clinic of Small Animal Surgery/Neurology, Vetsuisse Faculty, University of Zurich, Winterthurerstrasse 258c, Zurich, 8057, Switzerland  
Email: cguenther@vetclinics.uzh.ch



Creative Commons Non Commercial CC BY-NC: This article is distributed under the terms of the Creative Commons

Attribution-NonCommercial 4.0 License (<https://creativecommons.org/licenses/by-nc/4.0/>) which permits non-commercial use, reproduction and distribution of the work without further permission provided the original work is attributed as specified on the SAGE and Open Access pages (<https://us.sagepub.com/en-us/nam/open-access-at-sage>).



**Figure 1** (a) Sagittal, (b) dorsal and (c) transaxial contrast-enhanced CT brain images of a cat with a broad-based, well-demarcated space-occupying lesion over the left frontal lobe. Note the subtle thickening of the frontal bone over the suspected meningioma

clinic. Reported clinical signs included generalised tonic-clonic seizures, altered mentation, pupillary changes, and shaking and scratching of the head. Haematology and blood chemistry were within normal limits. The cat was initially treated with prednisolone (0.4 mg/kg PO q24h [Prednisolon; Streuli]) 5 days before referral.

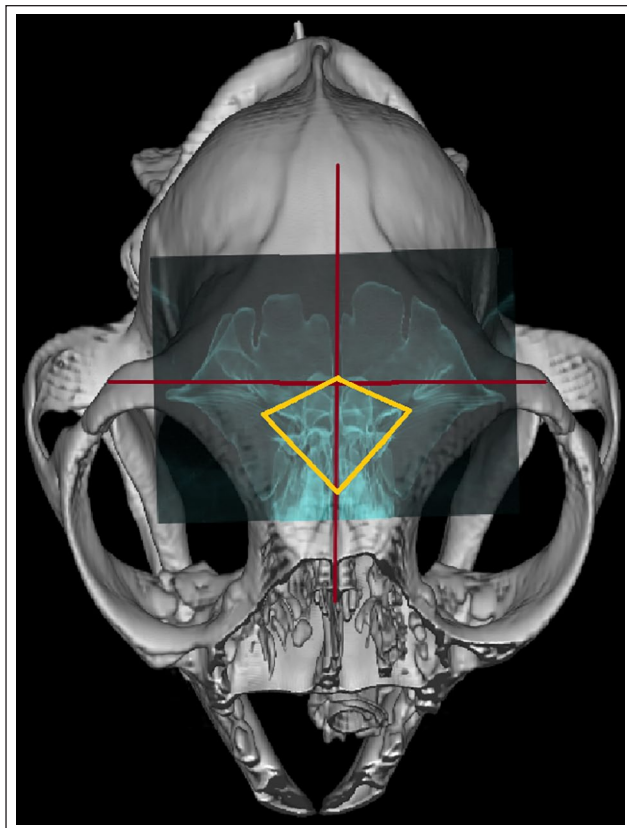
At presentation, neither physical nor neurological examination revealed abnormal findings. The CT study performed by the referring veterinary clinic showed a round, solitary, well-delineated and isodense, space-occupying lesion with marked homogeneous contrast enhancement in the left frontal lobe (Figure 1). Based on the imaging characteristics a meningioma was suspected. Thoracic radiographs and abdominal ultrasound showed no abnormalities.

Medetomidine (4 µg/kg IM [Dormitor; Provet AG]), methadone (0.2 mg/kg IM [Methadon; Streuli]) and propofol (2.8 mg/kg IV [Propofol MCT; Fresenius Kabi AG]) were used for sedation and induction of anaesthesia.

After intubation, oxygen with sevoflurane (Sevoflurane; Baxter AG) and fentanyl (5 µg/kg/h IV [Fentanyl Janssen; Janssen-Cilag]) was used to maintain anaesthesia. The cat received cefazoline (22 mg/kg IV [Kefzol; Teva Pharma]), esomeprazole (1 mg/kg IV [Esomep; AstraZeneca AG]) and mannitol (0.5 g/kg IV [Mannitol Bichsel; Grosse Apotheke Dr G Bichsel AG]) before surgery.

The surgical procedure was broadly based upon the description of a modified transfrontal craniotomy in dogs.<sup>12-14</sup> The fur was clipped from the lateral canthus of the eyes to the occipital protuberance and laterally to the zygomatic arches. The skin was prepared aseptically and the cat was placed in sternal recumbency with the head elevated ~30°.

Anatomical landmarks in cats differ from those in dogs. In dogs the bregma landmark, a point on the midline where the left and right frontoparietal sutures meet, demarcates the caudal extent of the frontal sinus. In cats this point can hardly be palpated. Instead, a transverse



**Figure 2** CT three-dimensional reconstruction. Rostradorsal view of the skull of the cat in this report. The red cross marks the caudal extent of the bone window and marks the midline point of a transverse line joining the left and right zygomatic processes of the frontal bones. The frontal sinus margins are reconstructed (blue). The red cross is pointing at the caudal extent of the bone window, connecting the zygomatic processes of the frontal bones. The yellow, diamond-shaped window demonstrates the extension of the surgical approach

line from the rostral border of the zygomatic process of the frontal bone at its insertion was drawn to the other side to identify the caudal extent of the frontal sinus (Figure 2). The skin was incised at the midline extending 4 cm caudally from the caudal end of the nasal bones. Subcutis, fascia and periosteum were bluntly retracted with a periosteal elevator.

Bilateral transfrontal craniotomy was started by drilling a 1.1 mm hole at the mid-point in the aforementioned imaginary line (Battery reamer/drill; DePuy Synthes). The cut was continued rostrolaterally at an angle of 30° and a length of 0.5 cm and then back in a rostromedial direction to the junction of the nasal bones. The same procedure was performed on the opposite side. The cut created a diamond-shaped bone plate, which was removed by using a periosteal elevator. Removal of the relatively thin bone was complicated by firm attachments to underlying bony septi and ethmoturbinates within the frontal sinus. The bone plate was stored in a

saline container and saved for replacement at the end of the procedure. After careful removal of the ethmoturbinates, exposing the internal table of the sinus, the cranial cavity was opened with a 2.0 mm bone burr (II-drive; Stryker). Fine Kerrison rongeurs were used to expose the frontal lobes and the overlying mass. After incision of the dura, the mass was gently mobilised by grabbing its surface with atraumatic forceps and removing attachment with surrounding tissue using iridectomy scissors. The mass was removed en bloc and was submitted for histological examination. Haemorrhage from the excisional area was minimal and was controlled with bipolar cauterisation and gauze sponges. The operation site was intensively flushed with physiological saline. The dura was left open and no grafts were placed over the defect. Neither cerebrospinal fluid (CSF) leakage nor haemorrhage were observed at the end of the procedure.

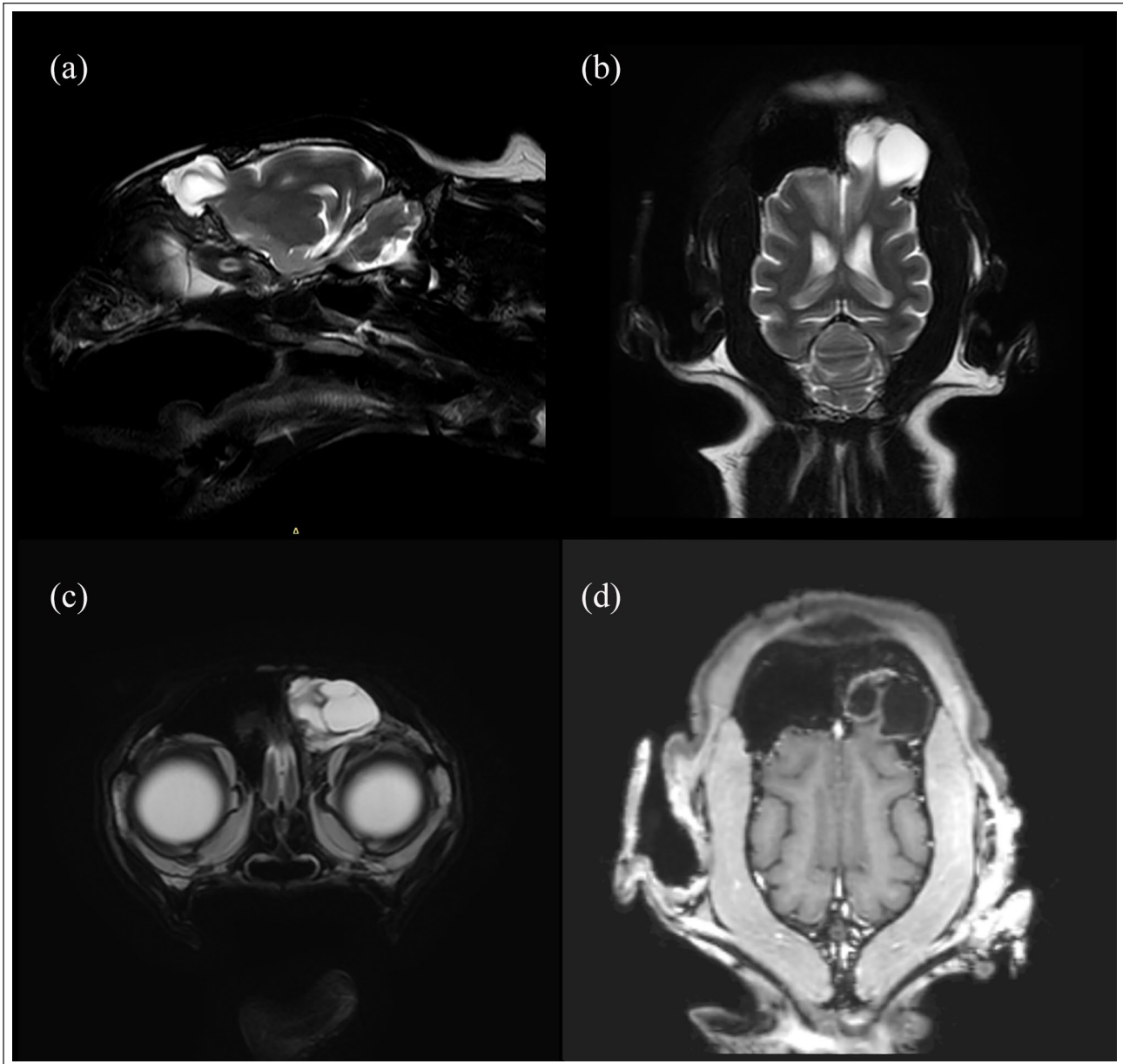
The bone plate was replaced after drilling three holes with a 2 mm burr close to the lateral and caudal borders and corresponding levels of the frontal bone. A monofilament of polydioxanone (PDS 3-0; Ethicon) was used to attach the bone fragment. The fascia and the subcutis were separately sutured in a continuous pattern. The skin was closed with interrupted sutures (Supramid 4-0 [B Braun Medical AG]).

Postoperatively, the cat was sedated for the first 12 h with dexmedetomidine (0.5 µg/kg/h IV [Dexdomitor; Provet AG]). Further cefazoline (22 mg/kg PO q12h), gabapentin (10 mg/kg PO q8h [Gabapentin Mepha; Mepha Pharma AG]), buprenorphine (20 µg/kg IV q6h [Temgesic; Indivior AG]), prednisolone (0.4 mg/kg PO q24h) and phenobarbital (2 mg/kg PO q12h [Aphenyl b-arbit; Streuli]) were administered. One day after surgery the cat started eating and no abnormalities were found on physical examination. Neurological examination revealed an absent menace reaction on the right side and mydriatic pupils bilaterally responsive to light normally. The cat was mildly hemiparetic with decreased postural reactions on the right side. After 3 days, the cat was discharged with cefazoline and a tapering dosage of prednisolone for 7 days and phenobarbital for the next 4 weeks.

Histological diagnosis was of a fibroblastic meningioma (World Health Organization grade 1).

Six months after surgery, follow-up examination showed persisting mild proprioceptive deficits and a mild hemiparesis on the right side. No further neurological deficit was found. The owner did not report any abnormalities. The cat still received phenobarbital (2 mg/kg PO q12h).

A scheduled MRI (Philips Ingenia 3.0T; Philips AG) was performed to exclude incomplete tumour removal or regrowth with the following sequences: T2-weighted (T2W) sagittal, transverse and dorsal; T2W gradient echo transverse; transverse fluid-attenuated inversion recovery (FLAIR); T1-weighted three-dimensional ultrafast



**Figure 3** T2-weighted (a) parasagittal, (b) dorsal and (c) transaxial MRI, and (d) T1-weighted post-gadolinium dorsal MRI of a cat after transfrontal craniotomy. (a) Herniation of a fluid-filled lesion containing small structures of brain tissue into the frontal sinus. (b) The boundaries of the lesion are continuous with the brain parenchyma. A thin septum originating from the cerebral cortex extends throughout the lesion and terminates with a broader-based attachment at the wall of the lesion. (c) The lesion fills the entire left frontal sinus. (d) Mild contrast uptake at the margins of the lesion facing the frontal sinus wall

gradient echo pre- and post-contrast agent injection; and transverse susceptibility-weighted images.

At the craniotomy site, a round, well-demarcated heterogeneous lesion protruded through the missing internal lamina of the left frontal bone into the left frontal sinus (1.6 × 1.0 × 0.9 cm). The lesion was continuous with the brain parenchyma of the left cerebral hemisphere. Within the lesion fluid was present, which was isointense compared with CSF in T2, hypointense in FLAIR and hypointense in T1. No contrast enhancement of the lesion

itself was noted. Mild contrast uptake was visible within the rostral margin of the bony frontal sinus. Also, a small portion of cerebral cortex bulged into the fluid-filled lesion and a thin, septum-like structure isointense to white matter extended throughout the lesion.

Based upon the MRI findings, a nasofrontal meningoencephalocele herniating into the left frontal sinus was assumed (Figure 3).

Because of the mild, non-progressive neurological deficits surgical treatment was not considered, although

another underlying cause of the neurological deficits could not be excluded. Further management included anticonvulsive treatment with phenobarbital (2mg/kg PO q12h) only.

Thirty-one months after removal of the meningioma the cat was still alive without further neurological progression. The referring veterinarian informed us about the development of hyperthyroidism and hypertrophic cardiomyopathy. The owner reported weight loss and that the cat had become weaker. Otherwise the cat was doing well.

## Discussion

This case report describes the development of a meningoencephalocele after bilateral transfrontal craniotomy for removal of a meningioma, which has not been previously described in a cat.

This approach has been described in detail in dogs but not specifically in cats.<sup>12</sup> Important differences to the procedure in dogs include the absence of useful anatomical landmarks such as the bregma line, and the wider opening angle of the frontal sinus at its caudal border. Despite the small dimensions of the feline frontal sinus, access to the frontal lobes via this approach is adequate and allowed complete resection of a unilateral meningioma without excessive damage to adjacent structures.

A nasofrontal meningoencephalocele was detected as a late postoperative complication of this surgery. By definition, meningoencephaloceles consist of skin-covered meninges and brain tissue herniating through a defect in the skull. They can be categorised into congenital and acquired conditions.<sup>15</sup> Acquired meningoencephaloceles are rarely described in cats and can be of non-traumatic, traumatic and spontaneous origin following the human classification scheme.<sup>16,17</sup> In the present case an iatrogenic traumatic aetiology was obvious.

In humans, meningoencephaloceles are reported complications after decompressive craniotomy performed owing to traumatic injury and drug abuse resulting in osseous destruction.<sup>17–20</sup> One study reported a 9.3% rate of meningoencephaloceles after cranioplasty.<sup>20</sup>

In the present case, the most likely explanation for development of the meningoencephalocele was the dural defect after removal of the meningioma. In humans, watertight closure of the dura after surgery is recommended as without closure and sealing the risk of infection and overall mortality is increased.<sup>21</sup>

Closure of the dura with fat, muscle flaps, muscle fascia, artificial materials and combinations of them are reported.<sup>22,23</sup> Various materials have also been used in dogs.<sup>24–27</sup> The need for dural sealing in veterinary patients remains controversial and has not been critically evaluated to date. Dural defects in dogs and cats have not been reported to be associated with significant increased risk of infection. The present case presents a

possible complication of failure to close a dural defect in a cat after craniotomy.

Surgical excision of meningoencephaloceles is recommended in humans because of CSF leakage and increased risk of meningitis.<sup>28,29</sup> The presented cat had no signs of CSF leakage or sinus infection. To our knowledge, no publication exists focusing on these risks in veterinary patients. Successful surgical treatment of congenital meningoencephalocele has been reported in a dog and a cat.<sup>30,31</sup> As the neurological deficits were not progressive at the time of diagnosis and the cat's neurological status remained unchanged subsequently surgical excision was not considered in the present case. The main limitation of this case report is the lack of pathology to exclude a regrowth of the meningioma and to confirm the assumption of a meningoencephalocele.

## Conclusions

Bilateral transfrontal craniotomy in cats allows access to the frontal cerebral cortex and, in this case, allowed removal of a meningioma. However, formation of post-operative meningoencephalocele may complicate the outcome and was likely the result of leaving a dural defect. The best technique to close dural defects remains to be established.

**Conflict of interest** The authors declared no potential conflicts of interest with respect to the research, authorship, and/or publication of this article.

**Funding** The authors received no financial support for the research, authorship, and/or publication of this article.

**Ethical approval** This work involved the use of non-experimental animals only (including owned or unowned animals and data from prospective or retrospective studies). Established internationally recognised high standards ('best practice') of individual veterinary clinical patient care were followed. Ethical approval from a committee was therefore not necessarily required.

**Informed consent** Informed consent (either verbal or written) was obtained from the owner or legal custodian of all animal(s) described in this work (either experimental or non-experimental animals) for the procedure(s) undertaken (either prospective or retrospective studies). No animals or humans are identifiable within this publication, and therefore additional informed consent for publication was not required.

**ORCID ID** Christian Günther  <https://orcid.org/0000-0001-8999-1223>

Katrin M Beckmann  <https://orcid.org/0000-0002-1823-7845>

## References

- 1 Troxel MT, Vite CH, Van Winkle TJ, et al. **Feline intracranial neoplasia: retrospective review of 160 cases (1985–2001).** *J Vet Intern Med* 2003; 17: 850–859.

- 2 Motta L, Mandara MT and Skerritt GC. **Canine and feline intracranial meningiomas: an updated review.** *Vet J* 2012; 192: 153–165.
- 3 Snyder JM, Shofer FS, Van Winkle TJ, et al. **Canine intracranial primary neoplasia: 173 cases (1986–2003).** *J Vet Intern Med* 2006; 20: 669–675.
- 4 Cameron S, Rishniw M, Miller AD, et al. **Characteristics and survival of 121 cats undergoing excision of intracranial meningiomas (1994–2011).** *Vet Surg* 2015; 44: 772–776.
- 5 Gordon LE, Thacher C, Matthiesen DT, et al. **Results of craniotomy for the treatment of cerebral meningioma in 42 cats.** *Vet Surg* 1994; 23: 94–100.
- 6 Körner M, Roos M, Meier VS, et al. **Radiation therapy for intracranial tumours in cats with neurological signs.** *J Feline Med Surg* 2019; 21: 765–771.
- 7 Forterre F, Fritsch G, Kaiser S, et al. **Surgical approach for tentorial meningiomas in cats: a review of six cases.** *J Feline Med Surg* 2006; 8: 227–233.
- 8 Forterre F, Jaggy A, Rohrbach H, et al. **Modified temporal approach for a rostro-temporal basal meningioma in a cat.** *J Feline Med Surg* 2009; 11: 510–513.
- 9 Kent M, Glass EN and Schachar J. **A lateral approach to the feline cerebellar fossa: case report and identification of an external landmark for the tentorium ossium.** *J Feline Med Surg* 2020; 22: 358–365.
- 10 Forterre F, Tomek A, Konar M, et al. **Multiple meningiomas: clinical, radiological, surgical, and pathological findings with outcome in four cats.** *J Feline Med Surg* 2007; 9: 36–43.
- 11 Forward AK, Volk HA and De Decker S. **Postoperative survival and early complications after intracranial surgery in dogs.** *Vet Surg* 2018; 47: 549–554.
- 12 Glass EN, Kapatkin A, Vite C, et al. **A modified bilateral transfrontal sinus approach to the canine frontal lobe and olfactory bulb: surgical technique and five cases.** *J Am Anim Hosp Assoc* 2000; 36: 43–50.
- 13 Kostolich M and Dulisch ML. **A surgical approach to the canine olfactory bulb for meningioma removal.** *Vet Surg* 1987; 16: 273–277.
- 14 Uriarte A, Moissonnier P, Thibaud JL, et al. **Surgical treatment and radiation therapy of frontal lobe meningiomas in 7 dogs.** *Can Vet J* 2011; 52: 748–752.
- 15 de Lahunta A, Glass EN and Kent M. **Veterinary neuroanatomy and clinical neurology.** 4th ed. St Louis, MO: Elsevier, 2015.
- 16 Raimondi F, Shihab N, Gutierrez-Quintana R, et al. **Magnetic resonance imaging findings in epileptic cats with a normal interictal neurological examination: 188 cases.** *Vet Rec* 2018; 180: 610.
- 17 Alonso RC, de la Peña MJ, Caicoya AG, et al. **Spontaneous skull base meningoencephaloceles and cerebrospinal fluid fistulas.** *Radiographics* 2013; 33: 553–570.
- 18 Honeybul S and Ho KM. **Decompressive craniectomy for severe traumatic brain injury: the relationship between surgical complications and the prediction of an unfavourable outcome.** *Injury* 2014; 45: 1332–1339.
- 19 Liang ES, Tipper G, Hunt L, et al. **Cranioplasty outcomes and associated complications: a single-centre observational study.** *Br J Neurosurg* 2016; 30: 122–127.
- 20 Coulter IC, Pesic-Smith JD, Cato-Addison WB, et al. **Routine but risky: a multi-centre analysis of the outcomes of cranioplasty in the northeast of England.** *Acta Neurochir (Wien)* 2014; 156: 1361–1368.
- 21 Daly DT, Lydiatt WM, Ogren FP, et al. **Extracranial approaches to the repair of cerebrospinal fluid rhinorrhea.** *Ear Nose Throat J* 1992; 71: 311–313.
- 22 Gök A, Erkutlu I, Alptekin M, et al. **Three-layer reconstruction with fascia lata and vascularized pericranium for anterior skull base defects.** *Acta Neurochir (Wien)* 2004; 146: 53–57.
- 23 Dafford EE and Anderson PA. **Comparison of dural repair techniques.** *Spine J* 2015; 15: 1099–1105.
- 24 Rosselli DD, Platt SR, Freeman C, et al. **Cranioplasty using titanium mesh after skull tumor resection in five dogs.** *Vet Surg* 2017; 46: 67–74.
- 25 Bordelon JT and Rochat MC. **Use of a titanium mesh for cranioplasty following radical rostrotentorial craniectomy to remove an ossifying fibroma in a dog.** *J Am Vet Med Assoc* 2007; 231: 1692–1695.
- 26 Sheahan DE and Gillian TD. **Reconstructive cranioplasty using a porcine small intestinal submucosal graft.** *J Small Anim Pract* 2008; 49: 257–259.
- 27 Mouatt JG. **Acrylic cranioplasty and axial pattern flap following calvarial and cerebral mass excision in a dog.** *Aust Vet J* 2002; 80: 211–215.
- 28 Schönauer C, Conrad M, Barbato R, et al. **Traumatic rupture into frontal sinus of a frontal intradiploic epidermoid cyst.** *Acta Neurochir (Wien)* 2002; 144: 401–402.
- 29 Gressot LV, Patel AJ, Kitagawa RS, et al. **Frontal sinus encephalocele: case report and review of literature.** *Clin Neurol Neurosurg* 2013; 115: 2174–2177.
- 30 Martlé VA, Caemaert J, Tshamala M, et al. **Surgical treatment of a canine intranasal meningoencephalocele.** *Vet Surg* 2009; 38: 515–519.
- 31 Dewey CW, Brewer DM, Cautela MA, et al. **Surgical treatment of a meningoencephalocele in a cat.** *Vet Surg* 2011; 40: 473–476.