



---

## **Feline infectious peritonitis virus-associated rhinitis in a cat**

Authors: André, Nicole M, Miller, Andrew D, and Whittaker, Gary R

Source: Journal of Feline Medicine and Surgery Open Reports, 6(1)

Published By: SAGE Publishing

URL: <https://doi.org/10.1177/2055116920930582>



# Feline infectious peritonitis virus-associated rhinitis in a cat

Nicole M André<sup>1</sup> , Andrew D Miller<sup>2</sup>  
and Gary R Whittaker<sup>1,3</sup>

*Journal of Feline Medicine and Surgery Open Reports*  
1–6

© The Author(s) 2020  
Article reuse guidelines:  
sagepub.com/journals-permissions  
DOI: 10.1177/2055116920930582  
journals.sagepub.com/home/jfmsopenreports

This paper was handled and processed  
by the American Editorial Office (AAFP)  
for publication in *JFMS Open Reports*



## Abstract

**Case summary** This report describes a cat with initial respiratory signs prior to developing fulminant feline infectious peritonitis (FIP) after adoption from an animal shelter. Histologic examination of the tissues revealed typical lesions associated with FIP in the lung, liver, large intestine and small intestine. Histologic examination of the nasal cavity revealed pyogranulomatous rhinitis. Immunohistochemistry with monoclonal antibody FIPV3-70 targeting FIP antigen in macrophages confirmed FIP and molecular analysis identified a spike protein mutation (R793S) consistent with the presence of an FIP virus. Pathological changes, immunolabeling and molecular analysis provide evidence that respiratory infection by feline coronavirus is part of the spectrum of FIP-associated disease.

**Relevance and novel information** This report highlights nasal pathology associated with FIP through a combination of histopathology, immunohistochemistry and molecular characterization of the virus. Our work supports a little-appreciated role of the respiratory tract in FIP.

**Keywords:** Feline infectious peritonitis; nasal cavity; rhinitis; feline coronavirus; spike protein

**Accepted:** 4 May 2020

## Introduction

Coronaviruses have been implicated in respiratory and gastrointestinal disease in many animal species.<sup>1</sup> In cats, feline coronavirus (FCoV) consists of two biotypes, commonly referred to as feline enteric coronavirus (FECV) and feline infectious peritonitis virus (FIPV).<sup>2,3</sup> FECV is generally considered to be associated with a mild, self-limiting gastrointestinal infection but can cause mild respiratory signs.<sup>4</sup> Initial infection with FCoV is thought to occur by oronasal exposure to the virus in fecal material or fecal-contaminated fomites.<sup>4</sup>

In some FCoV-infected cats, mutation of the viral genome leads to an alteration in the host cell tropism of FCoV from enterocytes to macrophages, leading to the systemic infection known as feline infectious peritonitis (FIP).<sup>2,3,5,6</sup> FIP is one of the most important infectious diseases affecting domestic and wild cat populations. There are multiple presentations of FIP: effusive (wet); non-effusive (dry); and a mixed form, which can include a combination of effusion and pyogranulomatous lesions.<sup>4,7</sup> Clinical signs can be variable in all presentations and comprise anorexia, pyrexia, lethargy,

diarrhea and weight loss.<sup>4,7,8</sup> Early studies suggested that upper respiratory infections characterized by conjunctivitis or rhinitis preceded the development of FIP.<sup>7,9,10</sup> although FCoV is not routinely considered a common respiratory pathogen in cats.<sup>4</sup>

This case report describes a cat with respiratory signs prior to developing systemic FIP. The pathological changes with marked FIPV immunolabeling supports previous work suggesting that respiratory infection is part of the spectrum of FIP-associated disease.

<sup>1</sup>Departments of Microbiology and Immunology, Cornell University College of Veterinary Medicine, Ithaca, NY, USA

<sup>2</sup>Biomedical Sciences, Section of Anatomic Pathology, Cornell University College of Veterinary Medicine, Ithaca, NY, USA

<sup>3</sup>Master of Public Health Program, Cornell University College of Veterinary Medicine, Ithaca, NY, USA

### Corresponding author:

Gary R Whittaker BSc, PhD, Department of Microbiology and Immunology, Cornell University College of Veterinary Medicine, 930 Campus Road, Ithaca, NY 14853, USA  
Email: grw7@cornell.edu



Creative Commons Non Commercial CC BY-NC: This article is distributed under the terms of the Creative Commons

Attribution-NonCommercial 4.0 License (<https://creativecommons.org/licenses/by-nc/4.0/>) which permits non-commercial use, reproduction and distribution of the work without further permission provided the original work is attributed as specified on the SAGE and Open Access pages (<https://us.sagepub.com/en-us/nam/open-access-at-sage>).

## Case description

An 8-week-old spayed female domestic shorthair cat was adopted from a shelter into a single-cat home. The cat received three feline viral rhinotracheitis, calicivirus and panleukopenia vaccinations, and was not vaccinated against rabies. The cat was previously dewormed and was feline leukemia virus negative. The diet consisted of a commercial dry and canned food.

At 10 weeks of age, the cat presented to the general practitioner (GP) for a wellness visit. On physical examination, a mild mucopurulent discharge was noted in both eyes, and the cat was sneezing. The remainder of the examination was normal. A fecal centrifugation was performed on formed feces and no ova or parasites were detected. Tobramycin eye drops were dispensed, and one drop was administered to both eyes every 12h for 10 days. In addition, lysine (Enisyl F) was dispensed and one pump was administered by mouth every 12h for 10 days. Fenbendazole suspension was administered orally at 0.6ml once daily for 5 days.

At 14 weeks of age, the cat was returned to the GP for evaluation of sneezing, diarrhea, a poor appetite and a distended abdomen. On physical examination, epaxial muscle loss was noted and the abdominal distension was confirmed. A fecal centrifugation was performed on soft feces, and no ova or parasites were detected. Metronidazole suspension was dispensed and 20mg was administered orally twice daily for 10 days and 25mg (0.4ml) of amoxicillin clavulanic acid 62.5mg/ml (Clavamox drops; Zoetis) was administered orally for 10 days.

The cat was returned to the GP 2 days later with hyporexia, polydipsia, lethargy and a reluctance to ambulate. A moderately distended abdomen was noted on physical examination. Cytological analysis of fluid obtained via abdominocentesis revealed a high protein non-septic exudate with mixed inflammation (Table 1). A complete blood count (CBC) and chemistry panel (Tables 2–6) were performed. The CBC with electronic differential revealed a slight anemia and neutrophilia (Table 2). The manual differential revealed abnormal red blood cell (RBC) and white blood cell (WBC)

**Table 1** Summary of the fluid analysis performed at 14 weeks of age

Fluid analysis	
Source of fluid	Abdominal fluid
Color of fluid	Light reddish-tan
Turbidity	Moderate
Viscosity	Slight
TNCC (Coulter)	16.2 ( $\times 10^3/\text{mm}^3$ )
Specific gravity	1.030
Total protein	5.8 (g/dl)

TNCC = total nucleated cell count

morphology (Tables 3–5). RBC evaluation revealed occasional poikilocytosis, anisocytosis, microcytosis and polychromasia, with Heinz bodies (Table 4). WBCs showed the following occasional changes in neutrophils: basophilic, vacuolated and foamy cytoplasm, swollen nucleus, indented nuclear margins and Döhle bodies (Table 5). The chemistry panel showed mild elevations in total protein and glucose, and moderate elevations of globulin and triglycerides. A decrease in alanine aminotransferase, alkaline phosphatase, creatine kinase and albumin were noted (Table 6). A tentative diagnosis of FIP was made based on clinical signs, fluid analysis and laboratory abnormalities. Prednisolone oral solution 3mg/ml was dispensed and 1.5mg (0.5ml) was administered twice daily.

At 15 weeks of age, the cat was returned to the GP for re-evaluation. An FCoV ELISA was performed and found to be positive at 1.228 ( $>1.20 = \text{positive}$ ,  $<0.90 = \text{negative}$ ). Lactated Ringer's fluids were administered 50ml subcutaneously (SC). Vitamin B12 injections were dispensed and 0.1ml was administered SC weekly. A week later, the cat was presented for an abdominocentesis prior to starting feline omega interferon. A total of 215ml of straw-colored viscous fluid was removed. The cat's appetite was decreased. Mirtazapine 7.5mg/ml suspension was dispensed and 1.88mg was administered (0.25ml) every 48–72h to increase appetite.

**Table 2** Summary of the complete blood counts – electronic differential performed at 14 weeks of age

	Electronic differential	RI
Hematocrit (%)	23.5	26.0–47.0
Hemoglobin (g/dl)	7.5	8.5–15.3
RBCs ( $\times 10^6/\mu\text{l}$ )	5.82	4.60–10.20
MCV (fl)	40.3	39.0–54.0
MCH (pg)	12.9	11.8–18.0
MCHC (g/dl)	32.1	29.0–36.0
RDW-CV (%)	18.1	16.0–23.0
Platelets ( $\times 10^3/\mu\text{l}$ )	237	100–518
MPV (fl)	13.4	9.9–16.3
WBCs ( $\times 10^3/\mu\text{l}$ )	16.45	5.50–19.50
Neutrophils ( $\times 10^3/\mu\text{l}$ )	13.52	3.12–12.58
Lymphocytes ( $\times 10^3/\mu\text{l}$ )	2.43	0.73–7.86
Monocytes ( $\times 10^3/\mu\text{l}$ )	0.28	0.07–1.36
Eosinophils ( $\times 10^3/\mu\text{l}$ )	0.21	0.06–1.93
Basophils ( $\times 10^3/\mu\text{l}$ )	0.01	0.00–0.12
Neutrophils (%)	82.2	38.0–80.0
Lymphocytes (%)	14.8	12.0–45.0
Monocytes (%)	1.7	1.0–8.0
Eosinophils (%)	1.2	1.0–11
Basophils (%)	0.1	0.0–1.2

RI = reference interval; RBCs = red blood cells; MCV = mean cell volume; MCHC = mean cell hemoglobin concentration; RDW-CV = red blood cell distribution width; MPV = mean platelet volume; WBCs = white blood cells

**Table 3** Summary of the complete blood count – manual differential performed at 14 weeks of age

	Manual differential	Reference interval
WBCs ( $\times 10^3/\mu\text{l}$ )	16.45	5.50–19.50
Plasma color from HCT	Trace lipemic	
Total plasma solids (g/dl)	7.4	6.0–7.5
PCV (spun HCT) (%)	23	24.0–45.0
Platelet estimate/HPF	Appears normal	6–36
Neutrophils	14642	2500–12,500
Bands	0	0–300
Transitional bands	0	0–1
Lymphocytes	987	1500–7000
Monocytes	0	0–800
Eosinophils	329	0–1500
Basophils	0	0–300
Atypical lymphocytes	0 lymphocytes with cleaved nucleus	0–1
Reactive lymphocytes	494 large lymphocytes with basophilic cytoplasm	0–1
Lymphoblasts	0	0–1
Metamyelocytes	0	0–1
Myelocytes	0	0–1
Other cells	0	0–1
NRBCs	0	0–2/100 WBCs

WBCs = white blood cells; HCT = hematocrit; PCV = packed cell volume; HPF = high-powered field; NRBCs = nucleated red blood cells

**Table 4** Red blood cell morphology – abnormal

Red blood cell morphology	
Size – anisocytosis	Occasional 1+
Size – microcytic	Occasional
Color – polychromasia	Rare
Shape – poikilocytosis	Occasional
Shape – Heinz bodies	Occasional

**Table 5** White blood cell (WBC) morphology – abnormal

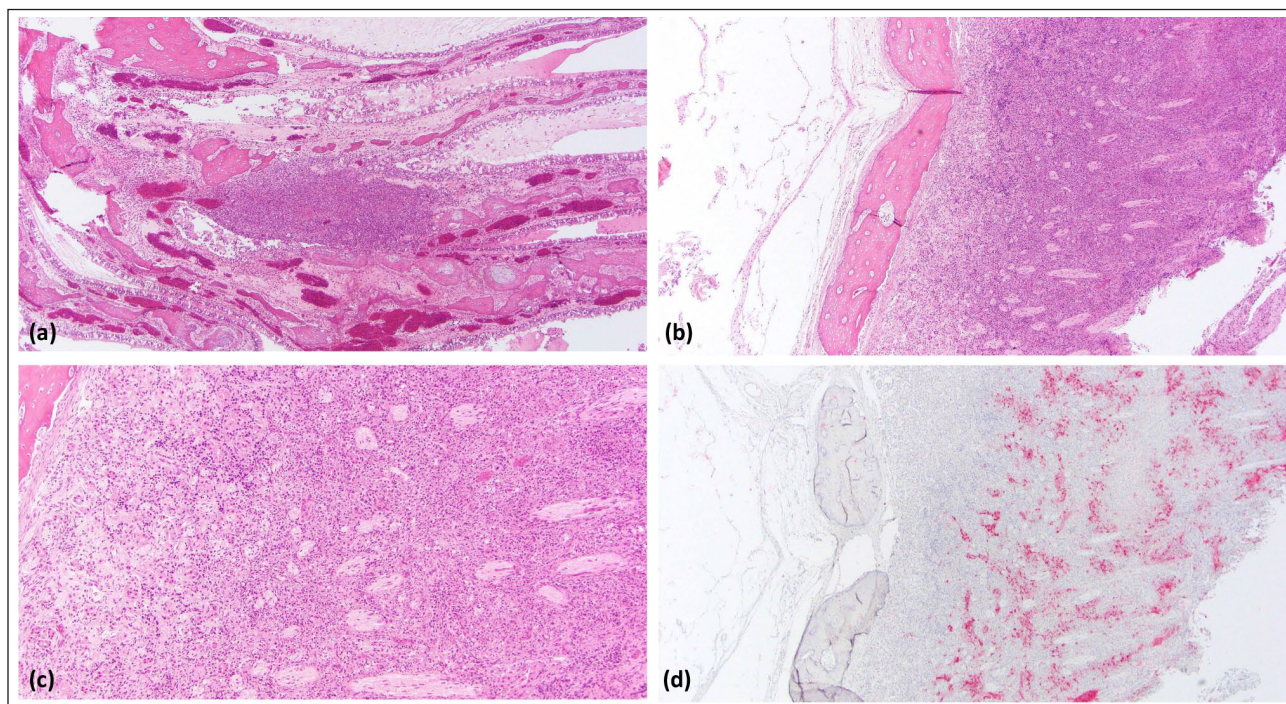
WBC morphology	
Basophilic cytoplasm	Occasional neutrophils
Döhle bodies	Occasional neutrophils
Foamy cytoplasm	Few neutrophils
Indistinct nuclear margins	Occasional neutrophils
Swollen nucleus	Few–moderate neutrophils
Vacuolated cytoplasm	Rare lymphocytes/ occasional neutrophils
Ruptured WBCs	Occasional–few

At 17 weeks of age, the patient was presented in respiratory distress and was laterally recumbent. Physical examination revealed an afebrile temperature of 99.4°F (37.4°C), heart rate of 140 beats per min, a respiratory rate of 42 breaths per min, pale mucous membranes and a capillary refill time of >2 s. The cat had a negative menace response and pupillary light response was present; it was

**Table 6** Summary of the chemistry profile performed at 14 weeks of age

Test	Result	Reference interval
Chloride (meg/l)	116	107–121
Sodium ( $\text{Na}^+$ ) (meg/l)	148	143–162
Potassium ( $\text{K}^+$ ) (meg/l)	4.5	
$\text{NA}^+:\text{K}^+$ ratio	32.8	
Carbon dioxide (mEg/l)	23.3	
Cholesterol (mg/dl)	118	63–132
Triglycerides (mg/dl)	68	15–49
ALT (U/l)	6	11–35
GGT (U/l)	4	
AST (U/l)	25	9–34
ALP (U/l)	18	39–124
Total bilirubin (mg/dl)	0.20	0.10–0.80
Creatine kinase (U/l)	102	185–894
Glucose (mg/dl)	117	59–102
Phosphorus (mg/dl)	7.9	6.9–9.5
Total protein (g/dl)	7.3	5.4–6.8
Albumin (g/dl)	1.7	2.5–3.6
Globulin (g/dl)	5.6	2.9–3.2
A:G ratio	0.3	
Calcium (mg/dl)	8.9	8.9–10.9
BUN (mg/dl)	24	19–34
Creatinine (mg/dl)	0.55	0.40–0.90
BUN:creatinine ratio	43.6	

ALT = alanine aminotransferase; GGT = gamma-glutamyl transferase; AST = aspartate aminotransferase; ALP = alkaline phosphatase; A:G = albumin:globulin; BUN = blood urea nitrogen



**Figure 1** Nasal histopathology. (a) Ethmoturbinates are replaced by extensive inflammation (low magnification). (b) The region of the cribriform plate is obscured by dense sheets of pyogranulomatous inflammation (low magnification). (c) High magnification illustrates the replacement of the cribriform plate by pyogranulomatous inflammation. (d) Feline infectious peritonitis immunohistochemistry reveals extensive immunolabeling in macrophages within the inflammation at the level of the cribriform plate (low magnification)

moderately dyspneic with normal bronchovesicular sounds, and slightly bradycardic with weak femoral pulses. The cat's abdomen was distended with a fluid wave. The clinical assessment was consistent with FIP. Owing to a poor prognosis the client elected euthanasia and necropsy was performed. No pleural effusion was present. A subset of tissues was fixed in 10% neutral buffered formalin, sectioned and stained with hematoxylin and eosin, and analyzed microscopically. Immunohistochemistry for the detection of FCoV was performed using monoclonal antibody FIPV 3-70 (1:1000; Custom Monoclonals), AP-Anti-Mouse IgG and Bond Polymer Refine Red Detection (Leica Microsystems). Positive controls consisted of FIPV-infected liver and a negative control was isotype matched.

Histologic examination revealed a diffuse pyogranulomatous rhinitis that partially obliterated the ethmoturbinates (Figure 1). Additional FIPV-associated lesions were found in lung, liver, large intestine, mesenteric lymph node and small intestine. No lesions were present in the brain or kidneys.

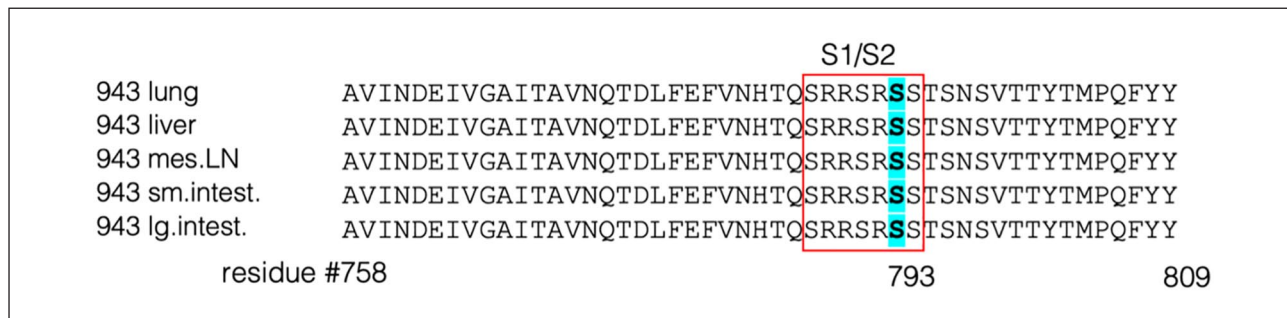
Respiratory samples were collected using two sterile flocked swabs from the conjunctiva, nasal cavity and the oropharynx. The samples were pooled and were sent to the Animal Health Diagnostic Center, Cornell University College of Veterinary Medicine, for the feline respiratory panel and the pooled sample was found to

be low positive for *Mycoplasma felis* (Table 7). All other respiratory agents screened in panel were negative within the pooled sample (Table 7).

PCR and Sanger sequencing were performed on a subset of tissues as described.<sup>11</sup> Briefly, 25 µl reverse transcription PCRs were performed with qScript XLT 1-Step RT PCR kit (Quantbio). PCR conditions were 20 mins at 50°C, 3 mins at 95°C and 40 cycles of 10s at 95°C, 20 s at 55°C, 40 s at 72°C and then 10 mins at 72°C.<sup>11</sup> Molecular analysis of the viral spike protein showed an amino acid change from an arginine to a serine (R-S) at

**Table 7** Summary of the respiratory panel performed at 14 weeks of age

Respiratory agent	Result	Methodology
<i>Bordetella</i> species	Not detected	PCR
<i>Chlamydia</i> species	Not detected	PCR
Influenza virus	Not detected	PCR
<i>Mycoplasma cynos</i>	Not detected	PCR
<i>Mycoplasma felis</i>	Low positive	PCR
Pneumovirus	Not detected	PCR
<i>Streptococcus zooepidemicus</i>	Not detected	PCR
Calicivirus	No virus isolated	Virus isolation
Herpesvirus	No virus isolated	Virus isolation



**Figure 2** Molecular analysis of the spike gene. A 156 base pair region of the feline coronavirus (FCoV) spike gene is shown and represented in single amino acid code, with variant residues and amino acid positions noted. The activation site between the S1 and S2 domains (S1/S2) is indicated and boxed amino acid positions are based on that for FCoV RM spike (Genbank accession # ACT10854.1) as a prototype sequence. Sequences were analyzed using Geneious Prime 2020.05

an essential P1 cleavage activation position at residue 793 (Figure 2).<sup>12</sup> This mutation was observed in all samples; that is, lung, liver, mesenteric lymph node, small intestine and large intestine.

### Discussion

This case report illustrates a cat with pathology in the nasal cavity with immunohistochemistry staining of macrophages associated with FIP. The cat was initially presented to the veterinarian for a wellness visit, where an upper respiratory tract infection was primarily observed and FIP was not considered a differential at the time. The respiratory signs resolved; however, clinical signs associated with FIP subsequently surfaced and ultimately caused the deterioration and euthanasia of the cat.

FIP has previously been observed in the nasal and oral cavities.<sup>9</sup> In a non-effusive case of FIP, small granulomas were observed on the frenulum of the tongue.<sup>9</sup> In an FIP case coinfecting with toxoplasmosis, histologic examination of the nasal submucosa showed a severe diffuse lymphoplasmacytic rhinitis with perivascular aggregations of neutrophils and macrophages, which immunohistochemistry revealed as FCoV antigen within macrophages.<sup>13</sup> In an experimental study, when the virus was aerosolized, lesions were frequently found in the nasal turbinates, lungs, pleura and tracheobronchial lymph nodes.<sup>14</sup>

The functionally relevant amino acid change (R793S) was found through the molecular analysis of the viral spike protein in all tissues in this cat (Figure 2). This mutation (R793S), an alteration from a charged to an uncharged amino acid, is predicted to eliminate the ability for furin to proteolytically process the S1/S2 cleavage activation site, which can ultimately affect viral entry.<sup>12</sup> FIP has been also associated with other mutations in the spike gene (1058)<sup>15</sup> and the 3c gene.<sup>16,17</sup> Additional sequencing of these regions is summarized in Table 8, and showed an M1058L conversion and truncated 3c, as expected.

**Table 8** Summary of the molecular analysis performed on the viral genome in various samples

	Spike S1/S2 sequence	Spike position 1058	3c gene
Brain	ND	ND	ND
Kidney	SRRSRSS	L	Truncated
Large intestine	SRRSRSS	L	Truncated
Liver	SRRSRSS	L	Truncated
Lung	SRRSRSS	L	Truncated
Mesenteric lymph node	SRRSRSS	L	Truncated

Individual sequences were premature stop codon and frameshift  
ND = not determined

The observations and findings in this case suggest that the respiratory system is a potential route of transmission for FCoV, given the significant rhinitis present in this young cat’s nasal cavity. Other coronaviruses, such as mouse hepatitis virus, infectious bronchitis virus in chickens and porcine respiratory coronavirus, transmit via the respiratory route prior to disseminating or targeting a specific organ system. The respiratory disease early in the course of disease in this cat may also be an early indicator of FIP. It is unlikely that an underlying immunodeficiency is the cause of the respiratory disease as it resolved and did not continue as other conditions developed. FCoV present in the nasal cavity may also suggest a role of significant hematogenous spread of the virus as the virus produces a vasculitis and the nasal cavity is extremely vascular.

Examination of the nasal cavities of FIP cats at necropsy could be performed to further support the region’s role in FIP. Currently, with the historical information, experimental studies and this case study, we confirm that the nasal cavity is involved in the pathogenesis of FIP; however, to further elucidate the precise mechanism, additional experiments are necessary. In addition,

continued molecular characterization in conjunction with histologic and immunohistochemical techniques in FIP pathogenesis is essential in order to uncover patterns between the virus and the disease to create methods to combat infections by earlier diagnosis in cats.

## Conclusions

This case report describes a kitten with FIP where the nasal cavity was extensively involved and respiratory signs were observed early on prior to clinical signs associated with FIP. A respiratory panel was performed on pooled respiratory swabs to exclude any common pathogens associated with feline respiratory disease complex (FRDC). While the swabs were low positive for *M felis*, no other FRDC pathogens were detected such as feline herpesvirus. While FIP is a systemic disease once it mutates, FCoV is not routinely thought of as a respiratory pathogen. This case suggests that the respiratory tract may be a mode of transmission for feline coronavirus.

**Acknowledgements** We thank Dr Alison Stout for clinical consultation and critical reading of the manuscript, the Section of Anatomic Pathology at the Animal Health Diagnostic Center for help with processing and training, Wendy Wingate for help with sample collection, and all the members of the Whittaker laboratory for helpful comments and support.

**Conflict of interest** The authors declared no potential conflicts of interest with respect to the research, authorship, and/or publication of this article.

**Funding** This work was funded by the Cornell Feline Health Center.

**Ethical approval** This work involved the use of non-experimental animals only (including owned or unowned animals and data from prospective or retrospective studies). Established internationally recognised high standards ('best practice') of individual veterinary clinical patient care were followed. Ethical approval from a committee was therefore not necessarily required.

**Informed consent** Informed consent (either verbal or written) was obtained from the owner or legal custodian of all animal(s) described in this work (either experimental or non-experimental animals) for the procedure(s) undertaken. No animals or humans are identifiable within this publication, and therefore additional informed consent for publication was not required.

**ORCID iD** Nicole M André  <https://orcid.org/0000-0002-3703-5026>

## References

- Whittaker GR. **Coronaviridae**. In: MacLachlan NJ and Dubovi EJ (eds). *Fenner's veterinary virology*. 5th ed. Cambridge, MA: Academic Press, 2016, pp 435–461.
- Addie D. **Feline coronavirus infections**. In: Greene CE (ed). *Infectious diseases of the dog and cat*. 4th ed. St Louis, MO: Elsevier Saunders, 2012, pp 92–108.
- Pedersen NC. **An update on feline infectious peritonitis: diagnostics and therapeutics**. *Vet J* 2014; 201: 133–141.
- Sykes JE. **Feline coronavirus infection**. In: Sykes JE (ed). *Canine and feline infectious diseases*, 2014, pp 195–208.
- Kipar A and Meli ML. **Feline infectious peritonitis: still an enigma?** *Vet Pathol* 2014; 51: 505–526.
- Felten S and Hartmann K. **Diagnosis of feline infectious peritonitis: a review of the current literature**. *Viruses* 2019; 11: E1068. DOI: 10.3390/v11111068.
- Barlough JE and Stoddart CA. **Feline coronaviral infections**. In: Greene CE (ed). *Infectious disease of the dog and cat*. Philadelphia, PA: W.B. Saunders Company, 1990, pp 300–312.
- Timoney J, Gillespie JH, Scott F, et al. *Hagan and Brunner's microbiology and infectious diseases of domestic animals*. 8th ed. New York: Cornell University Press, 1988, pp 886–893.
- Pedersen NC. **Coronavirus diseases (coronavirus enteritis, feline infectious peritonitis)**. In: Holtzworth J (ed). *Diseases of the cat medicine and surgery*. Philadelphia, PA: WB Saunders Company, 1987, pp 193–214.
- Hok K. **Development of clinical signs and occurrence of FCoV antigen in naturally infected barrier reared**. *Acta Vet Scand* 1993; 34: 345–356.
- André NM, Cossic B, Davies E, et al. **Distinct mutation in the feline coronavirus spike protein cleavage activation site in a cat with feline infectious peritonitis-associated meningoencephalomyelitis**. *JFMS Open Rep* 2019; 5. DOI: 10.1177/2055116919856103.
- Licitra BN, Millet JK, Regan AD, et al. **Mutation in spike protein cleavage site and pathogenesis of feline coronavirus**. *Emerg Infect Dis* 2013; 19: 1066–1073.
- Lingard AE, O'Brien C, Barrs VR, et al. **Concurrent feline infectious peritonitis and toxoplasmosis in three cases**. *Aust Vet Pract* 2010; 40: 9–16.
- Weiss RC and Scott FW. **Pathogenesis of feline infectious peritonitis: pathologic changes and immunofluorescence**. *Am J Vet Res* 1981; 42: 2036–2048.
- Chang HW, Egberink HF, Halpin R, et al. **Spike protein fusion peptide and feline coronavirus virulence**. *Emerg Infect Dis* 2012; 18: 1089–1095.
- Chang HW, de Groot RJ, Egberink HF, et al. **Feline infectious peritonitis: insights into feline coronavirus pathobiogenesis and epidemiology based on genetic analysis of the viral 3c gene**. *J Gen Virol* 2010; 91: 415–420.
- Pedersen NC, Liu H, Dodd KA, et al. **Significance of coronavirus mutants in feces and diseased tissues of cats suffering from feline infectious peritonitis**. *Viruses* 2009; 1: 166–184.