



---

## **Clinical and histological recovery of non-thymoma-associated exfoliative dermatitis in a cat treated with ciclosporin A**

Authors: Combarros, Daniel, Moulin, Jean-Paul, Correge, Sophie, Delverdier, Maxence, and Cadiergues, Marie-Christine

Source: Journal of Feline Medicine and Surgery Open Reports, 6(1)

Published By: SAGE Publishing

URL: <https://doi.org/10.1177/2055116920902307>



# Clinical and histological recovery of non-thymoma-associated exfoliative dermatitis in a cat treated with ciclosporin A

*Journal of Feline Medicine and Surgery Open Reports*  
1–5

© The Author(s) 2020

Article reuse guidelines:

sagepub.com/journals-permissions

DOI: 10.1177/2055116920902307

journals.sagepub.com/home/jfmsopenreports

This paper was handled and processed by the European Editorial Office (ISFM) for publication in JFMS Open Reports



Daniel Combarros<sup>1</sup>, Jean-Paul Moulin<sup>2</sup>, Sophie Corgege<sup>2</sup>, Maxence Delverdier<sup>3</sup> and Marie-Christine Cadiergues<sup>1</sup>

## Abstract

**Case summary** A 6-year-old neutered female European Shorthair cat was referred for chronic, moderately pruritic, alopecic and exfoliative dermatosis that was unresponsive to antiparasitic, antibiotic or steroidal anti-inflammatory drugs. The cat presented with truncular alopecia and numerous whitish adherent scales covering the whole body. Differential diagnoses included sebaceous adenitis, dermatophytosis, demodicosis, exfoliative dermatitis associated or not with thymoma, drug reaction, feline immunodeficiency virus- or feline leukaemia virus-associated dermatoses, epitheliotropic T-cell lymphoma, and *Malassezia* yeasts and/or bacterial overgrowth. Blood tests were within normal limits and the retrovirus tests were negative. Skin scrapings, fungal culture, coat brushing and skin cytology were negative for parasitic or microbial elements. Radiographs showed no signs of a thymic mass. Histological examination of skin biopsies revealed marked orthokeratotic hyperkeratosis, lymphocytic (CD3<sup>+</sup>) interface dermatitis and mural folliculitis with absence of sebaceous glands and occasional apoptotic cells in different epidermal layers. Clinical and histological findings were consistent with non-thymoma-associated exfoliative dermatitis syndrome. Ciclosporin A (7 mg/kg) was administered once daily. A dramatic improvement was observed after 3 weeks. Ciclosporin A intake was then progressively spaced out as the clinical signs diminished. Skin biopsies revealed resolution of hyperkeratosis, disappearance of the inflammatory infiltrate and recovery of the sebaceous glands.

**Relevance and novel information** T-cell infiltration with signs of epidermal cytotoxicity, in the absence of infectious agents or neoplastic process, suggests an immune-mediated process, and ciclosporin A, a calcineurin inhibitor, would be the drug of choice. This is the first report showing resolution of both the clinical and histological signs of non-thymoma-associated exfoliative dermatitis.

**Keywords:** Exfoliative dermatitis; sebaceous adenitis; ciclosporin A; histology; recovery

**Accepted:** 6 January 2020

## Introduction

Infiltration and destruction of the sebaceous glands by inflammatory cells (sebaceous adenitis) in cats, unlike dogs, is usually associated with other histological elementary lesions such as interface dermatitis, mural folliculitis or pan-epidermal keratinocyte apoptosis.<sup>1,2</sup> Clinical expression comprises severe exfoliation, scaling and crusting with variable levels of pruritus.<sup>3,4</sup> These clinical and histological signs have, in some cases, been associated with thymoma,<sup>3,5,6</sup> but not consistently. Because this histological syndrome shares some features with cutaneous lupus erythematosus or erythema multiforme,

<sup>1</sup>Department of Clinical Sciences, Université de Toulouse, ENVT, Toulouse, France; UDEAR, Université de Toulouse, INSERM, ENVT, Toulouse, France

<sup>2</sup>Veterinary Clinic, Saint-Céré, France

<sup>3</sup>Department of Basic Sciences, Université de Toulouse, ENVT, Toulouse, France; IHAP, Université de Toulouse, INRA, ENVT, Toulouse, France

### Corresponding author:

Marie-Christine Cadiergues DrMedVet, PhD, DipECVD, Department of Clinical Sciences, Université de Toulouse, ENVT, Toulouse, France; UDEAR, Université de Toulouse, INSERM, ENVT, 23 chemin des Capelles, Toulouse cedex 3, 31076, France  
Email: mc.cadiergues@envt.fr



Creative Commons Non Commercial CC BY-NC: This article is distributed under the terms of the Creative Commons

Attribution-NonCommercial 4.0 License (<https://creativecommons.org/licenses/by-nc/4.0/>) which permits non-commercial use, reproduction and distribution of the work without further permission provided the original work is attributed as specified on the SAGE and Open Access pages (<https://us.sagepub.com/en-us/nam/open-access-at-sage>).

attempts to assign a specific name to the disease, in the absence of thymoma, have resulted in confusion, with authors describing similar cases as sebaceous adenitis,<sup>7,8</sup> lupus-like dermatitis,<sup>9</sup> drug reaction<sup>2</sup> or 'non-thymoma-associated exfoliative dermatitis'.<sup>4</sup> Although the pathogenesis of this disease (or these diseases) has not been elucidated, an immunopathological response to an undefined trigger is highly suspected.

Here, we report a case of cat that developed generalised dermatosis characterised by alopecia, scaling, comedones and follicular casts, with histological signs of sebaceous adenitis, interface lymphocytic dermatitis and mural interface folliculitis, which fully responded to ciclosporin A. Control biopsies performed a few months after treatment initiation revealed resolution of the initial signs.

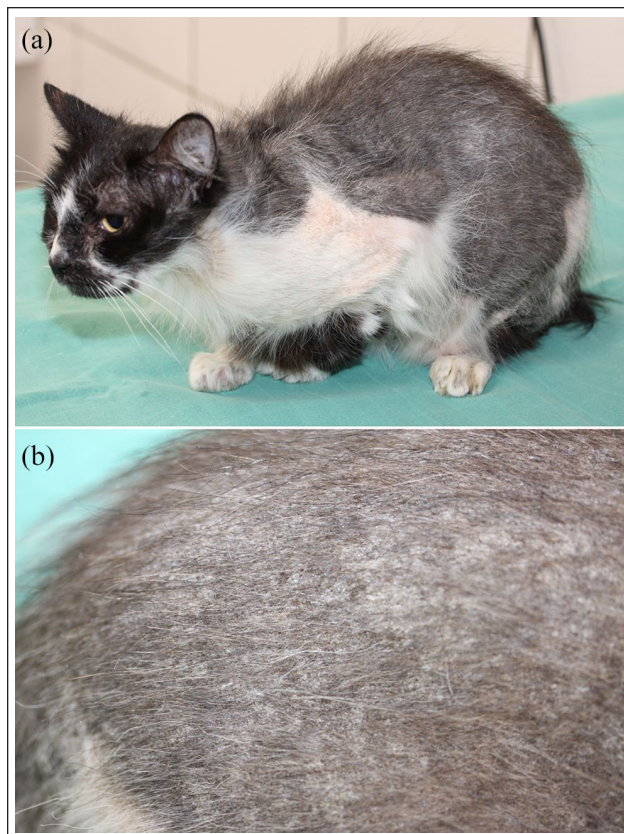
### Case description

A 6-year-old neutered female European Shorthair cat with free outdoor access and only casual contact with other pets was referred for a 1-year history of intermittent pruritus and fur loss. Prior to referral and because the cat's coat contained adult fleas, it had received a systemic ectoparasitic treatment (spinosad [Comfortis; Elanco]), which mildly improved the pruritus but not the alopecia. The cat had also received short courses (unknown dosage) of subcutaneous amoxicillin/clavulanic acid (Duphamox; Zoetis) and oral prednisolone (Dermipred, Boehringer Ingelheim) without any improvement. The cat was otherwise healthy and was fed a high-quality dry commercial feed.

Physical examination revealed no abnormalities other than dermatological signs. The cat presented with generalised alopecia with fur loss and broken hairs (Figure 1a). The entire skin was covered with small whitish adherent scales (Figure 1b), which were especially numerous on the face and muzzle. Follicular casts were observed on the caudal abdomen and extremities, and were associated with comedones on the ventral abdomen. The owners reported only mild licking which, after the dermatological examination, was not considered to be the sole cause of the alopecia.

The differential diagnoses included sebaceous adenitis, epitheliotropic T-cell lymphoma, dermatophytosis, demodicosis, exfoliative dermatitis associated or not with thymoma, drug reaction, feline immunodeficiency virus- or feline leukaemia virus-associated dermatosis, and *Malassezia* yeasts and/or bacterial overgrowth.

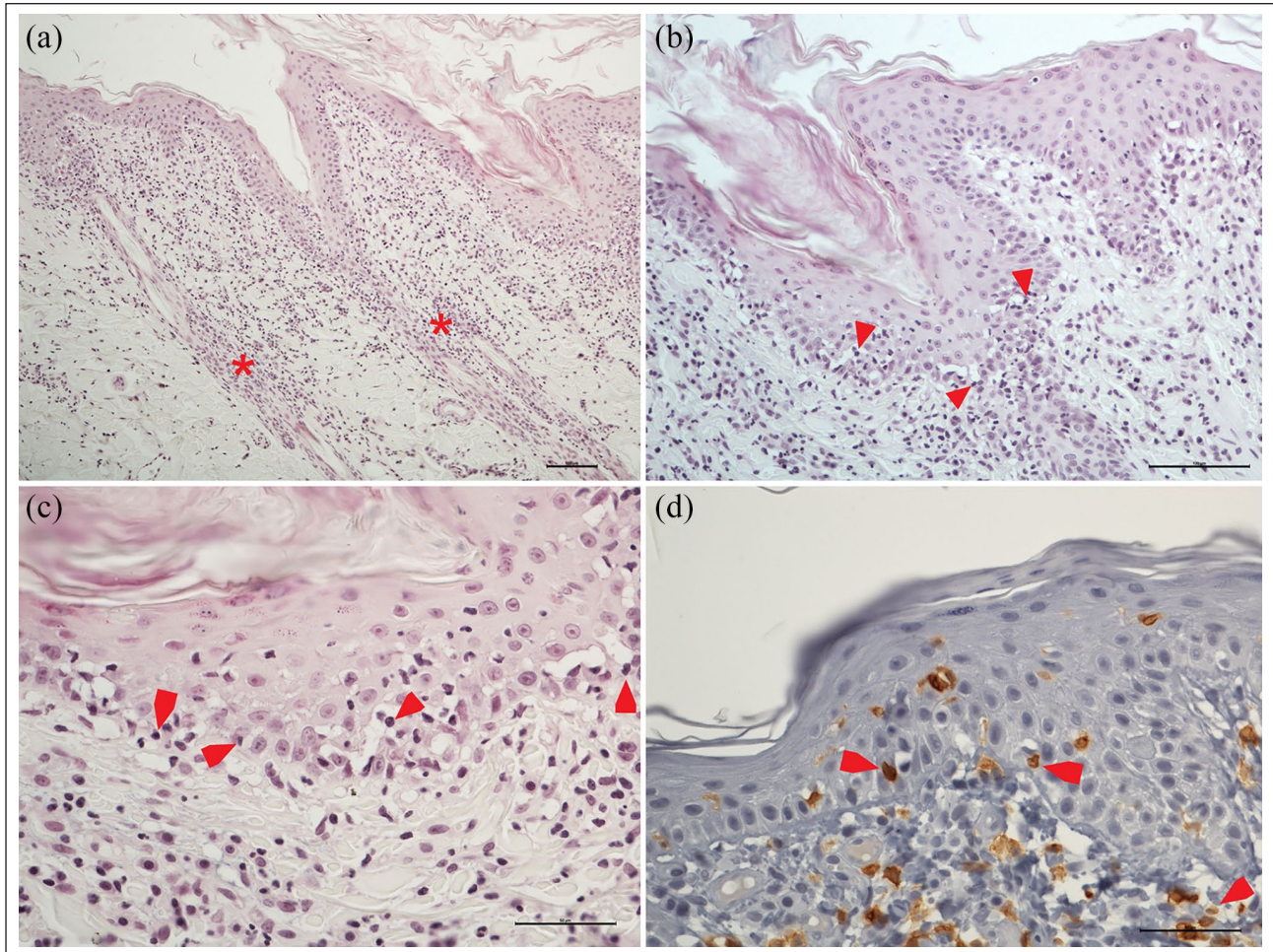
The complete biochemistry panel and blood count did not reveal any abnormalities, and the cat tested negative for both retroviruses. Trichograms, skin scrapings and brushing product examination and fungal culture were negative. Skin cytology using coloured tape stripping did not reveal any signs of microorganism overgrowth and thoracic radiographs did not show any evidence of thymus neoplasia.



**Figure 1** Initial physical examination: (a) generalised alopecia and scaling; and (b) close view of the dorsal skin showing abundant small adherent whitish scales

Multiple biopsies were obtained from the skin lesions under general anaesthesia for histological examination. Samples were processed, cut into 4µm sections and stained with haematoxylin and eosin following standard procedures. Histological examination revealed a diffusely acanthotic epidermis with orthokeratotic hyperkeratosis. A rich, mainly lymphocytic, infiltrate at the dermo-epidermal junction, including the follicular wall (Figure 2a), was observed. This infiltrate appeared to be more dense around the isthmus region of the hair follicles and was associated with hydropic degeneration of the basal keratinocytes (Figure 2b,c). No sebaceous glands were observed. Occasional apoptotic bodies were observed in the different epidermal layers. CD3 immunostaining revealed that the lymphocytes were mainly T-type cells (Figure 2d).

The cat was treated with ciclosporin A (CsA) at a dosage of 6.75 mg/kg every 24h (Atopica 25mg, one capsule per day; Elanco). A marked improvement was observed 3 weeks after beginning the treatment. The pruritus had ceased, the adherent scales had disappeared and fur regrowth was evident. CsA administration was reduced to 2/3 days at the same dosage (2 days on, 1 day off). Five weeks later, the cat was still improving and presented a thick coat with no follicular



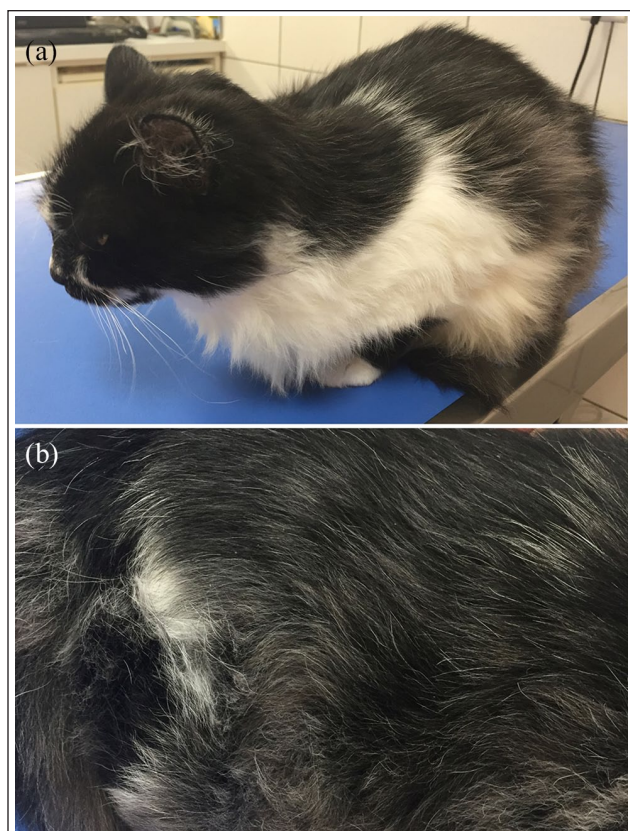
**Figure 2** Histopathological examination of biopsies taken from the flank. (a) Lymphocytic cell-rich interface dermatitis extending to the follicular wall (mural folliculitis) and lymphocytic exocytosis. No sebaceous glands, and only an inflammatory infiltrate in the isthmal region (\*), are observed. Note the diffuse irregular acanthosis (haematoxylin and eosin staining, magnification  $\times 100$ , bar = 100  $\mu\text{m}$ ). (b,c) Hydroptic degeneration of the basal cell layer of the epidermis with lymphocytic satellitosis (arrows) (haematoxylin and eosin staining, magnifications  $\times 200$  and  $\times 400$ , bars = 100  $\mu\text{m}$  and 50  $\mu\text{m}$ ). (d) Confirmation of the T-type cell nature of the cytotoxic lymphocytes (arrows) (CD3 immunostaining,  $\times 400$ , bar = 50  $\mu\text{m}$ )

casts or comedones. The only region that remained mildly alopecic was the dorsal aspect of the tail base at the level of the supracaudal gland. CsA administration was reduced to once every 2 days and then to twice a week, 1 month later (Figure 3). Four months after the initial consultation, the owner reported a very good general condition and normal skin aspect. However, close dermatological examination revealed the presence of some follicular casts, comedones and scales on the back. Administration was increased to once every 2 days, again with remission of the dermatological signs. Three months later, the cat was anaesthetised for unrelated reasons, and skin biopsies were taken from a previously affected skin region. Histological examination showed resolution of the hyperkeratosis and only very mild focal perivascular lymphoplasmacytic dermatitis (Figure 4a). Sebaceous glands were present and

presented no signs of inflammatory infiltrate (Figure 4b). Haematology and biochemistry blood panel were performed 6 and 24 months after starting CsA treatment and were within normal limits.

## Discussion

The clinical and histological pictures, taken together, were suggestive of an exfoliative dermatitis syndrome possibly associated with a thymoma. Although no evidence of thymoma was apparent on the chest radiography, this imaging method cannot completely rule out the presence of small neoplastic foci. Abdominal ultrasonography was not performed, so the presence of other neoplasms associated with alopecic paraneoplastic diseases cannot be excluded.<sup>10</sup> However, the absence of any general signs of illness despite the long course of the disease (1 year prior to referral and 24 months follow-up) and

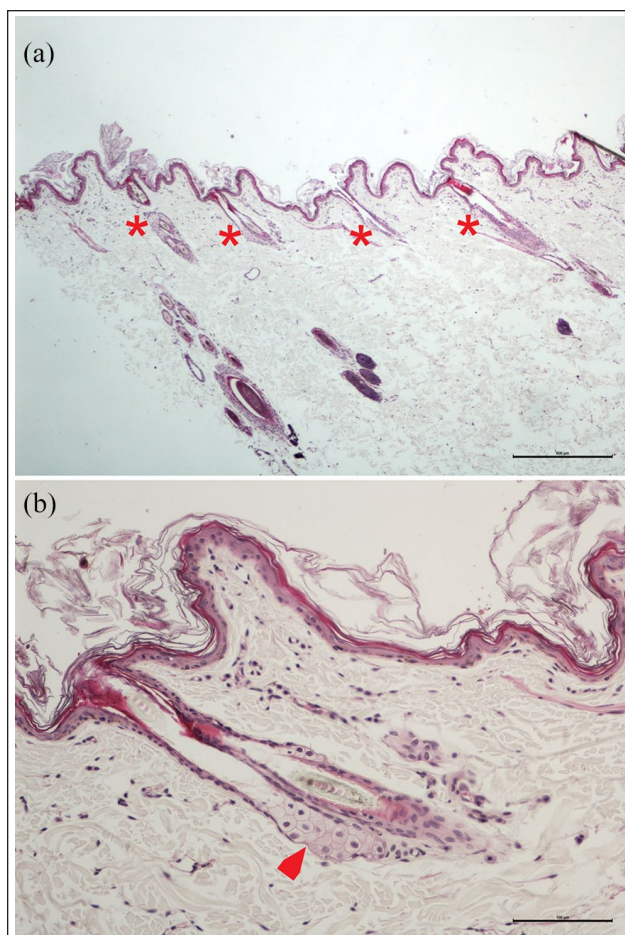


**Figure 3** Clinical presentation after 3 months of treatment with ciclosporin A: (a) clinical resolution, hair regrowth; and (b) close view of the dorsal skin showing absence of scaling

the extremely good response to immunomodulation make the paraneoplastic hypothesis less likely. As no underlying aetiology could be identified, the diagnosis could be suggestive of 'non-thymoma-associated exfoliative dermatitis syndrome'.

Similar histological findings in two other cats were associated with cutaneous lupus erythematosus.<sup>9</sup> However, in addition to exfoliative dermatitis these animals had erosive-ulcerative lesions on the nose and trunk. Such lesions were not observed in the present case. However, a drug reaction could not be definitively ruled out in our case because the cat periodically received external and internal antiparasitic treatments (spinosad, milbemycin oxime, praziquantel) and was correctly vaccinated once a year. Nevertheless, this hypothesis seems unlikely because clinical remission was achieved, even though these treatments were never stopped. Finally, a spontaneous resolution at the time of CsA treatment initiation, as reported previously,<sup>11</sup> would seem highly unlikely in view of the long clinical course of the disease and the worsening and improvement of the condition following tapering and increasing the dosage of CsA.

The histological lesions with T-cell infiltration indicative of epidermal cytotoxicity (basal cell degeneration,



**Figure 4** Histological findings on follow-up skin biopsies after treatment with ciclosporin A. (a,b) Disappearance of the interface inflammatory infiltrate and resolution of the epidermal acanthosis. Persistence of mild diffuse orthokeratotic hyperkeratosis. Presence of normal-looking sebaceous glands without any associated signs of inflammation (asterisks and arrow). Haematoxylin and eosin staining, magnifications  $\times 40$  and  $\times 200$ , bars =  $500\mu\text{m}$  and  $100\mu\text{m}$ , respectively

apoptosis) would suggest an immune-mediated process and CsA, a calcineurin inhibitor, was considered as the drug of choice. CsA not only inhibits T-cell activation, but also affects several cell types in the skin, impairing the ability of dendritic cells to stimulate T-cell proliferation, decreasing the number and activity of Langerhans cells in the epidermis, decreasing cytokine secretion by keratinocytes, and decreasing the functions of mast cells and eosinophils.<sup>12,13</sup> In this case, clinical improvement was observed from first control three weeks after starting CsA treatment. This supports the idea of this disease being cell mediated and not driven by humoral immunity, which is less affected by CsA treatment and would take longer to improve.<sup>14</sup> CsA is used to treat idiopathic sebaceous adenitis in the dog,<sup>15</sup> because it increases the number of sebaceous glands per hair follicle and reduces perifollicular

inflammation.<sup>15,16</sup> A good response was obtained when CsA was used in cats with signs similar to those described here.<sup>3,17</sup> Based on our personal experience, we elected to decrease the dose more slowly (from once daily to 2 days out of 3 and then to every other day) than usually recommended.<sup>14</sup> Finally, to the best of our knowledge, the histological features of control biopsies from cats suffering from non-thymoma-associated exfoliative dermatitis treated with CsA have not been reported before.

## Conclusions

CsA may be useful as a treatment option for non-thymoma-associated exfoliative dermatitis allowing resolution of both clinical and histological signs of the disease.

**Author note** This case report was presented in poster format at the South European Veterinary Congress held in Seville (Spain), 7–9 November 2019.

**Acknowledgements** The authors are very grateful to the owners of the cat for their continuing collaboration. They thank Diana Warwick for English editing.

**Conflict of interest** The authors declared no potential conflicts of interest with respect to the research, authorship, and/or publication of this article.

**Funding** The authors received no financial support for the research, authorship, and/or publication of this article.

**Ethical approval** This work involved the use of non-experimental animals only (owned or unowned), and followed established internationally recognised high standards ('best practice') of individual veterinary clinical patient care. Ethical approval from a committee was not necessarily required.

**Informed consent** Informed consent (either verbal or written) was obtained from the owner or legal custodian of all animal(s) described in this work for the procedure(s) undertaken. For any animals or humans individually identifiable within this publication, informed consent for their use in the publication (verbal or written) was obtained from the people involved.

**ORCID iD** Marie-Christine Cadiergues  <https://orcid.org/0000-0001-6909-0153>

## References

- 1 Miller WH Jr, Griffin CE and Campbell KL. **Parasitic skin disease.** In: Mosby E (ed.). *Muller and Kirk's small animal dermatology.* 7th ed. St Louis, MO: Saunders, 2012, pp 284–342.
- 2 Gross T, Ihrke P, Walder E, et al. *Skin diseases of the dog and cat: clinical and histopathologic diagnosis.* 2nd ed. Oxford: Blackwell Science, 2005, p 944.
- 3 Cavalcanti JV, Moura MP and Monteiro FO. **Thymoma associated with exfoliative dermatitis in a cat.** *J Feline Med Surg* 2014; 16: 1020–1023.
- 4 Linek M, Rufenacht S, Brachelente C, et al. **Nonthymoma-associated exfoliative dermatitis in 18 cats.** *Vet Dermatol* 2015; 26: 40–45.
- 5 Forster-Van Hijfte MA, Curtis CF and White RN. **Resolution of exfoliative dermatitis and Malassezia pachydermatis overgrowth in a cat after surgical thymoma resection.** *J Small Anim Pract* 1997; 38: 451–454.
- 6 Gojska-Zygnier O, Karas-Tecza J, Lechowski R, et al. **Cutaneous paraneoplastic syndrome in a cat with thymoma.** *Tierarztl Prax Ausg K Kleintiere Heimtiere* 2013; 41: 255–259.
- 7 de Sepibus M, Buhler I, Hauser B, et al. **Feline idiopathic mural folliculitis with sebaceous adenitis [in German].** *Schweiz Arch Tierheilkd* 2004; 146: 89–91.
- 8 Glos K, von Bomhard W, Bettenay S, et al. **Sebaceous adenitis and mural folliculitis in a cat responsive to topical fatty acid supplementation.** *Vet Dermatol* 2016; 27. DOI: 10.1111/vde.12282.
- 9 Wilhelm S, Grest P and Favrot C. **Two cases of feline exfoliative dermatitis and folliculitis with histological features of cutaneous lupus erythematosus.** *Tierarztliche Prax Ausg K Kleintiere Heimtiere* 2005; 33: 364–369.
- 10 Pascal-Tenorio A, Olivry T, Gross TL, et al. **Paraneoplastic alopecia associated with internal malignancies in the cat.** *Vet Dermatol* 1997; 8: 47–52.
- 11 Marignac G, Barlerin L, Guillot J, et al. **A case of seasonal lymphocytic mural folliculitis with spontaneous resolution in a cat [abstract].** *Vet Dermatol* 2003; 14: 247.
- 12 Al-Daraji WI, Grant KR, Ryan K, et al. **Localization of calcineurin/NFAT in human skin and psoriasis and inhibition of calcineurin/NFAT activation in human keratinocytes by cyclosporin A.** *J Invest Dermatol* 2002; 118: 779–788.
- 13 Palmeiro BS. **Cyclosporine in veterinary dermatology.** *Vet Clin North Am Small Anim Pract* 2013; 43: 153–171.
- 14 Colombo S and Sartori R. **Ciclosporin and the cat: current understanding and review of clinical use.** *J Feline Med Surg* 2018; 20: 244–255.
- 15 Lortz J, Favrot C, Mecklenburg L, et al. **A multicentre placebo-controlled clinical trial on the efficacy of oral ciclosporin A in the treatment of canine idiopathic sebaceous adenitis in comparison with conventional topical treatment.** *Vet Dermatol* 2010; 21: 593–601.
- 16 Linek M, Boss C, Haemmerling R, et al. **Effects of cyclosporine A on clinical and histologic abnormalities in dogs with sebaceous adenitis.** *J Am Vet Med Assoc* 2005; 226: 59–64.
- 17 Noli C and Toma S. **Three cases of immune-mediated adnexal skin disease treated with cyclosporin.** *Vet Dermatol* 2006; 17: 85–92.