




Diagnosis of insulinoma in a Maine Coon cat

Authors: Gifford, Carol H, Morris, Anita P, Kenney, Kurt J, and Estep, J Scot

Source: Journal of Feline Medicine and Surgery Open Reports, 6(1)

Published By: SAGE Publishing

URL: <https://doi.org/10.1177/2055116919894782>



Diagnosis of insulinoma in a Maine Coon cat

Carol H Gifford¹ , Anita P Morris², Kurt J Kenney³ and J Scot Estep⁴

Journal of Feline Medicine and Surgery Open Reports

1–10

© The Author(s) 2020

Article reuse guidelines:

sagepub.com/journals-permissions

DOI: 10.1177/2055116919894782

journals.sagepub.com/home/jfmsopenreports

This paper was handled and processed

by the American Editorial Office (AAFP)

for publication in *JFMS Open Reports*



Abstract

Case summary A 9-year-old male neutered Maine Coon cat presented with a 6-month history of polyphagia and one recent episode of tremors and weakness. Blood work revealed profound hypoglycemia and results of a paired insulin glucose test were consistent with an insulinoma. Abdominal ultrasound revealed a solitary pancreatic mass, and results of a fine-needle aspirate (FNA) gave further support for the location of the neuroendocrine tumor. After unsuccessful medical management of the hypoglycemia, the mass was surgically removed. Immunohistochemistry confirmed that it was an insulinoma. At the time of writing, the patient had been in clinical remission for 9 months.

Relevance and novel information Feline insulinomas are rare and there is very little information on their behavior, clinical course and histologic characteristics. This is the first reported case of an insulinoma in a Maine Coon cat and the first to describe results of an ultrasound-guided FNA of the mass. In addition, the progression of disease, histopathology and immunohistochemistry results add to the currently minimal database for feline insulinomas.

Keywords: Insulinoma; ultrasound; hypoglycemia; polyphagia; seizures; soft tissue surgery

Accepted: 12 November 2019

Introduction

Insulinomas are functional neuroendocrine tumors. They are principally comprised of insulin-producing beta cells. The symptoms associated with insulinomas are attributable to the effects of inappropriate insulin production. Numerous reports of canine insulinomas exist with a wealth of data on the disease in this species.^{1–4} Conversely, these tumors are very rare in cats, with only six well-documented cases in the literature.^{5–10} In dogs, there is no sex predilection, medium-to-large breeds are overrepresented, and the age of diagnosis ranges from 5 to 12 years of age, with a mean age of 9 years.^{1–4,11} The six cats showed no sex predilection and there was an overrepresentation of the Siamese breed.^{5–10} In addition, the age range of 12–17 years, with a mean age at diagnosis of 14 years, is significantly older than that reported for dogs.^{5–10} Clinical signs in both cats and dogs are the result of direct effects of hypoglycemia, including weakness, seizures and visual problems, as well as effects from secondary catecholamine release, such as tremors and anxiety.^{1–3,5–11} Many diagnostic criteria, such as insulin: glucose ratios, glucagon tolerance

tests and fructosamine levels have been evaluated for accuracy in diagnosing insulinomas in dogs. However, none of these is sensitive or specific enough to be diagnostic.^{1–3} Paired blood glucose and insulin levels showing hypoglycemia with a normal-to-elevated insulin level are considered the most accurate criteria for preliminary diagnosis in dogs.^{2,4,11,12} Standard diagnostic criteria are not established for cats. Radiographic imaging is not rewarding, but pancreatic ultrasound is often successful at revealing masses.^{1,11,13} Definitive diagnosis of insulinomas requires histopathology with appropriate immunohistochemistry. Initial emergent treatment involves treatment for the hypoglycemia and associated

¹Riverside Veterinary Care and Dental Services, Rutland, VT, USA

²Animal Sound, Woodstock, VT, USA

³Animal Hospital of Hinesburg, Hinesburg, VT, USA

⁴Texas Veterinary Pathology, San Antonio, TX, USA

Corresponding author:

Carol H Gifford DVM, Riverside Veterinary Care and Dental Services, 159 River Street, Rutland, VT 05701, USA
Email: cgifford.dvm@gmail.com



Creative Commons Non Commercial CC BY-NC: This article is distributed under the terms of the Creative Commons

Attribution-NonCommercial 4.0 License (<http://www.creativecommons.org/licenses/by-nc/4.0/>) which permits non-commercial use, reproduction and distribution of the work without further permission provided the original work is attributed as specified on the SAGE and Open Access pages (<https://us.sagepub.com/en-us/nam/open-access-at-sage>).

neurologic symptoms.¹⁴ Once stabilized medical treatment with steroids and a number of other medications is often attempted in dogs.^{2,14–16} However, surgery is considered the most effective treatment and offers the only chance for remission. Multiple retrospective studies show that about 30% of dogs are alive 14 months after surgery.^{2,4,11} Many of these survivors have post operative recurrence of symptoms and are managed successfully with medical treatments for an extended period of time.^{2,11} All six cats underwent surgery, with 2/6 cats remaining in remission for more than 14 months.^{8–10}

Case description

A 9-year-old male neutered Maine Coon cat was presented on day 1 due to a 20 min episode of twitching and weakness 24 h before the visit. The owner had also noted polyphagia during the prior 6 months. On presentation, the cat was bright and alert with no abnormalities on physical examination. A comprehensive blood count (Procyte DX; IDEXX) and urinalysis (Vetlab UA; IDEXX) revealed no abnormalities. However, a blood chemistry profile (Catalyst DX; IDEXX) showed marked hypoglycemia at 21 mg/dl (reference interval [RI] 71–159 mg/dl) and mild hypokalemia at 3.1 mmol/l (RI 3.5–5.8 mmol/l). The cat was immediately given a highly palatable canned feline diet (a/d; Hills Science Diets), which it ate voraciously. Further discussion with the owner did not reveal any exposure to insulin, oral hypoglycemics or other substances that could contribute to severe hypoglycemia.

The cat was hospitalized for stabilization and further diagnostics. Radiographs of the thorax and abdomen (Y-325; Bennett) revealed no abnormalities, and a fast ultrasound scan of the abdomen (DUS 60; Edan) revealed no evidence of free fluid. Blood drawn at admission was sent to a diagnostic laboratory (IDEXX) for a paired insulin and glucose level.

Over the next 48 h the patient was managed for hypoglycemia with 0.4 mg/kg prednisolone (Prednistab; Lloyd) orally every 12 h and ad libitum feeding of the highly palatable diet. On day 1 intravenous (IV) 5% dextrose in water (Hospira) was given at a rate of 4 ml/kg/h whenever the blood glucose level dropped below 80 mg/dl (RI 71–159 mg/dl). It was discontinued whenever the blood glucose was greater than 180 mg/dl (RI 71–159 mg/dl). IV lactated ringers (Hospira) with 20 mEq potassium chloride (Hospira) was given at a rate of 4 ml/kg/h when the blood glucose was between 80 and 180 mg/dl (RI 71–159 mg/dl). Owing to its feisty attitude, the cat was also given 0.1 mg/kg butorphanol (Dolorex; Merck) IV on day 1. As shown in Figure 1, the blood sugar readings ranged from 30 mg/dl to 192 mg/dl (RI 71–159 mg/dl) on day 1. The IV fluids were discontinued on day 2 to determine if prednisolone and frequent feedings would maintain its blood sugar at an acceptable level. During most of day 2 the blood sugar remained fairly steady, with a range of 60–95 mg/dl (RI 71–159 mg/dl). One low blood glucose reading of 43 mg/dl (RI 71–159 mg/dl) occurred just prior to the

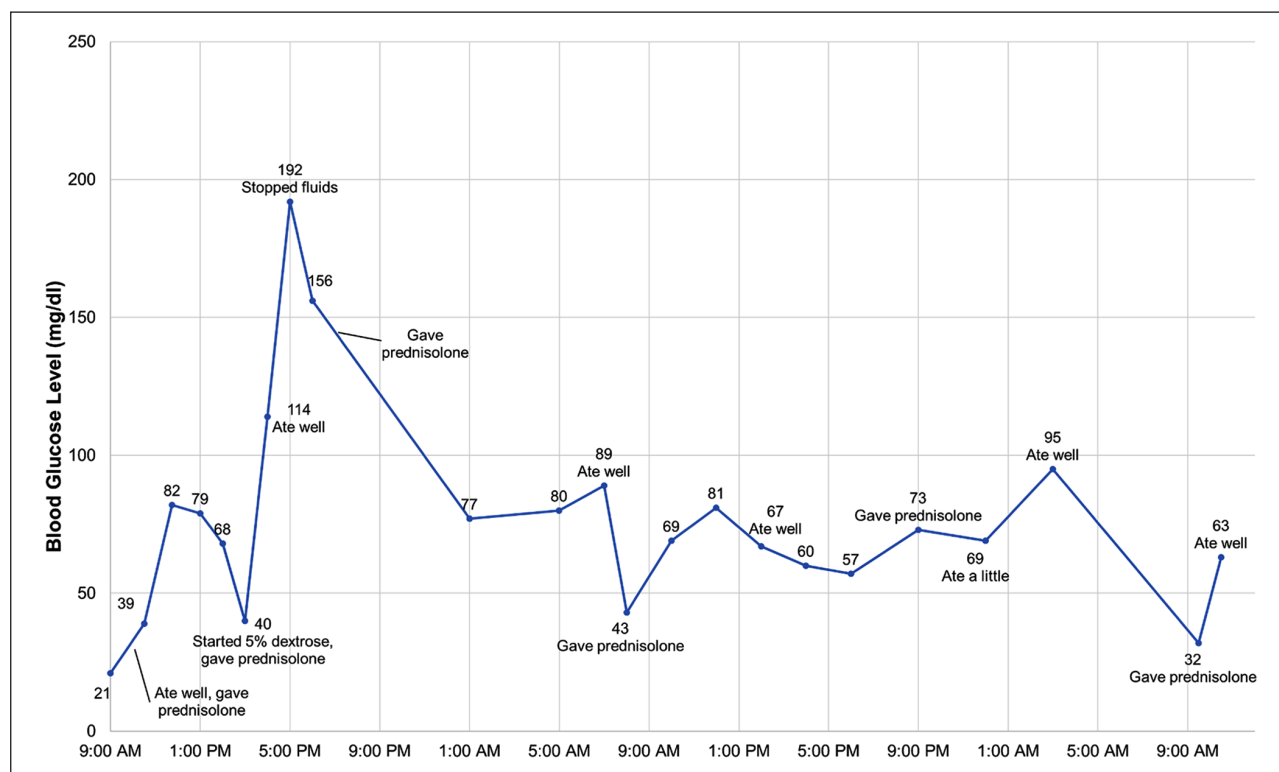


Figure 1 Blood glucose readings on days 1 and 2

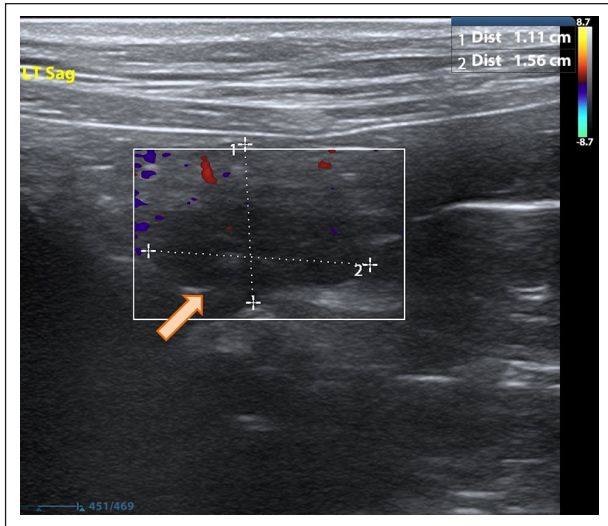


Figure 2 Abdominal ultrasound on day 6 showing hypoechoic pancreatic mass

cat's morning dose of prednisolone. The potassium level normalized on day 2 at 4.0 mmol/l (RI 3.5–5.8 mmol/l). During the entire hospitalization the patient exhibited no clinical signs of hypoglycemia and ate well. Therefore, it was elected to send the patient home on 0.4 mg/kg prednisolone every 12 h with frequent feedings.

On day 6, the cat returned for a comprehensive abdominal ultrasound (M9; Mindray). The owner reported that the cat was doing well with no further episodes of weakness. It was normal on physical examination and its blood glucose level at admission was 65 mg/dl (RI 71–159 mg/dl). The ultrasound revealed one 12 × 15 mm, well-vascularized and rounded hypoechoic structure in the left limb of the pancreas, as shown in Figure 2. The rest of the pancreas appeared heterogeneous and isoechoic to surrounding structures. The ultrasound also revealed mild multifocal gastrointestinal thickening in the duodenum with intact layering. Based on these findings, the owner elected to continue medical treatment pending results of the paired insulin glucose test.

On day 9, the paired glucose insulin test results were received and showed a severe hypoglycemia of 19 mg/dl (RI 71–159 mg/dl) with a normal insulin level of 15.6 units of insulin per milliliter (uIU/ml) (RI 10–81.3 uIU/ml). These results were relayed to the owner and the owner elected to continue medical treatment at that time as the patient was doing well. On day 17, the patient was dropped off for a glucose curve. The patient remained bright, alert and appetent during the visit. However, hourly glucose readings over the first 6 h of the visit remained very low, ranging from 35 to 43 mg/dl (RI 71–159 mg/dl). At that point a conversation with the owner revealed that multiple problems were occurring with the

current treatment. The patient was often difficult to medicate, and other pets in the house were often eating the cat's food. Strategies were discussed to help with these problems and the glucose curve was discontinued. The owner was also given a glucometer to monitor the cat's glucose levels at home.

Over the next 2 weeks the owner was unsuccessful at obtaining blood glucose readings from this temperamental patient and continued to struggle with the medication. At this point the owner agreed to a second ultrasound to reassess the staging and to obtain a fine-needle aspirate (FNA) of the pancreatic mass. In preparation for an ultrasound-guided aspirate of the pancreatic mass, a coagulation panel was done on day 33. This panel showed a normal platelet count (PC) of 118,000 K/ μ l (RI 155–641 K/ μ l), a normal prothrombin time (PT) of 9.9 s (RI 7.0–12.7 s) and normal partial thromoplastin time (PTT) of 27.3 s (RI 10.0–28.0 s). On day 34, the cat was admitted for a second ultrasound and sedated with 0.1 mg/kg butorphanol IV. The pancreatic mass appeared larger, measuring 12.1 × 19.9 mm (previous measurement on day 7 was 12.2 × 15.5 mm). The patient was then given 3.3 mg/kg tiletamine hydrochloride and zolazepam (Telazol; Dechra) IV. Ultrasound-guided FNA of the pancreatic mass was obtained with a 1.5 inch 22G hypodermic needle (Monoject; Covidien) on a 6 ml luer lock syringe (Monoject; Covidien). The slides were prepared with a squash preparation method and sent to a diagnostic laboratory (Texas Veterinary Pathology, TX, USA) for cytological evaluation. Following the procedure the cat was kept in the hospital for 24 h and monitored closely for signs related to hypoglycemia. During that time, its blood glucose ranged from 60 to 110 mg/dl (RI 71–159 mg/dl) and was clinically normal. The prednisolone and frequent feedings were continued while awaiting the results.

On day 69, results of the FNA were received. As shown in Figure 3, the slide contained clusters of epithelial cells with basophilic cytoplasm and naked nuclei. These findings are consistent with the type of glandular epithelial cells found in neuroendocrine tumors. The owner agreed to surgical excision of the mass.

On day 85, the patient was admitted for preoperative examination and diagnostic tests. The cat was normal on physical examination. A comprehensive blood count revealed a mild lymphopenia of 0.759 K/ μ l (RI 0.85–5.85 K/ μ l) and a mildly elevated albumin of 4.0 g/dl (RI 2.6–3.9 g/dl). The lymphopenia was most likely a response to stress and the mild hypoalbuminemia was considered to be an insignificant variant. Coagulation testing, including a PC, PT and PTT, were, again, within normal limits. A feline-specific lipase level was also carried out to provide a baseline in case postoperative pancreatitis was suspected. This lipase level was normal at 2.3 μ g/l (RI 0–3.5 μ g/l). Blood glucose readings every 2 h ranged from 67 to 114 mg/dl (RI 71–159 mg/dl) and the

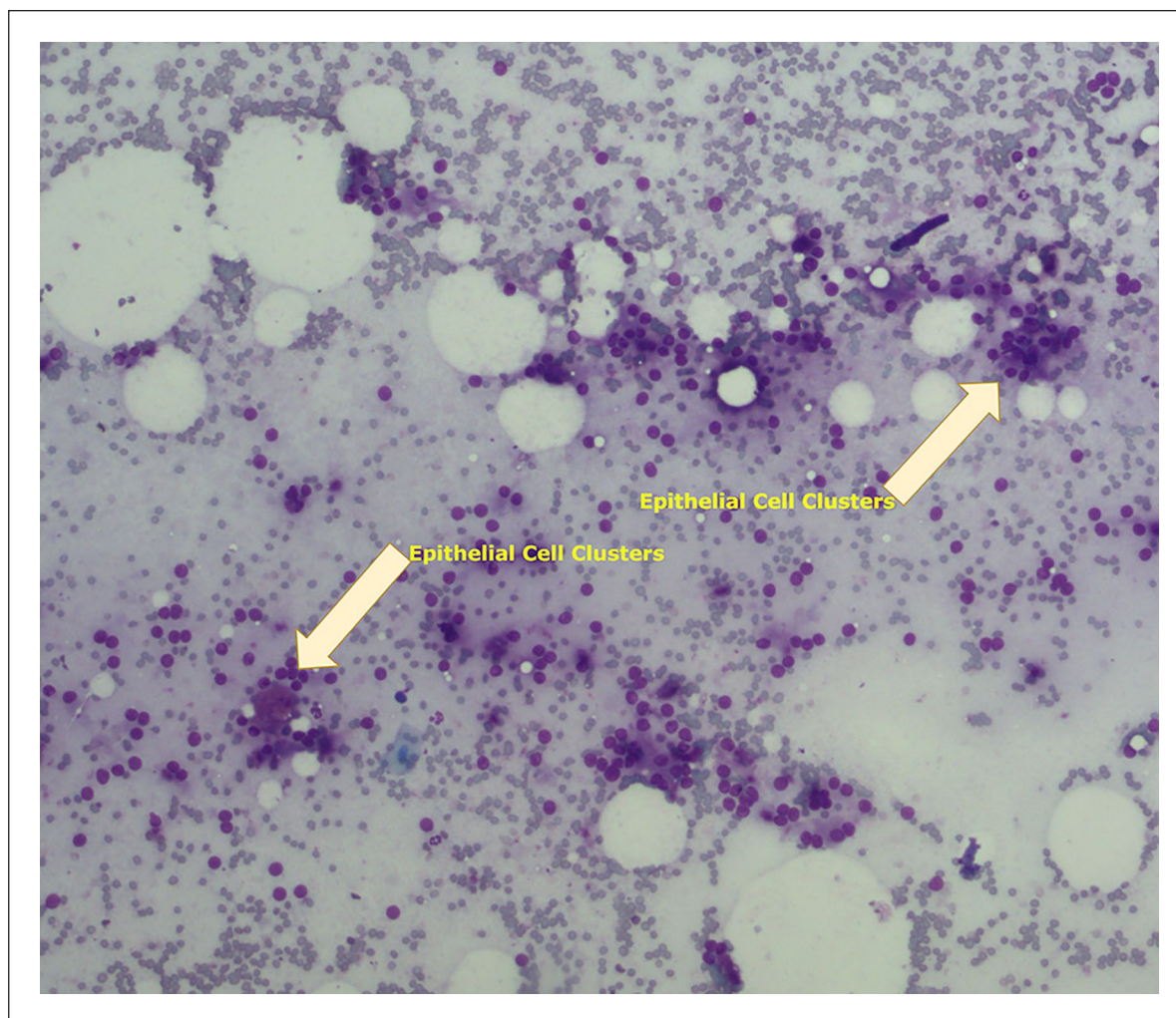


Figure 3 Cytology from a fine-needle aspirate of pancreatic mass showing clusters of epithelial cells with basophilic stippling and naked nuclei, consistent with a neuroendocrine tumor

patient was appetent and clinically normal throughout the day. It was given an evening meal and 0.4 mg/kg prednisolone.

Early on day 86 a blood sugar reading of 107 mg/dl (RI 71–159 mg/dl) was obtained and the patient was given a small meal. A dose of 14 mg/kg gabapentin (Time Cap Labs) was added to the meal as a sedative. One hour later the cat was given 1 mg/kg maropitant (Cerenia; Zoetis) subcutaneously as an antiemetic and to provide intraoperative and postoperative analgesia. One hour after that the patient was sedated with an intramuscular injection of 0.02 mg/kg hydromorphone (Hospira). Its blood sugar at the time of sedation was 71 mg/dl (RI 71–159 mg/dl). It was then given a combination of 0.2 mg/kg midazolam (Hospira) and 2.0 mg/kg ketamine (Ketaved, Vedco) IV. This was followed by 2.0 mg/kg alfaxalone (Alfaxan Multidose; Jurox) IV. It was intubated and isoflurane (Isothesia; Vet US) was used to maintain a surgical plane of anesthesia. Cefazolin

(Pfizer) at 22 mg/kg was also given IV before the surgical procedure. The patient was started on 9 ml/kg/h lactated ringers (Hospira) with plans to change to a dextrose solution if needed.

A midline incision from 3 cm caudal to the xiphoid process to the umbilicus was made with a laser scalpel (Aesculight 30W, CO₂ laser). Examination of the abdominal organs revealed no abnormalities aside from a solitary mass in the left limb of the pancreas, as shown in Figure 4. The fascia was opened with metzenbaum scissors and two mosquito forceps were clamped in a V shape around the mass to decrease hemorrhage. After 2 mins they were removed and the mass was excised with metzenbaum scissors. Minimal hemorrhaging at the site was controlled with one ligature of 3.0 polyglecaprone (Monocryl; Ethicon). The excised mass, shown in Figure 5, measured 1.8 cm in diameter. The abdomen and skin were closed in a routine manner and the patient recovered uneventfully from anesthesia.

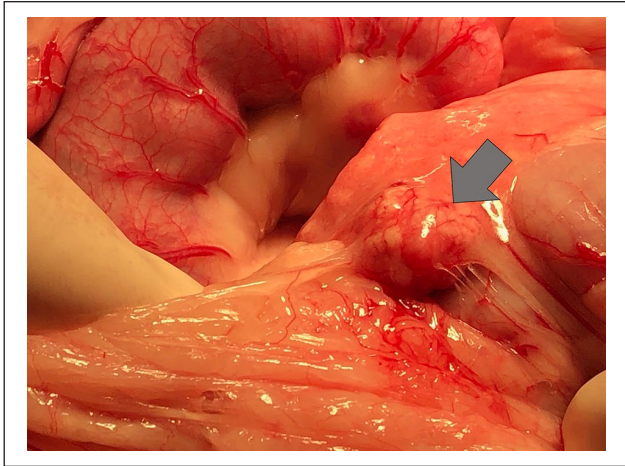


Figure 4 Intraoperative photograph of the pancreatic mass in the left limb of the pancreas

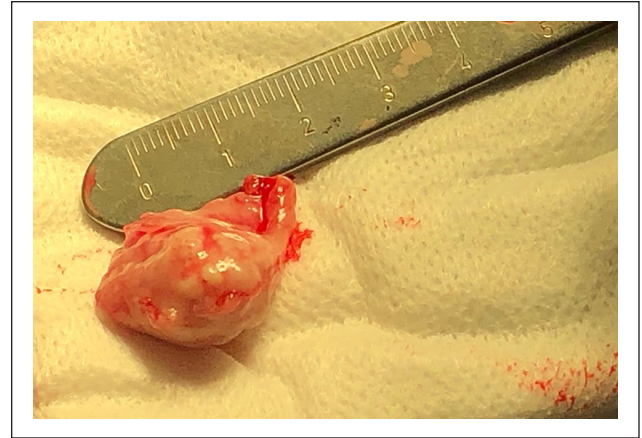


Figure 5 Pancreatic mass after excision

Blood sugar readings were done every 20 mins during surgery and hourly for 10h after the surgery, as shown in Figure 6. The patient was hospitalized overnight and frequent blood sugar readings continued. The cat's blood sugar levels were mildly elevated in the first few hours after surgery and then remained in the normal range for 24h after surgery. At discharge the patient was eating and was clinically normal. In a follow-up telephone call 3 days after discharge, the owner reported that the patient was eating well and appeared comfortable but

no longer had the voracious appetite exhibited before surgery. At a recheck examination on day 96, the cat was clinically normal and blood sugar readings every 2h over that day remained in the normal range.

Histological examination of the mass shown in Figure 7 illustrates the nesting pattern of epithelial cells consistent with a neuroendocrine neoplasm. The mass had completely replaced the involved lobule and exhibited a mitotic rate of three mitotic figures per high-powered field. Immunohistochemistry showed strong positive staining

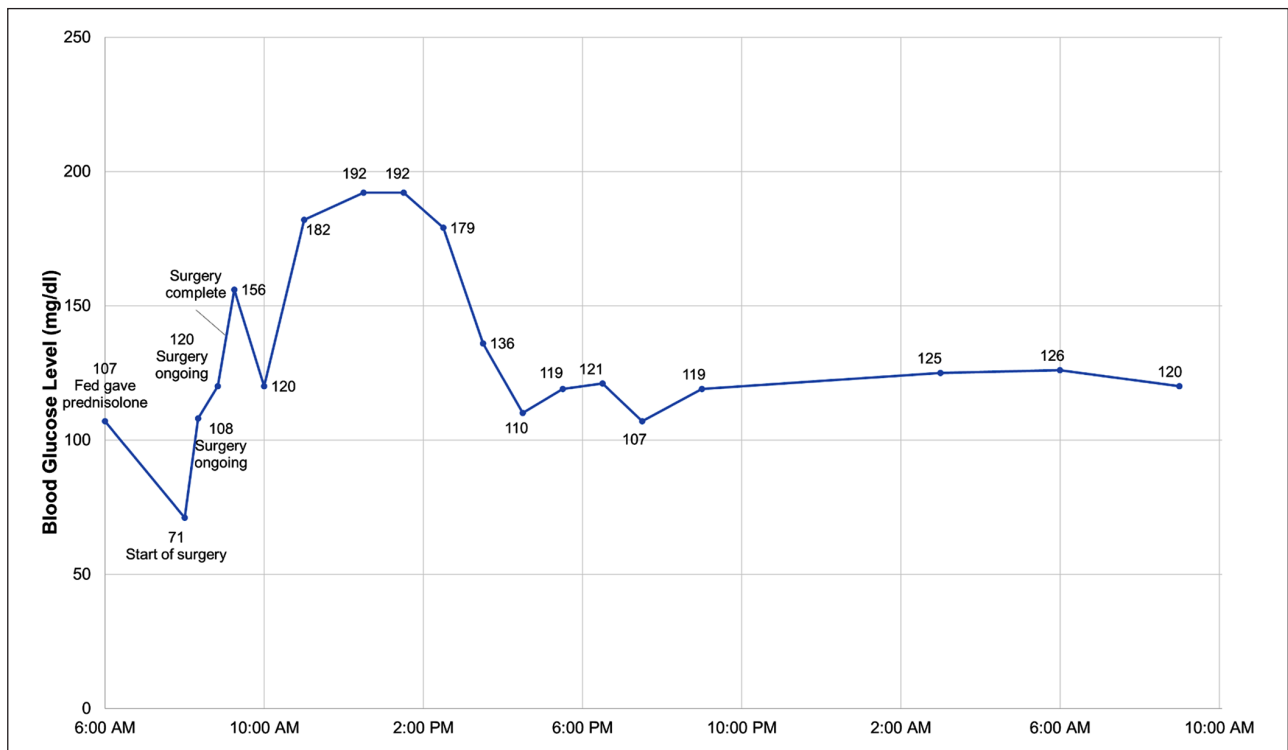


Figure 6 Preoperative and intraoperative blood glucose readings on days 86 and 87

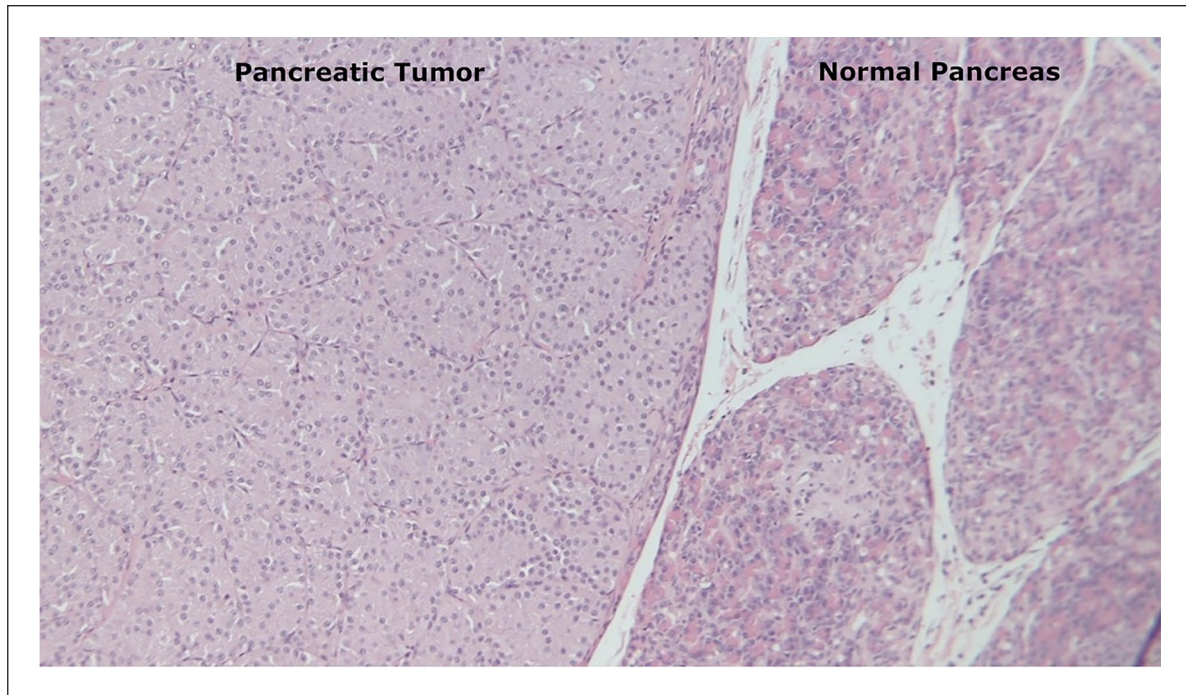


Figure 7 Histologic appearance of pancreatic mass showing multiple nests of epithelial cells with monomorphic round nuclei, indistinct cell borders and vacuolated cytoplasm adjacent to normal pancreatic tissue

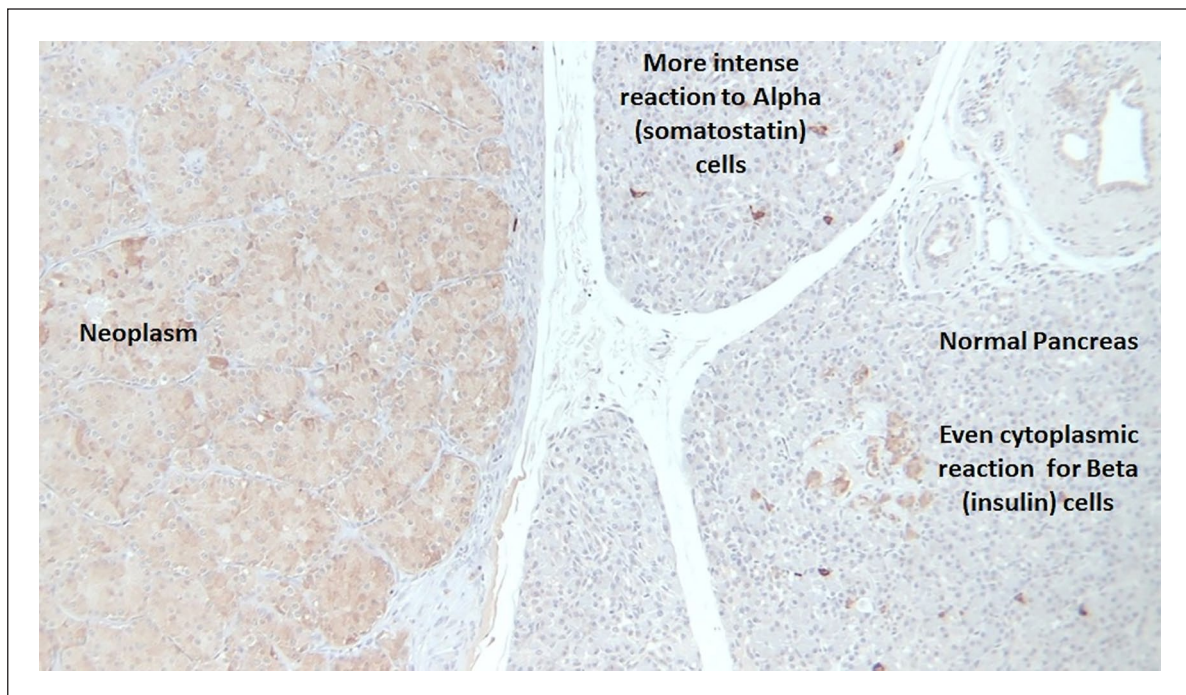


Figure 8 Pancreatic neoplasm and adjacent normal pancreas with immunohistochemical stain for the neuroendocrine marker chromogranin

for the neuroendocrine marker chromogranin A, as shown in Figure 8. There was also very strong staining for insulin,

as shown in Figure 9. Insignificant amounts of staining were obtained for gastrin and glucagon.

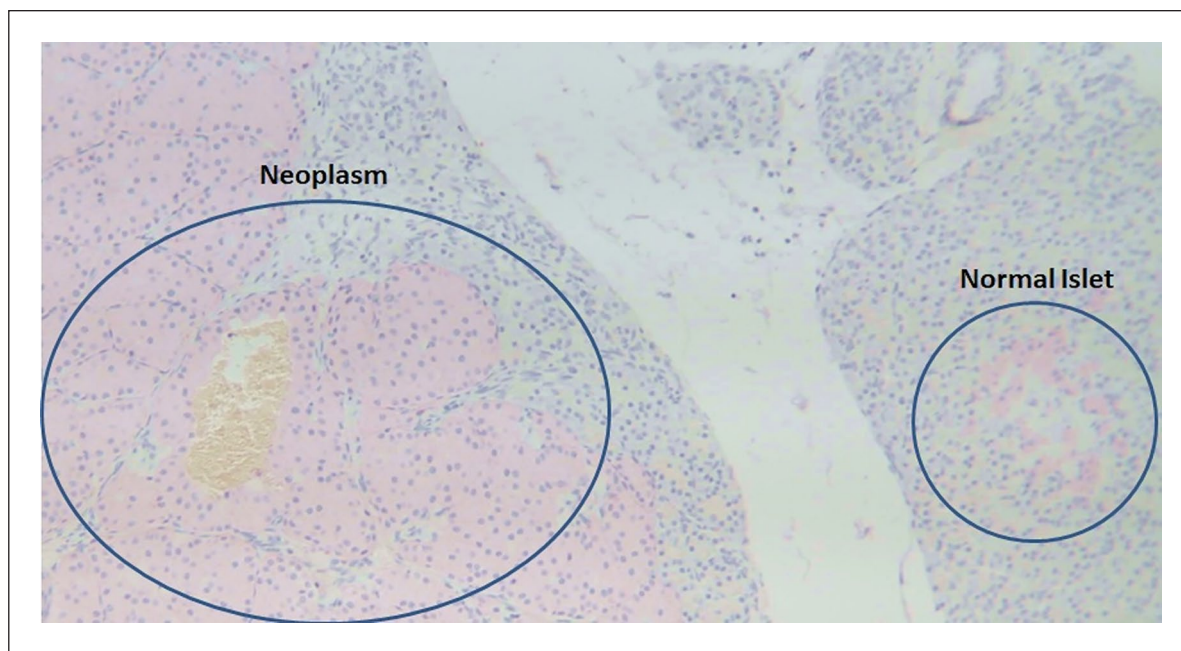


Figure 9 Pancreatic neoplasm and adjacent normal pancreas with immunohistochemical stain for insulin

Discussion

With so few documented cases of feline insulinoma it is difficult to say if the presentation and clinical course of this case is typical. This is the first Maine Coon cat and the fourth purebred cat with a documented insulinoma.^{5,6,10} Certainly, the initial presenting signs of tremors and weakness are clinical signs seen in dogs, but seizures are the most common presenting clinical sign in dogs.¹² Seizures were also the initial presenting sign in 4/6 prior feline cases, but were not seen in this patient.^{6–8,10} Polyphagia was a main clinical sign in this case, but it is not commonly reported in either dogs or cats.^{11–13} It is possible that the sedentary nature of this indoor cat's lifestyle, along with the owner's willingness to provide large amounts of food, allowed the cat to live with subclinical disease longer than the average dog or active cat.

Persistent hypoglycemia is the most consistent blood chemistry abnormality found in initial diagnostic testing and was present in this case. Diseases that cause increased glucose utilization, such as sepsis, seizures and some types of paraneoplastic syndrome, are important differential diagnoses, as well as diseases that cause decreased production of glucose, such as hepatic disease, neonatal hypoglycemia and hypoadrenocorticism. Non-islet cell tumors that produce factors with insulinomimetic effects are a rarely reported cause of feline hypoglycemia.¹⁷ Other causes of hypoglycemia, such as exogenous insulin overdose and ingestion of sulfonylureas, must also be considered. Xylitol toxicity is an important differential for hypoglycemia in the dog that has not been reported in cats.¹⁸ The hypokalemia seen in this patient is also

common and can be attributed to the high insulin levels causing intracellular movement of potassium.¹⁹ All of the six prior feline insulinomas were hypoglycemic. Only five cases reported insulin levels, and four of them had either normal or high insulin levels.^{5–8} One case had a low insulin level but that was attributed to laboratory error.⁹ In this case, the insulin level was inappropriately in the normal range at 15.6 uIU/ml (RI 10–81.3 uIU/ml) with profound hypoglycemia. This is considered diagnostic for an insulinoma.

Aggressively treating these cases with IV dextrose can cause further secretion of insulin and worsening of the hypoglycemic crisis.²⁰ Minimal use of parenteral glucose followed by glucocorticoids and frequent feedings is the most common initial treatment.^{3,6,7,10,14} This patient initially responded well to conservative treatment of frequent meals and steroids. Along with steroids and frequent feedings, several other medical treatments have been attempted in dogs. Diazoxide has been reported to have a good efficacy for hypoglycemic control, with a mean duration of 309 days in one study.^{2,11} Octreotide and streptozocin have also been tried, with limited success.^{11,15,16,21,22} None of these modalities has been well studied in cats.

Prior to the advent of advanced imaging, most canine patients were managed medically or with exploratory surgery. The earliest feline cases were treated with exploratory surgery and removal of the solitary pancreatic masses.^{5,10} Ultrasound is now a common diagnostic tool for insulinomas in dogs and was used in the other four feline cases.^{6–9} In all four cases, an abdominal

ultrasound successfully localized the pancreatic masses. Based on this information, ultrasound appears to be a specific test, but obviously more cases are needed to determine the sensitivity and specificity of abdominal ultrasound for feline insulinoma. The sensitivity of ultrasound in dogs is reported to range anywhere from 28% to 75%.^{23,24} Other modalities that are used include contrast-enhanced ultrasonography (CEU) and CT.²⁵ Some researchers advocate for triple-phase CT since studies have shown this to be the ideal phase for visualization of insulimomas varies.²⁵ Neither CEU or CT have been evaluated for diagnosis of feline insulinomas. Although there is some evidence that malignant insulinomas in dogs are more common in the right limb of the pancreas, they have been found in both limbs and at the angle of the pancreas.^{1,4,11} Interestingly, this case and four of the prior cases had masses located in the left limb of the pancreas.^{4,7-9} The gastrointestinal thickening with intact layering found in this cat was most consistent with mild chronic inflammation, although early neoplasia could not be ruled out. In the absence of gastrointestinal signs, it was elected not to pursue it further.

The cat in this study also underwent an ultrasound-guided FNA of the mass. It is important to emphasize that the results of the paired insulin and glucose levels were diagnostic, as previously mentioned, so this was not an absolutely necessary step. However, it did serve to confirm localization of the lesion to the very accessible

left limb of the pancreas. Additionally, FNA may have diagnostic significance in a case in which the insulin level is below the RI. A cat's small size makes this a simple procedure with minimal risk and one that can provide a diagnosis before surgery. Pancreatic FNA is a relatively safe procedure, with one recent study showing only a 1–2% incidence of hemorrhage.²⁶ Therefore, coagulation tests may not always be deemed necessary. As is typical of most insulinoma cases, this patient did not do well with medical management. Surgery was pursued with the hope of achieving remission.

Reported complications of insulinoma surgery in dogs include pancreatitis, persistent hypoglycemia, transient hyperglycemia, diabetes mellitus and endocrine pancreatic insufficiency.^{1,2,11} Postoperative complications occurred in four of the documented feline cases and included persistent hypoglycemia, transient diabetes mellitus, pancreatitis and postoperative neurologic signs.^{5,7,8,10} This information would seem to indicate a high risk of complications in cats with insulinoma surgery. The cat in this case did very well postoperatively, experiencing only mild transient hyperglycemia that resolved without treatment, as shown in Figure 6. Minimal gentle handling of the pancreas and a short surgery time likely contributed to an uncomplicated postoperative period. An antibiotic was given at the beginning of the surgery based on concern of a long or complicated procedure in this geriatric patient. In retrospect, the antibiotic

Table 1 Comparison of stage, anaplastic features and remission time

Case	Stage of disease*	Anaplastic features	Immunohistochemistry results	Postoperative outcome
McMillan et al ¹⁰	1	Invasive to adjacent tissue Rare MF/HPF	Negative for porcine insulin antisera	Seizures at 5 days, died at 4 weeks
O'Brien et al ⁵	1	Not invasive to adjacent tissue 2 MF/HPF	>50% insulin <10% somatostatin <10% human IAPP [†]	No monitoring Seizure recurrence at 7 months, euthanized at 2 years
Hawks et al ⁶	1	Partially encapsulated MF uncommon	Diffuse staining for insulin, neuron specific enolase, chromogranin A	Borderline blood glucose, recurrence at 10 months Euthanized at 18 months
Kraje ⁷	1	Not available	Diffuse staining for chromogranin A Patchy staining for insulin	Immediate neurologic complications Euthanized at 1 month
Greene and Bright ⁸	1	Minimally invasive Rare MF	Not available	No monitoring Clinically normal at 32 months
Schaub and Wigger ⁹	1	Epithelial-like cells in a string-like pattern	Highly positive for insulin	No monitoring Clinically normal at 18 months
Present case	1	Non-invasive 3 MF/HPF	>80% positive for chromogranin A >80% positive for insulin	Normal blood glucose curve at 6 months and clinically normal at 9 months post-surgery

*Staging: stage 1 = primary tumor only; stage 2 = primary plus regional lymph nodes; stage 3 = primary plus regional lymph nodes plus distant metastasis

[†]Human amyloid islet polypeptide

MF = mitotic figures; HPF = high-powered field; IAPP = islet amyloid polypeptide

was probably not necessary. Initially, postoperative analgesia with a continuous-rate infusion of hydromorphone was planned. However, the patient became aggressive after its preoperative dose of this opiate, so it was deemed inadvisable. Owing to the recent administration of steroids, a non-steroidal anti-inflammatory was contraindicated. It was elected to monitor it closely for signs of pain and treat these if needed. Based on monitoring of appetite, attitude, posture, respiratory rate and heart rate, the patient was judged to have minimal postoperative pain and no additional analgesia was given.

The histopathology from the excised mass provided more information on the nature of the neoplasm, including the non-invasive nature of the neoplasm and the high mitotic rate. However, immunohistochemistry was done to confirm that insulin-producing cells were present in the mass. Aside from insulin, some insulinomas in dogs have been shown to produce other neurohormones, including glucagon, somatostatin, pancreatic polypeptide and growth hormone.⁴ The earliest feline case reported a negative immunohistochemistry result for insulin.¹⁰ This negative result was attributed to the use of porcine antisera.¹⁰ The four other feline cases that reported histochemistry results showed a positive result for insulin.^{5-7,9} Three of these cases also reported a positive neuroendocrine marker. No other hormones showed significant activity in the feline insulinomas. One additional published study of the cellular and molecular characteristics of a feline insulinoma from an unidentified source showed significant levels of only a neuroendocrine marker and insulin.²⁷ The neoplasm in this study showed identical results with a strong positive result for a neuroendocrine marker and insulin.

In dogs, the anaplastic features that are typically used to determine malignancy for most neoplasms are not predictive for insulinomas.^{10,12,13} Several researchers have postulated that most canine insulinomas are malignant and that the clinical course depends on the duration of disease prior to surgery.^{1,11,12} There are too few data to determine if this is also true in felines. Table 1 shows the available information on stage of disease, anaplastic features and postoperative outcomes for the documented feline cases, as well as this case. Five of the cases provided information on anaplastic features.^{5,6,8-10} None of these cats had evidence of metastasis at the time of surgery and they all had fairly similar anaplastic features. However, three of the cases behaved malignantly with recurrence of clinical signs and two cases appear to have behaved benignly with no evidence of recurrence.⁵⁻¹⁰ This information indicates that anaplastic features may not be useful for predicting malignancy in felines. However, it is also important to note that the two cases with reportedly long remissions had no postoperative monitoring. More cases of feline insulinomas that

include long-term postoperative monitoring are needed to answer these questions and determine prognosis.

Table 1 also illustrates the lack of standardization and difficulty with comparing results for immunohistochemistry. All of the cases, aside from McMillan et al,¹⁰ showed positive results for insulin. However, aside from insulin, these cases did not run the same immunohistochemistry tests. Insulinomas in cats may not secrete significant amounts of glucagon, somatostatin or other neurohormones. However, more cases with a wider array of immuno-histochemistry tests are needed to determine this.

Conclusions

Feline insulinomas are most successfully treated with surgical excision, and surgery offers a significant chance for remission. Documentation of hypoglycemia occurring simultaneously with a high or normal insulin level is diagnostic. Abdominal ultrasound is a useful tool to stage and localize the disease. Staging and anaplastic features do not appear to accurately predict long-term prognosis. More data are needed to determine what factors are most predictive of long-term remission and survival in cats. Rapid diagnosis and excision of these tumors likely increases the likelihood of long-term remission.

Acknowledgements The authors thank Wesley Gifford for assistance with preparation of figures; Steve Hirsch for editing assistance; and Abigail Gifford MD and Daniel Gifford for technical assistance and encouragement. In addition, three esteemed Diplomates of the American Board of Veterinary Practitioners – Kimberlee Buck DVM, DABVP; Jeanie Spooner DVM, DABVP; and Beatriz Vivanco DVM, DABVP – gave invaluable inspiration and support.

Conflict of interest The authors declared no potential conflicts of interest with respect to the research, authorship, and/or publication of this article.

Funding The authors received no financial support for the research, authorship, and/or publication of this article.

Ethical approval This work involved the use of client-owned animal(s) only, and followed established internationally recognised high standards ('best practice') of individual veterinary clinical patient care. Ethical approval from a committee was not necessarily required.

Informed consent Informed consent (either verbal or written) was obtained from the owner or legal guardian of all animal(s) described in this work for the procedure(s) undertaken. For any animals or humans individually identifiable within this publication, informed consent for their use in the publication (verbal or written) was obtained from the people involved.

ORCID iD Carol H Gifford  <https://orcid.org/0000-0002-0369-7005>

References

- 1 Kruth A, Feldman E and Kennedy P. **Insulin-secreting islet cell tumors: establishing a diagnosis and the clinical course for 25 dogs.** *J Am Vet Med Assoc* 1982; 181: 54–58.
- 2 Leifer C, Peterson M and Matus R. **Insulin-secreting tumor: diagnosis and medical and surgical management in 55 dogs.** *J Am Vet Med Assoc* 1986; 188: 60–64.
- 3 Caywood D, Klausner J, O'Leary T, et al. **Pancreatic insulin-secreting neoplasms: clinical, diagnostic, and prognostic features in 73 dogs.** *J Am Anim Hosp Assoc* 1988; 5: 577–584.
- 4 Madarame H, Kayanuma H, Shida T, et al. **Retrospective study of canine insulinomas: eight cases (2005–2008).** *J Vet Med Sci* 2009; 71: 905–911.
- 5 O'Brien T, Norton F, Turner T, et al. **Pancreatic endocrine tumor in a cat: clinical, pathological, and immunohistochemical evaluation.** *J Am Vet Med Assoc* 1990; 26: 453–457.
- 6 Hawks D, Peterson M, Hawkins K, et al. **Insulin-secreting pancreatic (islet cell) carcinoma in a cat.** *J Vet Intern Med* 1992; 6: 193–196.
- 7 Kraje A. **Hypoglycemia and irreversible neurologic complications in a cat with insulinoma.** *J Am Vet Med Assoc* 2003; 223: 812–814.
- 8 Greene S and Bright R. **Insulinoma in a cat.** *J Small Anim Pract* 2008; 49: 38–40.
- 9 Schaub S and Wigger A. **Ultrasound-aided diagnosis of an insulinoma in a cat.** *Tierarztl Prax Ausg K Kleintiere Heimtiere* 2013; 41: 338–342.
- 10 McMillan F, Barr B and Feldman E. **Functional pancreatic islet cell tumor in a cat.** *J Am Anim Hosp Assoc* 1985; 21: 741–746.
- 11 Tobin R, Nelson R, Lucroy M, et al. **Outcome of surgical versus medical treatment of dogs with beta cell neoplasia: 39 cases (1990–1997).** *J Am Vet Med Assoc* 1999; 215: 226–230.
- 12 Goutal C, Brugmann B and Ryan K. **Insulinoma in dogs: a review.** *J Am Anim Hosp Assoc* 2012; 48: 151–163.
- 13 Fernandez N, Barton J and Spotswood T. **Hypoglycemia in a dog.** *Can Vet J* 2009; 50: 423–426.
- 14 Fischer J, Smith S and Harkin K. **Glucagon constant-rate infusion: a novel strategy for the management of hyperinsulinemic-hypoglycemic crisis in the dog.** *J Am Anim Hosp Assoc* 2000; 36: 27–32.
- 15 Moore A, Nelson R, Henry C, et al. **Streptozocin for treatment of pancreatic islet cell tumors in dogs: 17 cases (1989–1999).** *J Am Vet Med Assoc* 2002; 221: 811–818.
- 16 Northrup N, Rassnick K, Giege T, et al. **Prospective evaluation of biweekly streptozocin in 19 dogs with insulinoma.** *J Vet Intern Med* 2013; 27: 483–490.
- 17 Guillen A, Ressel L, Finotello R, et al. **Non-islet-cell tumour hypoglycaemia in a cat with hepatocellular carcinoma.** *JFMS Open Rep* 2019; 5. DOI:10.1177/2055116919856129.
- 18 Jerzsele A, Karancsi Z, Paszti E, et al. **Effects of p.o. administered xylitol in cats.** *J Vet Pharmacol Ther* 2018; 41: 409–414.
- 19 Guyton A and Hall J. **Insulin, glucagon and diabetes mellitus.** In: Guyton A and Hall J (eds). *Textbook of medical physiology*. 11th ed. Philadelphia, PA: Elsevier Saunders, 2006, pp 961–977.
- 20 Meleo K. **Management of insulinoma patients with refractory hypoglycemia.** *Probl Vet Med* 1990; 2: 602–609.
- 21 Robben J, van den Brom W, Mol J, et al. **Effect of octreotide on plasma concentrations of glucose, insulin, glucagon, growth hormone, and cortisol in healthy dogs and dogs with insulinoma.** *Res Vet Sci* 2006; 80: 25–32.
- 22 Simpson K, Stepien R, Elwood C, et al. **Evaluation of the long-acting somatostatin analogue octreotide in the management of insulinoma in three dogs.** *J Small Anim Pract* 1995; 36: 161–165.
- 23 Lamb C, Simpson K, Boswood A, et al. **Ultrasonography of pancreatic neoplasia in the dog: a retrospective review of 16 cases.** *Vet Rec* 1995; 137: 65–68.
- 24 Polton G, White R, Brearley M, et al. **Improved survival in a retrospective cohort of 28 dogs with insulinoma.** *J Small Anim Pract* 2007; 48: 151–156.
- 25 Fukushima K, Fujiwara R, Yamamoto K, et al. **Characterization of triple-phase computed tomography in dogs with pancreatic insulinoma.** *J Vet Med Sci* 2015; 77: 1549–1553.
- 26 Crain S, Sharkey L, Corder A, et al. **Safety of ultrasound-guided fine-needle aspiration of the feline pancreas: a case-control study.** *J Feline Med Surg* 2015; 17: 858–863.
- 27 Jackson T, Debey B, Lindbloom-Hawley S, et al. **Cellular and molecular characterization of a feline insulinoma.** *J Vet Intern Med* 2009; 23: 383–387.