



---

## **Apocrine gland anal sac adenocarcinoma with perineural metastasis in a cat**

Authors: Raleigh, Joseph S, Lanza, Matthew R, and Perry, James A

Source: Journal of Feline Medicine and Surgery Open Reports, 4(2)

Published By: SAGE Publishing

URL: <https://doi.org/10.1177/2055116918815323>



# Apocrine gland anal sac adenocarcinoma with perineural metastasis in a cat

Joseph S Raleigh<sup>1</sup>, Matthew R Lanza<sup>1</sup>  
and James A Perry<sup>2</sup>

*Journal of Feline Medicine and Surgery Open Reports*  
1–5

© The Author(s) 2018

Article reuse guidelines:

sagepub.com/journals-permissions

DOI: 10.1177/2055116918815323

journals.sagepub.com/home/jfmsopenreports

This paper was handled and processed  
by the American Editorial Office (AAFP)  
for publication in *JFMS Open Reports*



## Abstract

**Case summary** A 15-year-old female spayed domestic shorthair cat was presented for hyporexia and acute development of L4–Cd myelopathy (urinary incontinence, pelvic limb paresis with hyporeflexia and absent tail tone). Humane euthanasia was elected owing to the rapid neurological deterioration and necropsy was performed. Post-mortem examination identified a right-sided anal sac mass and medial iliac lymphadenopathy. No gross lesions were evident in the cauda equina or peripheral nerves. Histopathology and immunohistochemistry utilizing wide-spectrum cytokeratin confirmed apocrine gland carcinoma of the anal sac with lymph node, peripheral nerve and cauda equina metastasis.

**Relevance and novel information** This is the first report of feline anal sac adenocarcinoma metastasizing to perineural tissue. In addition, it provides a novel differential diagnosis for L4–Cd myelopathy and urinary incontinence in a cat.

**Keywords:** Apocrine gland anal sac adenocarcinoma; AGASACA; perineural metastasis; urinary incontinence; L4–Cd myelopathy

**Accepted:** 10 October 2018

## Introduction

Apocrine gland anal sac adenocarcinoma (AGASACA) is a malignant neoplasm arising from the secretory epithelium of the anal sac. While AGASACA in dogs represents 2% of all skin and subcutaneous tumors, it is exceedingly rare in cats.<sup>1,2</sup> Typical metastatic patterns in both species include spread to regional lymph nodes and, in advanced disease, other visceral organs and the lungs. This case describes a novel clinical presentation and metastatic pattern for feline AGASACA.

## Case description

A 15-year-old female spayed domestic shorthair cat was presented for evaluation of a 7 day history of hyporexia and inappropriate elimination outside of the litter box. No straining to defecate or urinate was reported. Historically, the cats had cystoliths successfully managed with dietary modification and, at the time of presentation, was being treated with itraconazole for dermatophytosis.

On physical examination, the cat showed signs of discomfort upon abdominal palpation. The bladder was approximately 4 cm × 3 cm and the cat leaked urine when lifted. A focal region of erythema lateral to the right anal gland was identified. There was no palpable mass, and a rectal examination was not performed. On neurological examination, the cat was ambulatory with mild paraparesis and a crouched

<sup>1</sup>University of Pennsylvania, School of Veterinary Medicine, Philadelphia, PA, USA

<sup>2</sup>Department of Clinical Sciences and Advanced Medicine, University of Pennsylvania, School of Veterinary Medicine, Philadelphia, PA, USA

### Corresponding author:

Joseph S Raleigh DVM, Small Animal Rotating Intern, University of Pennsylvania, School of Veterinary Medicine, 3800 Spruce Street, Philadelphia, PA 19104, USA  
Email: jsraleigh@ucdavis.edu



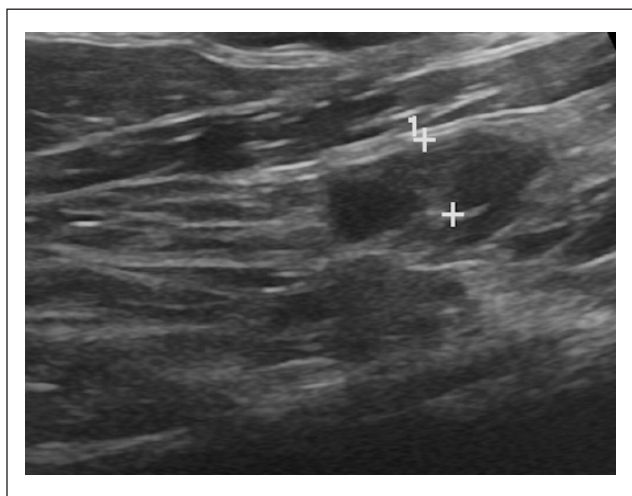
Creative Commons Non Commercial CC BY-NC: This article is distributed under the terms of the Creative Commons

Attribution-NonCommercial 4.0 License (<http://www.creativecommons.org/licenses/by-nc/4.0/>) which permits non-commercial use, reproduction and distribution of the work without further permission provided the original work is attributed as specified on the SAGE and Open Access pages (<https://us.sagepub.com/en-us/nam/open-access-at-sage>).

pelvic limb posture. Proprioceptive positioning was normal in the thoracic limbs and absent in the pelvic limbs. There was reduced tone in both pelvic limbs with bilateral reduction of the patellar reflex and pelvic limb withdrawal reflex. Anal tone was absent, the perineal reflex was reduced and the tail was flaccid with no voluntary movement. There was marked hyperesthesia on lumbosacral palpation. These neurological deficits were consistent with a L4–Cd myelopathy.

Based on these findings, the following differential diagnoses were considered: neoplasia (eg, lymphoma, meningioma, metastatic disease); trauma (eg, intervertebral disc disease); infectious/inflammatory disease (eg, viral [feline infectious peritonitis, feline leukemia virus], protozoal [toxoplasmosis] or immune-mediated); an ischemic myelopathy (secondary to occult heart disease or systemic hypertension) or multifactorial.

The following diagnostic tests were performed for systemic evaluation: venous blood gas analysis, complete blood count, chemistry panel, total thyroxine, urinalysis with cytopsin cytology, urine culture and an abdominal ultrasound. Significant blood work findings included an elevated total calcium (13.6 mg/dl), normal ionized calcium and mild elevations in phosphorus, magnesium, sodium, albumin and aspartate transaminase (AST). Urinalysis and cytopsin cytology revealed increased epithelial cells but no overt evidence of infection or neoplasia. Abdominal ultrasound showed several hyperechoic splenic nodules, a moderately distended urinary bladder, an enlarged pancreas with heterogeneous cyst-like nodules and regional lymphadenopathy as follows: hypogastric (6.9 mm), medial iliac (left: 3.9 mm; right: 5.4 mm) and ileocolic (2.8 mm) (Figure 1).



**Figure 1** Ultrasonographic image of the right medial iliac lymph node: the parenchyma was hypoechoic and rounded; diameter measured 5.4 mm; histopathology confirmed the presence of metastatic disease in both medial iliac lymph nodes

Lymphadenopathy was ultrasonographically defined as changes in either lymph node diameter or echotexture.

The diagnostic findings, clinical progression and differential diagnoses were reviewed with the owner, and radiographs of the lumbosacral spine, pelvis and urinary system were recommended. Fine-needle aspirates to further characterize the ultrasonographic changes to the spleen and pancreas were discussed as ancillary diagnostic tests. Given the cat's clinical deterioration and concerns for systemic disease, the owners elected humane euthanasia with necropsy.

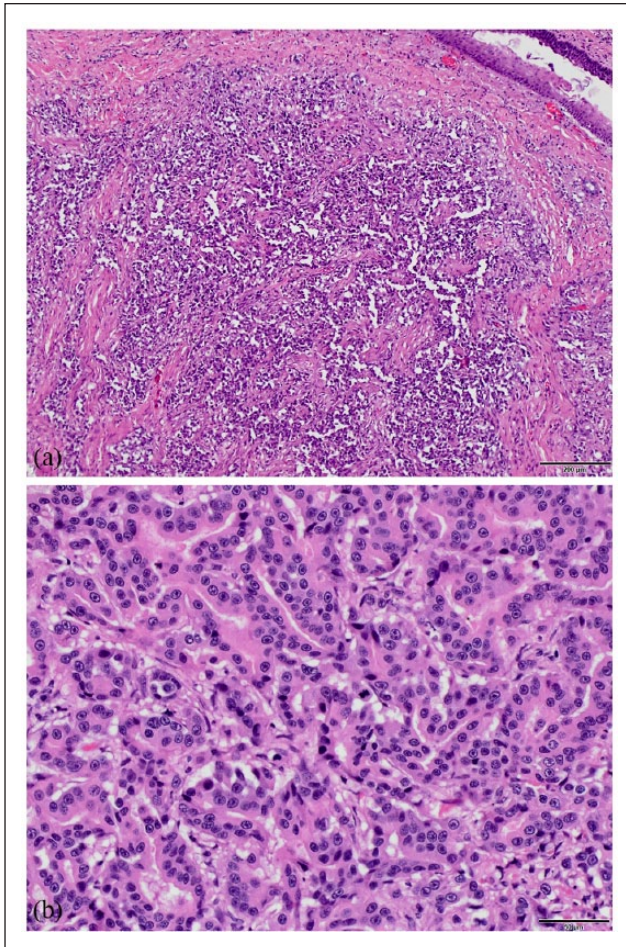
On gross necropsy, the right anal sac was effaced and expanded by a 1.5 cm diameter firm, white, multilobulated mass. Both medial iliac lymph nodes were diffusely enlarged, firm and tan-colored, with loss of corticomedullary distinction on cut surface. No masses were found in other organs, and the remaining lymph nodes were unremarkable on gross examination. Dissection of the pelvis and sectioning of the spinal canal revealed no grossly evident lesions.

Histopathological examination of hematoxylin and eosin-stained slides of the right anal sac mass revealed an infiltrative, unencapsulated, multilobulated neoplasm of polygonal cells arranged in cords and islands with rare tubule formation (Figure 2). Neoplastic cells had a moderate amount of eosinophilic cytoplasm and a single round-to-ovoid nucleus with stippled chromatin. Anisocytosis and anisokaryosis were moderate to marked. Mitoses were frequent and occasionally bizarre (Figure 2). A similarly appearing population of neoplastic cells effaced approximately 60% of each medial iliac lymph node. Similar pleomorphic cells infiltrated into the soft tissues and between the epineurium and perineurium of a nerve adjacent to the right medial iliac lymph node (Figure 3). These cells also surrounded and compressed individual nerve bundles and nerve roots located within the S3–Cd4 vertebrae (Figure 4). Affected nerve fibers frequently had dilated myelin sheaths.

Standard immunohistochemistry (IHC) for epithelial (wide-spectrum cytokeratin [WSCK], Z0622, Rb polyclonal antibody 1:1000 [Agilent; Dako]), T-cell (CD3 $\epsilon$ , MCA1477T, Rt monoclonal antibody [mAb] 1:600 [Bio-Rad]) and B-cell (CD79a, CST, 96024, Rb mAb 1:300) markers was performed on the anal sac mass, metastatic lymph nodes and perineural tissues to further characterize the neoplastic cells according to the IHC protocol described by Painter et al.<sup>3</sup> All neoplastic cells were positive for WSCK and negative for CD3 and CD79a, confirming the diagnosis of multifocal metastatic carcinoma of the anal sac (Figure 4).

## Discussion

This case demonstrates multiple novel findings, broadening our understanding of a rarely documented disease in cats. Specifically, the clinical presentation,

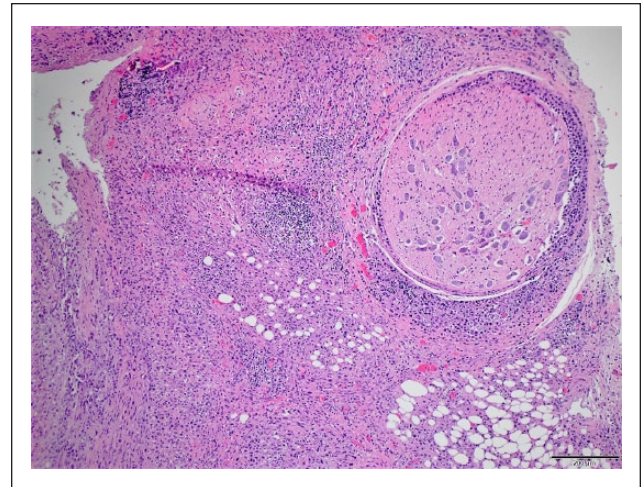


**Figure 2** Right anal sac: (a) arising from the gland of the anal sac is an infiltrative carcinoma, hematoxylin and eosin ( $\times 10$ ), scale bars =  $200\mu\text{m}$ . (b) Neoplastic cells forming tubules, hematoxylin and eosin ( $\times 40$ ), scale bars =  $50\mu\text{m}$

acute neurological deterioration and atypical metastatic pattern provide insight into the biological behavior of feline AGASACA.

Cats with AGASACA typically present with signs of local disease, such as perianal ulceration or discharge.<sup>4</sup> The erythematous tissue adjacent to the right anal sac found on physical examination is consistent with previous case descriptions, and necessitates thorough palpation of the perineal region. Atypical findings warrant further investigation via a rectal examination and, if present, a fine-needle aspirate of abnormal tissue. Documented cases of affected cats presenting with systemic signs are rare, and the acute neurological deterioration in this case is distinct.<sup>5</sup> Notably, a similar clinical progression has been reported in cats with spinal lymphosarcoma but not AGASACA.<sup>6</sup>

Anal sac adenocarcinomas are locally invasive with reported metastatic rates being variable depending on the study in both dogs and cats. A retrospective study of

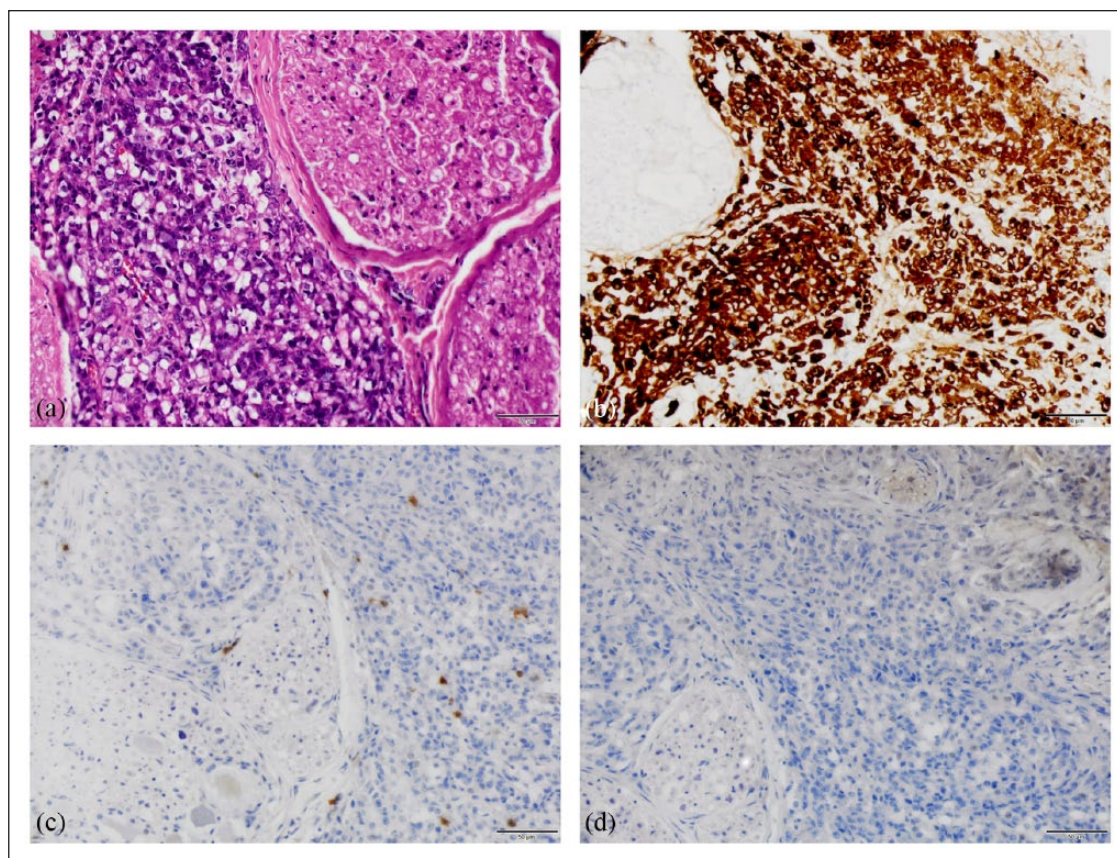


**Figure 3** Carcinoma cells around a peripheral nerve, hematoxylin and eosin ( $\times 10$ ), scale bars =  $200\mu\text{m}$

64 cats diagnosed with AGASACA documented a relatively low metastatic rate of 16%; however, complete tumor staging was not performed in each case. Prognosis was poor, with a reported median survival time of 3 months, and overall survival rates of 19% and 0% at years 1 and 2, respectively. More than 3/4 cats were euthanized owing to worsening clinical signs associated with local disease.<sup>4</sup> A more recent case series documented metastatic disease in 60% ( $n = 3/5$ ) of cats, with the sub-lumbar lymph nodes and lungs affected.<sup>7</sup> Although the metastatic potential may be decreased relative to dogs, these results indicate it is important to stage cats at the time of diagnosis.

The atypical metastatic pattern demonstrated in this case is another distinguishing feature. Perineural metastasis of AGASACA is rare in dogs and has never been confirmed in cats. In dogs, two studies have described the presence of metastatic lesions in the spinal cord. The first report found evidence on post-mortem examination, although there were no associated clinical signs.<sup>8</sup> The second report described an acute clinical deterioration similar to the present case. A dog with AGASACA rapidly progressed from pelvic limb paresis to paralysis as a result of metastatic spread to the spinal cord, vertebral bodies and canal.<sup>9</sup>

The primary route of carcinoma metastasis is via lymphatic vessels.<sup>10</sup> Perineural invasion has been documented in head and neck tumors in human medicine, as well as in a few other carcinomas. For several decades, neurotropic carcinomas were believed to follow lymphatics within the perineurium. However, recent studies have demonstrated that lymphatics do not penetrate the nerve sheath, which, in most cases, act as a strong barrier to carcinoma invasion. Currently, the mechanism of perineural invasion in carcinomas remains unknown.<sup>11</sup>



**Figure 4** Nerve bundles within S3–Cd4 vertebrae with metastatic carcinoma: (a) hematoxylin and eosin ( $\times 40$ ). (b) Cytokeratin positive ( $\times 40$ ). (c) CD3 negative ( $\times 40$ ). (d) CD79a negative ( $\times 40$ ). Scale bars = 50  $\mu\text{m}$

Neurological deficits were reported in a single previous case of feline AGASACA. A cat with confirmed local tumor recurrence was presented for signs consistent with sciatic nerve paralysis. Further diagnostics were not pursued, but perineural invasion cannot be excluded.<sup>4</sup> The current case represents the first account of a histologically confirmed AGASACA exhibiting perineural invasion with metastasis to individual nerve bundles and nerve roots within the S3–Cd4 vertebrae.

Available treatment options in this case were limited given the advanced disease stage. Local disease control via surgery or radiation therapy is the mainstay of treatment for AGASACA in dogs and improves overall survival times.<sup>12</sup> Adjunctive chemotherapy is often considered given the documented metastatic rates, and the current literature recommends multimodal protocols with surgery, chemotherapy and definitive radiation therapy for the longest median survival time.<sup>13</sup> Nevertheless, an accepted standard of care does not exist.

A combination of surgical cytoreduction, radiation and chemotherapy could have been explored. Isolated positive responses to radiation therapy have been reported in the treatment of feline spinal lymphosarcoma; however, treatment outcomes for carcinomas with

spinal cord metastasis are lacking in veterinary medicine.<sup>14</sup> In humans, radiation therapy is the preferred treatment with success rates varying based on the primary tumor site. Surgical resection is also considered in cases where adequate neurological function is present at the time of diagnosis.<sup>15</sup> Carboplatin-based chemotherapeutic protocols have been employed in previous feline AGASACA cases and may slow the progression of metastatic disease.<sup>16</sup> Ultimately, the efficacy of radiation and chemotherapy in this disease remains unclear; however, both modalities would have been offered if treatment had been pursued.

Certain diagnostics results were considered unrelated to the primary disease process and therefore not the focus of this case report. The elevated total calcium was likely due to the artificial increase in albumin secondary to dehydration. The elevations in phosphorous and magnesium were considered secondary to decreased glomerular filtration rate also due to dehydration. The elevated sodium was similarly due to a free-water deficit causing dehydration. The etiology of the dehydration was likely a combination of decreased mobility resulting in less drinking, systemic disease causing nausea and prolonged hyporexia. The mild elevation in AST was a

non-specific finding and likely reflected muscle damage caused by the neurological deficits. Histopathology of the splenic nodules visualized on ultrasound revealed multifocal myelolipomas. The heterogeneous cyst-like pancreatic nodules seen on ultrasound likely corresponded with regional dilation of the pancreatic duct noted histologically. This is typically a benign age-related change in cats. There was no evidence of neoplasia and the remainder of the pancreas was histologically and grossly normal. The discrepancy between ultrasonographic and necropsy findings likely represents a limitation in the diagnostic accuracy of imaging modalities.

## Conclusions

This case extends our understanding of the clinical and biological behavior of feline AGASACA. Further, it offers a novel differential diagnosis for an L4-Cd myelopathy and urinary incontinence in a cat. At a more general level, the findings underscore the importance of evaluating for anal sac disease throughout veterinary species.

**Conflict of interest** The authors declared no potential conflicts of interest with respect to the research, authorship, and/or publication of this article.

**Funding** The authors received no financial support for the research, authorship, and/or publication of this article.

## References

- 1 Goldschmidt MH and Shofer FS. *Skin tumours of dog and cat*. Oxford: Pergamon Press, 1992.
- 2 Goldschmidt MH and Zoltowski C. **Anal sac gland adenocarcinoma in the dog: 14 cases**. *J Small Anim Pract* 1981; 22: 119–128.
- 3 Painter JT, Clayton NP and Herbert RA. **Useful immunohistochemical markers of tumor differentiation**. *Toxicol Pathol* 2010; 38: 131–141.
- 4 Shoieb AM and Hanshaw DM. **Anal sac gland carcinoma in 64 cats in the United Kingdom (1995–2007)**. *Vet Pathol* 2009; 46: 677–683.
- 5 Mellanby RJ, Foale R, Friend E, et al. **Anal sac adenocarcinoma in a Siamese cat**. *J Feline Med Surg* 2002; 4: 205–207.
- 6 Lane SB, Kornegay JN, Duncan JR, et al. **Feline spinal lymphosarcoma: a retrospective evaluation of 23 cats**. *J Vet Intern Med* 1994; 8: 99–104.
- 7 Elliott JW and Blackwood L. **Treatment and outcome of four cats with apocrine gland carcinoma of the anal sac and review of the literature**. *J Feline Med Surg* 2011; 13: 712–717.
- 8 Meuten DJ, Cooper BJ, Capen CC, et al. **Hypercalcemia associated with an adenocarcinoma derived from the apocrine glands of the anal sac**. *Vet Pathol* 1981; 18: 454–471.
- 9 Brisson BA, Whiteside DP and Holmberg DL. **Metastatic anal sac adenocarcinoma in a dog presenting for acute paralysis**. *Can Vet J* 2004; 45: 678–681.
- 10 Friedl P and Wolf K. **Tumour-cell invasion and migration: diversity and escape mechanisms**. *Nat Rev Cancer* 2003; 3: 362–374.
- 11 Liebig C, Ayala G, Wilks JA, et al. **Perineural invasion in cancer: a review of the literature**. *Cancer* 2009; 115: 3379–3391.
- 12 Williams LE, Gliatto JM, Dodge RK, et al. **Carcinoma of the apocrine glands of the anal sac in dogs: 113 cases (1985–1995)**. *J Am Vet Med Assoc* 2003; 223: 825–831.
- 13 Turek MM, Forrest LJ, Adams WM, et al. **Postoperative radiotherapy and mitoxantrone for anal sac adenocarcinoma in the dog: 15 cases (1991–2001)**. *Vet Comp Oncol* 2003; 1: 94–104.
- 14 MacEwen E, Mooney S and Brown N. **Management of feline neoplasms**. In: Holzworth J (ed). *Diseases of the cat*. Philadelphia, PA: WB Saunders, 1987, pp 597–618.
- 15 Newton HB. **Overview of pathology and treatment of intramedullary spinal cord metastases**. In: Newton HB (ed). *Handbook of neuro-oncology neuroimaging*. 2nd ed. Amsterdam: Academic Press, 2016, pp 55–58.
- 16 Wright ZM, Fryer JS, Calise DV, et al. **Carboplatin chemotherapy in a cat with a recurrent anal sac apocrine gland adenocarcinoma**. *J Am Anim Hosp Assoc* 2010; 46: 66–69.