



Unusual invasion of primary pulmonary adenocarcinoma in a cat

Authors: Ambrosini, Yoko M, Johnson, Kelsey A, Matthews, Morgan, and Sato, Amy F

Source: Journal of Feline Medicine and Surgery Open Reports, 4(2)

Published By: SAGE Publishing

URL: <https://doi.org/10.1177/2055116918810897>



Unusual invasion of primary pulmonary adenocarcinoma in a cat

Yoko M Ambrosini, Kelsey A Johnson, Morgan Matthews and Amy F Sato

Journal of Feline Medicine and Surgery Open Reports
1–5

© The Author(s) 2018

Article reuse guidelines:

sagepub.com/journals-permissions

DOI: 10.1177/2055116918810897

journals.sagepub.com/home/jfmsopenreports

This paper was handled and processed by the American Editorial Office (AAFP) for publication in *JFMS Open Reports*



Abstract

Case summary An 11-year-old female spayed domestic shorthair cat was referred to the Foster Hospital for Small Animals, USA for suspected dysautonomia based on weight loss, vomiting and referral radiographs that showed severe dilation of the esophagus, stomach and entire gastrointestinal tract. After recheck radiographs revealed a decrease in gas compared with the referral images, persistently reduced gastrointestinal motility was deemed less likely; however, cardiomegaly and a soft tissue opacity overlying the esophagus were noted. Echocardiogram identified a pulmonary mass either impinging on or invading the local organs. At necropsy, gross pathology and histopathology showed an aggressive pulmonary carcinoma invading the heart, trachea and esophagus, resulting in a focal esophageal stricture. Gastrointestinal gas dilation was most likely secondary to aerophagia as a result of chronic partial esophageal obstruction.

Relevance and novel information To our knowledge, this is the first reported feline case of invasion of the esophagus and heart by a pulmonary adenocarcinoma. Other than weight loss, the clinical signs for this invasive neoplasm were not evident until the cat was diagnosed with hyperthyroidism and prescribed oral medications. This reinforces the fact that pulmonary adenocarcinoma is difficult to detect clinically until secondary problems from the primary or metastatic neoplasm arise.

Keywords: Pulmonary adenocarcinoma; metastasis; esophageal stricture; aerophagia; dysautonomia

Accepted: 11 October 2018

Case description

An 11-year-old 1.93 kg female spayed domestic shorthair cat was originally presented for chronic weight loss in the face of a voracious appetite, and was diagnosed with hyperthyroidism. Referral blood work showed total thyroxine 17.1 (0.8–4.7) µg/dl and alanine aminotransferase 215 (12–130) U/l. Methimazole 2.5 mg q12h treatment was initiated; however, shortly after starting the medication, the cat began vomiting while maintaining a good appetite. No improvement was noted when the methimazole formulation was changed from tablet to liquid. Supportive care with maropitant citrate (Cerenia 1 mg/kg [Zoetis]) was instituted without controlling the cat's signs. Orthogonal whole-body radiographs showed severe dilation of the upper and lower gastrointestinal tracts (Figure 1), with an

impression of esophageal fluid accumulation at the level of the carina, and moderate to marked generalized cardiomegaly. The cat was referred for further diagnostics and care for persistent vomiting, gastrointestinal stasis, and possible dysautonomia.

On presentation to the Foster Hospital for Small Animals at the Cummings School of Veterinary Medicine,

Department of Clinical Sciences, Cummings School of Veterinary Medicine at Tufts University, North Grafton, MA, USA

Corresponding author:

Yoko M Ambrosini DVM, MPVM, PhD, DACVIM, Department of Clinical Sciences, Cummings School of Veterinary Medicine at Tufts University, 200 Westboro Rd, North Grafton, MA 01536, USA
Email: yoko.ambrosini@tufts.edu



Creative Commons Non Commercial CC BY-NC: This article is distributed under the terms of the Creative Commons

Attribution-NonCommercial 4.0 License (<http://www.creativecommons.org/licenses/by-nc/4.0/>) which permits non-commercial use, reproduction and distribution of the work without further permission provided the original work is attributed as specified on the SAGE and Open Access pages (<https://us.sagepub.com/en-us/nam/open-access-at-sage>).

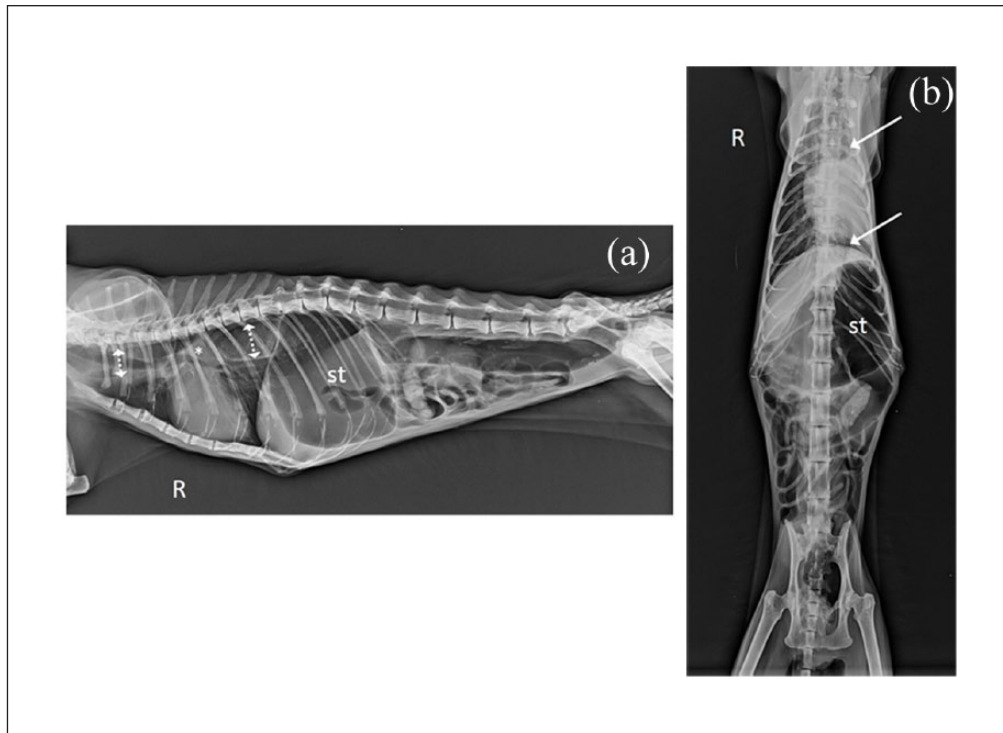


Figure 1 (a) Right lateral full-body referral radiograph. There is moderate-to-marked cardiomegaly and marked, diffuse gas dilation of the esophagus (dotted arrows), stomach, and small and large intestines. There is an ill-defined triangular fluid/soft tissue opacity at the carina (asterisk). (b) Ventrodorsal full-body referral radiograph. In addition to cardiomegaly and gastrointestinal gas accumulation, left lung collapse and a mediastinal shift to the left (solid arrows) are visible. R = right; st = stomach

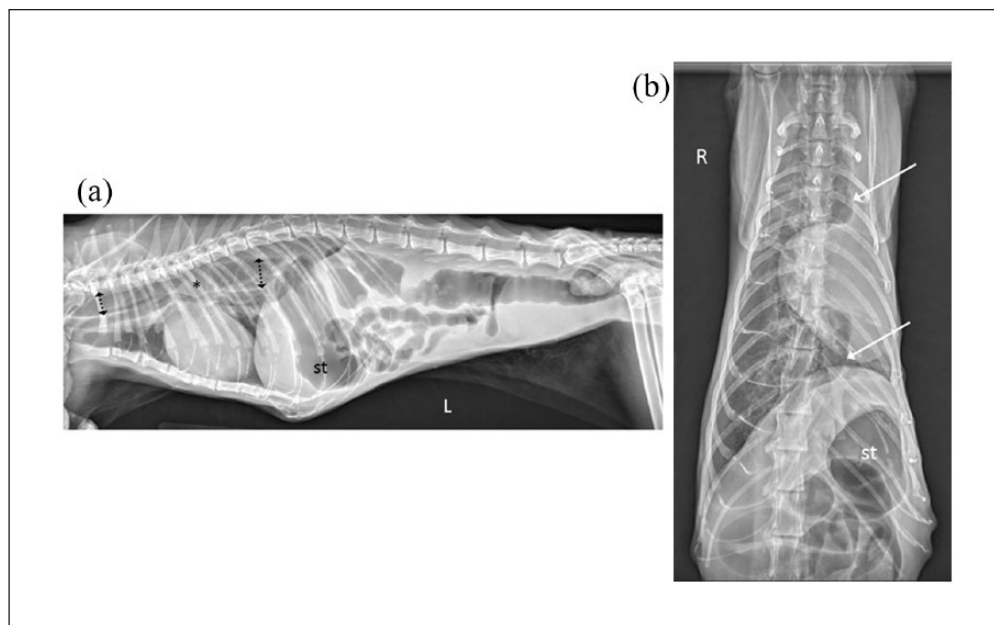


Figure 2 (a) Left lateral full-body radiograph. The moderate-to-marked cardiomegaly is unchanged, and the diffuse esophageal (dotted arrows) and gastrointestinal gas dilation are mildly reduced compared with the referral radiographs. A rounded soft tissue structure at the carina is now more visible (asterisk). (b) Dorsoventral thoracic radiograph. The previously identified left lung collapse and mediastinal shift (solid arrows) with cardiomegaly are unchanged. R = right; st = stomach

Tufts University, USA the cat had severe muscle wasting with moderate cachexia. The cat had a gallop rhythm, a small right-sided thyroid slip, mild anisocoria (miosis of the left eye) and repeatedly regurgitated on abdominal palpation. No overt lesions involving the paws or digits were noted. Neurologic consultation revealed generalized weak reflexes and withdrawal, with good perianal tone and eye motor function.

Recheck lateral whole-body and dorsoventral thoracic radiographs were obtained (Figure 2). Although, classically, abdominal radiographs are taken with a history of vomiting, whole-body radiographs, including the thorax, were chosen in this case so that all previously noted radiographic abnormalities in both the thorax and abdomen could be re-evaluated.

The cardiac silhouette was again moderately to markedly enlarged. The left cranial and caudal lung lobes were persistently collapsed, causing a leftward mediastinal shift. The right lung lobes were hyperinflated but otherwise normal in appearance. A focal, rounded, soft tissue opacity was noted overlying the esophagus at the level of the carina, visible only on the lateral view. The entire gastrointestinal tract, including the esophagus, was again diffusely gas-dilated; however, the volume of gas within the stomach and intestines was reduced compared with the previous referral images. Therefore aerophagia was thought a more likely cause than diffuse functional ileus. Cardiomegaly was attributed to thyrotoxic cardiomyopathy. Differentials for the left lung lobes' collapse included chronic lower airway disease (although this was considered unlikely given the lack of evidence for lower airway disease in the aerated right lung), or a mass obstructing the left primary bronchus. The soft tissue structure at the carina was thought to represent either focal fluid within the esophagus or a mass, possibly of esophageal, ectopic thyroid or left-sided pulmonary origin.

After reviewing the history with the owner, the cat was assessed to be chronically regurgitating, not vomiting. Given the possible esophageal involvement with a mass based on clinical signs and radiographic findings, CT of the thorax and/or endoscopic evaluation of the esophagus were recommended. Prior to anesthesia for CT, an echocardiogram was performed to evaluate the cat's cardiac murmur and cardiomegaly. Echocardiography detected a large mass adjacent to the heart base, compressing the pulmonary arteries, which was suspected to be producing a significant increase in right-sided cardiac pressures. Left ventricular hypertrophy was also noted. At the time of the examination, the cat was hypothermic at 96.3°F and hypotensive at 40 mmHg (systolic). These findings were discussed with the owner and humane euthanasia, with necropsy, was elected.

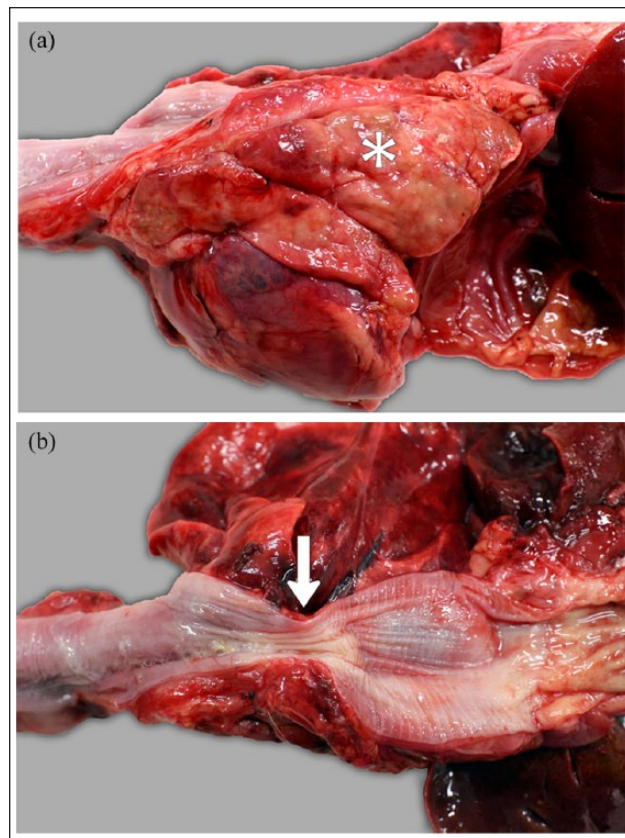


Figure 3 Photographs during post-mortem examination. (a) The left cranial and caudal lung lobes are consolidated and there is a solid, irregular, white-to-yellow mass (white asterisk) firmly adhered to the serosal surface of the adjacent esophagus and the base of the heart. (b) The mass seen in (a) is causing marked narrowing of the esophageal lumen (arrow)

Post-mortem examination revealed a focal esophageal stricture secondary to local invasion of the esophageal wall by a left-sided pulmonary mass (Figure 3). The gastrointestinal tract was otherwise unremarkable besides moderate gas distention. Histopathology of the mass revealed a densely cellular, unencapsulated neoplasm composed of polygonal cells arranged in cords, islands and acini supported by a robust fibrovascular stroma (Figure 4). The mitotic count was 19 per 10 high-power fields. Immunohistochemistry staining with thyroid transcription factor-1 revealed variable positive nuclear staining in the neoplastic cells, confirming a lung origin neoplasm and a morphologic diagnosis of pulmonary adenocarcinoma (Figure 5). Immunohistochemistry staining with thyroglobulin was negative. The neoplastic cells were found invading the adjacent esophageal musculature, the right atrium and the wall of the main pulmonary artery by both direct and vascular invasion (Figure 6). Findings were supportive of primary pulmonary adenocarcinoma with extensive regional tissue invasion causing secondary esophageal stricture.

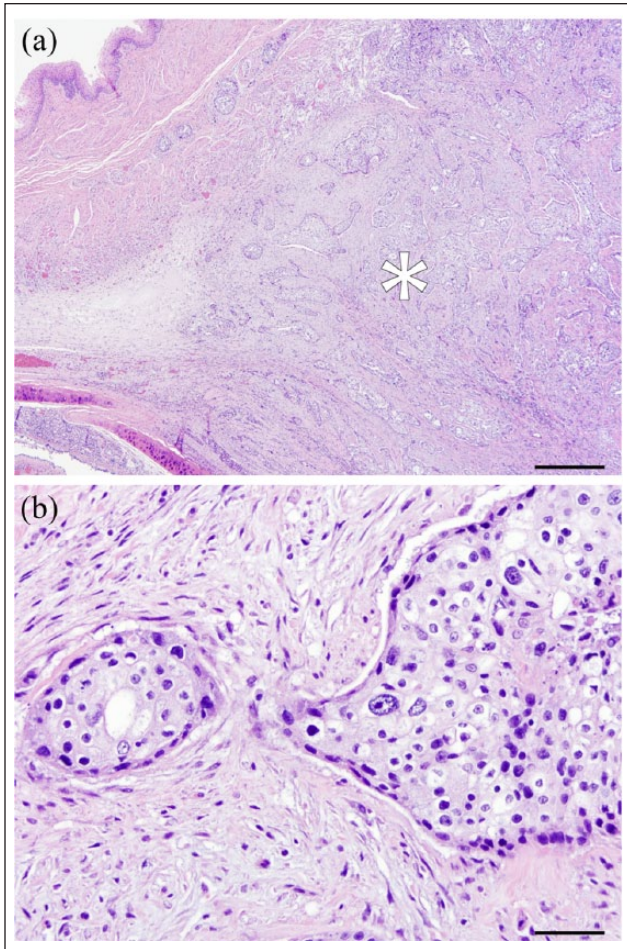


Figure 4 On $\times 4$ magnification of the esophagus and trachea, there is a densely cellular, unencapsulated, highly invasive neoplasm. (b) $\times 40$ magnification of the neoplasm shows polygonal cells arranged in cords, islands and acini, supported by a robust fibrovascular stroma

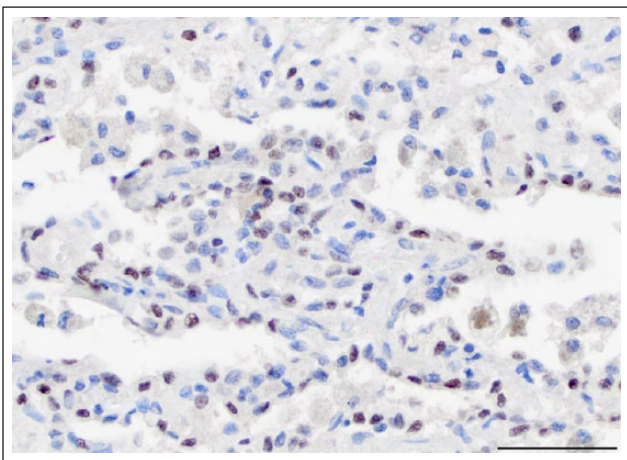


Figure 5 Staining with thyroid transcription factor-1 (TTF-1) shows positive nuclear staining, consistent with a primary lung adenocarcinoma

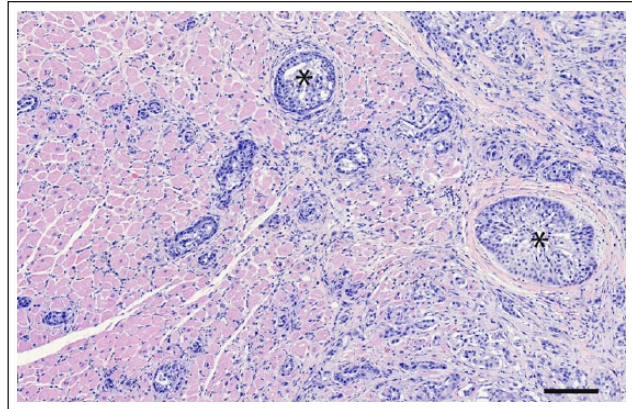


Figure 6 On $\times 10$ magnification, the myocardium is invaded by both direct and vascular invasion (black asterisks)

Discussion

Primary lung tumors are relatively uncommon in cats, with prevalence ranging from 0.69–0.75% in all cats undergoing necropsy.¹ Adenocarcinomas account for >50% of feline primary pulmonary neoplasms;² less common neoplasms include squamous cell carcinoma and adenosquamous carcinoma.^{2–5} The caudal lung lobes appear to be more commonly involved.^{5,6} The treatment of choice for solitary primary pulmonary tumors in cats is wide surgical resection, and median survival times of 12–18 months are reported for cats with completely resected, moderately differentiated lesions.⁷

The prognosis is guarded, however, for cats with more aggressive or multifocal disease.⁸ In one study, 85% of cats with pulmonary adenocarcinoma treated only with surgery succumbed to metastatic disease, with a median survival time of 115 days.⁸ In this same study, the prognosis was negatively affected if the primary lung tumor was poorly differentiated and if there was tracheobronchial metastasis.⁸ In another retrospective study of surgically treated primary lung tumor, cats that were clinically affected (eg, anorexia, dyspnea, cough, weight loss and lethargy) had significantly shorter survival times compared with cats without clinical signs.⁶ Of cats that survived to the time of suture removal, median survival time was 64 days.⁶ The impact of chemotherapy in cats with primary lung tumors is not well studied, but one cat that received mitoxantrone following a lung lobectomy lived for 34 months after surgery.⁹

In the literature, feline pulmonary tumors have metastatic rates ranging from 76–80%, with a variety of metastatic targets. In one study with a 76% metastatic rate, sites of metastasis included the regional lymph nodes (30%), intrathoracic organs (30%) and variable extrathoracic organs, including the digits (16%).³ In another study, similar findings were

observed with approximately 80% of feline pulmonary carcinomas examined metastasizing, with a decreasing order of intrathoracic carcinomatosis (38.5%), regional lymph nodes (33.3%) and distant visceral organs, including liver, kidney and skeletal muscle.² A syndrome of 'lung-digit disease' has been reported in cats, describing the predilection of pulmonary carcinomas for metastasis to the digits.¹⁰⁻¹² In one study, approximately 21% of amputated feline digits submitted to a single laboratory contained metastatic pulmonary carcinoma.¹⁰ Recently, more unusual metastasis of pulmonary adenocarcinoma to the skeletal muscle, eyes and aorta was reported.¹³⁻¹⁶

Originally, this cat was referred for suspected feline dysautonomia, given the gas-dilated gastrointestinal tract, as well as the history of vomiting/regurgitation. Dysautonomia is a rare condition reported mostly in Europe, with nine cases reported in the Midwestern USA.¹⁷ Young cats (<3 years old) are more typically affected; however, cases up to 11 years of age have been reported.¹⁷ The cat in this case report was 17 years old, and no corresponding sympathetic or parasympathetic deficits were identified on physical or neurologic evaluation (eg, dilated/non-responsive pupils, urinary retention or lack of anal tone). Comparison of referral and follow-up radiographs showed a decrease in gastrointestinal gas, rather than persistent functional ileus, as would be expected with dysautonomia.¹⁸ Instead, an esophageal lesion was suspected based on thorough assessment of the recheck radiographs together with the physical and neurological examination findings. Anisocoria was thought to be due to preganglionic Horner's syndrome, given the anatomic location and extensive local invasion of this tumor.

Conclusions

This was a unique presentation of pulmonary adenocarcinoma in which imaging helped clinicians and owners reach the most likely diagnosis and recommendations. Impingement of the esophagus secondary to primary pulmonary neoplasia can be considered a differential diagnosis in a cat with soft tissue opacity within the esophagus, and diffuse gas dilation of the esophagus and gastrointestinal tract.

Conflict of interest The authors declared no potential conflicts of interest with respect to the research, authorship, and/or publication of this article.

Funding The authors received no financial support for the research, authorship, and/or publication of this article.

References

- 1 Wilson DW and Dungworth DL. **Tumors of the respiratory tract.** In: Meuten DJ (ed). *Tumors in domestic animals*. 2008: 467-498.
- 2 Hahn KA and McEntee MF. **Primary lung tumors in cats: 86 cases (1979-1994).** *J Am Vet Med Assoc* 1997; 211: 1257-1260.
- 3 D'Costa S, Yoon B-I, Kim D-Y, et al. **Morphologic and molecular analysis of 39 spontaneous feline pulmonary carcinomas.** *Vet Pathol* 2012; 49: 971-978.
- 4 Moulton JE, von Tscharner C and Schneider R. **Classification of lung carcinomas in the dog and cat.** *Vet Pathol* 1981; 18: 513-528.
- 5 Aarsvold S, Reetz JA, Reichle JK, et al. **Computed tomographic findings in 57 cats with primary pulmonary neoplasia.** *Vet Radiol Ultrasound* 2015; 56: 272-277.
- 6 Maritato KC, Schertel ER, Kennedy SC, et al. **Outcome and prognostic indicators in 20 cats with surgically treated primary lung tumors.** *J Feline Med Surg* 2014; 16: 979-984.
- 7 Nunley J, Sutton J, Culp W, et al. **Primary pulmonary neoplasia in cats: assessment of computed tomography findings and survival.** *J Small Anim Pract* 2015; 56: 651-656.
- 8 Hahn KA and McEntee MF. **Prognosis factors for survival in cats after removal of a primary lung tumor: 21 cases (1979-1994).** *Vet Surg* 1998; 27: 307-311.
- 9 Clementsa DN, Hoganb AM and Cavea TA. **Treatment of a well differentiated pulmonary adenocarcinoma in a cat by pneumonectomy and adjuvant mitoxantrone chemotherapy.** *J Feline Med Surg* 2004; 6: 199-205.
- 10 Gottfried SD, Popovitch CA, Goldschmidt MH, et al. **Metastatic digital carcinoma in the cat: a retrospective study of 36 cats (1992-1998).** *J Am Anim Hosp Assoc* 2000; 36: 501-509.
- 11 Goldfinch N and Argyle DJ. **Feline lung-digit syndrome: unusual metastatic patterns of primary lung tumours in cats.** *J Feline Med Surg* 2012; 14: 202-208.
- 12 van der Linde-Sipman JS and van den Ingh TS. **Primary and metastatic carcinomas in the digits of cats.** *Vet Q* 2000; 22: 141-145.
- 13 Langlais LM, Gibson J, Taylor JA, et al. **Pulmonary adenocarcinoma with metastasis to skeletal muscle in a cat.** *Canadian Vet J* 2006; 47: 1122-1123.
- 14 Gionfriddo JR, Fix AS, Niyo Y, et al. **Ocular manifestations of a metastatic pulmonary adenocarcinoma in a cat.** *J Am Vet Med Assoc* 1990; 197: 372-374.
- 15 Cassotis NJ, Dubielzig RR, Gilger BC, et al. **Angioinvasive pulmonary carcinoma with posterior segment metastasis in four cats.** *Vet Ophthalmol* 1999; 2: 125-131.
- 16 Thrift E, Greenwell C, Turner A-L, et al. **Metastatic pulmonary carcinomas in cats ('feline lung-digit syndrome'): further variations on a theme.** *JFMS Open Rep* 2017; 3: 1-8. DOI: 10.1177/2055116917691069.
- 17 Kidder AC, Johannes C, O'Brien DP, et al. **Feline dysautonomia in the Midwestern United States: a retrospective study of nine cases.** *J Feline Med Surg* 2008; 10: 130-136.
- 18 Novellas R, Simpson KE, Gunn-Moore DA, et al. **Imaging findings in 11 cats with feline dysautonomia.** *J Feline Med Surg* 2010; 12: 584-591.