



Use of metronomic chemotherapy in the management of a cat with abdominal haemangiosarcoma

Authors: Yee-Ka Cheng, Katrina, Krockenberger, Mark, and Bennett, Peter

Source: Journal of Feline Medicine and Surgery Open Reports, 4(2)

Published By: SAGE Publishing

URL: <https://doi.org/10.1177/2055116918793455>



Use of metronomic chemotherapy in the management of a cat with abdominal haemangiosarcoma

Katrina Yee-Ka Cheng¹, Mark Krockenberger² and Peter Bennett¹

Journal of Feline Medicine and Surgery Open Reports
1–5

© The Author(s) 2018

Reprints and permissions:

sagepub.co.uk/journalsPermissions.nav

DOI: 10.1177/2055116918793455

journals.sagepub.com/home/jfmsopenreports

This paper was handled and processed by the European Editorial Office (ISFM) for publication in *JFMS Open Reports*



Abstract

Case summary A 12-year-old entire domestic shorthair was evaluated for a 5 week history of intermittent vomiting, loss of appetite and weight loss. Abdominal ultrasound revealed a multi-lobulated heterogeneous mass adjacent to the mesenteric vessels. Cytology from fine-needle aspirates was non-diagnostic. Histopathology from a Tru-cut biopsy was consistent with haemangiosarcoma. The cat was treated with metronomic chemotherapy using oral cyclophosphamide. The cat remained clinically well and was euthanased 10 months after diagnosis owing to development of a haemoabdomen.

Relevance and novel information Prognosis of feline abdominal haemangiosarcoma is generally poor and limited information on treatment is available in the veterinary literature. The use of metronomic chemotherapy with oral cyclophosphamide in this cat provided a 10 month period of good-quality life.

Keywords: Abdominal haemangiosarcoma; metronomic chemotherapy; cyclophosphamide; chemotherapy

Accepted: 21 June 2018

Introduction

Haemangiosarcoma (HSA) is a malignant neoplasm of vascular endothelial cells. HSA is uncommon in cats and accounts for 0.5–2% of all feline neoplasia¹. Visceral HSA has been reported to be less frequent than cutaneous or subcutaneous forms.^{2,3} It is most commonly diagnosed in middle-aged to older cats, with a reported mean age of 10 years.^{4,5} No sex or breed predilection has been reported.^{4,5} Visceral HSA has been found in various locations in cats,^{2,4–6} most frequently in the spleen, liver and intestines.^{4,7}

The prognosis of feline visceral HSA is guarded, despite therapeutic interventions.² In a retrospective study of 26 cats, 71% were euthanased within 1 day of diagnosis and reported median survival time was 77 days (range 23–296 days) in six that were not euthanased.⁴ Metronomic chemotherapy, which is generally well tolerated, has not been described in the management of HSA in cats. Metronomic cyclophosphamide has been shown to work through several pathways, having cytotoxic, anti-angiogenic and immunomodulatory effects.^{8,9} This

report describes the treatment of abdominal HSA in a cat receiving metronomic cyclophosphamide.

Case description

A 12-year-old entire male domestic shorthair cat was referred with a 5 week history of intermittent vomiting, loss of appetite and weight loss. A mid-abdominal mass had been identified at the referring practice on abdominal radiographs and ultrasound, with the origin not

¹University Teaching Veterinary Hospital Sydney, Sydney School of Veterinary Science, Faculty of Science, University of Sydney, NSW, Australia

²Veterinary Pathology Diagnostic Services, Sydney School of Veterinary Science, Faculty of Science, University of Sydney, NSW, Australia

Corresponding author:

Katrina Yee-Ka Cheng BVSc (Hons), MANZCVS, University Teaching Veterinary Hospital Sydney, University of Sydney, Evelyn Williams Building B10, NSW 2006, Australia.
Email: katrina.cheng@sydney.edu.au



Creative Commons Non Commercial CC BY-NC: This article is distributed under the terms of the Creative Commons

Attribution-NonCommercial 4.0 License (<http://www.creativecommons.org/licenses/by-nc/4.0/>) which permits non-commercial use, reproduction and distribution of the work without further permission provided the original work is attributed as specified on the SAGE and Open Access pages (<https://us.sagepub.com/en-us/nam/open-access-at-sage>).

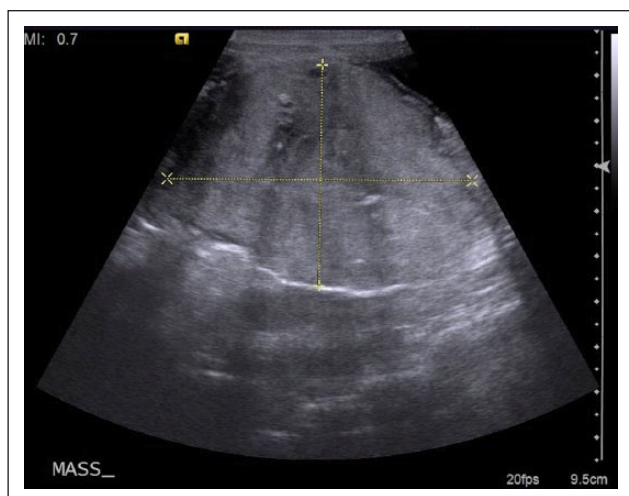


Figure 1 Ultrasound image of a large heterogeneous mass with multiple hyperechoic foci and circular anechoic areas. The mass was found adjacent to the mesenteric vessels with irregular borders

determined. The cat's previous history included chronic arthritis being treated intermittently with the non-steroidal anti-inflammatory drug (NSAID) meloxicam (Metacam; Boehringer Ingelheim), which was stopped by the referring practice prior to presentation. The cat had been in remission from diabetes mellitus for 2 years.

Blood work performed at the referring practice showed mild anaemia (haematocrit [HCT] 25.7 l/l; reference interval [RI] 30–45 l/l) that was not further characterised as blood film examination or reticulocyte evaluation was not performed. A limited biochemistry profile showed azotaemia, with creatinine at 254 $\mu\text{mol/l}$ (RI 53–177 $\mu\text{mol/l}$) and urea of 11.5 mmol/l (RI 5.4–12.5 mmol/l). A urinalysis was not performed.

An in-house SNAP ELISA for feline leukaemia virus and feline immunodeficiency virus was negative. Thoracic radiographs were unremarkable. An ultrasound-guided fine-needle aspirate of the mass was performed, which showed heavy blood contamination with a moderate number of large lymphocytes and reactive macrophages. The sample was considered non-diagnostic.

On presentation at the University Teaching Hospital, Sydney, the cat was bright and responsive, weighed 5.2 kg (body condition score 2/5) and had lost 900 g of weight over the previous month. On physical examination, a grade III/VI parasternal systolic heart murmur was auscultated. A large (6 × 4 cm), slightly irregular and firm mass was palpated in the mid-abdomen. The left kidney was palpably smaller than the right. The remainder of the physical examination was unremarkable.

A repeat abdominal ultrasound (Phillips EPIQ5; Phillips Medical Systems Netherlands) using linear array and curvilinear array (5 Mhz) transducers

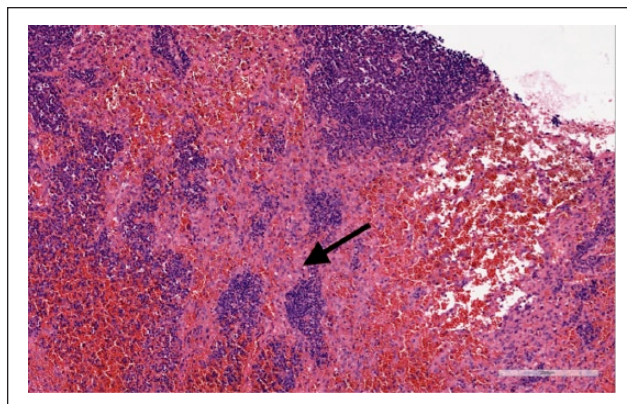


Figure 2 Histopathology of the abdominal mass. Irregular bands of pleomorphic spindle cells (black arrow) forming irregular blood-filled spaces intersperse lymphoid tissue comprised of small lymphocytes reminiscent of either residual lymph node or ectopic splenic tissue (haematoxylin and eosin)

identified a 50 × 67 mm lobulated heterogeneous mass in the mid-abdomen adjacent to the mesenteric vessels (Figure 1). The ileocolic lymph node was mildly enlarged (short axis 6 mm) with normal sonographic appearance. Nephrolithiasis and a decrease in size of the left kidney and presumed compensatory hypertrophy of the right kidney were identified. Cytological examination of the mass and the enlarged ileocolic lymph node by ultrasound-guided fine-needle aspirate showed blood contamination and was considered inconclusive. Ultrasound-guided core biopsies were obtained under sedation using a 14 G Tru-cut biopsy needle (Becton Dickinson Australia).

Histopathological evaluation of the Tru-cut biopsy revealed a non-encapsulated proliferation of irregular bands of pleomorphic spindle cells forming irregular blood-filled spaces and interspersed with multiple foci of lymphoid tissue (Figure 2). The cells had large round-to-angular, hyperchromic basophilic nuclei with 1–2 nucleoli, displaying marked anisokaryosis and a mitotic index of 2/10 high-power fields (Figure 3). The cells had a moderate amount of pale eosinophilic cytoplasm with indistinct cell boundaries. The diagnosis of HSA was made based on the cytological features of malignancy in the cell population forming vascular spaces.

The cat was started on oral metronomic chemotherapy with compounded 5 mg oral cyclophosphamide (Bova Compounding Chemist, 16.6 mg/m² daily). The cat's owner reported that the cat did well at home after starting treatment. There was one single vomit and loss of appetite for 2 days that resolved on temporary discontinuation of medication for 3 days. Four weeks after treatment started, the cat's appetite increased with only occasional vomiting (1–2 times a month). The cat started

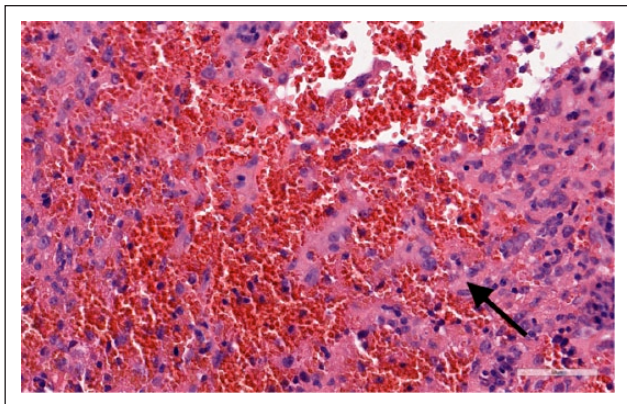


Figure 3 The mass is comprised of large pleomorphic irregular spindle cells with large round-to-elongated nucleolated nuclei and variable amounts of eosinophilic cytoplasm with indistinct cell boundaries (black arrow). The proliferative spindle cell population forms irregular blood-filled spaces (haematoxylin and eosin)

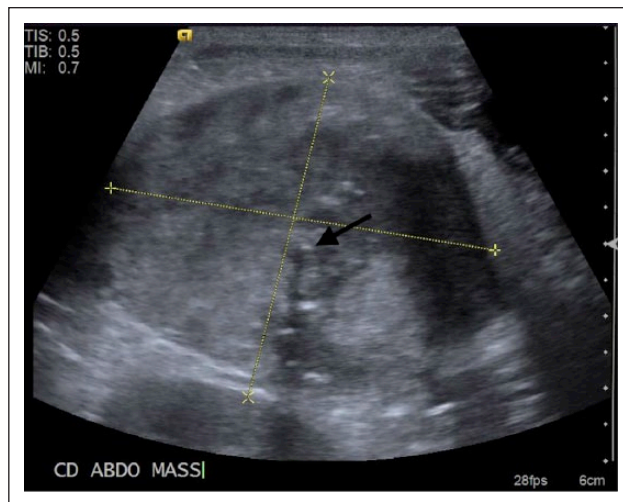


Figure 4 Ultrasound image of a large heterogeneous mass 8 months after treatment started that is similar in size but has progressive mineralisation (black arrow) and heterogeneity

gaining weight 6 weeks after commencing cyclophosphamide and maintained this for 8 months. The abdominal mass was palpated to be similar size on physical examination.

A complete blood count performed every 4–8 weeks revealed a mild, non-regenerative microcytic, normochromic anaemia (HCT 24–28 l/l [RI 30–45 l/l]; mean cell volume 34–37 fl [RI 40–45 fl]), mild persistent thrombocytopenia ($217\text{--}289 \times 10^9/l$; RI $300\text{--}700 \times 10^9/l$) with lymphocytopenia ($0.3\text{--}0.68 \times 10^9/l$; RI $1.6\text{--}7 \times 10^9/l$). A biochemistry panel performed 6 weeks post-treatment revealed persistent but stable azotaemia (creatinine 256 $\mu\text{mol/l}$ [RI 90–180 $\mu\text{mol/l}$], urea 15 mmol/l [RI 7.2–10.7 mmol/l]) and hyperphosphataemia (2.82 mmol/l [RI 1.3–2.3], not measured previously). The cat was clinically stable at this stage and was diagnosed with International Renal Interest Society stage 3 chronic kidney disease, based on its creatinine level. A commercial kidney diet (Hill's Prescription Diet k/d) was recommended.

Three months into treatment, the cat developed acute onset of sneezing, which resolved spontaneously with a presumptive diagnosis of viral upper respiratory disease. The cat developed alopecia from self-mutilation, over the flanks, 4 weeks into treatment; the alopecia resolved spontaneously. Eight months after treatment started, a repeat abdominal ultrasound was performed, which showed that the abdominal mass was similar in size (53×45 mm) with mild progression of mineralisation and heterogeneity (Figure 4). There was enlargement of multiple mildly heterogeneous ileocolic lymph nodes (largest one 20×30 mm), suggestive of metastatic disease. There was mild free peritoneal fluid and also mild progression of chronic changes in both kidneys. The cat continued to be clinically well until 10 months

after diagnosis, when it lost 300 g within a month. The cat presented for acute onset of anorexia and weakness 10 months after treatment started. On physical examination, the cat was tachycardic and tachypnoeic with weak femoral pulses. There was also evidence of fluid wave in the abdomen suspected to be due to haemorrhage. The cat was euthanased 6 days later owing to failure of improvement in clinical signs. Post-mortem examination of the cat was declined by the owner.

Discussion

In agreement with other reports,^{4,5,10} the cat in the current report had non-specific clinical signs, including vomiting, weight loss, lethargy and anorexia. Needle aspiration cytology in this cat was inconclusive, most likely owing to failure of the cancer cells to exfoliate and the presence of blood contamination in the sample.¹¹ The diagnosis of HSA of this case relied on histopathology on tissue biopsy. Immunohistochemical staining for factor VIII and CD31 antigens can be performed for confirmation of endothelial origin in uncertain cases.^{12,13}

Similar to dogs, feline visceral HSA has high metastatic potential, with a previously reported metastatic rate of 60–77%.^{4,5,7} Abdominal metastasis is common, with abdominal lymph nodes (33%) and the liver (27%) being the most common locations in one study.⁷ In our case, the enlarged ileocolic lymph nodes were most likely metastatic, but there was no evidence of metastasis to other organs. Pulmonary metastasis was reported in 33% of cats at diagnosis in one study,⁴ but was not observed in this case.

Currently, there is limited information on the management for affected cats with HSA. Surgery followed by adjuvant chemotherapy, most commonly doxorubicin,

vincristine and cyclophosphamide, is currently the standard of care treatment in dogs with visceral HSA. Because the mass was large and located in close proximity to the mesenteric vessels, surgery was not a feasible treatment option in the present case. Generally, HSA has a poor response to radiation therapy. In this case, we were limited by the location of the mass and therefore radiation was not a feasible option. Conventional maximum tolerated dose cytotoxic therapy was recommended to the owner but was declined owing, in part, to the risk of worsening the renal function that can be associated with the use of doxorubicin in cats.¹⁴ Metronomic chemotherapy was used in this cat with good clinical response.

Metronomic chemotherapy is the use of frequent but significantly lower doses of cytotoxic drugs without resting intervals. Cyclophosphamide combined with NSAIDs are the most commonly used drugs in people and veterinary patients.⁹ However, NSAIDs were not used in the present case owing to the concerns of worsening of the pre-existing kidney disease. The efficacy of the treatment protocol without the use of NSAIDs has not been evaluated as in the current case.

Similar to what was found in dogs previously, a recent retrospective study found that metronomic chemotherapy was well tolerated in 24 cats with various cancer types.¹⁵ The reported incidence of toxic events, including gastrointestinal, haematological and renal adverse effects after 4 weeks of therapy was 29% and defined as mild-to-moderate in intensity. Similarly, the cat in this case report tolerated metronomic chemotherapy well, with only mild thrombocytopenia recorded. Anorexia and vomiting only occurred once and resolved quickly after a 'drug holiday'. The cat did not have any anti-nausea medications as the owners had difficulty administering oral medications when the cat was inappetent.

The persistent lymphocytopenia on routine monitoring blood work was attributed to the stress during hospital visits or as a result of the chemotherapy.⁸ The mild non-regenerative anaemia was attributed to iron deficiency from low-grade intestinal bleeding and anaemia of chronic disease. The development of pruritus and alopecia in this cat was suspected to be behaviour-related or an adverse drug reaction based on negative findings on previous investigations for other differentials including food allergy and ectoparasite infestation.

Ideally, sub-staging of chronic kidney disease and routine urinalysis should be performed before and during treatment with cyclophosphamide. However, this was limited by the owner's reluctance to sedate the cat and an inability to collect a voided contaminated sample at home. Although 20% of cats (3/15) and 6% (2/30) of dogs had moderate renal toxicity after having cyclophosphamide, the association of the use of cyclophosphamide and renal toxicity cannot be confirmed owing to the concurrent use of NSAIDs in these cases.^{15,16} This

cat did not receive NSAIDs and its chronic kidney disease did not seem to progress throughout the treatment period.

Conclusions

Metronomic chemotherapy with oral cyclophosphamide was well tolerated and did not result in any significant adverse side effects. The cat's initial presenting clinical signs were improved significantly and tumour size was stable for 10 months, which was longer than survival times previously reported. Further studies are needed to evaluate the anticancer effect of metronomic chemotherapy for specific tumour types in a larger numbers of animals.

Acknowledgements The authors would like to thank Dr Scott Lindsay and Dr Timothy Foo for their expertise in pathology and diagnostic imaging, respectively.

Conflict of interest The authors declared no potential conflicts of interest with respect to the research, authorship, and/or publication of this article.

Funding The authors received no financial support for the research, authorship, and/or publication of this article.

References

- 1 Patnaik AK, Liu SK, Hurvitz AI, et al. **Nonhematopoietic neoplasms in cats.** *J Natl Cancer Inst* 1975; 54: 855.
- 2 Johannes CM, Henry CJ, Turnquist SE, et al. **Hemangiosarcoma in cats: 53 cases (1992–2002).** *J Am Vet Med Assoc* 2007; 231: 1851–1856.
- 3 Schultheiss PC. **A retrospective study of visceral and non-visceral hemangiosarcoma and hemangiomas in domestic animals.** *J Vet Diagn Invest* 2004; 16: 522–526.
- 4 Culp WTN, Drobatz KJ, Glassman MM, et al. **Feline visceral hemangiosarcoma.** *J Vet Intern Med* 2008; 22: 148–152.
- 5 Patnaik AK and Liu SK. **Angiosarcoma in cats.** *J Small Anim Pract* 1977; 18: 191–198.
- 6 Aupperle H, März I, Ellenberger C, et al. **Primary and secondary heart tumours in dogs and cats.** *J Comp Pathol* 2007; 136: 18–26.
- 7 Scavelli TD, Patnaik AK, Mehlhaff CJ, et al. **Hemangiosarcoma in the cat: retrospective evaluation of 31 surgical cases.** *J Am Vet Med Assoc* 1985; 187: 817–819.
- 8 Kerbel RS and Kamen BA. **The anti-angiogenic basis of metronomic chemotherapy.** *Nat Rev Cancer* 2004; 4: 423–436.
- 9 Gaspar TB, Henriques J, Marconato L, et al. **The use of low-dose metronomic chemotherapy in dogs – insight into a modern cancer field.** *Vet Comp Oncol* 2017; 15: 493–503.
- 10 Sharpe A, Cannon MJ, Lucke VM, et al. **Intestinal haemangiosarcoma in the cat: clinical and pathological features of four cases.** *J Small Anim Pract* 2000; 41: 411.
- 11 Bertazzolo W, Dell'Orco M, Bonfanti U, et al. **Canine angiosarcoma: cytologic, histologic, and immunohistochemical correlations.** *Vet Clin Pathol* 2005; 34: 28–34.
- 12 Ferrer L, Fondevila D, Rabanal RM, et al. **Immunohistochemical detection of CD31 antigen in normal and**

- neoplastic canine endothelial cells. *J Comp Pathol* 1995; 112: 319–326.
- 13 von Beust BR, Suter MM and Summers BA. **Factor VIII-related antigen in canine endothelial neoplasms: an immunohistochemical study.** *Vet Pathol* 1988; 25: 251.
 - 14 Reiman RA, Mauldin GE and Neal Mauldin G. **A comparison of toxicity of two dosing schemes for doxorubicin in the cat.** *J Feline Med Surg* 2008; 10: 324–331.
 - 15 Leo C, Stell A, Borrego J, et al. **Evaluation of low-dose metronomic (LDM) cyclophosphamide toxicity in cats with malignant neoplasia.** *J Feline Med Surg* 2014; 16: 671–678.
 - 16 Elmslie RE, Glawe P and Dow SW. **Metronomic therapy with cyclophosphamide and piroxicam effectively delays tumor recurrence in dogs with incompletely resected soft tissue sarcomas.** *J Vet Intern Med* 2008; 22: 1373–1379.