



Acute renal failure in an adult cat following oral administration of fosfomycin

Authors: Sakai, Yohei, Yoshida, Toshinori, Shibutani, Makoto, and Ohmori, Keitaro

Source: Journal of Feline Medicine and Surgery Open Reports, 4(2)

Published By: SAGE Publishing

URL: <https://doi.org/10.1177/2055116918786601>



Acute renal failure in an adult cat following oral administration of fosfomycin

Yohei Sakai, Toshinori Yoshida, Makoto Shibutani and Keitaro Ohmori

Journal of Feline Medicine and Surgery Open Reports
1–3

© The Author(s) 2018

Reprints and permissions:

sagepub.co.uk/journalsPermissions.nav

DOI: 10.1177/2055116918786601

journals.sagepub.com/home/jfmsopenreports

This paper was handled and processed by the European Editorial Office (ISFM) for publication in *JFMS Open Reports*



Abstract

Case summary A spayed female mixed breed cat of unknown age (presumably more than 9 years old), weighing 2.9 kg, was presented with a 4 day history of lethargy, anorexia and vomiting following oral administration of calcium fosfomycin (20 mg/kg q12h). A serum biochemical analysis revealed a dramatic increase in the levels of blood urea nitrogen (>140 mg/dl) and creatinine (15.3 mg/dl), and hypercalcaemia (13.1 mg/dl), hyperphosphataemia (13.3 mg/dl) and hyperkalaemia (6.1 mmol/l). The cat was hospitalised and treated with infusion therapy. However, the renal function and clinical signs did not improve with any treatment. The cat was euthanased upon the owner's request. Histopathological analysis of the kidneys revealed acute tubular necrosis in the cortex.

Relevance and novel information The present case report provides, for the first time, clinical and histopathological evidence for acute renal failure induced by oral administration of fosfomycin in an adult cat. It is highly advisable that fosfomycin should not be used in either young or adult cats.

Keywords: Adult cat, fosfomycin, acute tubular necrosis, acute renal failure

Accepted: 7 June 2018

Case description

A spayed female mixed-breed cat of unknown age (presumably >9 years old), weighing 2.9 kg, was presented with a 4 day history of lethargy, anorexia and vomiting (day 1). The cat had a history of bilateral ureteral calculi removed by surgical operation 1 month prior to the current presentation and hypertension that had been treated with oral administration of prazosin (0.17 mg/kg q12h Minipress [Pfizer]) for 2 months.

Bacterial cystitis was detected in the cat 14 days prior to the current presentation. Although bacterial identification was not performed, the antimicrobial susceptibility test revealed multidrug resistance to bacteria in the urine sample and fosfomycin was shown to be a susceptible antibiotic. Based on the result of the antimicrobial susceptibility test, oral administration of calcium fosfomycin (20 mg/kg q12h Fosmicin [Meiji Seika Pharma]) was initiated 7 days prior to the current presentation. The cat began to vomit 4 days after initiation of treatment with fosfomycin.

A serum biochemical analysis on day 1 detected a dramatic increase in the levels of blood urea nitrogen (BUN; >140 mg/dl; reference interval [RI] 17.6–32.8 mg/dl) and creatinine (15.3 mg/dl; RI 0.8–1.8 mg/dl), and hypercalcaemia (13.1 mg/dl; RI 8.8–11.9 mg/dl), hyperphosphataemia (13.3 mg/dl; RI 2.6–6.0 mg/dl) and hyperkalaemia (6.1 mmol/l; RI 3.4–4.6 mmol/l). In a serum biochemical analysis that was performed 3 weeks prior to day 1 of admission, the levels of BUN, creatinine and potassium were within normal reference intervals;

Cooperative Department of Veterinary Medicine, Faculty of Agriculture, Tokyo University of Agriculture and Technology, Tokyo, Japan

Corresponding author:

Keitaro Ohmori DVM, PhD, Cooperative Department of Veterinary Medicine, Faculty of Agriculture, Tokyo University of Agriculture and Technology, 3-5-8 Saiwai-cho, Fuchu, Tokyo 183-8509, Japan

Email: k-ohmori@cc.tuat.ac.jp



Creative Commons Non Commercial CC BY-NC: This article is distributed under the terms of the Creative Commons

Attribution-NonCommercial 4.0 License (<http://www.creativecommons.org/licenses/by-nc/4.0/>) which permits non-commercial use, reproduction and distribution of the work without further permission provided the original work is attributed as specified on the SAGE and Open Access pages (<https://us.sagepub.com/en-us/nam/open-access-at-sage>).

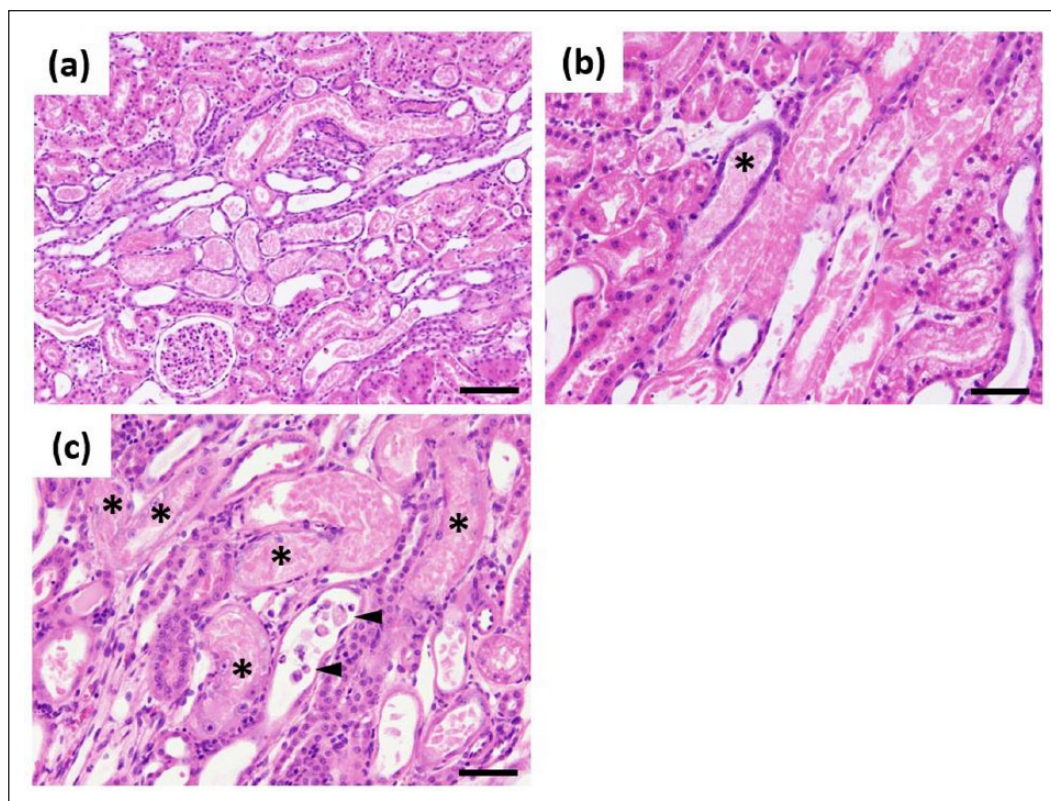


Figure 1 Histopathological changes in the kidneys. (a) Acute tubular necrosis was observed in the cortex. A glomerulus appeared to be normal. (b) Acute tubular necrosis and regeneration (*) were observed in the renal tubules at the pars recta. Eosinophilia of cytoplasm with intraluminal debris was evident in several tubules. Regenerative basophilic epithelial cells were found in the vicinity of tubular necrotic lesions. (c) Regeneration was observed in renal tubules with acute tubular necrosis. Several necrotic renal tubules were lined by variable-sized nuclei with prominent nucleoli and filled with eosinophilic cell debris (*; see karyomegaly in several tubules). Intraluminal cell debris with dense nuclei was also noted (arrowheads). Haematoxylin and eosin stain. Bar = 100 μ m (a) and 50 μ m (b,c)

those of calcium and phosphate were not measured in the analysis.

An abdominal ultrasound on day 1 did not illustrate any specific findings, including calculi in the right and left kidneys and both ureters. Based on the clinical course and a serum biochemical analysis, the cat was diagnosed with acute renal failure (ARF) induced by oral administration of fosfomycin.

The cat was hospitalised on day 1 and treated with saline infusion. Continuous infusion of bucladesine sodium (15 μ g/kg/min Actosin [Daiichi Sankyo]), diltiazem hydrochloride (2 μ g/kg/min Diltiazem Hydrochloride [Nichi-Iko Pharmaceutical]), dopamine hydrochloride (3–6 μ g/kg/min Dominin [Nippon Shinyaku]), dobutamine hydrochloride (3–6 μ g/kg/min Dobutrex [Shionogi]) and/or carperitide (0.1 μ g/kg/min Hanp [Daiichi Sankyo]) was also performed, depending on blood pressure, urine volume, and the levels of BUN and creatinine. When oliguria was observed, the cat was administered with furosemide (0.5–4 mg/kg Lasix [Sanofi]) and/or mannitol (0.5 g/kg

Mannitol injection [Yoshindo]) several times. However, the renal function and clinical signs did not improve with any treatment. On day 6, the cat was euthanased upon the owner's request.

After euthanasia, the right and left kidneys of the cat were subjected to pathological analysis. No macroscopic findings were detected in the kidneys. The kidneys were fixed in 10% neutral-buffered formalin, processed according to standard protocols and embedded in paraffin. Paraffin sections (5 μ m) were stained with haematoxylin and eosin. Renal tubular necrosis was diffusely observed in the cortex (Figure 1a). Eosinophilia of renal tubular cells with a small amount of pyknotic nuclear debris was observed especially at the pars recta (Figures 1b,c). Flattened tubular cells with variable sized nuclei and basophilic cytoplasm were occasionally observed with evidence of karyomegaly (Figures 1b,c). Granular and hyaline casts were frequently seen in the cortex and medulla. Interstitial lymphocyte infiltration was sporadically observed, but renal tubular lipidosis as seen in healthy cats was obscure (Figures 1a–c).

Discussion

A previous study demonstrated a nephrotoxic effect of fosfomycin on young cats.¹ Oral administration of calcium fosfomycin (20 mg/kg q12h) in healthy young cats for 3 days increased the serum levels of creatinine significantly and those of BUN less significantly; however, the young cats did not show any clinical signs associated with uraemia, such as anorexia and vomiting.¹ Histopathological analysis revealed tubular necrosis, disappearance of tubular cells and rearrangement of eosinophilic non-structural material in the kidneys of the young cats.¹ In healthy adult cats, oral or intravenous administration of fosfomycin did not increase the levels of BUN and creatinine significantly. However, histopathological changes were observed in the kidneys of the adult cats,¹ suggesting a possible nephrotoxic effect of fosfomycin on adult cats.

The present case report provides, for the first time, clinical and histopathological evidence for fosfomycin-induced ARF in an adult cat. The cat began to vomit 4 days after initiation of treatment with fosfomycin. It is, therefore, conceivable that the renal function was damaged shortly after oral administration of fosfomycin.

The histopathological changes observed in this case were consistent with renal tubular necrosis in cats.²⁻⁴ Renal tubular necrosis was typically identified as cytoplasmic hyper eosinophilia, but the near lack of nuclear debris implied that nuclear karyolysis rather than pyknosis was prominent. The findings suggested a few days or a week-long course of renal damage.⁴ This interpretation was in accordance with the evidence of tubular regeneration; ie, flattened basophilic tubular cells that were concomitantly observed in acute tubular necrosis of cats.^{2,5}

When ARF developed, the cat was being orally administered with both fosfomycin and prazosin. Thus, we cannot rule out the possibility that prazosin may have also affected the renal function in the cat. As prazosin had been administered to the cat for approximately 2 months prior to the use of fosfomycin, it is very unlikely

that a single administration of prazosin induced ARF based on the clinical course and histopathological findings observed. Alternatively, it is possible that the concurrent administration of fosfomycin and prazosin might have induced ARF in the cat, although this effect has never been reported previously. Further studies will be required to investigate the possible nephrotoxic effect of concurrent use of fosfomycin and prazosin in cats.

Conclusions

Not all adult cats develop ARF after administration of fosfomycin. As the mechanisms underlying the nephrotoxicity of fosfomycin in cats remain unclear, it is impossible to distinguish between fosfomycin-sensitive and non-sensitive cats. Therefore, it is highly advisable that fosfomycin should not be used in either young or adult cats.

Conflict of interest The authors declared no potential conflicts of interest with respect to the research, authorship, and/or publication of this article.

Funding The authors received no financial support for the research, authorship, and/or publication of this article.

References

- 1 Fukata T, Imai N and Shibata S. **Acute renal insufficiency in cats after fosfomycin administration.** *Vet Rec* 2008; 163: 337–338.
- 2 Cianciolo RE, Rhodes JL, Haskins ME, et al. **Renal failure associated with mucopolysaccharidosis type I in a cat from a MPS I research colony.** *Comp Med* 2011; 61: 441–444.
- 3 Tokarz D, Poppenga R, Kaae J, et al. **Amanitin toxicosis in two cats with acute hepatic and renal failure.** *Vet Pathol* 2012; 49: 1032–1035.
- 4 Cianciolo RE and Mohr FC. **Urinary system.** In: Maxie MG (ed). *Pathology of domestic animals.* Vol 2. 6th ed. St Louis, MO: Elsevier, 2016, pp 376–464.
- 5 Schmiedt CW, Brainard BM, Hinson W, et al. **Unilateral renal ischemia as a model of acute kidney injury and renal fibrosis in cats.** *Vet Pathol* 2016; 53: 87–101.