

Beak Deformities in Northwestern Crows: Evidence of a Multispecies Epizootic

Authors: Hemert, Caroline Van, and Handel, Colleen M.

Source: *The Auk*, 127(4) : 746-751

Published By: American Ornithological Society

URL: <https://doi.org/10.1525/auk.2010.10132>



The Auk 127(4):746–751, 2010
© The American Ornithologists' Union, 2010.
Printed in USA.

BEAK DEFORMITIES IN NORTHWESTERN CROWS: EVIDENCE OF A MULTISPECIES EPIZOOTIC

CAROLINE VAN HEMERT^{1,2,3} AND COLLEEN M. HANDEL¹

¹U.S. Geological Survey, Alaska Science Center, 4210 University Drive, Anchorage, Alaska 99508, USA; and

²Department of Biology and Wildlife, Institute of Arctic Biology, University of Alaska Fairbanks, P.O. Box 757000, Fairbanks, Alaska 99775, USA

ABSTRACT.—Beak abnormalities are rare among adult birds and, typically, are not widespread in a given population, within a region, or across multiple species. A high concentration of beak deformities was recently documented in Black-capped Chickadees (*Poecile atricapillus*) and other resident avian species in Alaska. We describe a parallel condition in Northwestern Crows (*Corvus caurinus*) that signals the emergence of a multispecies epizootic. On the basis of 186 Northwestern Crows captured at six sites in Alaska during 2007 and 2008, we estimated the prevalence of beak deformities in adults to be $16.9 \pm 5.3\%$, the highest rate of gross deformities ever recorded in a wild bird population. Prevalence varied among sites and was as high as 36% on the Kenai Peninsula, which suggests possible epizootic clusters. We also documented beak abnormalities in an additional 148 Northwestern Crows in south-central and southeastern Alaska and in 64 crows near Vancouver, British Columbia, and Puget Sound, Washington, a region where both Northwestern Crows and American Crows (*C. brachyrhynchos*) occur. The increase in frequency and distribution of crows observed with abnormal beaks throughout the Pacific Northwest since the late 1990s indicates a geographic expansion of this problem. Affected crows exhibited elongated and often crossed beaks that were morphologically similar to deformities documented in Black-capped Chickadees and other species in Alaska over approximately the same period. Additional research is needed to determine the etiology and potential adverse effects on bird populations affected by this disorder. *Received 21 May 2010, accepted 15 July 2010.*

Key words: abnormality, Alaska, American Crow, avian keratin disorder, beak, British Columbia, *Corvus brachyrhynchos*, *C. caurinus*, deformity, emerging disease, keratin, Northwestern Crow, Pacific coast, Washington.

Deformidades del Pico en *Corvus caurinus*: Evidencia de un Evento Epizootico en Varias Especies

RESUMEN.—Las anomalías del pico son poco frecuentes entre las aves adultas y típicamente no se encuentran difundidas ampliamente en una población o región, ni entre varias especies. Recientemente se documentó una alta concentración de deformidades en el pico en *Poecile atricapillus* y en otras especies de aves residentes en Alaska. Describimos una condición paralela en el cuervo *Corvus caurinus*, que señala la emergencia de un evento epizootico multiespecífico. Con base en 186 cuervos capturados en seis sitios de Alaska en 2007 y 2008, estimamos que la prevalencia de las deformidades del pico entre los adultos es del $16.9 \pm 5.3\%$, el valor bruto más alto de deformidades que se ha documentado en una población de aves silvestres. La prevalencia varió entre sitios y alcanzó el 36% en la península de Kenai, lo que sugiere la posibilidad de que existan conglomerados epizooticos. También documentamos anomalías en el pico en 148 individuos adicionales de esta especie del sur-centro y sureste de Alaska y en 64 individuos de cerca a Vancouver, British Columbia y Puget Sound, Washington, una región en donde se encuentran tanto *C. caurinus* como *C. brachyrhynchos*. El aumento en la frecuencia y distribución de cuervos con picos anormales observados en todo el Pacífico noroeste desde finales de la década del noventa indica que este problema se ha extendido geográficamente. Los cuervos afectados presentaban picos elongados y frecuentemente cruzados, que eran morfológicamente similares a los picos deformados que se han documentado en *P. atricapillus* y en otras especies de Alaska a lo largo del mismo período aproximado. Se necesita más investigación para determinar la etiología y los efectos adversos potenciales de este desorden en las poblaciones de aves afectadas.

³E-mail: cvanhemert@usgs.gov

The Auk, Vol. 127, Number 4, pages 746–751. ISSN 0004-8038, electronic ISSN 1938-4254. © 2010 by The American Ornithologists' Union. All rights reserved. Please direct all requests for permission to photocopy or reproduce article content through the University of California Press's Rights and Permissions website, <http://www.ucpressjournals.com/reprintInfo.asp>. DOI: 10.1525/auk.2010.10132

HIGH RATES OF gross deformities in wildlife populations often serve as indicators of underlying environmental health problems.^{1,2,3,4} An epizootic of beak deformities, referred to as “avian keratin disorder,” has been documented in Black-capped Chickadees (*Poecile atricapillus*) in Alaska during the past decade and afflicts an average of 6.5% of the adult population annually.⁵ In affected birds, the keratin layer of the beak becomes overgrown, resulting in noticeably elongated, often crossed presentation, sometimes accompanied by abnormal skin and feathers. Morphologically similar deformities have recently appeared in other, primarily resident Alaskan species, including Northwestern Crows (*Corvus caurinus*) throughout their range in coastal Alaska.⁵ Beak abnormalities have also been documented in coastal British Columbia and Washington, where the ranges of Northwestern Crows and American Crows (*C. brachyrhynchos*) overlap.^{6,7} The presence of deformities in crows suggests that this epizootic is not restricted to a discrete geographic area or a single species and that etiological agents may occur across a broad environmental gradient, affecting both terrestrial and coastal systems. The primary objectives of our study were to estimate the prevalence and describe the gross morphology of beak deformities in Alaskan Northwestern Crow populations in relation to recent findings in Black-capped Chickadees. We also investigated the geographic distribution of the problem by compiling and analyzing confirmed reports of beak abnormalities in all species of crows in North America.

PREVALENCE

Between March 2007 and April 2008, we captured, measured, and examined a total of 186 Northwestern Crows at six sites in coastal Alaska to characterize and estimate the prevalence of beak deformities in the population. We documented 19 adult Northwestern Crows with beaks classified as deformed on the basis of our prediction interval criteria (for further information, see Supplementary Methods and Table S1). We estimated an overall prevalence of $16.9 \pm 5.3\%$ among adults across all sites (Table 1), which exceeds an expected background level of deformity by >30 times.^{8,9}

Together, the prevalence of beak deformities in adult Northwestern Crows and that in Black-capped Chickadees ($6.5\%^5$) in Alaska represent the highest rates of gross deformities ever recorded in wild bird populations. It is possible that these estimates

TABLE 1. Estimated prevalence of beak deformities in Northwestern Crows captured at six sites in Alaska during winter in 2007 and 2008.

Site	Juveniles		Adults	
	Percentage deformed	<i>n</i>	Percentage deformed \pm SE	<i>n</i>
All sites ^a	0	50	16.9 ± 5.3	135
Seward	0	10	33.3 ± 11.1	18
Kenai	0	10	35.7 ± 12.8	14
Homer	0	1	3.2 ± 3.2	31
Valdez	0	9	10.7 ± 5.8	28
Juneau	0	8	14.3 ± 7.6	21
Haines	0	12	4.3 ± 4.3	23

^aOverall prevalence was calculated as the mean of the prevalence across the six sites.

of prevalence are positively biased because trapping of both species relied on baiting with supplemental food, which might attract a greater proportion of birds whose abnormal beaks impair natural foraging. However, both Northwestern Crows^{6,10,11} and Black-capped Chickadees^{12,13} in their normal state are generalist predators that are highly flexible behaviorally. These natural traits and the large numbers of birds with grossly deformed beaks observed throughout the region suggest that even if a trap-related bias occurred, it was unlikely to account for the unusually high prevalence documented in these two species.

We found that the occurrence of beak deformities in adult Northwestern Crows was independent of sex ($P = 0.806$, $z = -0.245$, $n = 135$) but differed between age classes in that we observed no evidence of beak deformities in captured juveniles ($n = 50$; Table 1). Age- and sex-related patterns of this epizootic appear to be very similar between Black-capped Chickadees and Northwestern Crows. In Black-capped Chickadees, deformities occur almost exclusively among adults and at only a slightly higher rate among females than among males.⁵

We detected geographic variation in the prevalence of deformities in Northwestern Crows across our study locations ($P = 0.043$, $z = 2.024$, $n = 135$; Table 1), with extremely high rates in Kenai (36%) and Seward (33%). Although sample sizes of individuals trapped per site were relatively small, differences in prevalence among sites suggest the occurrence of epizootic clusters, as has been noted in Black-capped Chickadees.⁵ Morphologically similar beak deformities also occur in a wide suite of other resident species, and we have documented Black-capped Chickadees and as many as eight other species with beak deformities at or near each of our Northwestern Crow study locations (C. M. Handel unpubl. data). Seward and Kenai may represent relative “hotspots” of this disorder in Northwestern Crows, although possible reasons for such spatial distribution are currently unknown. These two sites are the closest of our sampling locations in geographic proximity to the known epicenter of avian keratin disorder in Black-capped Chickadees,⁵ and abnormalities in other taxa have also been observed in this region of Alaska. An elevated prevalence of eye and skeletal abnormalities of unknown etiology in Wood Frogs (*Rana sylvatica*) was documented on the Kenai National Wildlife Refuge, near the city of Kenai.¹⁴ Although no link has been established between deformities in other taxa and avian keratin disorder, spatial overlap of these abnormalities may warrant concern about underlying environmental factors in this region.

MORPHOLOGY OF BEAK DEFORMITIES

We documented three distinct classes of deformities: elongation of the upper beak, elongation of the lower beak, and elongation of both the upper and lower beaks, all of which involve some form of overgrowth and apparently reflect different presentations of avian keratin disorder in Northwestern and American crows (Fig. 1). Measurements from our study and other reports compiled in our observation database of beak deformities indicate that the most common morphology associated with this condition in crows includes overgrowth of the upper beak (Fig. 1C, D and Table 2). Only four of the individuals that we captured in this study had an abnormally elongated lower beak and a pronounced underbite in relation to the upper beak (Fig. 1E, F). Among birds with normal




FIG. 1. Examples of beak deformities in crows in the Pacific Northwest. Severe overgrowth and crossing of upper and lower beaks in crows from (A) Juneau, Alaska (photo by Ron Horn), and (B) Seward, Alaska (photo by Bill O'Brien). Elongated upper beak with overbite from (C) Edmonds, Washington (photo by Kevin Mack), and (D) Juneau, Alaska (U.S. Geological Survey photo). Elongated lower beak with underbite from (E) Seattle, Washington (photo by John Huckabee), and (F) Valdez, Alaska (U.S. Geological Survey photo). All birds from Alaska are Northwestern Crows; those from Washington could be Northwestern or American crows.

beaks, minor (<5 mm) overbite was relatively common but we did not observe any measurable underbite. Four captured Northwestern Crows exhibited elongation of both the upper and lower beaks (Table 2). Other abnormal physical characteristics of the beak often accompanied gross deformities in affected individuals. Among birds captured with deformed beaks, 42% ($n = 8$) had a gap of >0.5 mm between the upper and lower beaks and 21% ($n = 4$)

showed a lateral offset, which resulted in crossed tips (cf. Fig. 1A, B). Birds with normal beaks exhibited gaps of >0.5 mm (16%; $n = 18$) and crossing (2%; $n = 2$) less frequently. Irregularities of the keratin covering the beak (rhamphotheca), including serrated edges, ridges, thickening, and flattening of the tomium, occurred in 84% ($n = 16$) of deformed beaks in contrast to only 7% ($n = 8$) of normal beaks. Beak deformities in Black-capped Chickadees and other affected species in Alaska demonstrate analogous morphologies, highlighting similarities in expression of avian keratin disorder across species.⁵

We documented several other conditions that affect keratinized tissues in Northwestern Crows with abnormal beaks, including abnormally long and curled claws (11%; $n = 2$); dermatoses, observed as dry, flaky, and/or reddened skin on the head and abdomen (16%; $n = 3$); leg scales that appeared to be thickened and sloughed easily (11%; $n = 2$); and evidence of ectoparasites (21%; $n = 4$). In birds with normal beaks, we noted abnormal claws (2%; $n = 2$), dermatoses (3%; $n = 3$), and ectoparasites (3%; $n = 4$) rarely and observed no evidence of abnormal leg scales. Two individuals with beak deformities captured in our study also had slightly abnormal plumage coloration, including white or reddish-brown feathers in the loreal and occipital regions. A subset of Black-capped Chickadees with beak deformities exhibited similar abnormalities of keratinized tissues.⁵ Presence of elongated claws, dermatoses, and abnormal feathers and leg scales among affected birds suggests the possibility of a systemic keratin disorder in which an overgrown beak is the most grossly evident sign. Alternatively, some of these conditions could result from altered function of abnormal beaks and may be related to compromised preening or feeding behavior or reduced nutritional status.

NUMBERS AND DISTRIBUTION OF SIGHTINGS

In reviewing all records of deformities from North America,⁵ we documented observations of 148 individual Northwestern Crows with grossly elongated or crossed beaks in Alaska between the 1980s (specific dates unknown) and 2009, with most observed since 1997 (Figs. 2 and 3). We also confirmed reports of 64 crows from Washington and British Columbia (2001–2009) but were unable to determine whether they were Northwestern or American crows because of the species' overlapping ranges. In comparison, we received only five reports of abnormal beaks among crows

TABLE 2. Morphometrics^a of birds with normal beaks compared to those with deformity on upper, lower, or both parts of the beak among adult Northwestern Crows captured in Alaska during winter in 2007 and 2008.

Status	<i>n</i>	Nares to tip (mm)		Gonys (mm)		Relative overgrowth (mm)	
		Mean ± SE	Minimum–maximum	Mean ± SE	Minimum–maximum	Mean ± SE	Minimum–maximum
Normal							
Males	60	34.6 ± 0.04	29.8–39.6	26.5 ± 0.03	22.1–31.1	2.2 ± 0.02	0–4.5
Females	56	33.6 ± 0.04	28.7–40.1	25.6 ± 0.03	20.2–30.7	2.3 ± 0.02	0–4.9
Upper deformity	11	40.3 ± 0.3	36.9–45.8	28.0 ± 0.2	24.7–30.8	7.8 ± 0.3	5.5–14.1
Lower deformity	4	32.6 ± 1.5	23.9–36.8	35.4 ± 1.7	31.5–45.5	–8.4 ± 2.8	–25.3 to –0.6
Upper and lower deformity	4	42.3 ± 0.7	39.0–45.4	32.3 ± 0.2	31.1–33.2	5.4 ± 0.5	3.3–8.4

^aNares to tip measured from anterior end of right nares to tip of upper beak; gonys measured from central notch on lower beak to tip; relative overgrowth calculated as amount tip of upper beak exceeds (+) or is shorter than (–) tip of lower beak (overbite – underbite; see Supplementary Information).

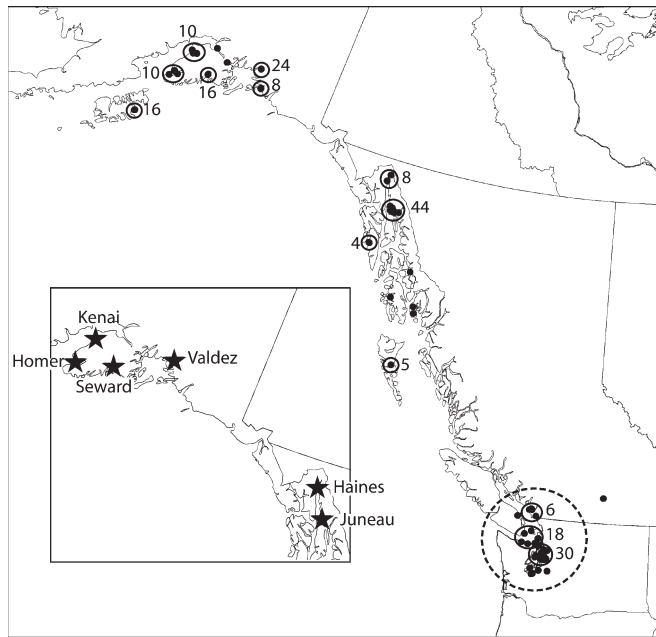


FIG. 2. Map showing distribution of all documented beak deformities (black dots) of Northwestern Crows in Alaska, and of what could be Northwestern or American crows where their distributions overlap in southern British Columbia and northern Washington. Numeric subtotals adjacent to open circles show minimum numbers of individuals with beak deformities for areas where there were multiple observations. Inset map shows study sites (stars) in Alaska where we estimated the prevalence of deformities in Northwestern Crows during winter 2007 and 2008. Most reports from southern British Columbia and northwestern Washington (dashed circle) occurred within a known area of overlap between ranges of Northwestern and American crows.

outside of this region: one American Crow from Ontario in 2001, one American Crow from Quebec in 2005, and three American Crows or Fish Crows (*C. ossifragus*) from Florida between 2005 and 2007 (because of overlapping ranges, we could not conclusively determine species). These records, in combination with findings in Black-capped Chickadees,⁵ suggest that avian keratin disorder occurs across multiple species and habitat types but is currently concentrated in Alaska and other areas of the Pacific Northwest. Additional sampling of crow populations outside of the Pacific Northwest and examination of recently collected museum specimens from across North America would help to verify this apparent geographic pattern. Interannual patterns of documented deformities as well as comparison of our data with historical museum specimens (*C. Van Hemert unpubl. data*) and live capture records¹⁵ (*R. Ha unpubl. data*) indicate that avian keratin disorder is a relatively new phenomenon in Northwestern Crows. Greater observer effort may have contributed in part to an increase in sightings over the past decade, but a dearth of published records or anecdotal reports of gross beak deformities prior to the late 1990s suggests recent emergence of this problem. A marked increase in the prevalence of abnormal beaks in Black-capped Chickadees has been observed over approximately the

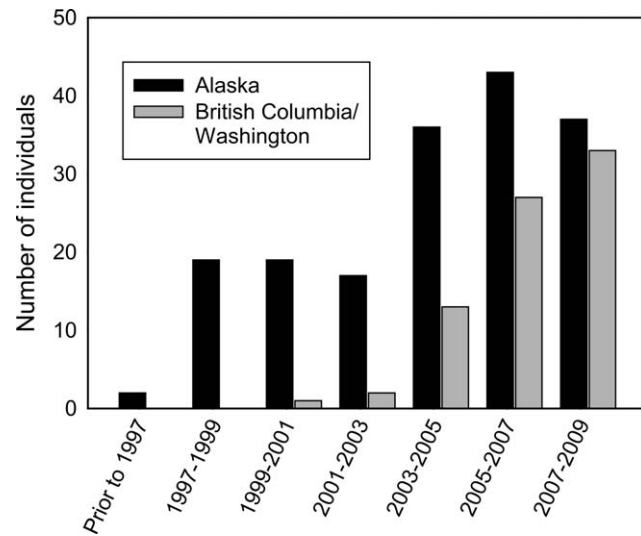


FIG. 3. Numbers of sightings of Northwestern Crows in Alaska (black bars) and Northwestern or American crows in British Columbia and Washington (gray bars) between 1980 and 2009. Summaries for each period begin on 1 July of the first year listed and are tallied through 30 June of the following year listed.

same period,⁵ which indicates nearly synchronous timing of this disorder in the two species.

Despite similarities in epizootic patterns among Northwestern Crows and Black-capped Chickadees, there also appears to be some discrepancy in the geographic distribution between the two species, with occurrence south of Alaska being relatively more common in crows than in chickadees. Our compilation of observations of beak deformities from across the continent indicates that affected Northwestern and American crows occur with much greater frequency in British Columbia and Washington than affected Black-capped Chickadees. Only 31 Black-capped Chickadees with beak abnormalities were documented anywhere outside of Alaska, including 5 from the Puget Sound area of Washington, compared with >2,000 affected individuals within Alaska.⁵ Black-capped Chickadees and Northwestern and American crows are gregarious and common visitors to feeders and other human food sources, and it is unlikely that large numbers of grossly abnormal beaks would go unnoticed in these species in populated areas.

Reports of beak deformities in Northwestern Crows occurred earlier in Alaska than in more southern parts of their coastal range, which suggests an increase in the regional distribution of avian keratin disorder. Affected Black-capped Chickadees have also been reported across a growing geographic area within Alaska.⁵ If movements of individual birds contribute to the transmission of this condition, differences between species in the geographic spread of deformities might reflect differences in their scales of movement. Individual Black-capped Chickadees have restricted ranges, averaging 10–15 ha,^{16,17,18} and distances between breeding and wintering sites are typically <1 km.¹⁹ In comparison, although movement patterns of Northwestern Crows, particularly in Alaska, have not been well described, resightings of

color-marked individuals from the present study indicate that movements of >40 km are not unusual. In British Columbia, median distances for both juvenile dispersal and seasonal movements were ~13 km but ranged as far as 177 km.⁶ A better understanding of relatedness between Alaskan and more southern populations of crows would help determine the degree to which movement patterns could contribute to exposure to or transfer of etiological agents.

Although the etiology of the deformities is not yet known, investigating occurrence across multiple species provides insights about possible causes. The similarity in physical characteristics of the deformities and geographic distribution supports the hypothesis of a common etiology. Black-capped Chickadees, Northwestern Crows, and other resident species seem to be disproportionately affected along the Pacific Northwest coast compared with the rest of North America, although many individuals with beak deformities have also been observed in interior Alaska.⁵ This distributional pattern suggests that factors unique to the region may contribute to the occurrence of avian keratin disorder. However, if causative agents are environmental in origin, such as anthropogenic toxicants or regional nutrient limitations, they would appear to be relatively diffuse and not easily traceable to specific locations or sources. Affected areas are geographically widespread, many of the affected populations are relatively isolated, and no unifying features (such as habitat type, extent of human development, proximity to coast, etc.) have been identified. Sampling of Northwestern Crows in areas isolated from human communities would help confirm whether birds with beak deformities occur away from anthropogenic influences, including food resources, potential point-source environmental contaminants, or other localized factors, as has been suggested in the case of Black-capped Chickadees.⁵ If infectious disease or parasites are implicated in the deformities, we expect the agent(s) to be transient across a broad geographic area. Because both Black-capped Chickadees and Northwestern Crows are year-round residents with generally restricted seasonal movements between wintering and breeding areas, it is unlikely that large-scale or migratory movements of individuals of either species could have been directly responsible for such transport.

Lack of knowledge about causative factors and subsequent physiological changes associated with beak deformities emphasizes the need for additional research into the pathology of avian keratin disorder. Without a diagnostic test, we are limited in our ability to detect deformities in wild populations and must rely on observation of gross signs. As such, we cannot identify individuals early in the disease phase or birds with incipient deformities. Similarly, a complete morphological assessment, including histological examination of affected tissues, is necessary to determine whether the same physiological and cellular changes are responsible for deformities in both Black-capped Chickadees and Northwestern Crows. Birds with severe beak overgrowth clearly experience functional limitations, including difficulty feeding and preening, and may also be subject to other underlying problems associated with abnormal keratin growth. Additional research, including investigation of pathology and possible mechanisms associated with gross beak deformities, is required to develop a comprehensive understanding of this multispecies epizootic and its potential implications for avian populations.

METHODS SUMMARY

As part of a larger study of beak deformities in Alaska, we began in 1998 to solicit published and unpublished information to document the occurrence and distribution of North American crow species with apparently abnormal beaks, excluding those resulting from trauma or easily identifiable diseases such as avian pox. We searched the published literature, presented requests for information to national and Canadian media, collaborated with other researchers conducting studies on crows in North America, and monitored online avian resources.⁵ We pooled observations of Northwestern and American crows from British Columbia and Washington, where their ranges overlap and they may hybridize.^{6,7} We estimated the prevalence of beak deformities in Northwestern Crow populations during late winter in 2007 and 2008 at six accessible coastal sites across south-central and southeastern Alaska: Seward (60.11°N, 149.44°W), Kenai (60.55°N, 151.23°W), Homer (59.64°N, 151.54°W), Valdez (61.12°N, 146.35°W), Haines (59.23°N, 135.44°W), and Juneau (58.38°N, 134.64°W; Fig. 2). These sampling sites support small to moderate-sized human population centers ranging from <3,000 to >30,000 residents, host relatively large numbers of Northwestern Crows ($n > 50$), and have both natural intertidal prey (mussels and other marine invertebrates) and anthropogenic food items (discarded fish waste and urban refuse) seasonally available to Northwestern Crows. Given the lack of historical data on beak morphometrics, we developed an iterative statistical method using measurements from the relatively large sample of apparently normal birds in our study ($n = 115$) to identify prediction intervals beyond which a beak would be considered deformed. Please see the online Supplementary Methods for additional details about field and analytical methods (<http://caliber.ucpress.net/doi/suppl/10.1525/auk.2010.10132>).

ACKNOWLEDGMENTS

Funding for this study was provided by the U.S. Geological Survey, the National Science Foundation Graduate Research Fellowship Program, and the University of Alaska Foundation Angus Gavin Memorial Bird Research Grant. We thank J. Terenzi and P. Farrell for their help in the field. L. Pajot provided assistance with capture efforts and genetic analyses. T. C. Comet shared drawings for trap designs. R. Ha shared data from Northwestern Crow captures in British Columbia. We would also like to acknowledge the many residents and birdwatchers who reported sightings and shared photographs of birds with abnormal beaks in their local communities. Thanks to T. O'Hara, D. O'Brien, S. Sharbaugh, and J. Blake for committee support from the University of Alaska Fairbanks. C. Benkman, P. Flint, S. Matsuoka, T. L. Tibbitts, and an anonymous reviewer provided helpful comments that improved the manuscript. Any use of trade, product, or firm names in this publication is for descriptive purposes only and does not imply endorsement by the U.S. Government.

LITERATURE CITED

1. OHLENDORF, H. M., D. J. HOFFMAN, M. K. SAIKI, AND T. W. ALDRICH. 1986. Embryonic mortality and abnormalities of aquatic

- birds: Apparent impacts of selenium from irrigation drainwater. *Science of the Total Environment* 52:49–63.
2. LUDWIG, J. P., H. KURITA MATSUBA, H. J. AUMAN, M. E. LUDWIG, C. L. SUMMER, J. P. GIESY, D. E. TILLITT, AND P. D. JONES. 1996. Deformities, PCBs, and TCDD-equivalents in Double-crested Cormorants (*Phalacrocorax auritus*) and Caspian Terns (*Hydroprogne caspia*) of the upper Great Lakes 1986–1991: Testing a cause-effect hypothesis. *Journal of Great Lakes Research* 22:172–197.
 3. JOHNSON, P. T. J., J. M. CHASE, K. L. DOSCH, R. B. HARTSON, J. A. GROSS, D. J. LARSON, D. R. SUTHERLAND, AND S. R. CARPENTER. 2007. Aquatic eutrophication promotes pathogenic infection in amphibians. *Proceedings of the National Academy of Sciences USA* 104:15781–15786.
 4. SUN, P. L., W. E. HAWKINS, R. M. OVERSTREET, AND N. J. BROWN-PETERSON. 2009. Morphological deformities as biomarkers in fish from contaminated rivers in Taiwan. *International Journal of Environmental Research and Public Health* 6:2307–2331.
 5. HANDEL, C. M., L. M. PAJOT, S. M. MATSUOKA, C. VAN HEMERT, J. TERENCE, S. L. TALBOT, D. M. MULCAHY, C. U. METEYER, AND K. A. TRUST. 2010. Epizootic of beak deformities among wild birds in Alaska: An emerging disease in North America? *Auk* 127:882–898.
 6. VERBEEK, N. A. M., AND R. W. BUTLER. 1999. Northwestern Crow (*Corvus caurinus*). In *The Birds of North America*, no. 407 (A. Poole and F. Gill, Eds.). Birds of North America, Philadelphia.
 7. VERBEEK, N. A. M., AND C. CAFFREY. 2002. American Crow (*Corvus brachyrhynchos*). In *The Birds of North America*, no. 647 (A. Poole and F. Gill, Eds.). Birds of North America, Philadelphia.
 8. HICKS, L. E. 1934. Individual and sexual variations in the European Starling. *Bird-Banding* 5:103–118.
 9. CRAVES, J. A. 1994. Passerines with deformed bills. *North American Bird Bander* 19:14–18.
 10. PETERSON, C. A., S. L. LEE, AND J. E. ELLIOTT. 2001. Scavenging of waterfowl carcasses by birds in agricultural fields of British Columbia. *Journal of Field Ornithology* 72:150–159.
 11. O'BRIEN, E. L., A. E. BURGER, AND R. D. DAWSON. 2005. Foraging decision rules and prey species preferences of Northwestern Crows (*Corvus caurinus*). *Ethology* 111:77–87.
 12. SMITH, S. M. 1991. *The Black-capped Chickadee: Behavioral Ecology and Natural History*. Cornell University Press, Ithaca, New York.
 13. WILSON, W. H., JR. 2001. The effects of supplemental feeding on wintering Black-capped Chickadees (*Poecile atricapilla*) in central Maine: Population and individual responses. *Wilson Bulletin* 113:65–72.
 14. REEVES, M. K., C. L. DOLPH, H. ZIMMER, R. S. TJEERDEMA, AND K. A. TRUST. 2008. Road proximity increases risk of skeletal abnormalities in Wood Frogs from National Wildlife Refuges in Alaska. *Environmental Health Perspectives* 116:1009–1014.
 15. JOHNSTON, D. W. 1961. *The Biosystematics of American Crows*. University of Washington Press, Seattle.
 16. ODUM, E. P. 1942. Annual cycle of the Black-capped Chickadee—3. *Auk* 59:499–531.
 17. GLASE, J. C. 1973. Ecology of social organization in the Black-capped Chickadee. *Living Bird* 12:235–267.
 18. SMITH, S. M. 1993. Black-capped Chickadee (*Poecile atricapillus*). In *The Birds of North America*, no. 39 (A. Poole, P. Stettenheim, and F. Gill, Eds.). Academy of Natural Sciences, Philadelphia, and American Ornithologists' Union, Washington, D.C.
 19. WEISE, C. M., AND J. R. MEYER. 1979. Juvenile dispersal and development of site-fidelity in the Black-capped Chickadee. *Auk* 96:40–55.

Associate Editor: M. T. Murphy