



Infraspinatus muscle necrosis in a cat with primary hyperaldosteronism

Authors: Otani, Go, and Ohta, Hiroshi

Source: Journal of Feline Medicine and Surgery Open Reports, 10(2)

Published By: SAGE Publishing

URL: <https://doi.org/10.1177/20551169241282737>



Infraspinatus muscle necrosis in a cat with primary hyperaldosteronism

Go Otani^{1,2} and Hiroshi Ohta^{1,3}

Journal of Feline Medicine and Surgery Open Reports
1–5

© The Author(s) 2024

Article reuse guidelines:

sagepub.com/journals-permissions

DOI: 10.1177/20551169241282737

journals.sagepub.com/home/jfmsopenreports

This paper was handled and processed

by the European Editorial Office (ISFM)

for publication in *JFMS Open Reports*



Abstract

Case summary Persistent and progressive weakness secondary to hypokalaemia, that is, hypokalaemic polymyopathy, is one of the most common clinical signs of primary hyperaldosteronism (PHA). Herein, we report a case of PHA with infraspinatus muscle necrosis. A 5-year-old castrated male domestic shorthair cat presented with a history of polyuria and polydipsia, decreased activity, staggering gait, difficulty in jumping and inward rotation of both forelimbs. Blood examination revealed hypokalaemia, increased serum creatinine kinase activity and high serum aldosterone concentration. Abdominal ultrasonography and CT revealed an enlarged right adrenal gland. Post-contrast thoracic CT showed peripheral contrast enhancement and a non-enhanced centre in the bilateral infraspinatus muscles. From the day of initial presentation, the cat was started on oral potassium replacement therapy. On day 17, the right adrenal gland was surgically resected and the left infraspinatus muscle was biopsied. Histopathological examination confirmed the presence of an adrenocortical adenoma in the right adrenal gland and necrosis of the muscle fibres in the left infraspinatus muscle. On day 29, all clinical signs had disappeared, and the serum potassium concentration, creatinine kinase activity and aldosterone concentration had normalised. On day 57, atrophy of the bilateral infraspinatus muscles was noted, but there was no evidence of any posture or gait abnormalities.

Relevance and novel information To the authors' knowledge, this is the first report of possible infraspinatus muscle necrosis in a cat with PHA. It is also possible that the infraspinatus muscle necrosis with hypokalaemic polymyopathy secondary to PHA was caused by compartment syndrome in the cat described here.

Keywords: Compartment syndrome; hypokalaemic polymyopathy; infraspinatus muscle; necrosis; primary hyperaldosteronism

Accepted: 23 August 2024

Introduction

Primary hyperaldosteronism (PHA) is the most common adrenocortical disorder in cats and is characterised by excessive secretion of aldosterone from unilateral or bilateral neoplasia or bilateral hyperplasia of the adrenal zona glomerulosa.^{1–3} Tumour-related PHA is characterised by excessive secretion of aldosterone from usually unilateral solitary adrenocortical adenoma or adenocarcinoma, leading to arterial hypertension and hypokalaemia.^{4–6} Aldosterone is mainly produced in the zona glomerulosa of the adrenal cortex and promotes the reabsorption of sodium ions in the distal tubules and facilitates the excretion of potassium ion and hydrogen ions into urine.⁷ In addition to the endocrine effects of aldosterone on renal

epithelial cells, aldosterone has effects on other epithelial and non-epithelial tissues, such as endothelial cells

¹Veterinary Teaching Hospital, Graduate School of Veterinary Medicine, Hokkaido University, Sapporo, Hokkaido, Japan

²Nara Animal Medical Center, Nara-shi, Nara, Japan

³Companion Animal Internal Medicine, Department of Companion Animal Clinical Sciences, School of Veterinary Medicine, Rakuno Gakuen University, Ebetsu, Hokkaido, Japan

Corresponding author:

Hiroshi Ohta DVM, PhD, Companion Animal Internal Medicine, Department of Companion Animal Clinical Sciences, School of Veterinary Medicine, Rakuno Gakuen University, 582 Bunkyo-dai-Midorimachi, Ebetsu, Hokkaido 069-8501, Japan
Email: h-ohta@rakuno.ac.jp



Creative Commons Non Commercial CC BY-NC: This article is distributed under the terms of the Creative Commons

Attribution-NonCommercial 4.0 License (<https://creativecommons.org/licenses/by-nc/4.0/>) which permits non-commercial use, reproduction and distribution of the work without further permission provided the original work is attributed as specified on the SAGE and Open Access pages (<https://us.sagepub.com/en-us/nam/open-access-at-sage>).

and cardiac tissue, and contributes to blood pressure homeostasis.⁸

The clinical signs of PHA are systemic hypertension through two main mechanisms: (1) increased reabsorption of sodium and water retention; and (2) increased total peripheral resistance due to the long-term aldosterone excess, which may lead to fibrosis and proliferation of endothelial and smooth muscle cells in tissues, such as the heart and kidney.⁷⁻⁹ Aldosterone excess and systemic hypertension may result in targeted organ damage, which may result in ocular signs, such as intraocular haemorrhage, retinal detachment, tortuous retinal vessels and retinal oedema, left ventricular hypertrophy and progressive loss of renal function.^{1,7,8,10} In addition, approximately 20% of cats with PHA have polyuria and polydipsia, possibly because of concurrent progesterone excess or hypokalaemia-induced reversible nephrogenic diabetes insipidus.^{4,5,10} Furthermore, hypokalaemia results in a more negative membrane potential of muscle and nerve fibres, meaning that depolarisation is more difficult and degeneration of skeletal muscle cells occurs throughout the body causing muscle weakness (ie, 'hypokalaemic polymyopathy').¹¹ In cats with PHA, clinical signs of hypokalaemic polymyopathy usually become evident when the serum potassium concentration becomes less than 2.5–3.0 mmol/l, although the severity of muscle weakness does not strictly correlate with the plasma potassium concentration.^{2,7,8,10,11} The main musculoskeletal manifestations of hypokalaemic polymyopathy in cats with PHA are a plantigrade stance in the hindlimbs, difficulty in jumping and/or a ventroflexion of the neck.^{2,7,8,10} Some cats have episodic muscle weakness and others have sudden-onset muscle weakness.² Severe cases may result in flaccid paresis with hyporeflexia, muscle hypotonia, difficulty in breathing and rhabdomyolysis.^{2,7,8,10,11} Hypokalaemic polymyopathy is associated with a significant increase in creatine kinase (CK) activity, suggesting widespread or severe muscle impairment.

A previous paper reported that of six cats with hypokalaemic polymyopathy mainly due to renal failure, there were pathological changes in the skeletal muscles of five of the cats.¹² However, there is no information on the pathology of hypokalaemic polymyopathy secondary to PHA. In this report, we present a case of infraspinatus muscle necrosis in a cat with PHA.

Case description

A 5-year-old castrated male domestic shorthair cat weighing 6.5 kg (body condition score 4/5) presented to the referring veterinarian with a chronic history of polyuria and polydipsia and a 2-week history of decreased activity, staggering gait, difficulty in jumping and inward rotation of both forelimbs. The referring veterinarian identified hypokalaemia and an intra-abdominal mass

and referred the cat to Hokkaido University Veterinary Teaching Hospital for further evaluation.

On the day of presentation at our hospital, physical examination revealed no abnormalities. The mean systolic blood pressure was 149 mmHg, and no neurological abnormalities were detected. Blood tests revealed severe hypokalaemia (2.2 mmol/l, reference interval [RI] 3.4–4.6), marked elevation of CK activity (>2000 IU/l, RI 87–309), elevated aspartate aminotransferase activity (152 IU/l, RI 18–51) and metabolic alkalosis (pH 7.45, HCO₃⁻ 33.4 mmol/l). Other blood test results were within their respective RIs. Abdominal ultrasonography showed enlargement of the right adrenal gland (Figure 1). Thoracic and abdominal CT examinations revealed no metastatic lesions and no vascular invasion of the enlarged right adrenal gland. Post-contrast CT images showed peripheral contrast enhancement and a non-enhanced centre in the bilateral infraspinatus muscles (Figure 2).

Based on these findings, PHA due to a right adrenal tumour was strongly suspected. From the day of initial presentation, oral potassium replacement therapy (potassium gluconate 3.75 mmol q12h) was initiated. On day 5, the potassium concentration was within the RI (3.9 mmol/l) and the cat had an elevated serum aldosterone concentration (7493 pmol/l) as measured by solid-phase radioimmunoassay available in a commercial human laboratory, although this assay has not been validated for use in cats. Based on the clinical signs, hypokalaemia, serum aldosterone concentration and adrenal imaging, the cat was diagnosed with PHA.

On day 17, surgical resection of the right adrenal gland and biopsy of the left infraspinatus muscle were performed. Histopathological examination of the resected right adrenal gland revealed an adrenal cortical adenoma, although immunohistochemistry was not performed to

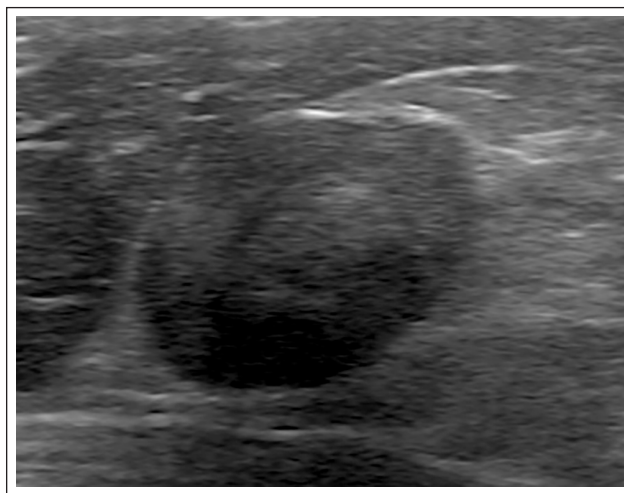


Figure 1 Ultrasonographic image of the enlarged right adrenal gland measuring 1.7 × 1.2 cm

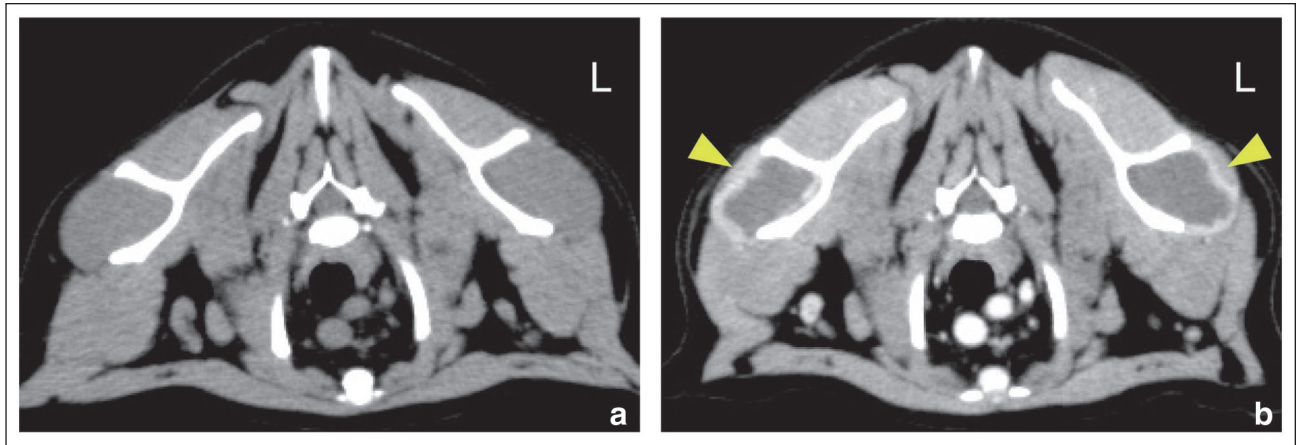


Figure 2 (a) Pre-contrast and (b) post-contrast transverse shoulder CT images. The post-contrast delayed phase image shows peripheral contrast enhancement (yellow arrowheads) and non-enhanced centres in the bilateral infraspinatus muscles (b)

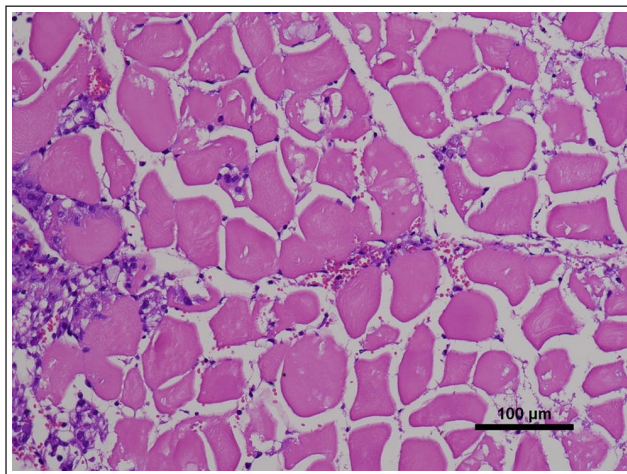


Figure 3 Histopathological image of the left infraspinatus muscle showing extensive necrosis of the muscle fibres and mild infiltrations of macrophages and lymphocytes. Haematoxylin and eosin stain. Bar = 100 µm

detect the origin of the tumour cells. Histopathological examination of the left infraspinatus muscle showed diffuse necrosis of the muscle fibres with mild infiltrations of macrophages and lymphocytes around the muscle fibres and in the surrounding adipose tissue (Figure 3). During and after the operation, the cat received a constant rate infusion of fentanyl (1–2 µg/kg/h) for 1 day, followed by buprenorphine (15 µg/kg IV q8h) for analgesia. The cat also received an intravenous infusion of crystalloid fluid containing 20 mEq/l of potassium ions (2.5 ml/kg/h) and intravenous cefazolin sodium (20 mg/kg q12h). However, the cat was discharged from our hospital on day 19, because it was very nervous during hospitalisation and there was no evidence of intra-abdominal bleeding. The cat was prescribed amoxicillin (15 mg/kg PO q12h) for 4 days.

On day 22, the cat revisited the hospital without any problems and blood tests revealed that the potassium concentration was still within the RI (3.8 mmol/l). On day 29, blood tests revealed that the potassium concentration remained within the RI (4.2 mmol/l), the CK activity had normalised (257 IU/l) and the serum aldosterone concentration had improved (172 pmol/l). On day 57, physical examination revealed atrophy of the bilateral infraspinatus muscles, but there was no evidence of any posture or gait abnormalities.

Discussion

In cats with PHA, one of the most common complications is hypokalaemic polymyopathy. However, little information is available concerning the histopathological changes of the skeletal muscle in cats with hypokalaemic polymyopathy.

A study of six cats with hypokalaemic polymyopathy mainly due to renal failure revealed electromyographic abnormalities, such as positive sharp waves, fibrillation potentials and occasional bizarre high-frequency discharges in multiple muscles, indicating generalised skeletal muscle impairment.¹² The study also reported that the muscle biopsy specimens from all five cats examined were normal except for one cat with mild muscle fibre necrosis and a mild infiltration of macrophages.¹² In addition, hypokalaemic polymyopathy has been reported in Burmese kittens in several countries.¹³ Burmese kittens develop hypokalaemia associated with disturbances of the intracellular and extracellular potassium balance.¹³ Burmese cats with hypokalaemic polymyopathy sometimes show diffuse electromyographic abnormalities, such as positive sharp waves, but muscle biopsy specimens are mostly normal on histopathological examination.¹⁴ To the best of the authors' knowledge, no other report has described the histopathological changes in the skeletal muscle of cats with hypokalaemic

polymyopathy. Therefore, the localised skeletal muscle necrosis observed in the present case is thought to be rare.

Histopathological examination of the biopsied left infraspinatus muscle revealed diffuse necrosis of the muscle fibres with mild infiltrations of macrophages and lymphocytes. These findings were consistent with the histopathological findings of sub-acute infraspinatus muscle myopathy in a dog.¹⁵

There are several reports of infraspinatus muscle myopathy in dogs, and this condition is called fibrous contracture of the infraspinatus muscle (FCIM). FCIM is an uncommon cause of shoulder lameness in dogs that primarily affects medium- to large-breed, young to adult, hunting, sporting and working dogs.^{16,17} In dogs with FCIM, unilateral infraspinatus muscle involvement is common, but bilateral involvement is also reported.^{16,17} Compartment syndrome has been proposed as the underlying cause of the acute phase of FCIM.^{16–19} The infraspinatus muscle is surrounded by fascia and the scapula (ie, bone-muscle compartment), thus it is unable to resist the supraphysiological compartmental pressure and cellular swelling that occur during heavy exercise.²⁰ Venous drainage is stopped, while arterial drainage is maintained. If the intracompartmental pressure exceeds the mean arterial pressure, muscle perfusion completely ceases, leading to acute ischaemia of the muscles and necrosis of the myofibers and surrounding cellular components. In a previous experimental study of osteofacial compartment syndrome in dogs, a muscle transducer was used to measure the intramuscular pressure.¹⁹ However, in clinical practice, the diagnosis of FCIM is based on clinical history and the tenderness and swelling of the infraspinatus muscle upon palpation. It has been reported that emergency fasciotomy to release the intracompartmental pressure can prevent contracture of the infraspinatus muscle.¹⁶ In the chronic phase of FCIM, the necrotic muscle undergoes fibrosis and contracture, resulting in the outward rotation of the forelimb and characteristic lameness.²⁰

No reports have described contracture of the infraspinatus muscle in cats. In addition, no report has described infraspinatus muscle necrosis in hypokalaemic cats with PHA. Thus, infraspinatus muscle necrosis is thought to be a rare condition in cats with PHA. Although the mechanism of infraspinatus muscle necrosis observed in the current case is not clear, the following mechanisms are possible: (1) forelimb weakness associated with hypokalaemic polymyopathy; (2) excessive weightbearing of the shoulder muscles leading to the development of compartment syndrome; and (3) ischaemic necrosis of the bilateral infraspinatus muscles, which we detected from a thoracic CT examination. In addition, physical examination revealed atrophy of the bilateral infraspinatus muscles on day 57. Although repeated histopathological

examination of the infraspinatus muscles was not performed, it was suspected that the cat had atrophy of the muscle fibres and fibrosis of the infraspinatus muscles that might be consistent with the chronic phase of infraspinatus muscle myopathy in dogs. However, there was no evidence of posture or gait abnormalities, indicating that infraspinatus muscle necrosis and subsequent atrophy does not necessarily affect the overall motor function of cats with PHA.

In the current case, the post-contrast CT examination incidentally detected the abnormal findings in the bilateral infraspinatus muscles. CT examination has become a routine diagnostic test for the investigation of abdominal masses and in screening for pulmonary metastasis. In cats with PHA, CT examination of the entire skeletal muscles and careful image evaluation may contribute to further understanding of the skeletal muscle involvement in cats with hypokalaemic myopathy secondary to PHA.

Conclusions

This report presents the first case of infraspinatus muscle necrosis possibly associated with PHA in a cat. It is also possible that the infraspinatus muscle necrosis in this cat with hypokalaemic polymyopathy secondary to PHA was caused by compartment syndrome.

Acknowledgements We thank Dr Yumiko Kagawa, an American College of Veterinary Pathologists board-certified pathologist, for her help with evaluating the results of the histopathological examination. We also thank Dr Kelly Zammit BVSc, from Edanz (<https://jp.edanz.com/ac>), for editing a draft of this manuscript.

Conflict of interest The authors declared no potential conflicts of interest with respect to the research, authorship, and/or publication of this article.

Funding The authors received no financial support for the research, authorship, and/or publication of this article.

Ethical approval The work described in this manuscript involved the use of non-experimental (owned or unowned) animals. Established internationally recognised high standards ('best practice') of veterinary clinical care for the individual patient were always followed and/or this work involved the use of cadavers. Ethical approval from a committee was therefore not specifically required for publication in *JFMS Open Reports*. Although not required, where ethical approval was still obtained, it is stated in the manuscript.

Informed consent Informed consent (verbal or written) was obtained from the owner or legal custodian of all animal(s) described in this work (experimental or non-experimental animals, including cadavers, tissues and samples) for all procedure(s) undertaken (prospective or retrospective studies). No animals or people are identifiable within this publication, and therefore additional informed consent for publication was not required.

ORCID iD Hiroshi Ohta  <https://orcid.org/0000-0002-3673-4319>

References

- 1 Javadi S, Djajadiningrat-Laanen SC, Kooistra HS, et al. **Primary hyperaldosteronism, a mediator of progressive renal disease in cats.** *Domest Anim Endocrinol* 2005; 28: 85–104.
- 2 Feldman EC. **Primary hyperaldosteronism in cats.** In: Feldman EC, Nelson RW, Reusch CE, et al (eds). *Canine and feline endocrinology*. 4th ed. St Louis, MO: Elsevier, 2015, pp 478–481.
- 3 Djajadiningrat-Laanen SC, Galac S, Boevé MH, et al. **Evaluation of the oral fludrocortisone suppression test for diagnosing primary hyperaldosteronism in cats.** *J Vet Intern Med* 2013; 27: 1493–1499.
- 4 Ash RA, Harvey AM and Tasker S. **Primary hyperaldosteronism in the cat: a series of 13 cases.** *J Feline Med Surg* 2005; 7: 173–182.
- 5 Lo AJ, Holt DE, Brown DC, et al. **Treatment of aldosterone-secreting adrenocortical tumors in cats by unilateral adrenalectomy: 10 cases (2002–2012).** *J Vet Intern Med* 2014; 28: 137–143.
- 6 Del Magno S, Foglia A, Rossanese M, et al. **Surgical findings and outcomes after unilateral adrenalectomy for primary hyperaldosteronism in cats: a multi-institutional retrospective study.** *J Feline Med Surg* 2023; 25. DOI: 10.1177/1098612X221135124.
- 7 Djajadiningrat-Laanen S, Galac S and Kooistra H. **Primary hyperaldosteronism: expanding the diagnostic net.** *J Feline Med Surg* 2011; 13: 641–650.
- 8 Kooistra HS. **Primary hyperaldosteronism in cats: an underdiagnosed disorder.** *Vet Clin North Am Small Anim Pract* 2020; 50: 1053–1063.
- 9 Connell JM, MacKenzie SM, Freel EM, et al. **A lifetime of aldosterone excess: long-term consequences of altered regulation of aldosterone production for cardiovascular function.** *Endocr Rev* 2008; 29: 133–154.
- 10 Behrend EN. **Aldosterone-secreting adrenal tumors.** In: Ettinger SJ, Feldman EC and Côté E (eds). *Textbook of veterinary internal medicine*. 8th ed. St Louis, MO: Elsevier, 2017, pp 1820–1824.
- 11 Kogika MM and de Morais HA. **A quick reference on hypokalemia.** *Vet Clin North Am Small Anim Pract* 2017; 47: 229–234.
- 12 Dow SW, LeCouteur RA, Fettman MJ, et al. **Potassium depletion in cats: hypokalemic polymyopathy.** *J Am Vet Med Assoc* 1987; 191: 1563–1568.
- 13 Gaschen F, Jaggy A and Jones B. **Congenital diseases of feline muscle and neuromuscular junction.** *J Feline Med Surg* 2004; 6: 355–366.
- 14 Jones BR, Swinney GW and Alley MR. **Hypokalaemic myopathy in Burmese kittens.** *N Z Vet J* 1988; 36: 150–151.
- 15 Orellana-James NG, Ginja MM, Regueiro M, et al. **Subacute and chronic MRI findings in bilateral canine fibrotic contracture of the infraspinatus muscle.** *J Small Anim Pract* 2013; 54: 428–431.
- 16 Devor M and Sørby R. **Fibrotic contracture of the canine infraspinatus muscle: pathophysiology and prevention by early surgical intervention.** *Vet Comp Orthop Traumatol* 2006; 19: 117–121.
- 17 Mikkelsen MA and Ottesen N. **CT findings in a dog with subacute myopathy and later fibrotic contracture of the infraspinatus muscle.** *Vet Radio Ultrasound* 2021; 62: E11–E15.
- 18 Franch J, Bertran J, Remolins G, et al. **Simultaneous bilateral contracture of the infraspinatus muscle.** *Vet Comp Orthop Traumatol* 2009; 22: 249–252.
- 19 Basinger RR, Aron DN, Crowe DT, et al. **Osteofascial compartment syndrome in the dog.** *Vet Surg* 1987; 16: 427–434.
- 20 Steiss JE. **Muscle disorders and rehabilitation in canine athletes.** *Vet Clin North Am Small Anim Pract* 2002; 32: 267–285.