



Modified circumferential preputioplasty using a Keyes biopsy punch for treatment of type I phimosis in two kittens

Authors: Hertel, Beatrice, Roberts, Victoria, Deroy-Bordenave, Claire, Adamany, Jessica, and Vallefucoco, Rosario

Source: Journal of Feline Medicine and Surgery Open Reports, 10(2)

Published By: SAGE Publishing

URL: <https://doi.org/10.1177/20551169241277068>

The BioOne Digital Library (<https://bioone.org/>) provides worldwide distribution for more than 580 journals and eBooks from BioOne's community of over 150 nonprofit societies, research institutions, and university presses in the biological, ecological, and environmental sciences. The BioOne Digital Library encompasses the BioOne Complete Archive (<https://bioone.org/subscribe>), the BioOne Complete Archive



Modified circumferential preputioplasty using a Keyes biopsy punch for treatment of type I phimosis in two kittens

Journal of Feline Medicine and Surgery Open Reports
1–6

© The Author(s) 2024

Article reuse guidelines:


sagepub.com/journals-permissions

DOI: 10.1177/20551169241277068

journals.sagepub.com/home/jfmsopenreports

This paper was handled and processed by the European Editorial Office (ISFM) for publication in *JFMS Open Reports*



Beatrice Hertel¹ , Victoria Roberts²,
Claire Deroy-Bordenave³, Jessica Adamany⁴
and Rosario Vallefuoco⁴

Abstract

Case series summary Medical records of two kittens diagnosed with type I phimosis were reviewed. Clinical signs on presentation, investigations, description of the surgical technique, and short- and long-term follow-up were reported. Type I phimosis was diagnosed in both kittens based on the clinical, radiographic and surgical exploration findings. Modified circumferential preputioplasty using 4 and 6mm Keyes biopsy punches was performed by the same surgeon in each case. The biopsy punch was centred over the existing narrowed preputial orifice and rotated clockwise and anticlockwise to obtain a sharp circumferential cut through the skin and submucosa of predictable diameter. The underlying mucosa was resected with micro curved scissors and mucocutaneous apposition was achieved with simple interrupted sutures placed circumferentially. Minor protrusion of the tip of the penis was recorded in the short-term follow-up (2 weeks) but resolved on the long-term follow-up (10 and 72 months). No evidence of urinary tract infection, strictures or clinical signs associated with phimosis were recorded at long-term follow-up.

Relevance and novel information This short case series describes the surgical correction of type I phimosis by circumferential preputioplasty implemented using a Keyes biopsy punch in two kittens. The technique described in this case series can be considered alongside other reported surgical techniques, and appears to provide a reliable, rapid and accurate removal of preputial skin in the two reported cases.

Keywords: Soft tissue surgery; urogenital; surgical technique; case series

Accepted: 6 August 2024

Introduction

Phimosis is defined as the inability to protrude the penis beyond the prepuce. Clinical signs depend on the size of the preputial orifice and the underlying cause (congenital or acquired).¹ Congenital causes include small or absent preputial orifice, inadequate penile length secondary to penile hypoplasia and persistent connective tissue bands adhering the penis to the preputial mucosa.² Acquired causes include trauma, lower urinary tract infection, neoplasia and cellulitis with resultant fibrosis leading to stenosis of the preputial orifice.^{3–7} Phimosis has been infrequently reported in cats⁸ and remains rare

in dogs.⁹ Ndiritu⁹ reported one (0.5%) case of phimosis in a population of 185 dogs treated for penile or preputial problems. In cats, it has been classified as type I and

¹San Marco Veterinary Clinic and Laboratory, Veggiano, Italy

²Lumbry Park Veterinary Specialists, Alton, UK

³Vet and Surg, Le Haillan, France

⁴Pride Veterinary Referrals, Derby, UK

Corresponding author:

Beatrice Hertel DVM, MRCVS, San Marco Veterinary Clinic and Laboratory, Viale dell'industria 3, Veggiano 35030, Italy
Email: beatrice.hertel@hotmail.it



Creative Commons Non Commercial CC BY-NC: This article is distributed under the terms of the Creative Commons

Attribution-NonCommercial 4.0 License (<https://creativecommons.org/licenses/by-nc/4.0/>) which permits non-commercial use,

reproduction and distribution of the work without further permission provided the original work is attributed as specified on the SAGE and Open

Access pages (<https://us.sagepub.com/en-us/nam/open-access-at-sage>).

type II:¹⁰ type I is defined as a narrowed preputial orifice with generalised swelling or outward ballooning of the prepuce in the absence of adhesion between the penis and the prepuce;¹⁰ and type II is defined as a narrowed preputial orifice, penile-preputial adhesions and preputial urine pooling resulting in more discrete preputial swelling.¹⁰ Clinical signs secondary to phimosis include pollakiuria, stranguria, urine dribbling, excessive preputial licking, vocalisation, preputial distension secondary to preputial urine pooling, balanoposthitis and skin ulceration.^{3,4,7} Published literature on phimosis in cats is limited and both medical and surgical management options have been described.^{5,10–12}

Medical management with topical application of steroid ointment and/or enlargement of the prepuce with a haemostat has been reported ineffective.¹⁰

Surgical correction aims to enlarge the preputial orifice resulting in alleviation of the clinical signs with a low rate of postoperative complications.^{5,10,11}

The surgical corrective technique depends on the type of phimosis. Type II phimosis has been corrected by preputial urethrostomy¹³ and modified preputial urethrostomy,¹⁰ whereas surgical techniques for type I phimosis include a ventral wedge resection followed by apposition of the ipsilateral mucocutaneous edges by sutures,⁸ a single ventral releasing incision followed by apposition of the ipsilateral mucocutaneous edges by sutures,⁵ a sutureless single ventral releasing incision⁵ and a circumferential preputioplasty.¹¹ It has been reported that wedge and circumferential preputioplasty followed by apposition of the ipsilateral mucocutaneous edges by sutures carry better outcomes.¹⁰

The amount of tissue resected appears to be a crucial factor for a successful outcome.¹⁰ Resection of excessive skin/mucosa would result in permanent penile exposure, which could increase the risk of recurrent urinary tract infections (UTIs),¹⁰ while resection of inadequate tissue may cause stricture and persistence of the clinical signs. Care should be taken to obtain a symmetrical and accurate resection of preputial tissue; however, there is scant information regarding the degree of tissue resection performed.^{5,8,11}

Modification of the existing surgical technique has been considered by the authors to obtain a preputial opening of predictable diameter. The purpose of this short case series is to describe a modified circumferential preputioplasty technique using a Keyes biopsy punch for treatment of type I phimosis in two kittens and to report the short- and long-term outcomes.

Surgical technique

Each kitten was premedicated using dexmedetomidine 0.005 mg/kg IM (Dexdom; Pfizer) in combination with methadone (0.2 mg/kg, Comfortan; Dechra). Induction was performed with propofol 2 mg/kg IV (PropoFlo Plus; Zoetis) and anaesthesia was maintained with

isoflurane (Isoflo; Zoetis) in 100% oxygen. The patient was positioned in dorsal recumbency, the pelvic limbs were retracted cranially and an anal purse string suture was placed. The perineal region was clipped and aseptically prepared for the surgery. In both cases, urinary catheterisation was not possible. The existing narrowed preputial orifice was identified and a Keyes biopsy punch (Kai Medical) was centred over it and rotated clockwise and anticlockwise, perpendicularly to the skin, to obtain a sharp circumferential cut of the preputial skin and submucosa of predictable diameter (Figures 1 and 2m). After withdrawal of the punch, an accurate resection of the underlying mucosa was achieved with micro curved scissors. The penis was identified, exteriorised and confirmed to be grossly normal. A urinary catheter was then placed. Mucocutaneous apposition was finally achieved with simple interrupted sutures (5-0 monocril) (Figure 3).

Case series description

Case 1

A 7-month-old male castrated domestic longhair cat weighing 3.2 kg was presented with a 2 month history of persistent stranguria, inappropriate urination, intermittent haematuria and scrotal irritation secondary to excessive licking after elective castration. On clinical examination, a firm swelling of the prepuce alongside severe narrowing of the preputial orifice were noted. Urine could be seen dribbling from the preputial orifice on bladder expression. Haematological and serum biochemical analyses and abdominal ultrasound were within normal limits. Urinalysis revealed an active UTI with *Staphylococcus* species. The surgery was performed as per the technique described above using a 6 mm Keyes biopsy punch. The cat was discharged the day after on meloxicam 0.1 mg/kg PO (Metacam; Boehringer Ingelheim) and amoxicillin–clavulanic acid 20 mg/kg (Clavaseptin; Vetoquinol) for 7 days. A buster collar and home exercise restriction were recommended for 15 days. In addition, absorbent tissue as litter was recommended for 15 days.

Case 2

A 4-month-old male intact domestic shorthair cat weighing 2.5 kg was presented with a history of persistent dysuria since adoption 2 months prior. Clinical examination showed a severe narrowing of the preputial orifice. No evidence of preputial swelling or inflammation were noted. Dipstick urine analysis was performed and it was largely unremarkable. Further investigations were declined by the owner and surgery was elected. The kitten underwent surgical correction of the phimosis with the same technique using a 4 mm Keyes biopsy punch (Figure 4). The cat was discharged the next day with the same medications and instructions as case 1.

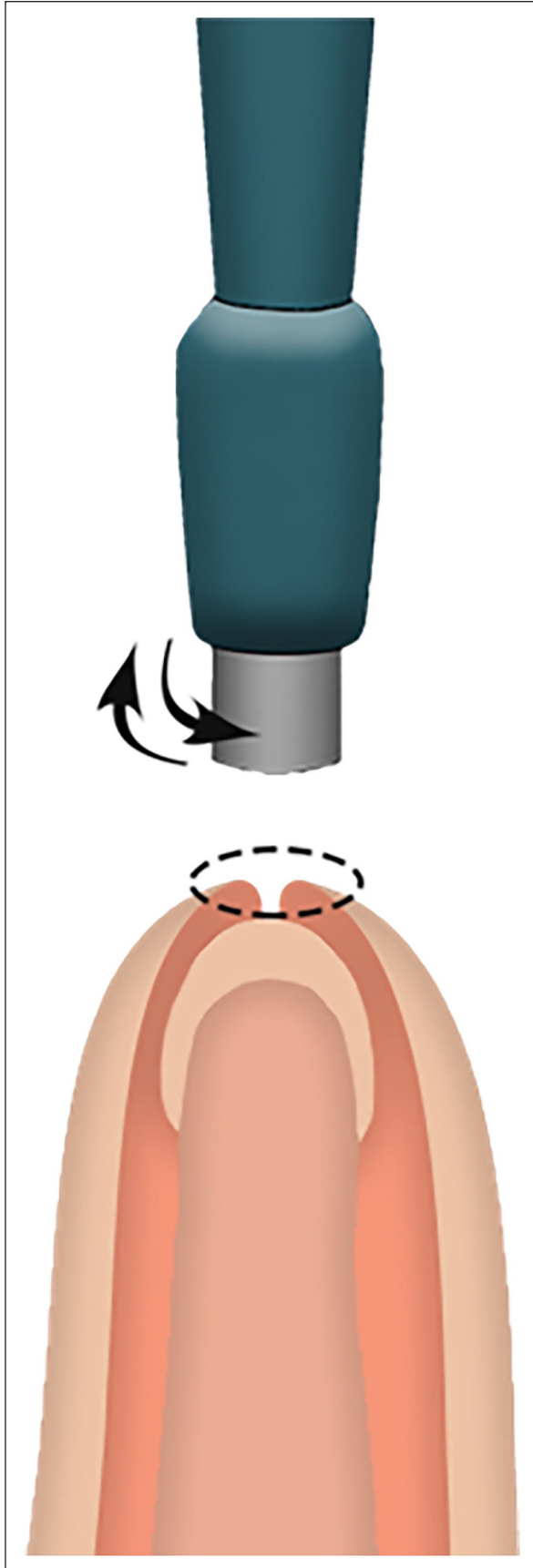


Figure 1 Type 1 phimosis (sagittal section) and circumferential preputioplasty using a Keyes biopsy punch

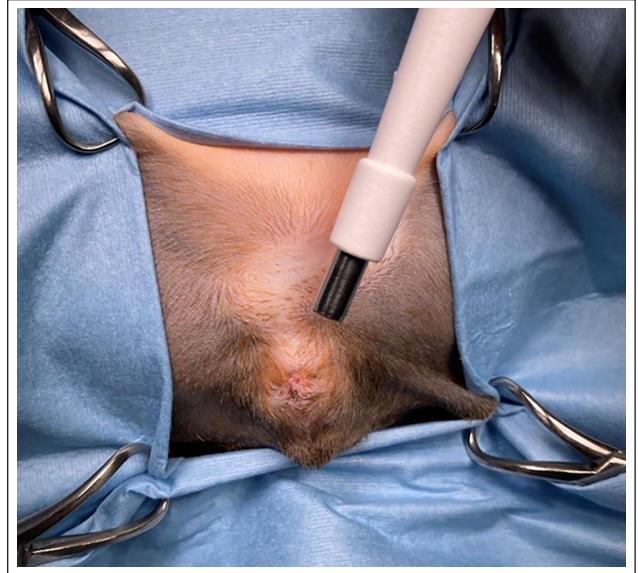

Figure 2 Case 1: Keyes biopsy punch that will be centred over the narrowed preputial orifice

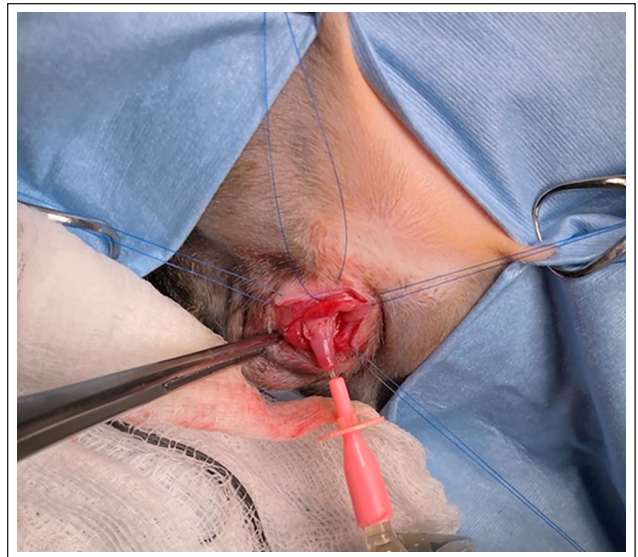


Figure 3 Case 1: after withdrawal of the Keyes biopsy punch, a urinary catheter was placed to allow precise resection of the underlying mucosa with micro curved scissors. Mucocutaneous apposition was achieved with 5-0 monocryl simple interrupted sutures placed circumferentially

Short- and long-term follow-ups

In both cases, no stranguria or pollakiuria was reported after discharge; however, minor exposure of the penile tip (1–2mm) was noted on discharge and at the first recheck 1 week later. Full resolution of penile exposure was observed at the second recheck 2 weeks postoperatively in both cases.

In case 1, urinalysis was repeated after antibiotic therapy, showing resolution of the previous UTI. Reassessment was performed 10 months postoperatively

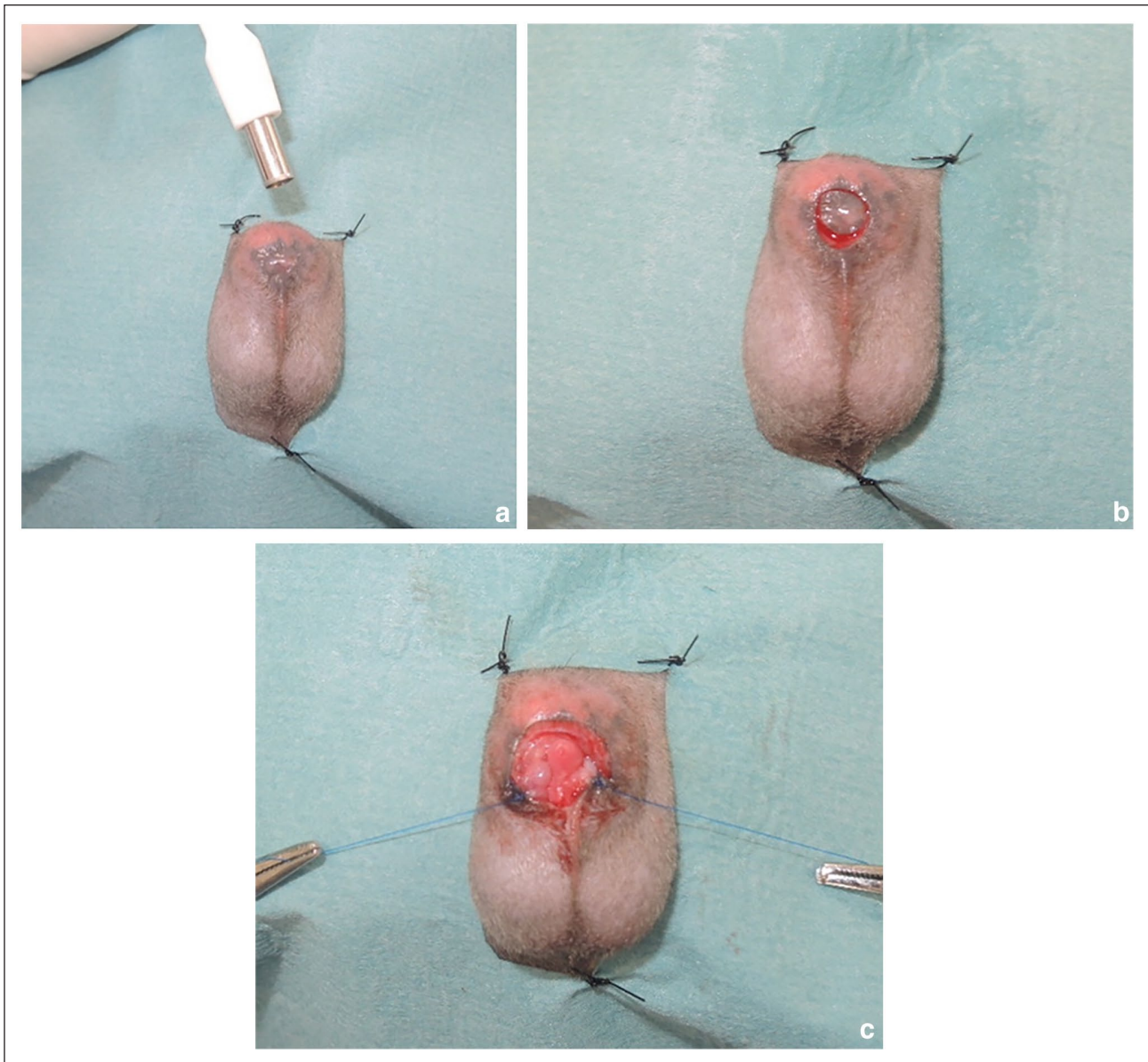


Figure 4 Case 2: (a) the Keyes biopsy punch has been centred over the narrowed preputial orifice; (b) after withdrawal of the Keyes biopsy punch, sharp dissection and resection of the tissue has been performed with micro curved scissors; and (c) penile exposure after dissection and placement of stay sutures prior mucocutaneous apposition with simple interrupted sutures

and revealed no penile exposure or grossly evident strictures (Figure 5). In both cases, resolution of previous clinical signs, no urinary signs and no protrusion of the tip of the penis were reported at telephonic follow-up 52 and 72 months postoperatively.

Discussion

Phimosis is an uncommon disorder in small animals, and congenital and acquired forms have been described. The underlying cause of phimosis was not determined for the kittens described in this report. Based on the

clinical history, the cause of phimosis for case 1 could be traumatic in origin, due to self-trauma of the scrotal region after an elective castration. Conversely, the signs of case 2 had been noted since adoption. In the latter case, no signs of inflammation or infection were reported. Congenital phimosis can be suspected, but an acquired form cannot be completely ruled out given the incomplete history for this case. Excessive perineal cleaning by the dam or aberrant suckling behaviour of littermates toward the prepuce are believed to be the most common cause of acquired phimosis in both cats and dogs.^{5-7,11}

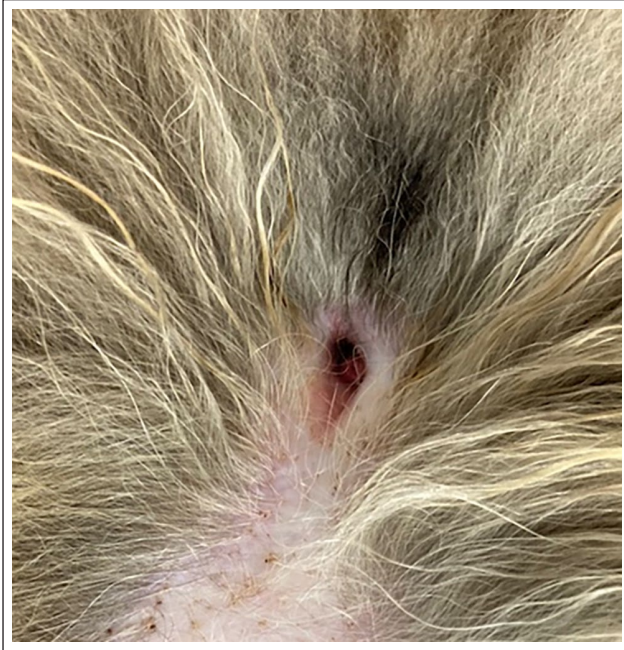

Figure 5 Case 1 at the 10-month postoperative follow-up showing no protrusion of the tip of the penis or any grossly evident strictures

Regardless of the aetiology, surgical correction is currently considered the gold standard treatment for both type I and II phimosis^{1,10} and accurate mucocutaneous apposition with sutures is vital.⁵ A sutureless releasing incision technique, where no tissue is resected and no sutures are placed, is not recommended.¹⁰ This is due to the fact that leaving the preputial incision to heal by second intention can lead to granulation tissue formation and subsequent wound contraction, thus increasing the risk of stricture formation, which may necessitate revision surgery.⁵ Wedge and circumferential preputioplasty followed by apposition of the ipsilateral mucocutaneous edges by sutures for correction of phimosis type I are associated with resolution of clinical signs and low rates of complication, making these techniques an acceptable surgical option.¹⁰ However, technical differences exist between the two surgical techniques. Ventral wedge resection provides a relatively limited increase in the size of the preputial orifice only on one side (ventral) of the prepuce, leaving the potential for residual abnormal tissue on the remaining circumference.⁵ Conversely, the circumferential preputioplasty allows the preputial orifice to be widened at all aspects, removing 360° necrotic or cicatricial skin alongside oedematous or redundant preputial mucosa.¹⁰ In a case series by De Vlaming et al,¹⁰ all the cats that underwent circumferential preputioplasty had a degree of penile exposure in the immediate postoperative period that resolved in all except 2/8 cases.

In the two cases described here, penile exposure was also present in the immediate postoperative period but had resolved by 2 weeks postoperatively. Given the rapid resolution, the most likely cause for this complication is considered to be normal postoperative tissue inflammation and oedema.

In addition, two kittens in the above-mentioned case series¹⁰ developed UTIs a few months postoperatively and the authors suggested UTI as a potential complication of the procedure. In the present cases, no UTI was reported; however, because of the small number of cases of both case series, further studies are needed to confirm UTI as a consistent postoperative complication of the procedure before making further recommendations.

The modified circumferential preputioplasty technique with a Keyes biopsy punch described here was considered to prevent persistent penile exposure secondary to extensive resection. Two sizes of punch were used based on the subjective assessment of the size of the prepuce.

Keyes biopsy punches have historically been used in veterinary medicine to sample skin tumours and inflammatory lesions.¹⁴ However, a multitude of other applications have been reported owing to specific conformation of the instrument,¹⁵ such as for removal of ectopic cilia in dogs¹⁶ or for intestinal biopsies.¹⁷ Its design creates a cylindrical specimen that can be grasped with forceps, elevated and cut with scissors. The depth of the cut is only limited to the blade length. Even pressure can result in a uniform 360° cut, enabling a more precise dissection and easier resection.

As previously discussed, in cases of phimosis, the diameter of the new preputial orifice remains a crucial factor for long-term success and the use of a Keyes biopsy punch is a valid option for resection of small portions of tissue where precise resection is required. In addition, it is easy to use, with no/minimal learning curve required. Among the various techniques, circumferential preputioplasty carries a better outcome and lower complication rates. However, persistent penile exposure results in the tip of the penis being dry. This can potentially lead to excessive grooming and predispose to recurrent UTIs. With our technique, permanent exposure was avoided.

For the cats in the present report, the modified circumferential preputioplasty was easy to perform and allowed resolution of clinical signs in the short- and long-term follow-ups. It successfully prevented persistent penile exposure. No revision surgeries were needed, and no postoperative UTIs were reported.

Conclusions

Modified circumferential preputioplasty using a Keyes biopsy punch appears to provide reliable, rapid and accurate removal of preputial skin, based on the two cases described.

Author note This paper was presented as a poster at the 2023 BSAVA Congress in Manchester, UK.

Conflict of interest The authors declared no potential conflicts of interest with respect to the research, authorship, and/or publication of this article.

Funding The authors received no financial support for the research, authorship, and/or publication of this article.

Ethical approval The work described in this manuscript involved the use of non-experimental (owned or unowned) animals. Established internationally recognised high standards ('best practice') of veterinary clinical care for the individual patient were always followed and/or this work involved the use of cadavers. Ethical approval from a committee was therefore not specifically required for publication in *JFMS Open Reports*. Although not required, where ethical approval was still obtained, it is stated in the manuscript.

Informed consent Informed consent (verbal or written) was obtained from the owner or legal custodian of all animal(s) described in this work (experimental or non-experimental animals, including cadavers, tissues and samples) for all procedure(s) undertaken (prospective or retrospective studies). No animals or people are identifiable within this publication, and therefore additional informed consent for publication was not required.

ORCID iD Beatrice Hertel  <https://orcid.org/0000-0003-4305-233X>

References

- Johnston SA and Tobias KM. *Veterinary surgery: small animal expert consult*. 2nd ed. St Louis, MO: Elsevier, 2018, pp 2165–2166.
- Christie TR. **Phimosis and paraphimosis**. In: Bojrab MJ (ed). *Pathophysiology in small animal surgery*. Philadelphia, PA: Lea & Febiger, 1981, pp 442–443.
- MacPhail CM. **Surgery of the male reproductive tract**. In: Fossum TW (ed). *Small animal surgery*. 4th ed. St Louis, MO: Elsevier Mosby, 2013, pp 846–848.
- Boothe HW. **Penis, prepuce, and scrotum**. In: Slatter D (ed). *Textbook of small animal surgery*. 3rd ed. Philadelphia, PA: WB Saunders Company, 2003, pp 1531–1542.
- May LR and Hauptman JG. **Phimosis in cats: 10 cases (2000–2008)**. *J Am Anim Hosp Assoc* 2009; 45: 277–283.
- Papazoglou LG and Kazakos GM. **Surgical conditions of the canine penis and prepuce**. *Compendium* 2002; 34: 204–218.
- Hobson HP. **Surgical pathophysiology of the penis**. *Dis Mech Small Anim Surg* 1993; 2: 552–559.
- Bright SR and Mellanby RJ. **Congenital phimosis in a cat**. *J Feline Med Surg* 2004; 6: 367–370.
- Ndiritu CG. **Lesions of the canine penis and prepuce**. *Modern Vet Pract* 1979; 60: 712–715.
- De Vlaming A, Wallace ML and Ellison GW. **Clinical characteristics, classification, and surgical outcome for kittens with phimosis: 8 cases (2009–2017)**. *J Am Vet Med Assoc* 2019; 255: 1039–1046.
- Yoon HY and Jeong SW. **Surgical correction of a congenital or acquired phimosis in two cats**. *J Vet Clin* 2013; 30: 123–126.
- John MK, Cari AO, Jody PL, et al. **Inherited and congenital diseases of the feline lower urinary tract**. *Vet Clin Small Anim Pract* 1996; 26: 265–279.
- Yeh LS and Chin SC. **Modified perineal urethrostomy using preputial mucosa in cats**. *J Am Vet Med Assoc* 2000; 216: 1092–1095.
- Ehrhart N. **Principles of tumor biopsy**. *Clin Tech Small Anim Pract* 1998; 13: 10–16.
- Tyagi N, Suneja A, Mishra K, et al. **Comparison of Keyes punch biopsy instrument with cervical punch biopsy forceps for diagnosing cervical lesions**. *Gynecol Obstet Investig* 2017; 82: 157–162.
- D'Anna N, Sapienza JS, Guandalini A, et al. **Use of a dermal biopsy punch for removal of ectopic cilia in dogs: 19 cases**. *Vet Ophthalmol* 2007; 10: 65–67.
- Keats MM, Weeren R, Greenlee P, et al. **Investigation of Keyes skin biopsy instrument for intestinal biopsy versus a standard biopsy technique**. *J Am Anim Hosp Assoc* 2004; 40: 405–410.