



Distal partial ulnectomy with ulnar styloid process excision for management of an aneurysmal bone cyst in a cat

Authors: Sanchez Villamil, Carlos, Llanos Diez, Cesar, Thomas, Grace, Garty, Rachel, Lappalainen, Marianne, et al.

Source: Journal of Feline Medicine and Surgery Open Reports, 10(2)

Published By: SAGE Publishing

URL: <https://doi.org/10.1177/20551169241269323>



Distal partial ulnectomy with ulnar styloid process excision for management of an aneurysmal bone cyst in a cat

Journal of Feline Medicine and Surgery Open Reports
1–6

© The Author(s) 2024

Article reuse guidelines:

sagepub.com/journals-permissions

DOI: 10.1177/20551169241269323

journals.sagepub.com/home/jfmsopenreports

This paper was handled and processed by the European Editorial Office (ISFM) for publication in *JFMS Open Reports*



Carlos Sanchez Villamil¹, Cesar Llanos Diez¹,
Grace Thomas¹, Rachel Garty² , Marianne Lappalainen¹,
Julius Klever¹ and Alexandros Hardas²

Abstract

Case summary An 8-year-old male neutered domestic shorthair cat was presented with an acute onset of left thoracic limb lameness and a firm swelling on the lateral aspect of the left distal antebrachium. A CT scan of the left thoracic limb revealed an expansile osteolytic cystic bone lesion centred at the distal left ulnar metaphysis. Cytology from fine-needle aspiration was not consistent with neoplasia. The CT features and the cytology results were suggestive of a bone cyst. A distal partial ulnectomy with ulnar styloid process excision was performed as the biopsy method and as the treatment approach. Histopathology results were consistent with an aneurysmal bone cyst (ABC). Carpal instability was not detected after distal partial ulnectomy; therefore, a stabilisation method was not required. Limb function was excellent after surgery, with no lameness and no recurrence detected by the owner at 2, 6 and 24 weeks postoperatively. The veterinary examination at 12 weeks postoperatively confirmed the owner's outcome assessment.

Relevance and novel information To the authors' knowledge, this is the first report describing a distal partial ulnectomy with ulnar styloid process excision in a cat. Despite disrupting the short ulnar collateral ligament, this technique provided excellent short-term limb function with no need for carpal joint stabilisation. This technique allowed for the complete excision of a distal ulnar ABC and avoided cyst debridement, which could be associated with haemorrhage, recurrence and malignant transformation. Distal partial ulnectomy should be considered for distal ulnar bone lesions in cats.

Keywords: Bone cyst; ostectomy; lameness; excision; ulna; stabilisation

Accepted: 19 June 2024

Introduction

Bone cysts in cats and dogs are rare.¹ They can be classified as cystic (simple or unicameral), aneurysmal or subchondral. Simple cysts are fluid-filled cavities lined by fibrous tissue (not epithelium).² Aneurysmal cysts are expansile osteolytic lesions containing vascular sinusoids.² Subchondral cysts are adjacent to a synovial membrane and can open into a joint space.² The aetiology of these lesions is unknown.¹ Clinical signs often include swelling, pain, lameness and limb disuse, especially if

¹The Royal Veterinary College Department of Clinical Science and Services, Hatfield, Hertfordshire, UK

²The Royal Veterinary College Department of Pathobiology and Population Sciences, Hatfield, Hertfordshire, UK

Corresponding author:

Carlos Sanchez Villamil DVM, CertAVP, MVetMed, PGCert(VetEd), FHEA, MRCVS, DipECVS, The Royal Veterinary College Department of Clinical Science and Services, 5 New Cottages, Hatfield AL9 7TF, Hertfordshire, UK
Email: cvillamil@rvc.ac.uk



Creative Commons Non Commercial CC BY-NC: This article is distributed under the terms of the Creative Commons

Attribution-NonCommercial 4.0 License (<https://creativecommons.org/licenses/by-nc/4.0/>) which permits non-commercial use, reproduction and distribution of the work without further permission provided the original work is attributed as specified on the SAGE and Open Access pages (<https://us.sagepub.com/en-us/nam/open-access-at-sage>).

bone fracture occurs.¹ Presumptive diagnosis is often based on imaging features: cysts are expansile, locally aggressive, lucent lesions with little or no periosteal reaction.³ Histopathology is required for confirmation and differentiation from trauma, hypertrophic osteodystrophy, haemangioma, infectious causes, multiple cartilaginous exostosis and neoplasia.³ Biopsy could lead to bone fracture or, in the case of an aneurysmal bone cyst (ABC), uncontrollable haemorrhage.³ Therefore, when complete excision by ostectomy is possible, an excisional biopsy may be indicated. When ostectomy would cause a defect in a weightbearing bone or joint impairment, other treatment alternatives may be considered. Various treatments have been reported in human medicine with varying results, including conservative management; steroid injection; curettage alone; curettage and grafting with bone marrow; demineralised bone matrix or allograft chips; stabilisation techniques combined with grafts; or cyst drainage with Kirschner wire insertion.⁴ In veterinary medicine, surgical curettage and filling of the cystic lesion with bone graft, or intralesional steroid injection, are described treatment options which can result in good outcomes.⁴ Bone cysts are benign lesions, thus excisional biopsy should be curative.⁵ Malignant transformation has been described in veterinary medicine for simple cysts⁴ and ABCs.⁵ All reported cases of malignant transformation had undergone cyst debridement and not ostectomy. This may be a reason to favour ostectomy when possible.

Case description

An 8-year-old male neutered domestic shorthair cat was referred for investigation of a cystic bone lesion of the left distal ulna. Six weeks before referral, the cat had presented to its primary care veterinarian for an acute onset of left thoracic limb lameness. The patient was an indoor cat with no history of trauma and was reported to be systemically normal. A firm swelling was noted on the lateral aspect of the left distal antebrachium, just proximal to the carpal joint. The left carpal joint seemed unaffected on manipulation and painless. The cat was sedated for the acquisition of orthogonal radiographs of both thoracic limbs and the thorax. The thorax was reported as normal, but a bone mass was identified affecting the left distal ulna. Fine-needle aspiration (FNA) of the lesion was performed. Cytological interpretation was inconclusive but an atypical cell population was not observed. Haematology and biochemistry were largely unremarkable, aside from mild azotaemia that was suspected to be pre-renal (creatinine 153 µmol/l, reference interval [RI] 88–140; blood urea nitrogen 9.91 mmol/l, RI 3.5–12). The cat tested negative for

feline leukaemia and immunodeficiency viruses. Meloxicam 0.05 mg/kg PO q12h was prescribed until the referral appointment.

On presentation to the referral hospital, the systemic examination was unremarkable. Using a numerical rating scale,⁶ left thoracic limb lameness of 2/5 was detected. There was a firm, painful swelling on the lateral aspect of the left distal antebrachium. The left carpal joint was stable in varus and valgus stress, it had full range of motion in flexion and extension, and effusion, pain or crepitus were not noted. Haematology showed moderate leukopenia ($3.81 \times 10^9/l$, RI 5.5–19.50) and neutropenia ($2.02 \times 10^9/l$, RI 2.5–12.50). On manual smear, whole blood count had unremarkable morphology. Biochemistry showed a mild increase in cholesterol (5.9 mmol/l, RI 2.2–4.0).

A CT scan of the thorax, antebrachia, carpi and manus was performed under sedation with methadone (0.1 mg/kg IV) and medetomidine (0.005 mg/kg IV). A solitary, well defined, oval, smoothly marginated, expansile bone mass was located in the left distal ulna, centred at the distal ulnar metaphysis. Owing to its expansile nature, there was marked thinning of the ulnar cortex with multiple small regions of cortical destruction. There was marked osteolysis of the core of the mass which contained multiple, incomplete, linear, mineral septations. The lesion was filled with fluid-attenuating material and sedimented soft tissue attenuating non-enhancing material, probably representing blood. It measured approximately 3 cm (H) × 1.8 cm (W) × 2.1 cm (L). The mass was compressing the caudal border of the radius, which was slightly deformed. There was mild, smooth and continuous periosteal reaction at that level. There was mild soft tissue swelling around the mass. This monostotic, expansile and cystic bone mass was most likely consistent with a bone cyst (ie, aneurysmal) (Figure 1). The sedation was topped up with intravenous alfaxalone to effect for sampling. A haemorrhagic fluid was obtained on ultrasound-guided FNA. The sample was poorly cellular aside from blood components and diagnosis could not be reached on cytology. The cat was continued on meloxicam as previously prescribed.

A partial distal ulnectomy was performed 1 week after the investigations. The patient was anaesthetised and positioned in right lateral recumbency with the left fore limb uppermost. The whole left fore limb was clipped from shoulder to digits, including the digits. A hanging limb protocol was used for draping, with the whole manus included in the surgical field. A lateral approach to the distal ulna was performed by incising the skin right over the bone. The dissection plane involved soft tissues beyond the gross limit of the mass so as not to penetrate the gross lesion. The ulna

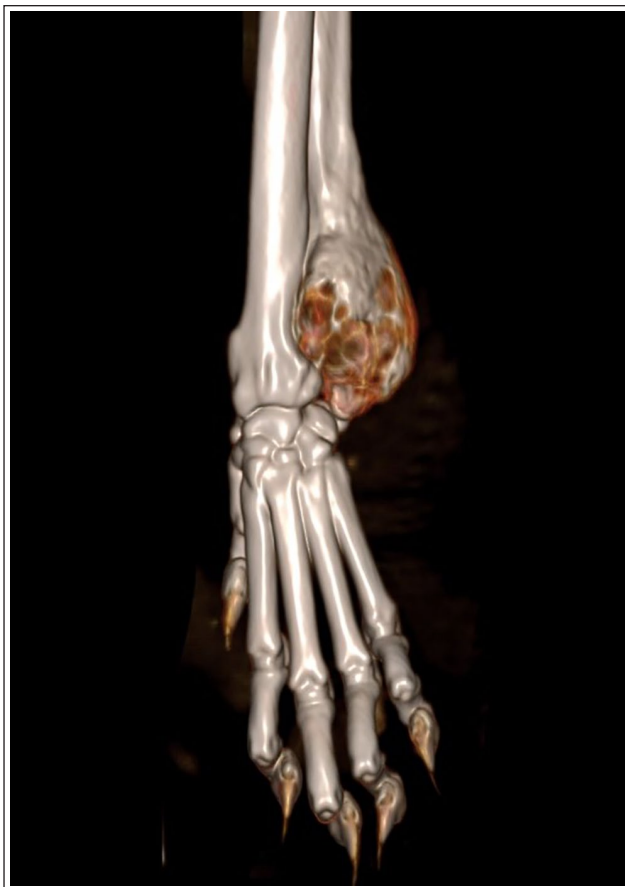

Figure 1 Three-dimensional CT reformatted image of the left distal antebrachium, carpus and manus of the cat at the time of diagnosis. There is an expansile bone lesion in the distal ulna with regions of cortical destruction

was cut with an oscillating saw (Colibri II; Synthes) approximately 4 cm from the ulnar styloid process and 1 cm proximal to the proximal gross limit of the mass (Figure 2).

To allow for ulnar styloid process excision, the radio-ulnar ligament, short ulnar collateral ligament, palmar ulnocarpal ligament and accessorioulnocarpal ligament were transected. The left carpal joint was deemed stable on intraoperative assessment after the ulnectomy. The subcutaneous layer and dermis were closed with 3-0 monofilament polyglecaprone 25 suture (Monocryl; Ethicon). Orthogonal postoperative radiographs were obtained to assess for the level of the osteotomy and for complete excision of the lesion (Figure 3). A dressing was not applied. On recovery, pain was controlled with buprenorphine (0.02mg/kg PO q6h) and meloxicam (0.05mg/kg PO q24h). The cat started weightbearing on his left thoracic limb immediately after recovery from anaesthesia and was 2/5 lame⁶ at the time of discharge 2 days postoperatively. The meloxicam therapy was

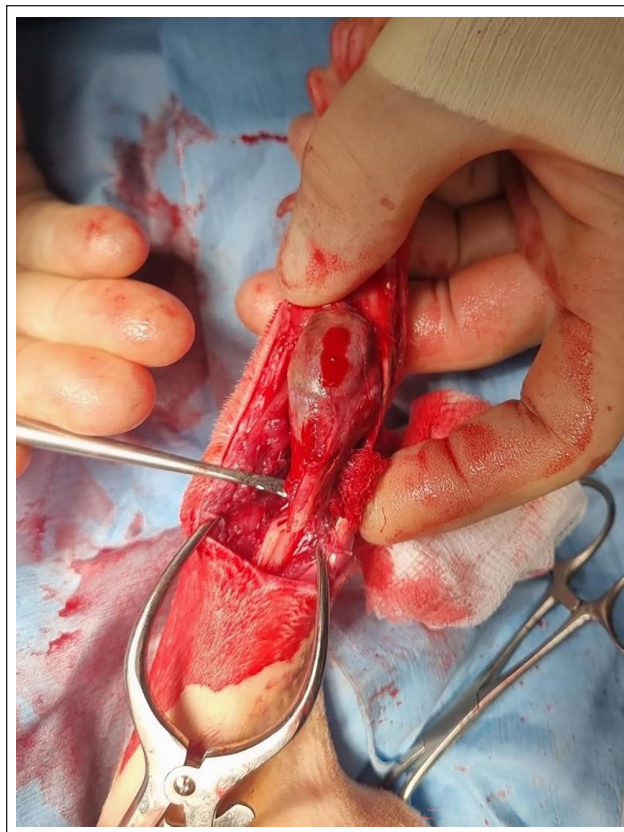

Figure 2 Intraoperative image of the lateral aspect of the left distal ulna. An ulnar osteotomy has been performed proximal to the cystic bone lesion

maintained for a total of 12 days. Cage rest was recommended for 14 days.

Histopathological examination of the lesion revealed a focal ABC (Figure 4). There were no bacterial isolates after 48h of incubation from direct or enrichment cultures.

The owners were contacted by telephone 2, 6 and 24 weeks postoperatively and the cat was reported to have a normal demeanour and no appreciable lameness. At 12 weeks postoperatively, the patient was reassessed at the referral hospital and was completely sound with no lameness and no evidence of recurrence.

Discussion

The cat described in this report underwent a distal partial ulnectomy that allowed for complete excision of a bone cyst while preserving limb function. Two studies have evaluated carpal joint stability in cadaveric dogs after distal ulnar osteotomy and concurrent disruption of the short ulnar collateral ligament.^{7,8} One of these studies demonstrated a slight increase in carpal valgus in a model mimicking weightbearing during stance⁷ and the

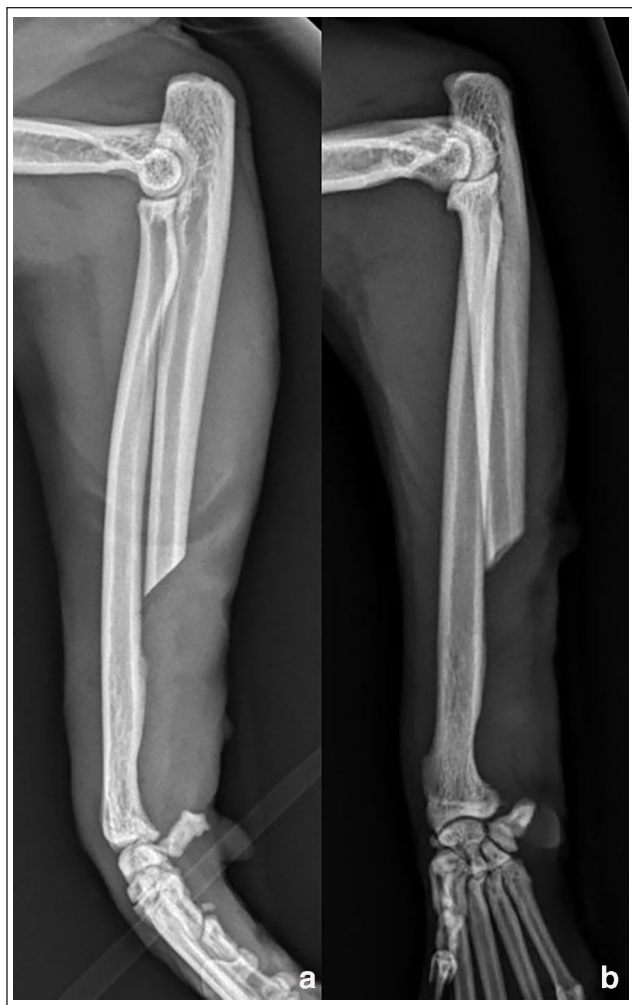


Figure 3 (a) Mediolateral and (b) oblique postoperative orthogonal radiographs of the left antebrachium of the cat after distal partial ulnectomy with ulnar styloid process excision.

other study documented an increase in the carpal angle upon stress radiography.⁸ In 2023, Griffin et al⁹ reported eight dogs that underwent distal ulnar ostectomy, including the ulnar styloid process and disruption of the short ulnar collateral ligament. Those dogs retained good function in the long term postoperatively. Only one dog had transient carpal instability intraoperatively that did not require surgical stabilisation aside from soft tissue imbrication during closure. Surgical revision was not required. These results suggest that the slight carpal instability found in a canine cadaveric model may not be reflected in a clinical scenario, or that dogs can have a normal limb function despite mild carpal instability. To the authors' knowledge, there are no cadaveric or in vivo studies reporting joint stability or limb function after distal ulnectomy with ulnar styloid process excision in cats.

Cats differ from dogs in that they have only a single short radial collateral ligament, and antebrachiocarpal subluxation is possible with rupture of the dorsal joint capsule and short radial collateral ligament alone.¹⁰ Injury to the short ulnar collateral ligament in cats and dogs seems better tolerated than damage to the short radial collateral ligament. The stability of the antebrachiocarpal joint medially depends mainly on the short radial collateral ligament. On the lateral side, the ulnar carpal bone is joined to the ulna through the short ulnar collateral ligament; however, it is also joined to the radius through the dorsal radiocarpal ligament. It is possible that upon disruption of the short ulnar collateral ligament, the dorsal radiocarpal ligament continues to provide strength against varus stress; hence the residual stability despite short ulnar collateral ligament disruption. The normal physiological valgus posture of the distal forelimb places greater tensile load on the medial aspect of the carpus,¹⁰ which could also play a protective role against lateral collateral instability. In the cat reported here, an excellent outcome was achieved in the short term with no need for carpal stabilisation. No lameness was detected from 2 weeks postoperatively and lasted until the last telephone follow-up 6 months postoperatively. All canine cases treated by Griffin et al⁹ had some form of external coaptation for 14 days; however, no dressing was used in this cat.

To the authors' knowledge, there have been eight case reports describing bone cysts in cats, two in the proximal humerus,^{4,11} two in the scapula,^{12,13} one in the ilium,¹ one in a rib,¹⁴ one in a metatarsal¹⁵ and one in the distal ulna.¹⁶ The previous report of a distal ulnar cyst¹⁶ was managed without surgery with steroid injections. Therefore, this current case report is the first describing surgical management of a distal ulnar bone cyst in a cat. Distal partial ulnectomy allowed for complete excision of the bone cyst and avoided surgical debridement of the cyst. A previous report described a malignant transformation after debridement of a bone cyst in a cat,⁴ suggesting that distal partial ulnectomy may be preferred over cyst debridement. Distal partial ulnectomy may also prevent haemorrhage that could occur during debridement of an ABC. The technique may also be applied safely for other distal ulnar bone lesions.

Conclusions

Distal partial ulnectomy with ulnar styloid process excision and short ulnar collateral ligament disruption was well tolerated in a cat and provided excellent limb function in the short term. This technique was successful at managing a distal ulnar ABC and could be applied for other distal ulnar bony lesions.

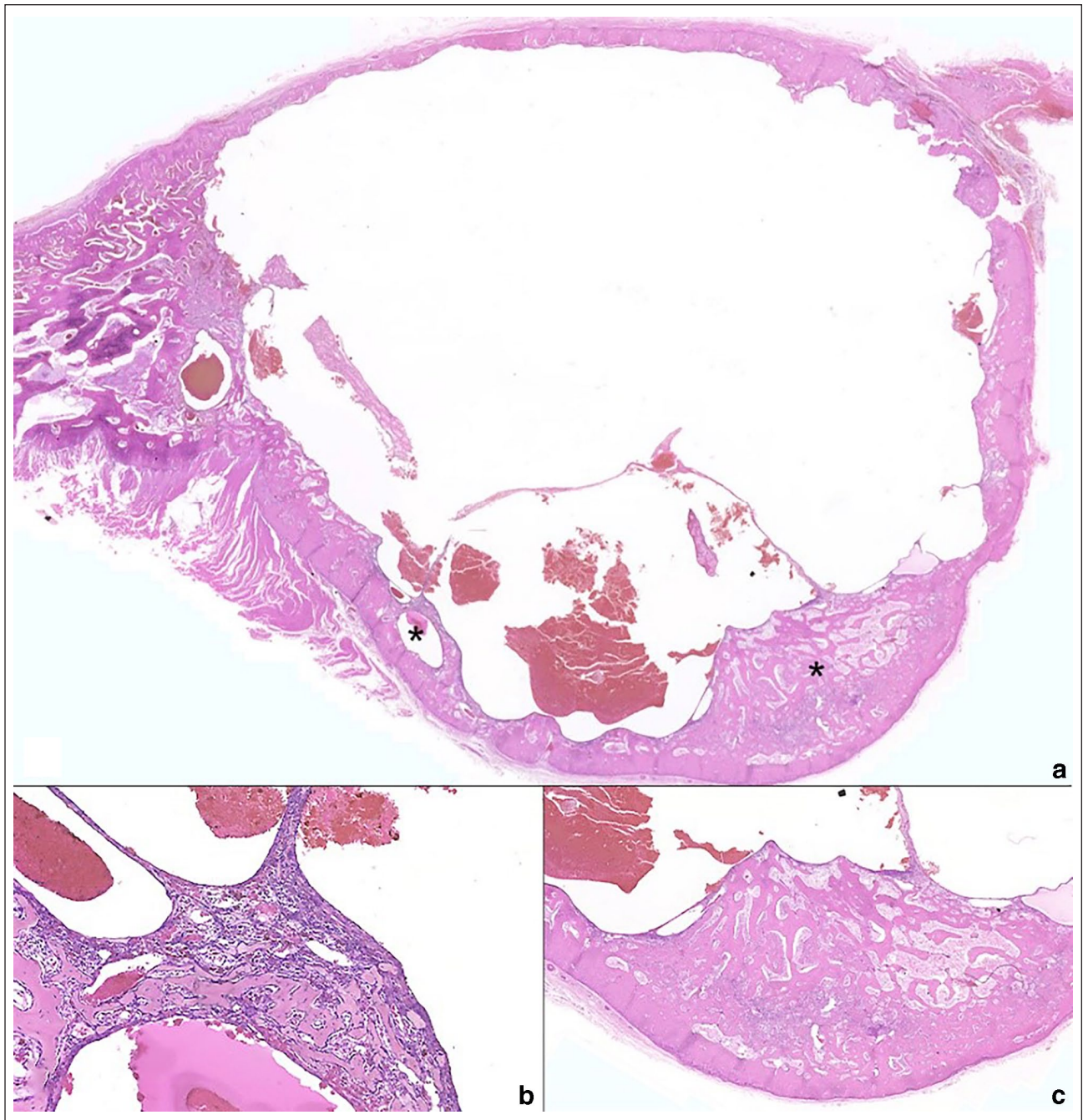


Figure 4 (a) Aneurysmal bone cyst located at the distal end of the left ulna of the cat; * highlights low power depictions of panels (b,c), H&E. (b) Cyst wall composed of connective tissue with capillaries and trabeculae of woven bone, H&E. (c) Large cystic structure lined by connective tissue that extends to the endosteal surface of the cortex, H&E. H&E = haematoxylin and eosin

Conflict of interest The authors declared no potential conflicts of interest with respect to the research, authorship, and/or publication of this article.

Funding The authors received no financial support for the research, authorship, and/or publication of this article.

Ethical approval The work described in this manuscript involved the use of non-experimental (owned or unowned) animals. Established internationally recognised high standards ('best practice') of veterinary clinical care for the individual patient were always followed and/or this work involved the use of cadavers. Ethical approval from a committee was therefore not specifically required for publication in *JFMS Open*

Reports. Although not required, where ethical approval was still obtained, it is stated in the manuscript.

Informed consent Informed consent (verbal or written) was obtained from the owner or legal custodian of all animal(s) described in this work (experimental or non-experimental animals, including cadavers) for all procedure(s) undertaken (prospective or retrospective studies). No animals or people are identifiable within this publication, and therefore additional informed consent for publication was not required.

ORCID iD Rachel Garty  <https://orcid.org/0009-0004-4339-1651>

Julius Klever  <https://orcid.org/0000-0002-6401-4853>

References

- Winblad K, Fransson BA, Svensson G, et al. **Aneurysmal bone cyst in the pelvis of a cat: successful outcome of partial ilectomy with limb preservation.** *JFMS Open Rep* 2020; 6. DOI: 10.1177/2055116920974984.
- Olson EJ and Carlson CS. **Bones, joints, tendons, and ligaments 1.** In: Zachary JF (ed). *Pathologic basis of veterinary disease*. 6th ed. St Louis: Elsevier, 2017, pp 954–1008.
- Towle HA and Breur GJ. **Miscellaneous orthopaedic conditions.** In: Johnston SA and Tobias KM (eds). *Veterinary surgery: small animal*. 2nd ed. St Louis: Elsevier, 2018, pp 1299–1315.
- Berger B, Brühshwein A, Eddicks L, et al. **Malignant transformation of a unicameral bone cyst in a cat.** *Can Vet J* 2016; 57: 377–381.
- Barnhart MD. **Malignant transformation of an aneurysmal bone cyst in a dog.** *Vet Surg* 2002; 31: 519–524.
- Quinn MM, Keuler NS, Lu Y, et al. **Evaluation of agreement between numerical rating scales, visual analogue scoring scales, and force plate gait analysis in dogs.** *Vet Surg* 2007; 36: 360–367.
- Amsellem PM, Young AN, Muirhead TL, et al. **Effect of distal ulnar ostectomy on carpal joint stability during weight bearing in the dog.** *Vet Surg* 2017; 46: 1154–1160.
- Young AN, Amsellem P, Muirhead TL, et al. **Ulnar ostectomy decreases the stability of canine cadaver carpi as assessed with stress radiography.** *Vet Radiol Ultrasound* 2019; 60: 19–27.
- Griffin MA, Martin TW, Thamm DH, et al. **Partial ulnar ostectomy, stereotactic body radiation therapy, and palliative radiation therapy as local limb sparing treatment modalities for ulnar tumors in dogs.** *Front Vet Sci* 2023. DOI: 10.3389/fvets.2023.1172139.
- Basa RM and Johnson KA. **Management of feline carpal injuries: what are the options and when is arthrodesis indicated?** *J Feline Med Surg* 2019; 21: 809–823.
- Kim K, Kim H, Kim H, et al. **Humeral aneurysmal bone cyst in a cat with sequential computed tomographic findings.** *Vet Sci* 2022; 9. DOI: 10.3390/vetsci9110594
- Benamou J, Lussier B, Alexander K, et al. **Use of magnetic resonance imaging and histopathologic findings for diagnosis of an aneurysmal bone cyst in the scapula of a cat.** *J Am Vet Med Assoc* 2012; 240: 69–74.
- Manca S, Mate de Haro L, Civello A, et al. **Aneurysmal bone cyst in the scapula of a young cat.** *Vet Rec Case Rep* 2022; 10. DOI: 10.1002/vrc2.459
- Billier DS, Johnson GC, Birchard SJ, et al. **Aneurysmal bone cyst in a rib of a cat.** *J Am Vet Med Assoc* 1987; 190: 1193–1195.
- Nicetto T, Coltro A and Massari F. **Tarsometatarsal stabilization after metatarsal bone amputation for treatment of an aneurysmal bone cyst in a cat.** *J Am Vet Med Assoc* 2021; 259: 294–299.
- Miura N, Fujiki M, Miyoshi Y, et al. **Steroid injection therapy in a feline solitary bone cyst.** *J Vet Med Sci* 2003; 65: 523–525.