



Successful treatment of non-pruritus, excessive hair shedding and scales in a cat due to *Demodex gatoi* with fluralaner topical spot-on

Authors: Chuenngam, Thapanee, and Chermprapai, Suttiwee

Source: Journal of Feline Medicine and Surgery Open Reports, 10(1)

Published By: SAGE Publishing

URL: <https://doi.org/10.1177/20551169241246866>



Successful treatment of non-pruritus, excessive hair shedding and scales in a cat due to *Demodex gatoi* with fluralaner topical spot-on

Journal of Feline Medicine and Surgery Open Reports
1–5

© The Author(s) 2024

Article reuse guidelines:

sagepub.com/journals-permissions

DOI: 10.1177/20551169241246866

journals.sagepub.com/home/jfmsopenreports

This paper was handled and processed by the European Editorial Office (ISFM) for publication in *JFMS Open Reports*



Thapanee Chuengnam¹ and Suttiwee Chermprapai²

Abstract

Case summary A 1-year-old female intact Scottish Fold cat was presented with a 1-month history of excessive hair shedding with white scales on the coat without pruritus. The cat lived mostly indoors and had no history of any systemic disease. Dermatological examinations were performed step by step. Several *Demodex gatoi* were identified from cellophane tape impressions from the scales and examined under a low-power objective (10×) microscope. Skin cytology showed keratinocytes without any microorganisms. Based on the findings, fluralaner (Bravecto for cats; MSD) spot-on was used once every 12 weeks for ectoparasiticide control. An essential fatty acid supplement was recommended to repair and restore the coat and skin barrier. After 4 weeks of treatment, the cat showed substantial improvement, with a normal coat and no scales. Re-examination using a cellophane tape impression for mites was negative. Ectoparasiticide control is highly recommended regularly for the treatment and prevention of ectoparasites.

Relevance and novel information Feline demodicosis is an uncommon parasitic dermatosis with primary clinical signs that may cause generalised or localised dermatitis with frequent pruritus, erythema and alopecia. The aims of this study were to report on dermatological lesions with excessive hair shedding and scales in a cat that were caused by demodicosis, without presenting the main clinical sign of pruritus or overgrooming. In addition, to the authors' knowledge, this is the first report of the successful treatment of demodicosis due to *D. gatoi* infestation with fluralaner single spot-on in an off-label use that was safe and easy to apply clinically.

Keywords: *Demodex gatoi*; excessive hair shedding; fluralaner; scales

Accepted: 13 March 2024

Introduction

Feline demodicosis is an uncommon parasitic dermatosis in cats.^{1–3} *Demodex gatoi*, a short-bodied mite that lives in the superficial skin in the stratum corneum,^{2–5} seems to be the most common demodicosis in cats.¹ The primary clinical signs of *D. gatoi* infestation are pruritus, overgrooming and self-induced alopecia.^{1–4,6} It is easily transmissible to other cats via casual contact and is not associated with underlying immunocompromise in most cases.^{1,4,7} Because *D. gatoi* is a superficial mite, diagnosis by superficial scrapings with mineral oil applied to the blade and skin should be performed; cellophane tape may also be used by impressing on the skin surface.^{1,4,7}

However, because this mite is translucent and has a small size,^{2,3,8} it can be difficult to detect directly on the

¹Dermatology Center, Kasetsart University Veterinary Teaching Hospital, Faculty of Veterinary Medicine, Kasetsart University, Bangkok, Thailand

²Department of Companion Animal Clinical Sciences, Faculty of Veterinary Medicine, Kasetsart University, Bangkok, Thailand

Corresponding author:

Suttiwee Chermprapai DVM, PhD, Department of Companion Animal Clinical Sciences, Faculty of Veterinary Medicine, Kasetsart University, 50 Ngamwongwan Road, Ladyao, Chatuchak, Bangkok, 10900, Thailand
Email: fvetstw@ku.ac.th



Creative Commons Non Commercial CC BY-NC: This article is distributed under the terms of the Creative Commons

Attribution-NonCommercial 4.0 License (<https://creativecommons.org/licenses/by-nc/4.0/>) which permits non-commercial use, reproduction and distribution of the work without further permission provided the original work is attributed as specified on the SAGE and Open Access pages (<https://us.sagepub.com/en-us/nam/open-access-at-sage>).

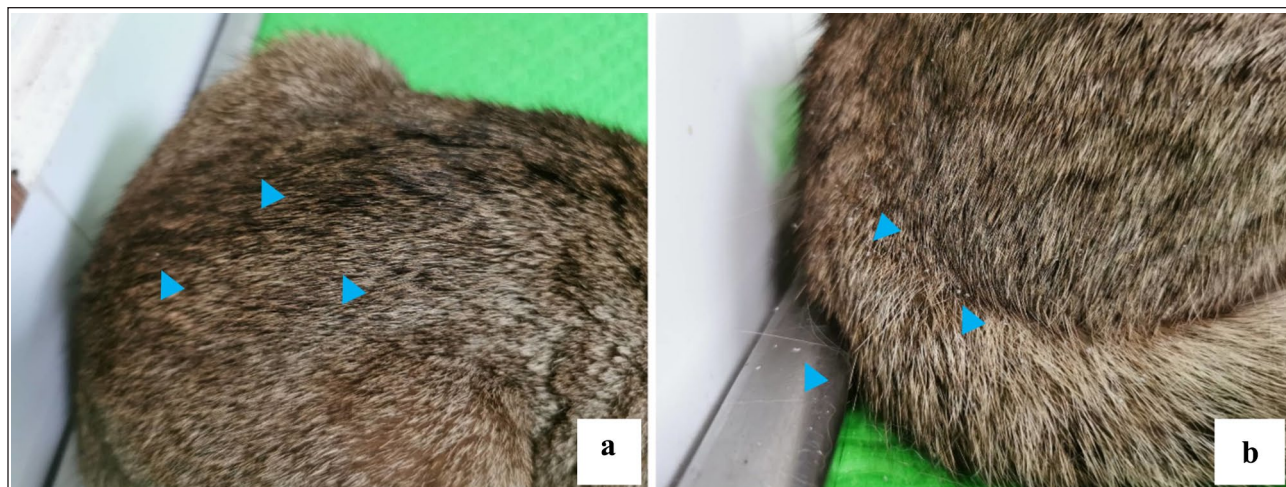


Figure 1 Clinical presentation of excessive hair shedding: (a,b) white scales (blue arrowheads) were found on the coat without marked hypotrichosis or alopecia

superficial scraping; thus, faecal floatation to detect undigested mites due to ingestion associated with excessive grooming can be helpful in diagnosing this mite.^{1,3,4,7,8}

In past decades, the treatment management for feline demodicosis has been difficult.^{2,8,9} For example, the use of 2% lime sulfur dips every 5–7 days for 4–6 weeks is both time- and labour-consuming.^{3,4,8,9} Amitraz may cause adverse effects and can be toxic to cats.^{7,9} Fluralaner is a drug in the group of isoxazolines, a new class of ectoparasitocides that have been used to treat demodicosis in cats and have been reported to be safe and effective in the treatment of feline demodicosis,^{3,8–14} for both *Demodex cati* and *D gatoi*.

This case report describes the diagnosis of *D gatoi* infestation in a cat presenting with excessive hair shedding and scales without pruritus (which has been reported as the main clinical sign of infestation)^{1–6} and the successful treatment using a fluralaner topical spot-on.

Case description

A 1-year-old female intact Scottish Fold cat was presented with a 1-month history of excessive hair shedding, with white scales observed on the coat without clinical signs of pruritus, alopecia or hypotrichosis (Figure 1). The cat lived mainly indoors, without any ectoparasiticide control having been given previously, in the same household with another cat with a history of feline atopic skin syndrome that had been treated using monthly selamectin spot-on for ectoparasite control. The physical examination, including heart and lung sound auscultation, oral cavity examination and lymph node palpation, was normal. Dermatological examinations were performed step by step. Flea combing to detect flea or flea dirt was negative. Trichogram revealed small numbers of the telogen phase of hair with several

short-bodied mites morphologically consistent with *D gatoi*, similar to the findings of cellophane tape impressions on the scaling areas, examined under a low-power objective (10×) microscope and identified as an adult stage of *D gatoi* (Figure 2). Skin cytology showed keratinocytes without any organisms. No fluorescence was detected on hairs under Wood's lamp examination. Based on the findings, fluralaner (Bravecto for cats; MSD) spot-on 250 mg/cat was used once for ectoparasitocidal control. In addition, an essential fatty acids supplement was recommended to repair and restore the coat and skin barrier. After 4 weeks of treatment, the cat showed substantial improvement, with a normal coat and no scales (Figure 3). Re-examination 1 month later using cellophane tape impression for mites was negative. Ectoparasitic control was continued once every 12 weeks for treatment and prevention of ectoparasites.

Discussion

Generally, pruritus, which usually manifests as overgrooming, hypotrichosis or alopecia, is the primary clinical presentation of *D gatoi* infestation.^{1–6} Intense pruritus seems to be associated with a hypersensitivity reaction to the mite.^{1–3} This case presented dermatological lesions in a cat with excessive hair shedding, white scales due to *D gatoi* infestation without pruritus, with the successful treatment supporting the efficacy of the safe use of single-dose fluralaner spot-on for the control of *D gatoi* as an off-label treatment for demodicosis in cats.

Where there are skin lesions of excessive hair shedding with white scales, without systemic signs involved, dermatological examinations should be performed step by step. It is possible that the clinical presentation of excessive scaling is a manifestation of mite (*Cheyletiella* species and *D gatoi*) proliferation.^{4,5} Ruling out ectoparasites can be achieved by skin scraping, trichogramography

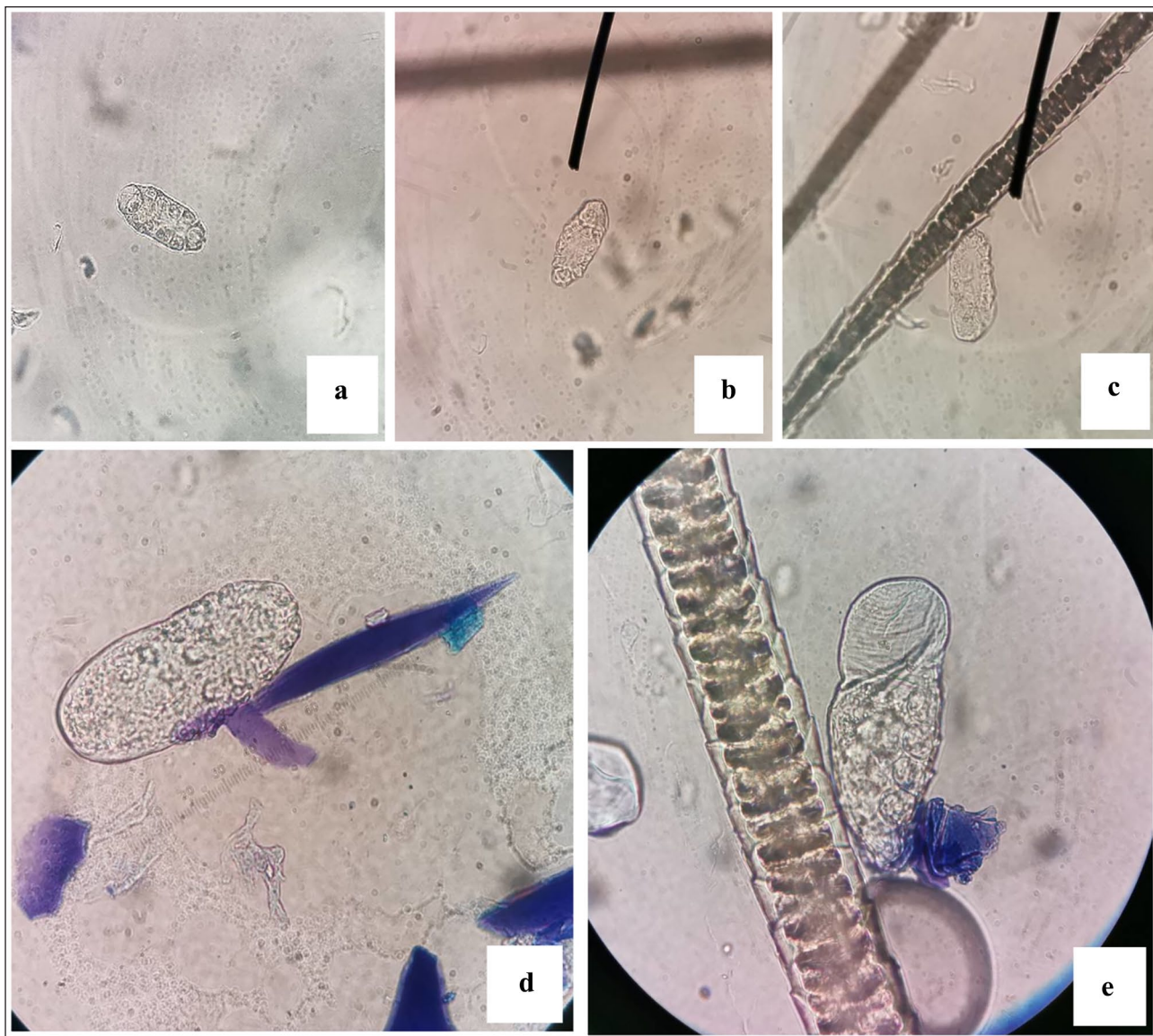


Figure 2 Light microscopy of scales collected from cellophane tape impression: (a–c) multiple short-bodied mites morphologically consistent with *Demodex gatoi* at $\times 100$ magnification. (d,e) $\times 1000$ magnification of *D gatoi* (stained with methylene blue)

and coat brushing.⁵ Cellophane tape impression to detect superficial mites has also been described.⁴ Abnormalities of the hair, such as broken hair tips, were not detected based on the trichogram, indicating that this cat did not have the habit of licking and overgrooming. Skin cytology identified keratinocytes without any organism. In this case, *D gatoi* was diagnosed using the cellophane tape impression technique, which is easy, rapid and cheap.² The detection of mites can be used to confirm an infestation; however, in some, it is not easy to detect this mite because of its translucence and small size.^{2,3,8} In addition, severe self-induced alopecia pruritic cats in particular will decrease the number of mites on the stratum corneum, making a correct diagnosis challenging.

Alternatively, faecal floatation for demodex in faeces should be examined for diagnosis.^{2-4,7,8} *D gatoi* infestation should be included in a differential list in cats with excessive scaling, with or without pruritus.

The conventional treatment of *D gatoi* infestation is 2% lime sulfur dips or 0.0125% amitraz baths; however, both treatments are not always tolerated by infected cats.^{4,12-14} Oral ivermectin, 0.2–0.3 mg/kg q24h or q48h, has been effective in some cases but failure has also been reported.¹ Weekly topical selamectin administered was ineffective.^{2,3} Weekly topical moxidectin/imidacloprid spot-on administration has been reported as an alternative successful treatment of *D gatoi* infestation in cats.^{4,15} There were contradictory results regarding successful

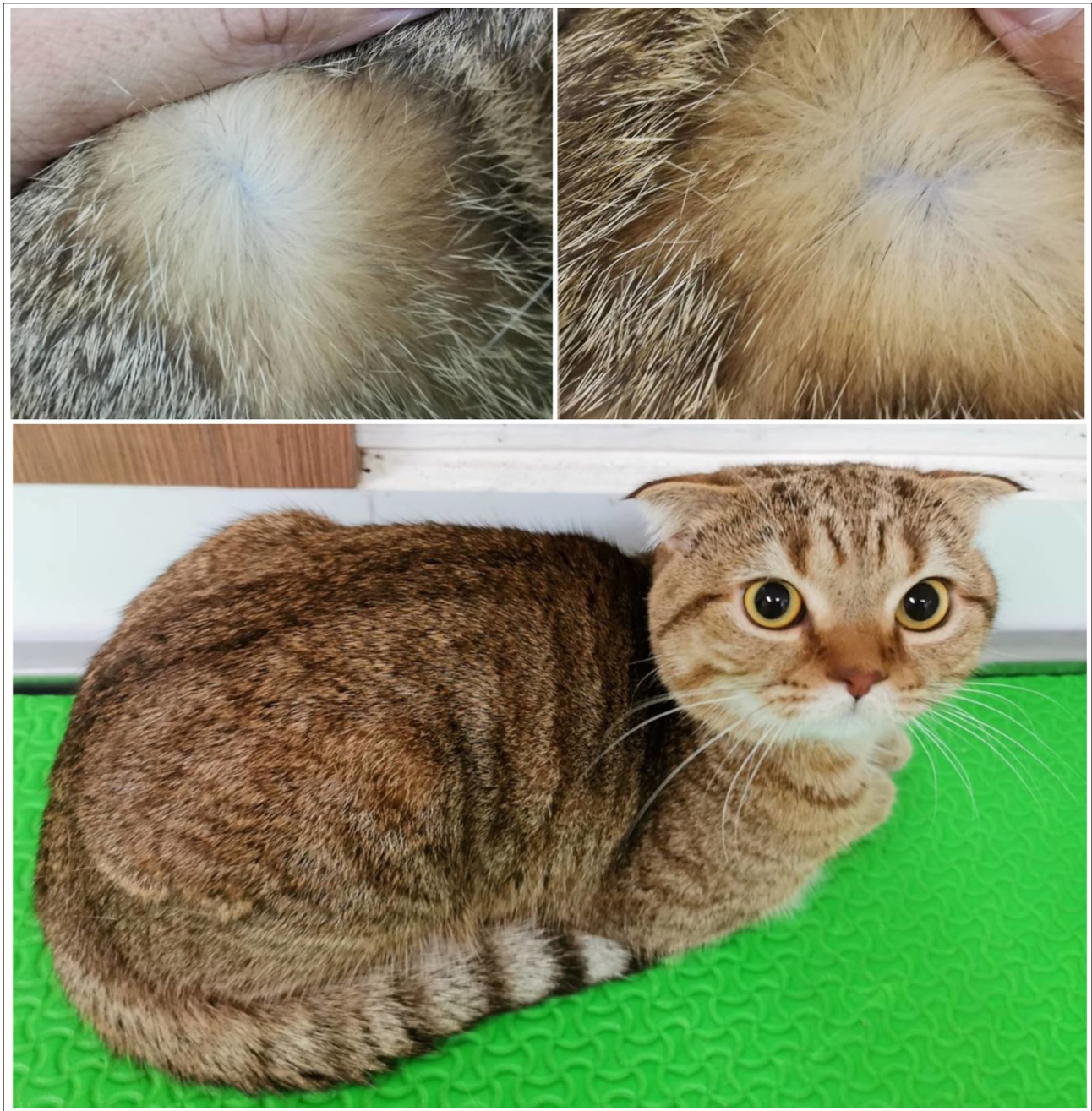

Figure 3 After 4 weeks of treatment, the cat showed substantial improvement, with a normal coat without scales

treatment using topical moxidectin.¹ Fluralaner is one of the drugs in the group of isoxazolines, labelled for the treatment and prevention of fleas and for the treatment and control of black-legged ticks in cats^{14,16} by inhibiting both gamma-aminobutyric acid and glutamate-gated chloride channels with high selectivity for arthropod rather than mammalian receptors.^{12,13} Clinical cases have reported the efficacy of off-label oral fluralaner for the treatment of *D gatoi* in two shelter cats⁸ and topical fluralaner spot-on for the treatment of demodicosis due to

D cati.^{9-11,13,14} To the authors' knowledge, this was the first report of the successful treatment of demodicosis due to *D gatoi* infestation by applying topical fluralaner spot-on, supporting the efficacy of the safe use of single-dose fluralaner spot-on for the control of *D gatoi* as an off-label treatment for demodicosis in cats.

In this case, follow-up dermatological examination was carried out on the affected cat every 4 weeks. The skin and coat were normal. A cellophane tape impression revealed no mites, which confirmed the resolution

of the infestation. However, *D gatoi* is easy to transmit by casual contact; consequently, the infected cat and the other cat in the same household were both prescribed fluralaner spot-on to prevent reinfestation.

This report showed the efficacy of successful treatment of infestation in one application. Additional studies should evaluate the duration of fluralaner efficacy to control *D gatoi* infestation for further repeat drug applications to prevent re-infestation.

Conclusions



D gatoi infestation in a cat can be presented as only scales and excessive hair shedding without pruritus. Although pruritus is not a primary sign, demodicosis should be one of the differential diagnoses and step-by-step dermatological examinations should be performed. One application of the off-label use of topical fluralaner spot-on successfully treated the cat infested with *D gatoi* without adverse effects. The topical application of fluralaner is an effective and easy-to-use treatment of *D gatoi* infestation in cats.

Conflict of interest The authors declared no potential conflicts of interest with respect to the research, authorship, and/or publication of this article.

Funding The authors received no financial support for the research, authorship, and/or publication of this article.

Ethical approval The work described in this manuscript involved the use of non-experimental (owned or unowned) animals. Established internationally recognised high standards ('best practice') of veterinary clinical care for the individual patient were always followed and/or this work involved the use of cadavers. Ethical approval from a committee was therefore not specifically required for publication in *JFMS Open Reports*. Although not required, where ethical approval was still obtained, it is stated in the manuscript.

Informed consent Informed consent (verbal or written) was obtained from the owner or legal custodian of all animal(s) described in this work (experimental or non-experimental animals, including cadavers) for all procedure(s) undertaken (prospective or retrospective studies). No animals or people are identifiable within this publication, and therefore additional informed consent for publication was not required.

ORCID ID Thapanee Chuenngam  <https://orcid.org/0009-0002-7572-8197>
Suttiwee Chermprapai  <https://orcid.org/0000-0003-1665-5848>

References

- 1 Beale K. **Feline demodicosis: a consideration in the itchy or overgrooming cat.** *J Feline Med Surg* 2012; 14: 209–213.
- 2 Saari SAM, Juuti KH, Palojarvi JH, et al. **Demodex gatoi-associated contagious pruritic dermatosis in cats—a report from six households in Finland.** *Acta Vet Scand* 2009; 51. DOI: 10.1186/1751-0147-51-40.
- 3 De Almeida GPS, Campos DR, Scott FB, et al. **Successful treatment of feline demodicosis with oral sarolaner: case report.** *Bras Med Vet* 2020; 42. DOI: 10.29374/2527-2179.bjvm113420.
- 4 Mueller RS, Rosenkrantz W, Bensignor E, et al. **Diagnosis and treatment of demodicosis in dogs and cats: clinical consensus guidelines of the World Association for Veterinary Dermatology.** *Vet Dermatol* 2020; 31: 5–27.
- 5 Miller WH, Griffin CE and Campbell KL. **Parasitic skin disease.** In: Miller WH, Griffin CE and Campbell KL (eds). *Small animal dermatology*. 7th ed. St Louis, MO: Elsevier Mosby, 2013, pp 284–342.
- 6 Guaguere E, Muller A and Degorce-Rubiales F. **Feline demodicosis: a retrospective study of 12 cases.** *Vet Dermatol* 2004; 15: S34.
- 7 Silbermayr K, Joachim A, Litschauer B, et al. **The first case of Demodex gatoi in Austria, detected with fecal flotation.** *Parasitol Res* 2013; 112: 2805–2810.
- 8 Duangkaew L and Hoffman H. **Efficacy of oral fluralaner for the treatment of Demodex gatoi in two shelter cats.** *Vet Dermatol* 2018; 29: 262.
- 9 Bouza-Rapti P, Tachmazidou A and Farmaki R. **Effectiveness of a fluralaner spot-on formulation in a case of feline demodicosis due to Demodex cati.** *JFMS Open Rep* 2022; 8. DOI: 10.1177/20551169211069529.
- 10 Zhou X, Hohman A and Hsu WH. **Review of extralabel use of isoxazolines for treatment of demodicosis in dogs and cats.** *J Am Vet Med Assoc* 2020; 256: 1342–1346.
- 11 Zhou X, Hohman A and Hsu WH. **Current review of isoxazoline ectoparasiticides used in veterinary medicine.** *J Vet Pharmacol Ther* 2021; 45: 1–15.
- 12 Simpson AC. **Successful treatment of otodemodicosis due to Demodex cati with sarolaner/selamectin topical solution in a cat.** *JFMS Open Rep* 2021; 7. DOI: 10.1177/2055116920984386.
- 13 Chansiripornchai P and Chansiripornchai N. **Successful treatment of demodicosis due to Demodex cati in a cat using spot-on formulation of fluralaner.** *Thai J Vet Med* 2021; 51: 789–793.
- 14 Matricoti I and Maina E. **The use of oral fluralaner for the treatment of feline generalised demodicosis: a case report.** *J Small Anim Pract* 2017; 58: 476–479.
- 15 Jeanmarie S and Dunbar G. **Successful treatment of Demodex gatoi with 10% imidacloprid/1% moxidectin.** *J Am Anim Hosp Assoc* 2016; 52: 68–72.
- 16 MSD Website. **Bravecto product label.** <https://www.bravecto.com.au/bravecto-spot-on-for-cats/> (2019, accessed 11 August 2020).