



Severe pericardial effusion in a cat with peritoneopericardial diaphragmatic hernia and incarcerated hepatic sarcoma

Authors: Ciaravolo, Susan V, Dobson, Elizabeth, Liffman, Rebekah, and Stickney, Alison

Source: Journal of Feline Medicine and Surgery Open Reports, 8(2)

Published By: SAGE Publishing

URL: <https://doi.org/10.1177/20551169221121926>



Severe pericardial effusion in a cat with peritoneopericardial diaphragmatic hernia and incarcerated hepatic sarcoma

Susan V Ciaravolo¹, Elizabeth Dobson²,
Rebekah Liffman² and Alison Stickney¹

Journal of Feline Medicine and Surgery Open Reports
1–6

© The Author(s) 2022

Article reuse guidelines:

sagepub.com/journals-permissions

DOI: 10.1177/20551169221121926

journals.sagepub.com/home/jfmsopenreports

This paper was handled and processed by the European Editorial Office (ISFM) for publication in *JFMS Open Reports*



Abstract

Case summary A 4-year-old female neutered domestic longhair cat was presented at a referral hospital for dyspnoea with a history of suspected pleural effusion. Thoracic ultrasonography demonstrated a large-volume pericardial effusion causing cardiac tamponade and a cystic mass within the pericardium. CT revealed a peritoneopericardial diaphragmatic hernia (PPDH) caused by a defect of the ventral diaphragm. Herniated contents consisted of the right lateral and caudate liver lobes, and an associated cystic hepatic mass. Ventral midline coeliotomy was performed for herniorrhaphy and partial pericardiectomy, together with lobectomy of the incarcerated liver mass. Histopathology and immunohistochemistry diagnosed a poorly differentiated hepatic sarcoma with inflammation and remodelling in the adjacent incarcerated liver parenchyma. The patient developed metastatic sarcoma 2 months after surgery and was euthanased as a result.

Relevance and novel information Pericardial effusion causing cardiac tamponade is a previously unreported sequelae to PPDH in cats. Reports on the presence of malignancy in incarcerated liver are scarce and the location is not typical for a sarcoma in this species.

Keywords: Peritoneopericardial diaphragmatic hernia; sarcoma; pericardial effusion; cardiac tamponade

Accepted: 28 July 2022

Introduction

Feline peritoneopericardial diaphragmatic hernia (PPDH) is a congenital malformation caused by disruption of the division of pleural and peritoneal cavities in early embryogenesis, resulting in a defect of the ventral diaphragm. It is an incidental finding or associated with only mild gastrointestinal or respiratory signs.^{1–3}

Pericardial effusion (PE) is uncommon in cats, is usually low volume and is rarely severe enough to cause cardiac tamponade.⁴ Congestive heart failure is the most common cause of PE in cats; less common are non-cardiac causes, including neoplasia (lymphoma or carcinoma) and feline infectious peritonitis.^{4,5} There are no previous reports of PPDH causing severe PE and cardiac tamponade in a cat, and only a single case reported in dogs.^{6,7}

Prevalence studies demonstrate that soft tissue sarcomas are relatively common feline tumours (20.6%), while

primary hepatic tumours are rare (1.3%) and mostly of epithelial cell origin.^{8–11} Feline injection site sarcomas (FISSs) are thought to develop secondarily to chronic inflammation, induced by vaccine adjuvants, acting as a trigger for malignant transformation through uncontrolled proliferation of fibroblasts and myoblasts.^{12,13} Reports of sarcomas arising within other chronically inflamed sites suggest that similar mechanisms could predispose to malignant transformation elsewhere.^{12,13}

¹Peninsula Vet Emergency and Referral Hospital, Melbourne, Victoria, Australia

²ASAP Laboratory, Melbourne, Victoria, Australia

Corresponding author:

Susan V Ciaravolo BSc, DVM, MANZCVS (Medicine), Peninsula Vet Emergency and Referral Hospital, 2/161 Mornington-Tyabb Road, Mornington, VIC 3931, Australia
Email: susan@penvetreferral.com.au



Creative Commons Non Commercial CC BY-NC: This article is distributed under the terms of the Creative Commons

Attribution-NonCommercial 4.0 License (<https://creativecommons.org/licenses/by-nc/4.0/>) which permits non-commercial use, reproduction and distribution of the work without further permission provided the original work is attributed as specified on the SAGE and Open Access pages (<https://us.sagepub.com/en-us/nam/open-access-at-sage>).

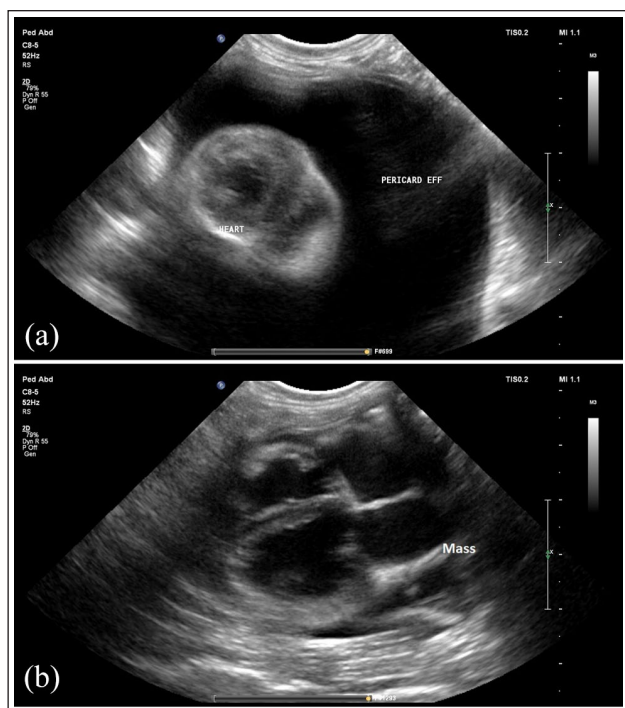


Figure 1 (a) Thoracic ultrasonography of a cat with peritoneopericardial diaphragmatic hernia demonstrating large-volume anechoic pericardial effusion and (b) the heterogeneous cystic mass lesion within the pericardium, identified after pericardiocentesis, caudal to the heart

This report describes a cat with PPDH containing herniated liver that underwent malignant transformation, causing severe PE and subsequent cardiac tamponade, sequelae that have not been reported previously.

Case description

A 4-year-old female neutered domestic longhair cat with a chronic history of intermittent vomiting and fluctuating appetite was referred following a 4-week history of progressive lethargy, hyporexia and increased respiratory effort. Thoracic radiographs and blind thoracocentesis of a suspected pleural effusion were performed prior to referral, removing 150 ml of straw-coloured high protein transudate (total nucleated cell count, 1.8×10^9 cells/l; total protein, 40 g/l). Complete blood count and minimum database biochemistry detected no abnormalities. After centesis, respiratory signs and appetite improved; no further treatment was administered.

At presentation to the referral hospital, 7 days after centesis, physical examination abnormalities included tachypnoea (60 breaths/min), increased inspiratory effort, tachycardia (220 beats/min), diffusely muffled heart and lung sounds and a lean body condition (score 3/9, weight 4.43 kg)

Thoracic ultrasonography identified large-volume PE and cardiac tamponade (Figure 1a). Electrocardiogram

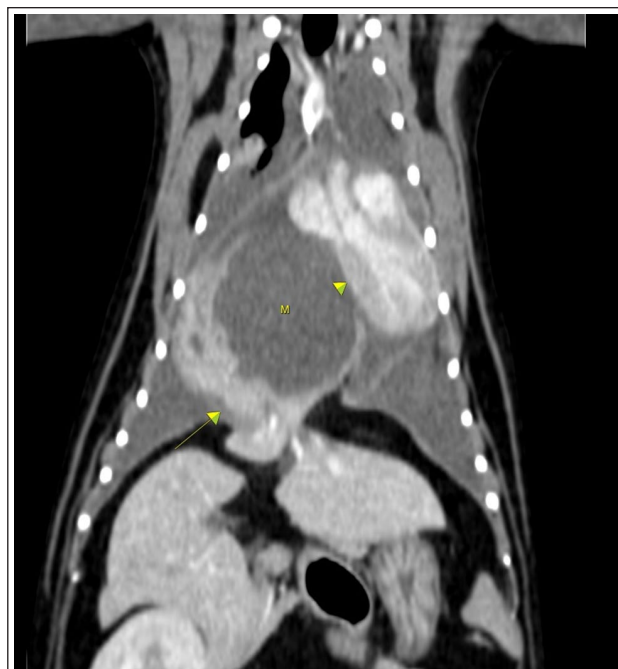

Figure 2 CT angiography of thorax, dorsal reconstruction: right lateral and quadrate liver displaced cranially through ventral diaphragm defect (arrow) with a large cavitory, fluid-filled, lesion (M) originating from the herniated hepatic parenchyma. The lesion was causing left lateral displacement of the heart and direct compression of right heart chambers (arrowhead)

(ECG) was consistent with electrical alternans. The patient was anaesthetised (butorphanol 0.2 mg/kg IV; propofol IV induction and inhaled isoflurane maintenance) to reduce movement and allow for control of ventilation during pericardiocentesis. Ultrasound-guided pericardiocentesis, using a 14 G fenestrated polyurethane catheter (MILACATH extended use; MILA International) inserted at the fifth intercostal space, removed 300 ml straw-coloured effusion (low cellularity, high-protein transudate; total protein 45 g/l). Subsequently, tachycardia and ECG abnormalities resolved, repeat ultrasound identified a cystic mass caudal to the heart (Figure 1b), subjectively normal cardiac structure and contractility and small-volume pleural effusion.

CT of the thorax and abdomen, pre- and post-intravenous iohexol contrast (Omnipaque; GE Healthcare), was performed (GE Healthcare Lightspeed 16 slice CT scanner, reconstructed using bone, soft tissue [pre- and post-contrast] and lung algorithms), and identified a large defect in the ventral diaphragm with herniated right lateral and quadrate liver lobes (PPDH). Arising from the herniated liver was a 4.5 cm diameter, well-defined cavitory mass, directly compressing the right cardiac chambers and causing left lateral displacement of the heart (Figure 2). The mass was thought to

represent either necrosis, inflammatory change or neoplasia. Other abnormalities included small-volume pleural effusion, mild lymph node enlargement, absent gallbladder and transitional T13 vertebrae.

The following day the patient underwent herniorrhaphy via a ventral midline coeliotomy. Anaesthesia included fentanyl 3 µg/kg, ketamine 0.5 mg/kg and midazolam 0.2 mg/kg IV premedication, alfaxalone 2 mg/kg IV induction, fentanyl 3 µg/kg/h and ketamine 0.1 mg/kg/h constant rate infusions (CRIs) with inhaled isoflurane for maintenance. The diaphragmatic defect was enlarged radially, adhesions to the pericardium were manually dissected and herniated contents retrieved. Right lateral and quadrate liver lobectomy, including associated mass, was performed with a DST Series TA V30 linear stapler (Medtronic). Partial pericardiectomy was also performed to reduce the risk of future restrictive pericarditis, pericardial cyst formation or recurrent tamponade. 3/0 Polydioxanone (PDS) suture (Wego-PDO; Foosin Medical Supplies) in a continuous pattern apposed diaphragm edges for herniorrhaphy. A 14G thoracostomy tube (Guidewire Inserted Chest Tube; MILA International) was placed in the left hemithorax, as per the manufacturer's instructions, and secured with 3/0 PDS suture. The patient recovered uneventfully; fentanyl and ketamine CRIs were weaned with regular assessment of pain scores. The thoracostomy tube was removed after 8h as it was non-productive, with no recurrence of effusion. The patient was discharged home the following evening.

Histological examination, with routine haematoxylin and eosin staining, of the resected liver lobe and mass found a moderately well circumscribed but locally infiltrative proliferation of neoplastic polygonal-to-spindle cells with scant supporting stroma (Figure 3). The large cystic space contained necrotic debris, haemorrhage, aggregates of mineral and sloughed cells with abundant mucous in some sections. Around the periphery was a thick wall of reactive fibroplasia within which were proliferating bile ducts. The neoplastic cells had variably distinct cell borders and typically a moderate amount of eosinophilic fibrillar cytoplasm and round-to-oval nuclei with stippled chromatin and large size nucleoli. The cells had moderate anisokaryosis with scattered large size nuclei and occasional multinucleation. Twenty-two mitotic figures were counted in 10 high-power fields.

Liver adjacent to the mass had severe loss of normal architecture and marked, mixed inflammation. There was extensive bile duct hyperplasia with atypia and scattered mitoses in some biliary epithelial cells; in some areas, the hepatocytes were pleomorphic with enlarged, atypical nuclei. Atypical spindle cells were dispersed throughout the sinusoids (Figure 4). Immunohistochemical stains (vimentin, cytokeratin 7, HepPar-1, factor 8) were applied to the sections. All atypical cells

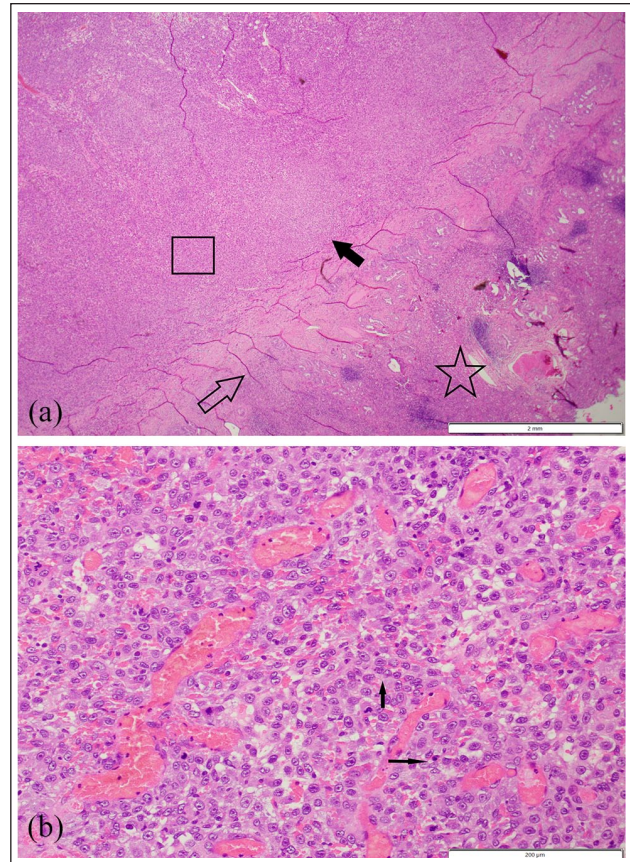


Figure 3 Histopathology of the incarcerated hepatic neoplasm (haematoxylin and eosin, [a] $\times 20$ and [b] $\times 200$) consisting of neoplastic polygonal spindle cells effacing hepatic parenchyma (examples indicated by filled arrows) with extensive fibrosis (open arrow), inflammation and parenchymal loss of the adjacent liver (star). Square denotes the region of the mass magnified for (b)

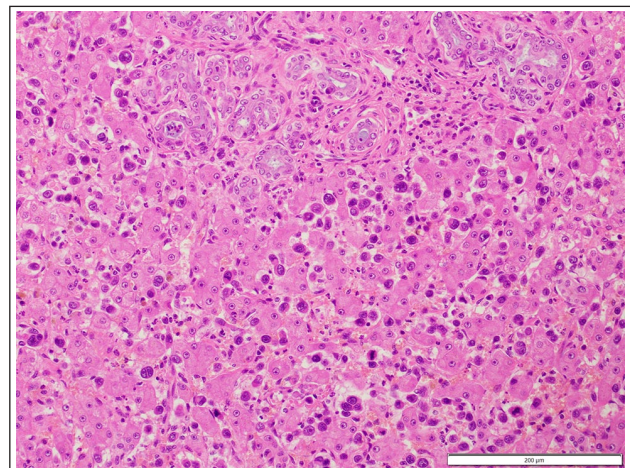


Figure 4 Histopathology of the liver adjacent to the mass with sinusoidal atypical spindle cells, biliary hyperplasia, peribiliary fibrosis and occasional hepatocyte atypia (haematoxylin and eosin, $\times 200$)

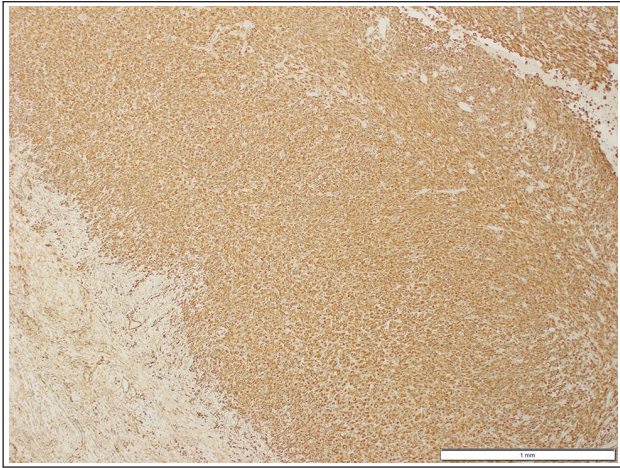


Figure 5 Immunohistochemical staining of the incarcerated hepatic neoplasm with vimentin has strong positive staining of malignant spindle cells and negative staining of hepatocytes (vimentin, $\times 40$)

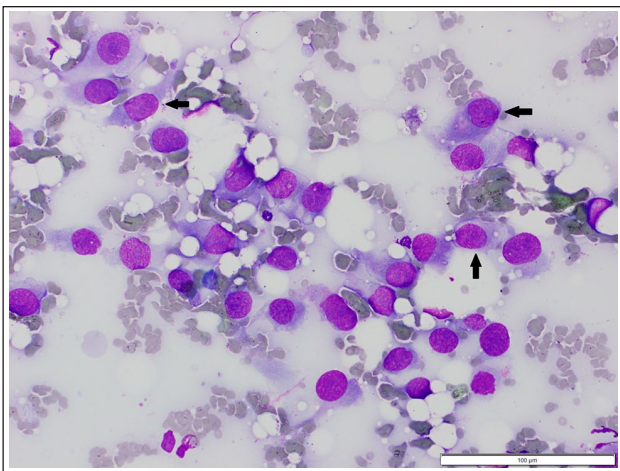


Figure 6 Cytology of the abdominal mass, detected 2 months after excision of hepatic sarcoma, composed of atypical spindloid cells (black arrows) with multiple features of malignancy (Wright–Giemsa, $\times 400$)

in the mass and dispersed in sinusoids stained strongly with vimentin (mesenchymal cell marker; Figure 5) but did not stain with factor 8, cytokeratin 7 or HepPar-1 (endothelial, biliary epithelial and hepatocyte markers, respectively). Staining confirmed the mass was consistent with a poorly differentiated sarcoma rather than carcinoma.

Two weeks after surgery the patient was gaining weight and the clinical signs had resolved. Repeat thoracic ultrasound found no pleural or pericardial effusion, and ultrasonographic evaluation of the remaining liver was unremarkable.

Two months postoperatively the patient re-presented with reduced appetite, weight loss and vomiting.

Abdominal ultrasound identified a hypoechoic splenic nodule and a mass in the right cranial abdomen, both of which were aspirated. Cytological evaluation of smears from both sites (stained with Wright–Giemsa [Figure 6]) contained low-to-moderate numbers of atypical spindle cells, with a moderate amount of wispy basophilic cytoplasm that was often finely vacuolated. Nuclei were round to oval, with coarsely stippled chromatin and large prominent nucleoli. Occasional binucleated cells were present, the cells displayed karyomegaly, a high nuclear-to-cytoplasmic ratio and moderate anisocytosis and anisokaryosis. Combined with the clinical history, the features of the smears were diagnostic of sarcoma and presumed to be metastatic disease.

The owners declined further surgical intervention or chemotherapy, electing to palliate with prednisolone (1 mg/kg PO q12h) until euthanasia 2 months later.

Discussion

The cat in this report uniquely presented for clinical manifestations of cardiac tamponade from a large-volume PE secondary to PPDH with an incarcerated neoplasm. Reports of cardiac tamponade from intrapericardial hepatic cysts exist but lack concurrent PE or malignancy.^{14–16} PE associated with PPDH is usually minor, except one recent report of an 8-month-old dog with an intrapericardial pseudocyst.^{4,6,7}

The patient in this report had a history of mild gastrointestinal signs, common in PPDH, but respiratory signs developed over 4 weeks, likely reflecting the development of PE and expansion of the space-occupying mass in the thorax. The volume of effusion indicated chronic accumulation, which may have developed secondarily to inflammation of the incarcerated liver or the expanding neoplasm. Neoplastic PE secondary to sarcoma is an unusual finding, as it is most often associated with lymphoma or abdominal carcinoma.^{4,5,7}

The referring veterinarian's radiographs were not reviewed, but it is suspected that the large-volume PE may have been mistaken as pleural fluid. If pleural effusion was present, it could have been due to the developing PE or the mass compressing the right heart causing right-sided congestive heart failure. The latter is considered less likely owing to the resolution of tachycardia and ECG abnormalities following pericardiocentesis, despite the mass remaining within the pericardium.

Soft tissue sarcomas are not uncommon in cats, but are most often identified on the limbs or trunk rather than arising from abdominal organs.¹² Primary hepatic neoplasia in cats is uncommon and most often an epithelial origin malignancy (hepatic carcinoma or biliary cholangiocarcinoma).^{8–11} Visceral haemangiosarcomas are infrequently reported, while other sarcomas arising within hepatic parenchyma are scarce.¹⁷

In this case, a poorly differentiated sarcoma arose within an incarcerated liver lobe. Negative factor 8

immunohistochemical staining suggested the tumour was not consistent with a haemangiosarcoma. The severe chronic inflammation and fibroplasia in adjacent hepatic parenchyma could suggest that malignant transformation occurred secondarily to the incarceration, not unlike the theorised mechanism for FISS development.^{12,13} Alternatively, these inflammatory changes may have developed secondarily to the malignancy. The neoplastic cell population infiltrated the adjacent liver with an unusual dispersal of highly atypical cells within sinusoids of intact hepatocytes. These cells were not further classified but could represent hepatic stem cells or unusual local tumour invasion, or be similar to the microscopic foci of sarcoma identified in adjacent granulomatous tissue in FISS.

This sarcoma exhibited behaviours comparable to FISS, which have a rapid and extremely high recurrence rate (30–70%) if incompletely excised.^{12,13} Complete surgical excision was not achieved in the present case owing to the intimate association of the neoplasm with adjacent liver, diaphragm and pericardium. We suspect the mass identified at follow-up was tumour recurrence, rather than metastatic disease, owing to the right cranial abdomen location, while the nodule in the spleen was more consistent with metastatic disease. FISSs have a low reported incidence of metastasis (5–28%). The rapid metastasis in this case may have been a result of the abdominal location, seeding during surgery or aggressive biological behaviour.¹²

Multiple case series report prolonged survival in feline patients with PPDH, both with and without surgical intervention, indicating that malignant transformation of herniated viscera is a rare occurrence.^{1,3,18,19} Three case reports document malignant transformation of herniated liver in PPDH; all cats were >11 years of age and two did not survive to discharge.^{20–22} One was euthanased owing to metastatic cholangiocarcinoma at the time of investigation, one died of cardiorespiratory arrest 44h after excision of a hepatic fibrosarcoma and herniorrhaphy, and the final cat had an incarcerated hepatic myelolipoma which was removed without complication or recurrence. Although considerably younger, the poor outcome in the present case is similar to previous reports.

Conclusions

The sequelae to malignant transformation of incarcerated liver in a PPDH in this case are unique. Although rare, malignancy should be considered a differential diagnosis in cats that develop clinical signs where PPDH was previously asymptomatic, regardless of age.

Conflict of interest The authors declared no potential conflicts of interest with respect to the research, authorship, and/or publication of this article.

Funding The authors received no financial support for the research, authorship, and/or publication of this article.

Ethical approval The work described in this manuscript involved the use of non-experimental (owned or unowned) animals. Established internationally recognised high standards ('best practice') of veterinary clinical care for the individual patient were always followed and/or this work involved the use of cadavers. Ethical approval from a committee was therefore not specifically required for publication in *JFMS Open Reports*. Although not required, where ethical approval was still obtained, it is stated in the manuscript.

Informed consent Informed consent (verbal or written) was obtained from the owner or legal custodian of all animal(s) described in this work (experimental or non-experimental animals, including cadavers) for all procedure(s) undertaken (prospective or retrospective studies). No animals or people are identifiable within this publication, and therefore additional informed consent for publication was not required.

References

- 1 Wilson GP, Newton CD and Burt JK. **A review of 116 diaphragmatic hernias in dogs and cats.** *J Am Vet Med Assoc* 1971; 159: 1142–1145.
- 2 Margolis C, Pipan MZ, Demchur J, et al. **Congenital peritoneopericardial diaphragmatic hernia in a family of Persian cats.** *JFMS Open Rep* 2018; 4. DOI: 10.1177/2055116918804305.
- 3 Reimer SB, Kyles AE, Filipowicz DE, et al. **Long-term outcome of cats treated conservatively or surgically for peritoneopericardial diaphragmatic hernia: 66 cases (1987–2002).** *J Am Vet Med Assoc* 2004; 224: 728–732.
- 4 Hall DJ, Shofer F, Meier CK, et al. **Pericardial effusion in cats: a retrospective study of clinical findings and outcome in 146 cats.** *J Vet Intern Med* 2007; 21: 1002–1007.
- 5 Dempsey SM and Ewing PJ. **A review of the pathophysiology, classification, and analysis of canine and feline cavity effusions.** *J Am Anim Hosp Assoc* 2011; 47: 1–11. DOI: 10.5326/JAAHA-MS-5558.
- 6 Hennink I, Düver P, Rytz U, et al. **Case report: unusual peritoneopericardial diaphragmatic hernia in an 8-month-old German Shepherd dog, associated with a pericardial pseudocyst and coexisting severe pericardial effusion resulting in right-sided heart failure.** *Front Vet Sci* 2021; 8: 673543. DOI: 10.3389/fvets.2021.673543.
- 7 Davidson BJ, Paling AC, Lahmers SL, et al. **Disease association and clinical assessment of feline pericardial effusion.** *J Am Anim Hosp Assoc* 2008; 44: 5–9. DOI: 10.5326/0440005.
- 8 Manuali E, Forte C, Vichi G, et al. **Tumours in European Shorthair cats: a retrospective study of 680 cases.** *J Feline Med Surg* 2020; 22: 1095–1102.
- 9 van Sprundel RGHM, van den Ingh TSAM, Guscetti F, et al. **Classification of primary hepatic tumours in the cat.** *Vet J* 2014; 202: 255–266.
- 10 Patnaik AK. **A morphologic and immunocytochemical study of hepatic neoplasms in cats.** *Vet Pathol* 1992; 29: 405–415.

- 11 Lawrence HJ, Erb HN and Harvey HJ. **Non-lymphomatous hepatobiliary masses in cats: 41 cases (1972 to 1991).** *Vet Surg* 1994; 23: 365–368.
- 12 Hartmann K, Day MJ, Thiry E, et al. **Feline injection-site sarcoma: ABCD guidelines on prevention and management.** *J Feline Med Surg* 2015; 17: 606–613.
- 13 McEntee MC and Page RL. **Feline vaccine-associated sarcomas.** *J Vet Intern Med* 2001; 15: 176–182.
- 14 Scruggs SM and Bright JM. **Chronic cardiac tamponade in a cat caused by an intrapericardial biliary cyst.** *J Feline Med Surg* 2010; 12: 338–340.
- 15 Liptak J, Bissett S, Allan G, et al. **Hepatic cysts incarcerated in a peritoneopericardial diaphragmatic hernia.** *J Feline Med Surg* 2002; 4: 123–125.
- 16 Less R, Bright J and Orton E. **Intrapericardial cyst causing cardiac tamponade in a cat.** *J Am Anim Hosp Assoc* 2000; 36: 115–119.
- 17 Culp WTN, Drobotz KJ, Glassman MM, et al. **Feline visceral hemangiosarcoma.** *J Vet Intern Med* 2008; 22: 148–152.
- 18 Burns CG, Bergh MS and McLoughlin MA. **Surgical and nonsurgical treatment of peritoneopericardial diaphragmatic hernia in dogs and cats: 58 cases (1999–2008).** *J Am Vet Med Assoc* 2013; 242: 643–650.
- 19 Banz AC and Gottfried SD. **Peritoneopericardial diaphragmatic hernia: a retrospective study of 31 cats and eight dogs.** *J Am Anim Hosp Assoc* 2010; 46: 398–404.
- 20 Barge P, Sebastián-Marcos P, Martínez M, et al. **Cholangiocarcinoma and hepatic myelolipoma incarcerated in a peritoneopericardial diaphragmatic hernia with pulmonary metastasis and carcinomatosis in a cat.** *JFMS Open Rep* 2019; 5. DOI: 10.1177/2055116919835081.
- 21 Linton M, Tong L, Simon A, et al. **Hepatic fibrosarcoma incarcerated in a peritoneopericardial diaphragmatic hernia in a cat.** *JFMS Open Rep* 2016; 2. DOI: 10.1177/2055116916638681.
- 22 Wouda R, Chalkley M, Fraser A, et al. **Hepatic myelolipoma incarcerated in a peritoneopericardial diaphragmatic hernia in a cat.** *Aust Vet J* 2010; 88: 231–235.