



Long-term outcome after total scapulectomy for the treatment of osteosarcoma in a cat

Authors: Pfitzer, Johannes M, Natsios, Pavlos, Beer, Patricia, and Nolff, Mirja C

Source: Journal of Feline Medicine and Surgery Open Reports, 8(2)

Published By: SAGE Publishing

URL: <https://doi.org/10.1177/20551169221121901>



Long-term outcome after total scapulectomy for the treatment of osteosarcoma in a cat

Johannes M Pfitzer, Pavlos Natsios ,
Patricia Beer  and Mirja C Nolff 

Journal of Feline Medicine and Surgery Open Reports
1–5

© The Author(s) 2022

Article reuse guidelines:

sagepub.com/journals-permissions

DOI: 10.1177/20551169221121901

journals.sagepub.com/home/jfmsopenreports

This paper was handled and processed by the European Editorial Office (ISFM) for publication in *JFMS Open Reports*



Abstract

Case summary A 10-year-old neutered female domestic shorthair cat was presented for acute lameness of the right forelimb after a pathological fracture caused by scapular osteosarcoma. Total scapulectomy was performed, including the glenoid, and the humerus was sutured to the second rib via a bone tunnel in the humeral head. Two months postoperatively, the cat showed mild lameness without any other impairment or signs of pain. The owner reported that the cat was back to normal activity, including climbing and running. Follow-up checks 6 and 18 months after surgery were unremarkable. At the final follow-up, 33 months postoperatively, the cat showed mild lameness, but the orthopaedic examination was still non-painful. Walking fluoroscopy revealed a failure of the fixation of the humeral head, which was now travelling along ribs 1–4 with each step. The owner still rated the cat's quality of life and leg function as excellent.

Relevance and novel information Suture fixation of the humerus to the second rib via a bone tunnel in the humeral head after performing total scapulectomy, and the long-term outcome of the procedure, has so far not been described in cats. While the technique initially led to full return of limb function, the fixation was found to have failed at 33 months after surgery, resulting in a gait alteration that did not impair activity or quality of life.

Keywords: Functional outcome; scapulectomy; feline osteosarcoma; long-term outcome

Accepted: 28 July 2022

Introduction

Osteosarcomas are the most common bone tumours in cats.^{1–7} Osteosarcoma of the scapula is relatively rare, having been described in 1–5% of cats with osteosarcoma.^{3,7–9} In contrast to dogs it is thought that osteosarcomas behave less aggressively in cats with an overall metastatic rate of 5–10% and a mean survival time of 2–4 years after radical surgical resection.^{10,11} However, Nakano et al¹² reported a higher metastasis rate of 46.3% for appendicular or scapular osteosarcomas in cats treated by limb amputation alone without further chemotherapy.¹¹ Grade, size and completeness of resection are important prognostic factors.¹⁰ Complete scapulectomy has the potential to create a comparable margin to amputation, and excellent function has been reported up to 6 months after this procedure in cats.¹³

In the present case report, a cat with an osteosarcoma of the scapula treated with a modified technique for

total scapulectomy is presented. In addition, the first long-term (33 months) outcome for this procedure is described.

Case description

A 10-year-old neutered female domestic cat weighing 6 kg with a body condition score of 6/9 was presented for severe lameness of the right forelimb, which had been noted for a week after acute onset by the referring

Clinic of Small Animal Surgery, Tierspital, Vetsuisse Faculty, University of Zürich, Zürich, Switzerland

Corresponding author:

Johannes M Pfitzer MSc, Small Animal Surgery, University of Zurich Vetsuisse Faculty, Winterthurerstrasse 260, Zürich 8057, Switzerland

Email: johannes.pfitzer@gmx.de



Creative Commons Non Commercial CC BY-NC: This article is distributed under the terms of the Creative Commons

Attribution-NonCommercial 4.0 License (<https://creativecommons.org/licenses/by-nc/4.0/>) which permits non-commercial use, reproduction and distribution of the work without further permission provided the original work is attributed as specified on the SAGE and Open Access pages (<https://us.sagepub.com/en-us/nam/open-access-at-sage>).

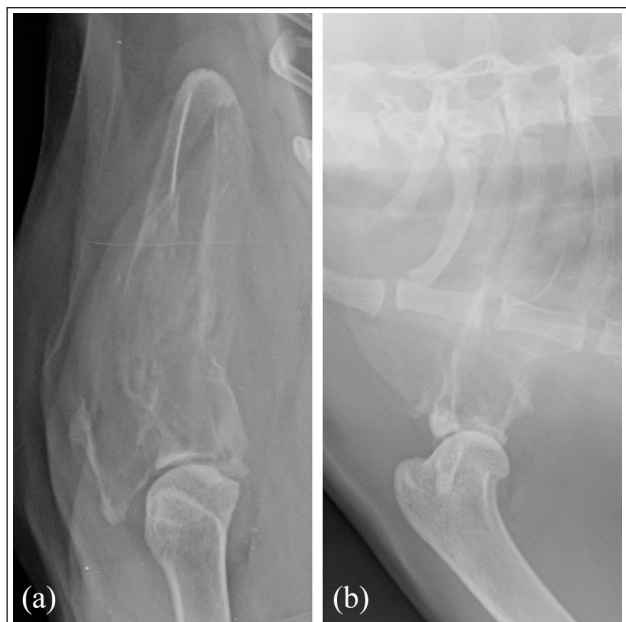

Figure 1 Radiographs of the right scapula in (a) anteroposterior and (b) laterolateral projection showing a mixed osteolytic and osteoproliferative lesion of the scapular neck and a discontinuity of the cranial contour line of the scapula

veterinarian and did not improve on pain medication (meloxicam 0.1 mg/kg PO q24h [Inflacam Suspension für Katzen; Virbac]) prescribed by the referring veterinarian.

Clinical examination indicated pain when manipulating the right shoulder joint. Routine haematological and blood chemistry tests showed mildly decreased urea (5.4 mmol/l; reference interval [RI] 7.4–12.6), and a mild increase of alkaline phosphatase (49 U/l; RI 16–43) and creatine kinase (563 U/l; RI 77–355). Radiographs of the right shoulder revealed a mixed osteolytic and osteoproliferative lesion of the scapular neck and a discontinuity of the cranial contour line of the scapula (Figure 1). Two-view radiographs of the thorax were within normal limits. A Tru-cut biopsy of the affected area came back as fibrosis (callus formation) with lymphoplasmacytic cellular inflammation without evidence of neoplasia.

CT of the thorax and the right scapula conducted 2 weeks later showed the presence of a monostotic predominantly osteolytic bone lesion with extensive loss of the cortex in the region of the scapular neck and body. A pathological fracture of the scapular neck could also be seen. In addition, discrete, ill-defined areas of increased attenuation within the infraspinatus and subscapularis muscles were detected, which were suspicious for potential soft tissue invasion of the tumour. No signs of metastatic disease were present in the CT views of the thorax. Based on the appearance of the lesions the most likely differential diagnosis was neoplasia (osteosarcoma, chondrosarcoma and soft tissue sarcoma)

complicated by a pathological fracture and potential neoplastic invasion into the surrounding muscles.

Owing to the severe lameness and bone destruction, the owner opted against another attempt to biopsy the lesion and decided to progress with a total scapulectomy. A right total scapulectomy was performed the day after CT. For premedication the cat received methadone 0.2 mg/kg (Methadon Streuli; Injektionslösung), midazolam 0.1 mg/kg (Domicum; Generika) and dexmedetomidine 0.0025 mg/kg (Dexdor; Orion). Cefazoline 22 mg/kg (Kefzol; Generika) was administered as perioperative antibiotics. Anaesthesia was induced with alfaxalone 1 mg/kg (Alfaxan; Vetoquinol) and maintained with isoflurane adapted to the conditions (Attane Isoflurane; Piramal Healthcare). During anaesthesia, the cat received a continuous drip infusion (30 ml/h) Ringer's lactate (Ringer-Lactate; Braun).

Owing to the potential soft tissue invasion of the tumour, the extrinsic muscles of the scapula (omotraversarius, trapezius, rhomboideus, serratus dorsalis and ventralis) were resected at a distance of 2 cm from the scapula. The intrinsic muscles of the scapula inserting at the caudal aspect (long head of the triceps brachii muscle, teres minor muscle and teres major muscle) were separated at their origin on the scapula. Both portions of the deltoideus muscle were cut mid-body at the level of the shoulder joint. The infraspinatus, supraspinatus and subscapularis muscles were dissected at the level of their insertions at the humerus. After infiltrating the epineurium of the suprascapular and axillary nerves with ropivacaine 1 mg/kg (Ropivacain Fresenius 2 mg/ml; Fresenius Kabi), they were sharply transected. The coracobrachialis muscle was then severed at its humeral insertion. The glenohumeral ligaments and the joint capsule were transected circumferentially with a cut centred midway between the scapula and humerus. The biceps brachii muscle was sharply dissected at its proximal tendinous portion, which was sutured to the remains of the humeral joint capsule with a horizontal mattress suture (MonoPlus 2/0; B. Braun). The brachial plexus was preserved.

During the preparation process, special care was taken not to open the pleural cavity to prevent the development of a pneumothorax. After gloves and instruments were changed, the second rib was identified, and a hole was drilled caudally to cranially in the distal third of the second rib using a 1.5 mm drill bit about 1 cm proximal to the costochondral junction. A bone tunnel was then drilled through the humeral head from lateral to medial using a 2 mm drill. For the attachment of the humeral head to the second rib, a silk suture 1 (Ethicon) was passed first through the bone tunnel in the second rib from caudal to cranial and then the two suture ends were passed from medial to lateral through the bone tunnel of the humeral head. The suture was secured

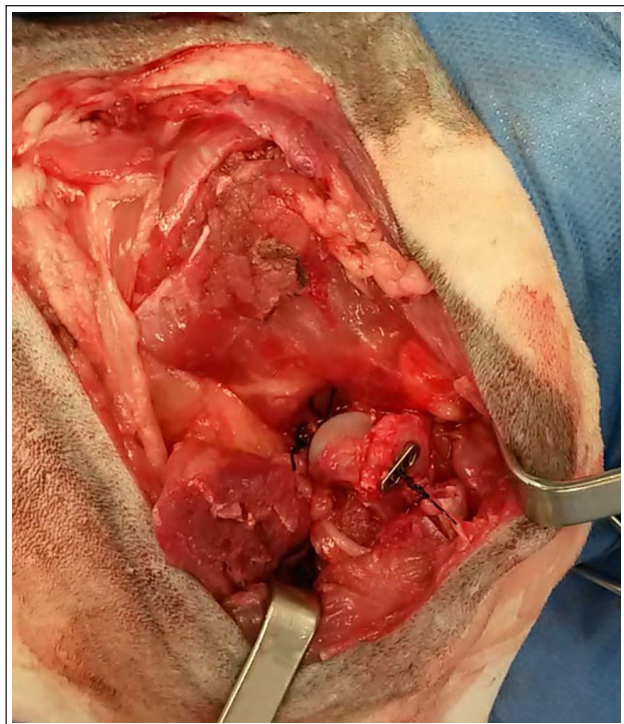


Figure 2 The surgical field after performing total scapulectomy is shown. The humeral head was fixed to the second rib by passing a suture (Silk suture 1; Ethicon) through bone tunnels in the second rib and the humeral head. The suture was secured using a two-hole titanium button (Suture Button, 3.5 mm; Arthrex)

using a two-hole titanium button placed lateral to the humeral head (Suture Button, 3.5 mm; Arthrex) (Figure 2). The remaining joint capsule was anchored around the second and third rib by suturing it to the intercostal muscles using silk suture 0 (Ethicon). Additional coverage was achieved by suturing the rhomboideus and trapezius to the serratus ventralis and deltoideus using polydioxanone 2-0 suture material (2-0 PDS; Ethicon). The remains of the omotransversarius were then attached cranially to the aforementioned fused muscles using the same suture. Finally, the skin was closed routinely.

Histopathology came back as an osteoblastic osteosarcoma. The overlying epidermis and dermis showed no signs of neoplastic infiltration, and neither did the muscles surrounding the scapula. All surgical margins were free of neoplastic cells (R0). Owing to this result, no additional adjuvant treatment was planned.

In the first 24 h postoperatively analgesia was achieved by an intravenous constant rate infusion of fentanyl at 0.0035 mg/kg/h (Fentanyl Sintetica Injektionslösung 0.1 mg/kg; Sintetica) and ketamine at 0.025 mg/kg/h (Ketasol-100 Injektionslösung; Dr E Graeub). In addition, gabapentin (10 mg/kg PO q8h [Gabapentin Mepha Kapseln 100 mg; Mepha Pharma]) and meloxicam (0.2 mg/kg PO q24h [Metacam 2 mg/ml für

Katzen, Injektionslösung; Boehringer Ingelheim]) were administered. The cat was discharged 3 days postoperatively. Meloxicam (0.1 mg/kg PO q24h [Inflacam Suspension für Katzen; Virbac]) was continued for another 5 days and gabapentin (10 mg/kg q8h) for an additional 11 days.

At this time the cat had a normal neurological function and was able to ambulate when limb strapping was applied. Without limb strapping, the leg was severely abducted and the cat ambulated on three legs. The limb strapping consisted of adhesive tape applied proximally to the elbow joint around both forelimbs in a manner that allowed a physiological stance but no unphysiological abduction. A regular change of the limb strapping every 3–5 days was performed in clinics and by the owner over a period of 3 weeks. At this time the limb strapping was removed. The owner was instructed to keep the cat at home, keep the cat calm and to avoid high-impact movements for a period of 6 weeks.

At the 2-month recheck, the cat walked with mild lameness (see Video 1 in the supplementary material). The owner reported excellent function with the cat being able to walk, jump and climb as it did preoperatively. The 6-month radiographic recheck of the thorax was performed by the referring veterinarian, where the two latero-lateral radiographs showed no signs of metastasis. Eighteen months postoperatively, the cat was presented for another recheck showing a normal neurological function with a mild lameness of the affected leg. Palpation of the shoulder muscles, as well as manipulation of the humerus (flexion, extension and abduction), did not elicit apparent discomfort. The range of motion was similar to that of the contralateral shoulder joint, except for abduction, which was increased to 90° vs 35° of the contralateral shoulder joint.

On the final recheck at the university clinic, 33 months postoperatively, the cat was able to walk and jump without any restrictions and there were no clinical signs of tumour recurrence. The right forelimb was still not painful during manipulation and palpation, with normal neurological status. However, the cat now showed a circumduct inward movement of the paw, which was positioned more medially during the stance phase than before. Biplane fluoroscopic gait evaluation while walking confirmed failure of the fixation resulting in movement of the humeral head in the sagittal plane at a distance along the first to fourth rib and approximately 50% of the thoracic wall height. The owner still rated function and quality of life as excellent.

Discussion

Total scapulectomies have occasionally been reported in veterinary patients, with good-to-fair outcomes in one case series including six large breed dogs¹⁴ and a fair-to-poor outcome in a case report of a 66 kg dog,¹⁵ which

led to the recommendation to not remove the entire scapula but rather preserve the glenoid, if possible.¹⁵ This recommendation was contradicted by a feline case published by Clarke and Findji in 2012.¹³ The authors reported an excellent outcome after complete scapulectomy, resulting in normal function and minimal lameness up to 6 months after the procedure.¹³ Contrary to our case, Clarke and Findji fixated the humeral head using the remaining joint capsule and muscles.¹³ In the present case, this approach was slightly changed by including an additional fixation using a suture that was passed through a transhumeral and transcostal bone tunnel. This technique was chosen because it was assumed that by doing so additional strength and stabilisation could be added to the fixation of the forelimb to the trunk of the body. In addition, this method allows resection of all muscles as far away from the scapula as possible to secure optimal margins. This approach resulted in a good function for 3 years, at which point it was found the suture had failed. At this stage, the cat showed a marked alteration in gait but no signs of pain and was able to go about its normal daily activity. The owner still rated the outcome to be excellent. Despite this, fixation using a more rigid suture material, such as a fibre wire (FiberWire; Arthrex) or nylon (Nylon; Ethicon), could have avoided this late failure. In addition, a silk suture could trigger an inflammatory reaction of the surrounding tissue and undergo a slow degradation by proteolysis finally leading to suture failure.¹⁶ However, it is unclear if the suture or the drill hole in the rib failed.

A major concern associated with amputation is the pain that occurs immediately after surgery and the potential for long-term neuropathic pain.¹⁷ To address this issue, the cat in our case, in addition to meloxicam, may have benefited from the application of further pre-operative analgesia such as alpha-2 adrenergic agonists, opioids and ketamine.¹⁷ Additionally, local anaesthesia might have been continued in the postoperative phase in the form of a wound soaker catheter applied in the amputation wound,¹⁸ and the pain medication during the postoperative phase could have been supplemented with an opioid such as buprenorphine. The given pain medication (meloxicam, gabapentin) could have also been continued for a longer period in order to further minimise the risk for the emergence of long-term neuropathic pain.¹⁷ Furthermore, it should be noted that the method described can be associated with a potential risk of developing a pneumothorax with all its consequences due to the tunnelling of the rib.

Only Clarke and Findji¹³ described the clinical outcome after complete scapular resection in cats before and, in contrast to large dogs, this resulted in good function and tumour control, as seen in the present case. This might be attributable to the relatively low

weight of feline patients; however, as this was a single case, a general recommendation cannot be made.

Conclusions

A total scapulectomy resulted in long-term tumour control and sustained acceptable limb function in this cat. Potential complications associated with this procedure are failure of fixation, pneumothorax and wound infection.

Supplementary material The following file is available online:

Video 1: Video showing the cat 3 months after performing a total scapulectomy.

Conflict of interest The authors declared no potential conflicts of interest with respect to the research, authorship, and/or publication of this article.

Funding The authors received no financial support for the research, authorship, and/or publication of this article.

Ethical approval The work described in this manuscript involved the use of non-experimental (owned or unowned) animals. Established internationally recognised high standards ('best practice') of veterinary clinical care for the individual patient were always followed and/or this work involved the use of cadavers. Ethical approval from a committee was therefore not specifically required for publication in *JFMS Open Reports*. Although not required, where ethical approval was still obtained it is stated in the manuscript.

Informed consent Informed consent (verbal or written) was obtained from the owner or legal custodian of all animal(s) described in this work (experimental or non-experimental animals, including cadavers) for all procedure(s) undertaken (prospective or retrospective studies). For any animals or people individually identifiable within this publication, informed consent (verbal or written) for their use in the publication was obtained from the people involved.

ORCID iD Pavlos Natsios  <https://orcid.org/0000-0001-8122-8899>

Patricia Beer  <https://orcid.org/0000-0002-1961-4729>

Mirja C Nolf  <https://orcid.org/0000-0001-9317-7769>

References

- Schmidt RE and Langham RF. **A survey of feline neoplasms.** *J Am Vet Med Assoc* 1967; 151: 1325–1328.
- Whitehead JE. **Neoplasia in the cat.** *Vet Med Small Anim Clin* 1967; 62: 357–359.
- Brodey RS. **Canine and feline neoplasia.** *Adv Vet Sci Comp Med* 1970; 14: 309–354.
- Bomhard D v on. **Epidemiologie.** In: Nolte I and Nolte M (eds). *Praxis der Onkologie bei Hund und Katze.* Stuttgart: Enke, 2001, pp 104–108.
- Bastianello SS. **A survey on neoplasia in domestic species over a 40-year period from 1935 to 1974 in the Republic of**

- South Africa. V. Tumours occurring in the cat. *J Vet Res* 1983; 50: 105–111.
- 6 Liu SK, Dorfman HD and Patnaik AK. Primary and secondary bone tumors in the cat. *J Small Anim Pract* 1974; 15: 141–156.
 - 7 Quigley PJ and Leedale AH. Tumors involving bone in the domestic cat: a review of fifty-eight cases. *Vet Pathol* 1983; 20: 670–686.
 - 8 Bitetto WV, Patnaik AK, Schrader SC, et al. Osteosarcoma in cats: 22 cases (1974–1984). *J Am Vet Med Assoc* 1987; 190: 91–93.
 - 9 Kessler M, Tassani-Prell M, Bomhard D von, et al. Das Osteosarkom der Katze: epidemiologische, klinische und röntgenologische Befunde bei 78 Tieren (1990–1995) [article in German]. *Tierärztl Prax* 1997; 25: 275–283.
 - 10 Dimopoulou M, Kirpensteijn J, Moens H, et al. Histologic prognosticators in feline osteosarcoma: a comparison with phenotypically similar canine osteosarcoma. *Vet Surg* 2008; 37: 466–471.
 - 11 Helm E and Morris J. Musculoskeletal neoplasia: an important differential for lumps or lameness in the cat. *J Feline Med Surg* 2012; 14: 43–54.
 - 12 Nakano Y, Kagawa Y, Shimoyama Y, et al. Outcome of appendicular or scapular osteosarcoma treated by limb amputation in cats: 67 cases (1997–2018). *J Am Vet Med Assoc* 2021; 260: 24–28.
 - 13 Clarke BS and Findji L. Total scapulectomy for the treatment of chondrosarcoma in a cat. *J Am Vet Med Assoc* 2012; 241: 364–367.
 - 14 Norton C, Drenen CM and Emms SG. Subtotal scapulectomy as the treatment for scapular tumour in the dog: a report of six cases. *Aust Vet J* 2006; 84: 364–366.
 - 15 Kirpensteijn J, Straw RC and Pardo AD. Total and partial scapulectomy in the dog. *J Am Anim Hosp Assoc* 1994; 30: 313–319.
 - 16 Jo YY, Kweon H, Kim DW, et al. Accelerated biodegradation of silk sutures through matrix metalloproteinase activation by incorporating 4-hexylresorcinol. *Sci Rep* 2017; 7. DOI: 10.1038/srep42441.
 - 17 O'Hagan BJ. Neuropathic pain in a cat post-amputation. *Aust Vet J* 2006; 84: 83–86.
 - 18 Abelson AL, McCobb EC, Shaw S, et al. Use of wound soaker catheters for the administration of local anesthesia for post-operative analgesia: 56 cases. *Vet Anaesth Analg* 2009; 36: 597–602.