



Pancreatic leiomyosarcoma in a domestic shorthair cat

Authors: Bobis Villagr a, Diego, Almeida, Mariana, Cox, Alistair, and Henderson, Elisabeth

Source: Journal of Feline Medicine and Surgery Open Reports, 8(1)

Published By: SAGE Publishing

URL: <https://doi.org/10.1177/20551169221098328>



Pancreatic leiomyosarcoma in a domestic shorthair cat

Diego Bobis Villagr ¹ , Mariana Almeida¹, Alistair Cox² and Elisabeth Henderson¹

Journal of Feline Medicine and Surgery Open Reports
1–5

© The Author(s) 2022

Article reuse guidelines:

sagepub.com/journals-permissions

DOI: 10.1177/20551169221098328

journals.sagepub.com/home/jfmsopenreports

This paper was handled and processed by the European Editorial Office (ISFM) for publication in *JFMS Open Reports*



Abstract

Case summary A 7-year-old female neutered domestic shorthair cat was presented with weight loss, abdominal distension, lethargy, pyrexia and hyporexia. Haematology and biochemistry were unremarkable. Abdominal ultrasound revealed a cystic mass within the left cranial abdominal quadrant, adjacent to the pancreas, stomach and spleen. CT revealed a 10.5 cm, rounded, well-encapsulated, hypodense mass arising from the left pancreatic lobe. The remaining organs of the abdominal and thoracic cavity were unremarkable. A partial left lobe pancreatectomy and splenic lymph node removal were performed. Histopathology of the pancreatic mass reported a proliferating population of neoplastic spindle cells most consistent with a preliminary diagnosis of soft tissue sarcoma. Immunohistochemistry characteristics, together with the morphological findings, were consistent with a diagnosis of leiomyosarcoma. The patient recovered without any concerns after receiving routine postoperative care. Clinical examination and abdominal ultrasound 5 months postoperatively revealed no abnormalities.

Relevance and novel information To our knowledge, this is the first report of pancreatic leiomyosarcoma in a cat. Pancreatic leiomyosarcoma should be considered as one of the possible differential diagnoses for cats presenting with a pancreatic mass.

Keywords: Leiomyosarcoma; pancreatic neoplasia; mesenchymal tumour; immunohistochemistry; oncology surgery

Accepted: 14 April 2022

Case description

A 7-year-old female neutered domestic shorthair cat was referred with an acute history of lethargy, hyporexia, abdominal distension and weight loss. Nausea and mild pyrexia (39.2°C) were also noted. No other pertinent patient history was reported. No traumatic history had occurred and the patient was kept indoors. The primary care veterinarian had identified an abdominal mass with an unclear origin during ultrasound examination.

Clinical examination revealed mild dehydration, abdominal distension and an adequate body condition score (4/9). Body weight was 3.8 kg. A large, firm mass was identified within the cranial abdominal quadrant. The mass did not appear to be painful upon palpation. Peripheral lymph nodes were within normal limits.

Haematology revealed a mild erythrocytosis (51.5%; reference interval [RI] 27–50%), which was deemed likely

to be secondary to dehydration. Serum biochemistry was unremarkable, with the exception of mildly decreased alanine aminotransferase (17 U/l; RI 18–84).

Thoracic and abdominal CT was performed, followed by ultrasound-guided fine-needle aspiration (FNA) of the abdominal mass. Other procedures performed under general anaesthesia included: premedication with methadone (0.2 mg/kg/IV [Comfortan; Dechra]) and

¹Lumbry Park Veterinary Specialists, Alton, UK

²FINN Pathologists, Norfolk, UK

Corresponding author:

Diego Bobis Villagr  DVM, MSc, PhD, PGDip SAS, PGCert VEaMIS, RCVS Advanced Practitioner in Small Animal Surgery, MRCVS, Lumbry Park Veterinary Specialists, Selborne Road, Alton GU34 3HL, UK
Email: diegobobis88@gmail.com



Creative Commons Non Commercial CC BY-NC: This article is distributed under the terms of the Creative Commons

Attribution-NonCommercial 4.0 License (<https://creativecommons.org/licenses/by-nc/4.0/>) which permits non-commercial use, reproduction and distribution of the work without further permission provided the original work is attributed as specified on the SAGE and Open Access pages (<https://us.sagepub.com/en-us/nam/open-access-at-sage>).

dexmedetomidine (0.003 mg/kg/IV [Dexdomitor; Vetoquinol]); induction with alfaxalone (1–2 mg/kg/IV [Alfaxan; Jurox]); and maintenance with isoflurane (Isoflo; Zoetis) in 100% oxygen, adjusted to clinical effect. A dopamine constant rate infusion (0.003–0.01 mg/kg/min/IV [Sterile Dopamine Concentrate 200 mg/5 ml; Martindale Pharmaceuticals]) was administered to counteract hypotension.

CT revealed a large, 10.5 cm, rounded, apparently well-encapsulated, hypodense mass arising from the left pancreatic lobe. Heterogeneous contrast enhancement was noted within the parts of the mass adjacent to the left pancreatic limb. The remainder of the mass was hypodense and fluid filled (Figure 1). The mass displaced the spleen laterally, the splenic vein dorsally, the stomach craniomedially and the left kidney caudodorsally. No overt infiltration of the surrounding organs was noted. There were two additional smaller masses, which were both up to 2 cm in size, homogeneously hypodense and thin-walled. Both smaller masses arose within the left limb of the pancreas, adjacent to the greater curvature of the stomach. No other pathology was identified.

Ultrasound-guided FNA of the larger mass revealed a low-to-moderate nucleated cellularity and adequate cell preservation. An inflammatory cell population was present, comprising of a mixture of small lymphocytes and macrophages with occasional non-degenerate neutrophils. Among the inflammatory cells, a population of slender spindle cells was observed in clusters, as well as individually. These had an oval nucleus with finely stippled chromatin, no visible nucleolus and a moderate to abundant amount of wispy basophilic cytoplasm. The cells displayed mild anisocytosis and anisokaryosis; therefore, it was postulated that they may represent reactive fibroplasia. However, an inflamed mesenchymal neoplasm could not be ruled out (Figure 2).

Surgical resection of the mass was subsequently planned. The same anaesthetic protocol was used as previously described. In addition, an epidural with morphine (0.1 mg/kg) was performed. Cefuroxime (20 mg/kg IV [Zinacef; GlaxoSmithKline]) was administered perioperatively. A ventral midline coeliotomy from the xiphoid to the pubis was performed. Exploration revealed a large multilocular cystic mass within the mid-distal portion of the left limb of the pancreas (Figure 3). The leaves of the greater omentum were adhered to the dorsal and ventral surfaces of the mass. The splenic lymph node was subjectively enlarged, and the body and right limb of the pancreas was oedematous. The distal left pancreatic lobe and large pancreatic mass were bluntly dissected from the splenic blood supply (vein and artery) and greater curvature of the stomach, and resected en bloc. The arterial branch supplying the proximal left limb of the pancreas was preserved. The remaining two smaller cystic pancreatic masses were resected separately due to their close association with

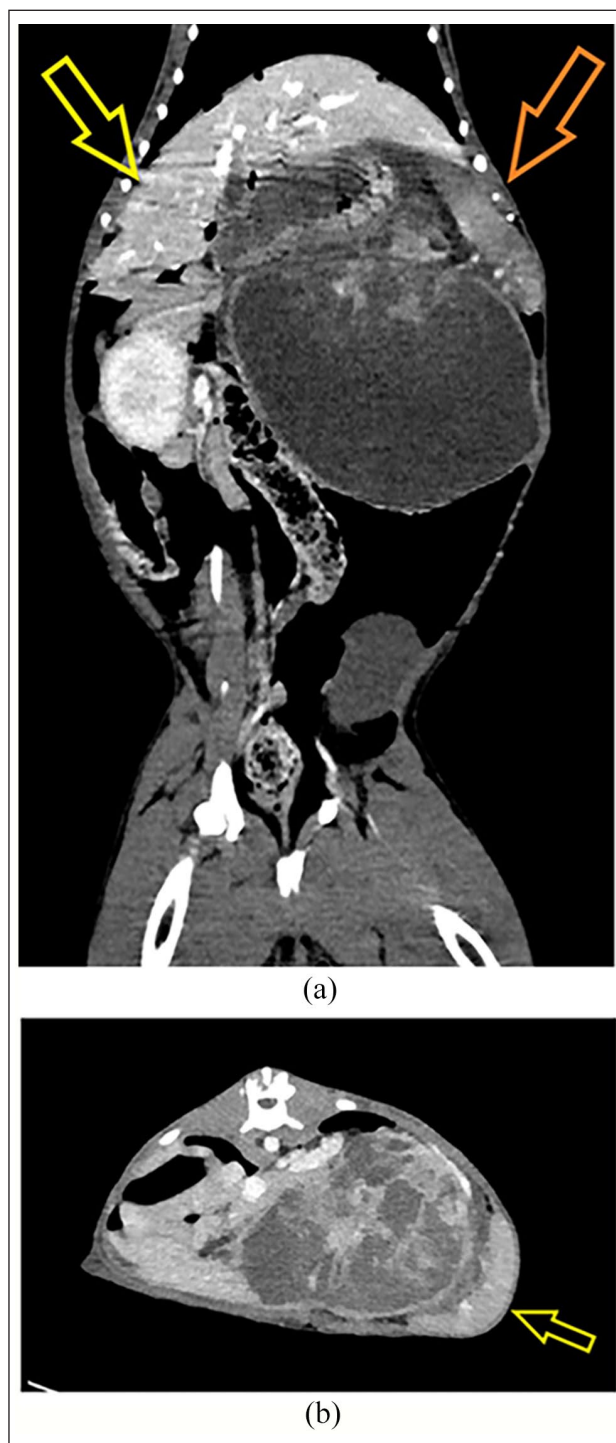

Figure 1 (a) Post-contrast dorsal view (matrix 512 × 512, window level 76 HU, window width 372 HU, field of view adjusted to patient size, patient in sternal recumbency) showing a large rounded well-encapsulated, hypodense mass arising from the left pancreatic lobe. Craniolateral displacement of the spleen (orange arrow) and the liver (yellow arrow) was noted. (b) Post-contrast transverse view (matrix 512 × 512, window level 76 HU, window width 372 HU, field of view adjusted to patient size, patient in sternal recumbency) showing a large, rounded, well-encapsulated, hypodense mass arising from the left pancreatic lobe. Lateral displacement of the spleen (yellow arrow) was noted

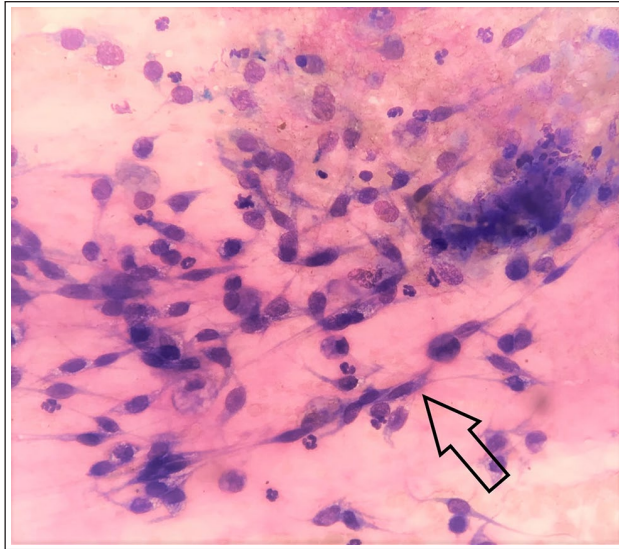


Figure 2 A population of slender spindle cells (black arrow) was revealed by cytology. Magnification $\times 100$

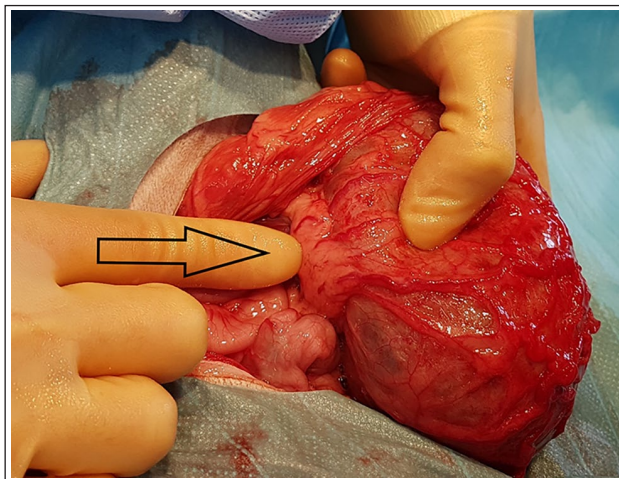


Figure 3 Intraoperative photograph showing the large pancreatic mass within the omental bursa; the greater and lesser omentum adhered to the mass. The distal left pancreatic limb was present (black arrow)

the left gastroepiploic artery. Lymphadenectomy of the splenic lymph node was subsequently carried out.

All tissues resected were fixed (10% formal saline) and submitted externally for histopathology (Finn Pathologists; Norfolk). Haematoxylin and eosin-stained sections of the splenic lymph node were examined and revealed a normal architecture with prominent lymphoid follicles. The subcapsular and medullary sinuses contained quite a large number of mixed cells, and the medullary cords contained increased numbers of plasma cells with some mature lymphocytes. These findings were consistent with lymphoid follicular hyperplasia and drainage response. Haematoxylin and eosin-stained sections of the left pancreatic limb masses (larger than the two smaller masses) were examined,

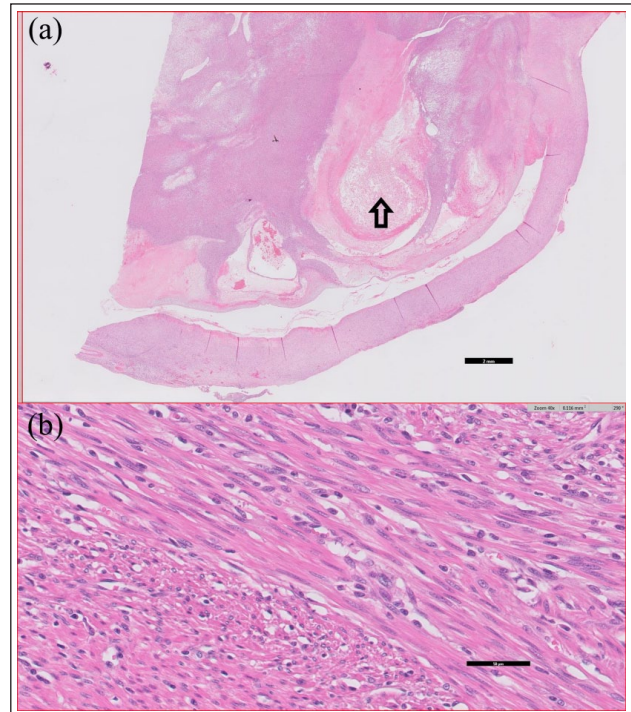


Figure 4 (a) Low ($\times 0.5$ magnification) and (b) high-power ($\times 40$ magnification) view of the spindle cell population. Areas of cavitation and necrosis are seen (black arrow)

revealing a proliferating population of spindle cells, which formed broad interweaving streams and multiple lobules with patchy necrosis. Individual cells were described as elongated and spindloid, often long, narrow and strap-like, resembling smooth muscle cells, with an oval-to-cigar-shaped nucleus containing stippled chromatin and several small nucleoli. Cellular and nuclear pleomorphism were moderate, and mitoses were uncommon (one in 10 high power fields [2.37 mm^2]). There were some admixed lymphocytes and plasma cells throughout, and areas of necrosis filled with fibrin and red blood cells, with some accompanying macrophages displaying erythrophagocytosis (Figure 4).

Histopathology identified a soft tissue sarcoma. Immunohistochemistry was performed to aid classification of the soft tissue sarcoma. Standard immunohistochemistry protocol based on desmin (Dako Monoclonal Mouse, Anti-Human Desmin, M0760, 1:100) and actin: (Dako Monoclonal Mouse, Anti-Human Smooth Muscle Actin, Clone 1A4, M0851, 1:400). Desmin (smooth and striated muscle) and smooth muscle actin (smooth muscle) staining revealed a widespread moderate-to-strong cytoplasmic labelling of the proliferating cellular population (Figure 5). The combined histological staining characteristics, morphology and immunohistochemical findings were consistent with the diagnosis of leiomyosarcoma. The histological origin of the mass was uncertain, but both imaging and surgical examination confirmed a pancreatic origin.

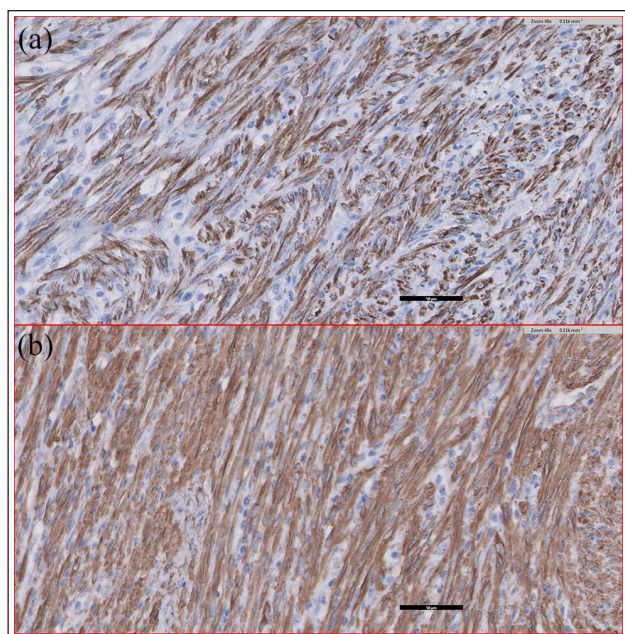


Figure 5 Positive cytoplasmic staining with (a) desmin and (b) smooth muscle actin (both $\times 40$ magnification)

Postoperatively, the cat was administered a constant rate infusion of dexmedetomidine (5–20 $\mu\text{g}/\text{kg}/\text{hIV}$ [Dexdomitor; Vetoquinol]) and methadone (0.2 mg/kg q4h IV [Comfortan; Dechra]) as multimodal analgesia. Fluid therapy was also administered (2.5 ml/kg/hIV [Hartmann's; Vetivex]). The cat was discharged from the hospital 24h after surgery with buprenorphine (0.01 mg/kg q8h sublingually for 10 days). A 2-week follow-up revealed no concerns, and the patient was asymptomatic. At 5 months postoperatively, the owners reported that their cat remained asymptomatic. Clinical examination was unremarkable. Conscious abdominal ultrasound revealed a well-marginated pancreas with a normal echotexture and pancreatic duct. The surrounding mesentery did not reveal any evidence of inflammation.

Discussion

Pancreatic neoplasia is an uncommon pathology in both small animals and humans.^{1–5} The most commonly reported type of feline pancreatic neoplasia is an adenocarcinoma of ductular or acinar origin. Other types of tumour are described, including pancreatic lymphoma, pancreatic beta cell tumours (insulinoma), sarcoma, adenoma and several unclassified neoplasia.^{1,3–6}

Clinical signs in patients with pancreatic neoplasia are typically non-specific, such as anorexia, weight loss, episodes of diarrhoea or vomiting, lethargy, discomfort and abdominal pain.^{1,7–9} These clinical signs are similar to those described in the case reported here. Clinical signs reported with pancreatic beta cell tumours tend to differ and are associated with hyperinsulinaemia.

They can include weakness, ataxia, collapse, tremors, disorientation and seizures.^{1,7–9}

Leiomyosarcomas are slow growing and locally invasive malignant lesions that arise from the smooth muscle. Metastatic disease is uncommon and slow to occur.^{10,11} Leiomyosarcomas have been reported as intestinal, gastric, renal, uterine, cardiac, urinary, ocular, vulval or dermal in cats. To our knowledge, this is the first case report to describe a primary pancreatic leiomyosarcoma in small animals. Pancreatic leiomyosarcoma is described in the human literature as 0.1% of all pancreatic neoplasia. It is the most commonly described mesenchymal tumour, originating from the walls of the pancreatic vasculature or from the smooth muscle cells of the pancreatic duct.^{12–18}

Within the human literature, there are no well-established diagnostic imaging criteria or characteristics used for the identification of pancreatic leiomyosarcoma. In the majority of cases, a well-encapsulated, contrast-enhancing cystic lesion often associated with an appearance consistent with internal haemorrhage is identified on CT.^{19–21} A similar appearance on CT was noted in the case reported here.

Histopathology and immunohistochemistry are the gold standard tests for the accurate diagnosis of a leiomyosarcoma. Confirmation of a leiomyosarcoma is gained via identification of the presence of a spindle cell neoplasm and positive desmin and smooth muscle actin immunohistochemical labelling.^{11–13,21}

The treatment for pancreatic leiomyosarcoma in small animals is not yet established. However, the human literature suggests that a surgical approach with complete resection of the primary pancreatic neoplasia should be considered as the gold standard. In some cases, complete remission is described following excision of the mass.^{12,15,17,21–25} According to the human literature, the longest survival period reported following complete tumour resection was more than 20 years.²³ In cases with advanced neoplastic disease (presence of metastatic lesions), a median survival time of 2 years has been reported (range 8 weeks to 3 years).^{12,19,26,27}

Conclusions

This case report describes a cat with history of abdominal distension, lethargy, hyporexia and weight loss. A pancreatic mass was suspected on abdominal ultrasound and confirmed on CT. Mass resection and concurrent left partial pancreatectomy was carried out. Histopathology and immunohistochemistry identified a leiomyosarcoma. Postoperatively, the cat was clinically asymptomatic. At 5 months postoperatively, the patient remained asymptomatic and there was no evidence of tumour recurrence on abdominal ultrasound. To our knowledge, this is the first report of a pancreatic leiomyosarcoma in a cat. Pancreatic leiomyosarcoma should be considered a possible differential diagnosis for cats presenting with a

pancreatic mass. Prognosis after surgical resection can be considered to be good. A larger number of cases is needed to evaluate and provide more information on the clinical signs, treatment, outcome and prognosis.

Conflict of interest The authors declared no potential conflicts of interest with respect to the research, authorship, and/or publication of this article.

Funding The authors received no financial support for the research, authorship, and/or publication of this article.

Ethical approval The work described in this manuscript involved the use of non-experimental (owned or unowned) animals. Established internationally recognised high standards ('best practice') of veterinary clinical care for the individual patient were always followed and/or this work involved the use of cadavers. Ethical approval from a committee was therefore not specifically required for publication in *JFMS Open Reports*. Although not required, where ethical approval was still obtained, it is stated in the manuscript.

Informed consent Informed consent (verbal or written) was obtained from the owner or legal custodian of all animal(s) described in this work (experimental or non-experimental animals, including cadavers) for all procedure(s) undertaken (prospective or retrospective studies). For any animals or people individually identifiable within this publication, informed consent (verbal or written) for their use in the publication was obtained from the people involved.

ORCID iD Diego Bobis Villagr   <https://orcid.org/0000-0002-9081-2808>

References

- 1 Torner K, Staudacher M, Steiger K, et al. **Clinical and pathological data of non-epithelial pancreatic tumors in cats.** *Vet Sci* 2020; 7: 55. DOI: 10.3390/vetsci7020055.
- 2 Siegel RL, Miller KD, Jemal A, et al. **Cancer statistics, 2020.** *CA Cancer J Clin* 2020; 70: 7–30.
- 3 Munday JS, Loehr CV and Kiupel M. **Tumors of the alimentary tract.** In: Meuten DJ (ed). *Tumors in domestic animals*. 5th ed. Ames, IA: Wiley Blackwell, 2017, pp 499–601.
- 4 Jubb KVF and Stent AW. **Exocrine pancreas.** In: Maxie MG (ed). *Pathology of domestic animals*. 6th ed. St Louis, MO: Elsevier, 2016, pp 353–368.
- 5 Head KW, Cullen JM, Dubielzig RR, et al. **Histological classification of tumours of the pancreas of domestic animals.** In: Head KW, Cullen JM, Dubielzig RR, et al (eds). *World Health Organization international histological classification of tumors of domestic animals, histological classification of tumours of the alimentary system of domestic animals*. Washington, DC: Armed Forces Institute of Pathology, 2003, pp 111–118.
- 6 Kircher CH and Nielsen SW. **Tumours of the pancreas.** *Bull World Health Organ* 1976; 53: 195–202.
- 7 Bennett PF, Hahn KA, Toal RL, et al. **Ultrasonographic and cytopathological diagnosis of exocrine pancreatic carcinoma in the dog and the cat.** *J Am Anim Hosp Assoc* 2001; 37: 466–473.
- 8 Seaman RL. **Exocrine pancreatic neoplasia in the cat: a case series.** *J Am Anim Hosp Assoc* 2004; 40: 238–245.
- 9 Linderman MJ, Brodsky EM, De Lorimier LP, et al. **Feline exocrine pancreatic carcinoma. A retrospective study of 34 cases.** *Vet Comp Oncol* 2013; 11: 208–218.
- 10 Marks SL. **Update on feline gastrointestinal neoplasia.** *Proceedings of the 28th World Small Animal Veterinary Association World Congress; 2003 Oct 24–27; Bangkok, Thailand.*
- 11 Hart K, Brownlie HB, Ogden D, et al. **A case of gastric leiomyosarcoma in a domestic shorthair cat.** *JFMS Open Rep* 2018, 4. DOI: 10.1177/2055116918818912.
- 12 Reyes MCD, Huang X, Bain A, et al. **Primary pancreatic leiomyosarcoma with metastasis to the liver diagnosed by endoscopic ultrasound-guided fine needle aspiration and fine needle biopsy.** *Diagn Cytopathol* 2016; 44: 1070–1073.
- 13 Baylor SM and Berg JW. **Cross-classification and survival characteristics of 5,000 cases of cancer of the pancreas.** *J Surg Oncol* 1973; 5: 335–358.
- 14 Zhang H, Jensen MH, Famell MB, et al. **Primary leiomyosarcoma of the pancreas: study of 9 cases and review of literature.** *Am J Surg Pathol* 2010; 34: 1846–1856.
- 15 Deveaux PG, Aranha GV and Yong S. **Leiomyosarcoma of the pancreas.** *HPB (Oxford)* 2001; 3: 175–177.
- 16 Izumi H, Okada K, Imaizumi T, et al. **Leiomyosarcoma of the pancreas: report of a case.** *Surg Today* 2011; 41: 1556–1561.
- 17 Machado MC, Cunha JE, Penteado S, et al. **Preoperative diagnosis of pancreatic leiomyosarcoma.** *Int J Pancreatol* 2000; 28: 97–100.
- 18 Zalatnai A, Kov acs M, Flautner L, et al. **Pancreatic leiomyosarcoma. Case report with immunohistochemical and flow cytometric studies.** *Virchows Arch* 1998; 432: 469–472.
- 19 Xu J, Zhang T, Wang T, et al. **Clinical characteristics and prognosis of primary leiomyosarcoma of the pancreas: a systematic review.** *World J Surg Oncol* 2013; 11: 290. DOI: 10.1186/1477-7819-11-290.
- 20 Barral M, Faraoun SA, Fishman EK, et al. **Imaging features of rare pancreatic tumors.** *Diagn Interv Imaging* 2016; 97: 1259–1273.
- 21 Fadaee N, Sefa T, Das A, et al. **Pancreatic leiomyosarcoma: a diagnostic challenge and literature review.** *BMJ Case Rep* 2019; 12: e231529. DOI: 10.1136/bcr-2019-231529.
- 22 Kocakoc E, Havan N, Bilgin M, et al. **Primary pancreatic leiomyosarcoma.** *Iran J Radiol* 2014; 11: e4880. DOI: 10.5812/iranradiol.4880.
- 23 Maarouf A, Scoazec JY, Berger F, et al. **Cystic leiomyosarcoma of the pancreas successfully treated by splenopancreatectomy: a 20-year follow-up.** *Pancreas* 2007; 35: 95–98.
- 24 Komoda H, Nishida T, Yumiba T, et al. **Primary leiomyosarcoma of the pancreas – a case report and case review.** *Virchows Arch* 2002; 440: 334–337.
- 25 Aihara H, Kawamura YJ, Toyama N, et al. **A small leiomyosarcoma of the pancreas treated by local excision.** *HPB (Oxford)* 2002; 4: 145–148.
- 26 H ebert-Magee S, Varadarajulu S, Frost AR, et al. **Primary pancreatic leiomyosarcoma: a rare diagnosis obtained by EUS-FNA cytology.** *Gastrointest Endosc* 2014; 80: 361–362.
- 27 Ishii H, Okada S, Okazaki N, et al. **Leiomyosarcoma of the pancreas: report of a case diagnosed by fine needle aspiration biopsy.** *Jpn J Clin Oncol* 1994; 24: 42–45.