

Cutaneous *Mycobacterium goodii* infection in an immunocompetent cat in Louisiana: clinical presentation, molecular identification, antimicrobial susceptibility and management

Authors: Wu, Chi-Yen, Diaz, Sandra, Ellis, Angela, Jones, Rebekah, and Pucheu-Haston, Cherie

Source: Journal of Feline Medicine and Surgery Open Reports, 8(1)

Published By: SAGE Publishing

URL: <https://doi.org/10.1177/20551169221090442>

BioOne Complete (complete.BioOne.org) is a full-text database of 200 subscribed and open-access titles in the biological, ecological, and environmental sciences published by nonprofit societies, associations, museums, institutions, and presses.



Cutaneous *Mycobacterium goodii* infection in an immunocompetent cat in Louisiana: clinical presentation, molecular identification, antimicrobial susceptibility and management

Journal of Feline Medicine and Surgery Open Reports
1–6

© The Author(s) 2022

Article reuse guidelines:

sagepub.com/journals-permissions

DOI: 10.1177/20551169221090442

journals.sagepub.com/home/jfmsopenreports

This paper was handled and processed by the American Editorial Office (AAFP) for publication in *JFMS Open Reports*



Chi-Yen Wu¹, Sandra Diaz² , Angela Ellis³,
Rebekah Jones⁴ and Cherie Pucheu-Haston¹

Abstract

Case summary A 9-year-old spayed female domestic shorthair cat was presented to a referral hospital for management of recurring non-healing ulcerations and a subcutaneous mass on the ventral abdomen. Prior treatment included antibiotics (cefovecin followed by clindamycin), wound cleaning and surgical debulking, but the ulcerations and mass recurred 1 month after surgical removal. At this point, the cat was started on doxycycline and pradofloxacin and referred for further work-up. The culture of skin biopsy specimens obtained at the time of referral revealed a population of bacterial colonies with two distinctly different phenotypes. Matrix-assisted laser desorption/ionization time-of-flight mass spectrometry and 16S rRNA gene sequencing identified both colonies as *Mycobacterium goodii*. A diagnosis of a cutaneous infection of rapidly growing mycobacteria was made, and treatment with oral pradofloxacin and doxycycline was initiated. The ulcerations resolved within 4 months, and the subcutaneous mass gradually decreased in size until it was no longer palpable, even 4 months after the cessation of antibiotics.

Relevance and novel information This is the second reported feline cutaneous *M goodii* infection in North America. The organism was not visualized on histopathology but was successfully cultured from tissue obtained by skin punch biopsy. A phenotypic switching phenomenon affecting the susceptibility results was suspected, possibly explaining the presence of phenotypically different but genetically identical strains. This case highlights the importance of submitting aseptically obtained tissue, fluid or fine-needle aspirates for culture and species identification, as well as histopathology, when infection with higher bacteria, such as rapidly growing mycobacteria, is suspected.

Keywords: *Mycobacterium goodii*; rapidly growing mycobacteria; cutaneous mycobacterial infection; atypical mycobacteriosis; phenotypic switching; pradofloxacin; doxycycline

Accepted: 10 March 2022

¹Department of Veterinary Clinical Sciences, School of Veterinary Medicine, Louisiana State University, Baton Rouge, LA, USA

²Department of Veterinary Clinical Sciences, College of Veterinary Medicine, The Ohio State University, Columbus, OH, USA

³Antech Diagnostics Fountain Valley, CA, USA

⁴Department of Biomedical and Diagnostic Sciences, College of Veterinary Medicine, University of Tennessee, Knoxville, TN, USA

Corresponding author:

Cherie Pucheu-Haston DVM, PhD, DACVD, Department of Veterinary Clinical Sciences, School of Veterinary Medicine, Louisiana State University, Skip Bertman Dr, Baton Rouge, LA 70803, USA

Email: cpucheu@lsu.edu



Creative Commons Non Commercial CC BY-NC: This article is distributed under the terms of the Creative Commons

Attribution-NonCommercial 4.0 License (<https://creativecommons.org/licenses/by-nc/4.0/>) which permits non-commercial use, reproduction and distribution of the work without further permission provided the original work is attributed as specified on the SAGE and Open Access pages (<https://us.sagepub.com/en-us/nam/open-access-at-sage>).

Introduction

Feline cutaneous atypical mycobacteriosis is caused by aerobic, non-mobile, mycolic acid-containing, acid-fast rapidly growing mycobacteria (RGM). It is thought that cutaneous RGM are introduced into the skin either by puncture with a contaminated object or by exposure of a wound to contaminated soil, water or decaying vegetation.^{1,2} Lesions include nodules, erosions, ulcerations and draining tracts, and most frequently affect areas with abundant adipose tissue, such as the ventral abdomen.¹ The organisms may not be readily identifiable by routine stains in cytologic or histopathologic specimens; they may also not be identified using special stains (eg, Ziehl–Neelsen). Culture or molecular diagnostics (eg, PCR assays) of aseptically obtained deep tissue or fluid may be required to identify the organism and its speciation. When little fluid is present, multiple tissue aspirates could be submitted for PCR instead. Treatments usually include long-term administration of systemic antimicrobials with or without debulking surgery.

RGM are classified into three groups, the *Mycobacterium fortuitum* group, the *Mycobacterium chelonae-abscessus* group and the *Mycobacterium smegmatis* group, although some species do not fit into any of these groups.³ Infections with *Mycobacterium goodii*, a species belonging to the *M smegmatis* group, have rarely been reported in animals. To our knowledge, the present case represents only the second case of feline cutaneous *M goodii* infection reported in North America and the first case in Louisiana.

Case description

A 9-year-old spayed female domestic shorthair cat weighing 4.3 kg was presented to the general practice veterinarian for two suspected puncture wounds on the ventral abdomen and inguinal areas. The wounds were cleaned, and the cat was administered cefovecin (8 mg/kg SC [Convenia; Zoetis]). Nine days later, the cat was started on a 10-day course of clindamycin (5 mg/kg PO q12h). Three weeks after the initial presentation, the cat returned because the owner reported a hard mass growing under the wound site. The wounds were cleaned again, but antibiotics were not prescribed.

The cat returned a month later as the mass had grown further. A 6 × 3 cm mass was surgically removed and submitted with an additional 9.5 × 3.2 cm skin biopsy sample for histopathologic evaluation, which revealed severe multifocal-to-coalescing pyogranulomatous dermatitis and panniculitis (Figure 1a, b). Grocott–Gömöri methenamine silver, Ziehl–Neelsen stain and Fite–Faraco stain were negative for fungi and acid-fast bacilli, respectively. Rare Gram-positive bacilli were present in a Gram stain section. The cat was restarted on clindamycin after surgery, but 1 month later the cat returned with non-healing tracts on the ventral abdomen. Complete blood

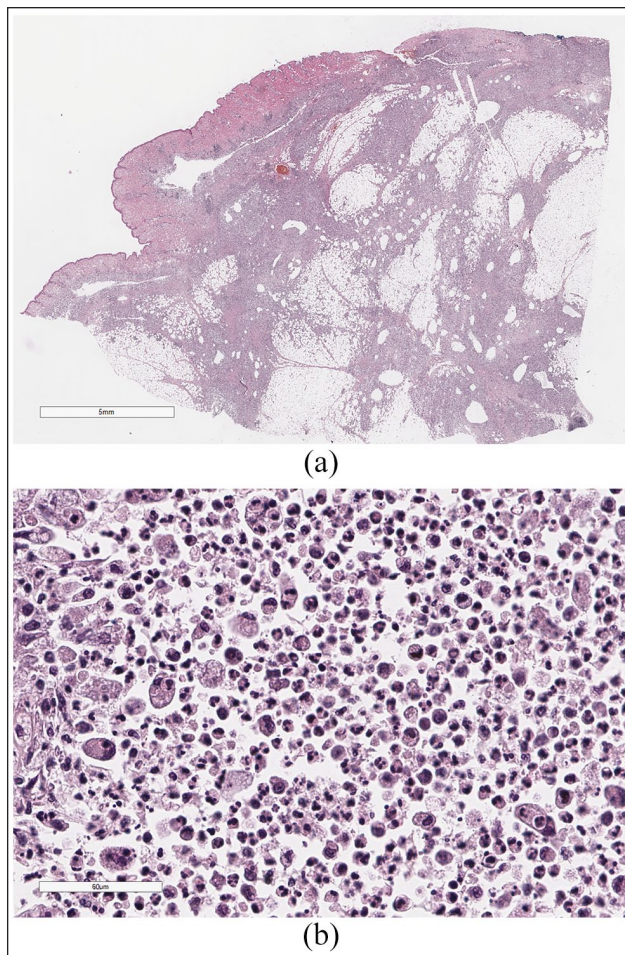


Figure 1 (a) Multifocal-to-coalescing regions of necrosis and pyogranulomatous inflammation severely disrupt the dermis and subcutis in this section of haired skin. Hematoxylin and eosin stain; bar = 5 mm. (b) A higher magnification of the inflammation. Loose sheets of epithelioid macrophages and degenerate neutrophils. Some macrophages contain phagocytized neutrophils. Hematoxylin and eosin stain; bar = 60 µm

count revealed leukocytosis (25,630/µl; reference interval [RI] 5500–19,500) and neutrophilia (23,290/µl; RI 2500–14,000). Serum biochemistry revealed elevated alanine transaminase (ALT; 669 U/l [RI 22–100]). Aerobic and anaerobic bacterial cultures were performed on swab samples, but no organisms were isolated. The cat was continued on clindamycin for another month and was then switched to doxycycline (5.5 mg/kg PO q12h) and pradofloxacin (7.5 mg/kg PO q24h [Veraflox; Bayer]) because of a suspicion of mycobacterial infection.

Three weeks later (21 weeks after the initial presentation), the cat was presented to the Dermatology Service at Louisiana State University. Multiple erythematous-to-violaceous macules and ulcerations were present on the ventral abdomen (Figure 2). Three cavernous, communicating tracts were seen in the right inguinal area.

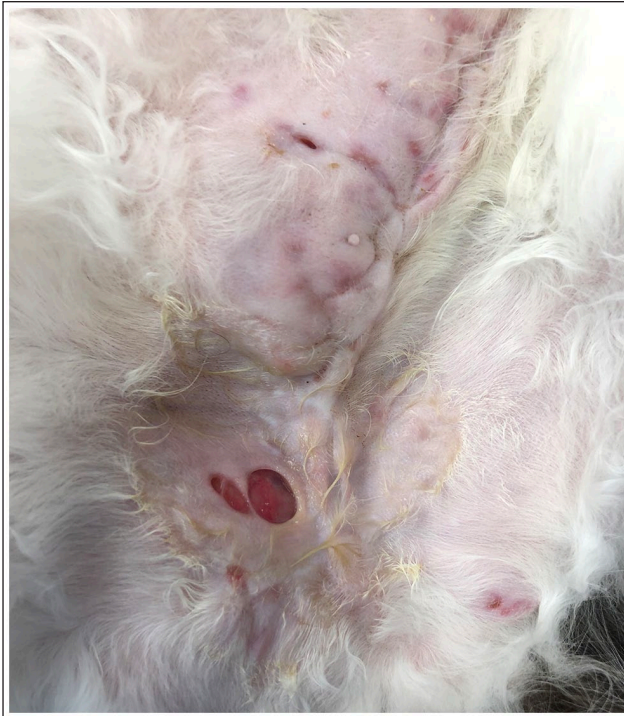

Figure 2 The cat first presented to the dermatology service with multiple erythematous-to-purpuric macules and ulcerations forming cavernous and communicating draining tracts on the ventral abdomen. A firm, irregularly shaped subcutaneous mass was present along the previous incision site and extended to the right

They extended into the musculature and contained very small amounts of serous exudate. An approximately 6×6 cm, palpable, firm, irregularly shaped subcutaneous mass was present along, and to the right of, the previous incision site. Physical examination was otherwise unremarkable.

A Diff-Quik-stained cytologic examination of an impression smear of the draining tracts revealed pyogranulomatous inflammation. One macrophage was suspected of containing a few intracytoplasmic, negatively stained rod-shaped bacteria. The cat was lightly sedated with dexmedetomidine (3.5 µg/kg IV [Dexdomitor; Zoetis]) and butorphanol (0.3 mg/kg IV [Torbugesic-SA; Zoetis]). Affected areas were anesthetized by subcutaneous injections of lidocaine (Lidocaine 2%; VetOne) in a ring-block pattern. Three 4 mm punch biopsy specimens were collected for aerobic and anaerobic bacterial, mycobacterial and fungal culture and submitted to the Clinical Bacteriology and Mycology Laboratory at the University of Tennessee College of Veterinary Medicine. A fine-needle aspiration was attempted, but the volume of fluid obtained was not considered sufficient for further evaluation at the time. Pradofloxacin was continued pending the results, but doxycycline was discontinued because of the previously noted increase in ALT level. The owners

were instructed to apply silver sulfadiazine 1% cream to the erosions and ulcerations twice daily.

Aerobic bacterial culture revealed two isolates with distinctly different appearances. One had a smooth white surface, while the other had a white, rough and dry surface. Matrix-assisted laser desorption/ionization time-of-flight mass spectrometry (MALDI-TOF MS) identified both types of colonies as *M goodii*. These results were confirmed by 16S rRNA gene sequencing.

Antimicrobial susceptibility tests (Table 1) by broth microdilution revealed slightly different susceptibility results: both isolates were susceptible to doxycycline and most fluoroquinolones; however, one isolate was resistant to ciprofloxacin. Based on the results, silver sulfadiazine and pradofloxacin were continued, and doxycycline (5.5 mg/kg PO q12h) was restarted after re-evaluation of ALT (35 U/l; RI 0–90).

Eight weeks after the presentation to the dermatology service, the subcutaneous mass had decreased in size, and the cat only had a small ulcer remaining in the right inguinal area. Medications were continued at the same dosage. Four weeks later, only a small erosion was present in the right inguinal area. The subcutaneous mass was smaller, measuring 6×4.3 cm. Image analysis software (ImageJ v1.53k; National Institutes of Health) was also used to measure the surface area of the lesion. The mass measured 20.2 cm². The doxycycline dose was increased (5.5 mg/kg PO in the morning and 11 mg/kg PO at night), while the rest of the medications remained the same. Over the next 10 weeks, the mass continued to decrease in size and fragmented into three small masses measuring 1.8×1 cm (surface area 1.9 cm²), 0.9×0.5 cm (surface area 0.5 cm²) and 0.7×0.5 cm (surface area 0.4 cm²). A linear structure believed to represent suture material and fibrosis could now be palpated. Treatment remained unchanged. Eleven weeks later, there were only two subcutaneous masses measuring 1.7×0.6 cm (surface area 1.2 cm²) and 0.8×0.5 cm (surface area 0.4 cm²). The suspected suture material remained unchanged. Twenty-five weeks later (66 weeks after the presentation to the dermatology service), the cat returned (1 week after the owner discontinued all medications), at which time only the suspected suture material remained palpable. By the time this article was submitted, the cat had been off antibiotics for 4 months with no lesion recurrence noted.

Discussion

Feline cutaneous RGM infections are uncommon but do occasionally occur; however, detailed clinical characterization of infections with individual species has been infrequently reported in case reports and small-scale case series. Infections often occur following traumatic inoculation or wound contamination. In the present case, the infection was suspected to be a post-traumatic

Table 1 Results of antimicrobial susceptibility tests for *Mycobacterium goodii* determined by use of the broth microdilution and Kirby–Bauer methods

Antimicrobial	Broth microdilution* ([μ g/ml]/interpretation)				Kirby–Bauer† (mm/interpretation)			
	Isolate A		Isolate B		Isolate A		Isolate B	
Amikacin	≤ 1	S	≤ 1	S	–	–	–	–
Amoxicillin-clavulanate	8/4	NA	8/4	NA	–	–	–	–
Cefepime	> 32	NA	> 32	NA	–	–	–	–
Cefoxitin	> 128	R	128	R	–	–	–	–
Ceftriaxone	> 64	NA	> 64	NA	–	–	–	–
Ciprofloxacin	4	R	0.25	S	–	–	–	–
Clarithromycin	> 16	R	> 16	R	–	–	–	–
Doxycycline	≤ 0.12	S	≤ 0.12	S	–	–	–	–
Enrofloxacin	≤ 0.25	NA	≤ 0.25	NA	30	NA	35	NA
Imipenem	8	I	8	I	–	–	–	–
Linezolid	2	S	4	S	–	–	–	–
Marbofloxacin	≤ 1	NA	≤ 1	NA	33	NA	38	NA
Minocycline	≤ 1	S	≤ 1	S	–	–	–	–
Moxifloxacin	≤ 0.25	S	≤ 0.25	S	–	–	–	–
Pradofloxacin	≤ 0.25	NA	≤ 0.25	NA	41	NA	45	NA
Tigecycline	0.03	NA	≤ 0.015	NA	–	–	–	–
Tobramycin	2	S	2	S	–	–	–	–
Trimethoprim-sulfamethoxazole	$\leq 0.25/4.75$	S	$\leq 0.25/4.75$	S	–	–	–	–

*This method and the breakpoints are approved by the Clinical and Laboratory Standards Institute (CLSI)

†This is not a CLSI standardized method

S = susceptible; I = intermediate; R = resistant; NA = not applicable because standardized CLSI minimum inhibitory concentration breakpoints have not been established; (–) = not tested

phenomenon, as the cat lived with one other cat, initially presented with puncture wounds and had access to the yard.

M goodii, a species currently classified in the *M smegmatis* group,³ is rarely reported in cats. *M smegmatis* was first described in 1885 in humans.⁴ In 1999, *M goodii* was differentiated from *M smegmatis* based on gene sequencing results.⁵ It is likely that some earlier cases identified as *M smegmatis* were actually *M goodii*. More recently, MALDI-TOF MS using Mycobacteria Libraries v2.0 misidentified *M goodii* as *M smegmatis*;⁶ however, Mycobacteria Libraries v3.0 correctly identifies *M goodii*.⁶

M goodii has been considered as an emerging nosocomial pathogen in human patients.⁷ Prosthetic device contamination has been identified and is likely a common source of *M goodii* infections.^{7,8} Infection frequently results in osteomyelitis;^{3,5} however, endocarditis, lipoid pneumonia, bursitis, vasculitis and endophthalmitis have also been reported.

To our knowledge, only two veterinary cases have been identified in North America: one dog in Georgia⁹ and one cat in the south-eastern USA.² The cat was an 8-year-old spayed female Maine Coon with unspecified cutaneous lesions on the tail base and left flank. The cat was medically managed with marbofloxacin and

doxycycline for more than 11 months but had not achieved resolution by the time the article was submitted.

In the present case, a cutaneous RGM infection was highly suspected because of typical skin lesions on the ventral abdomen and a previous histopathologic diagnosis of pyogranulomatous dermatitis and panniculitis, despite the failure to reveal acid-fast positive bacilli. As acid-fast stains inconsistently detect saprophytic mycobacteria,^{9,10} culture is still indicated before this differential can be ruled out. Aseptically obtained, ultrasound-guided fine-needle aspirates of the subcutaneous tissue and/or fluid have been suggested as preferred specimens to isolate RGM.^{11,12}

Interestingly, bacteria with two distinctly different phenotypes were cultured. One had a smooth white appearance, while the other was white, rough and dry. Despite the phenotypic differences, 16S rRNA gene sequencing revealed that both isolates were genetically identical. One possible explanation is that the isolate may have undergone phenotypic switching. This phenomenon can occur when bacteria experience environmental stress. Phenotype switching may increase the development of adaptive changes and be involved in the development of antimicrobial resistance. Indeed,

the bacteria isolated in the current case had two slightly different antibiotic resistance profiles. However, phenotypic switching can also occur randomly in the absence of stress. Phenotypic switching has been identified in both tuberculous and non-tuberculous mycobacteria, including *M smegmatis*.^{13,14}

We selected pradofloxacin and doxycycline based on antimicrobial susceptibility testing results (Table 1). For RGM, broth microdilution standards for amikacin, cefoxitin, ciprofloxacin, clarithromycin, doxycycline (or minocycline), imipenem, linezolid, meropenem, moxifloxacin, trimethoprim-sulfamethoxazole and tobramycin have been approved by the Clinical and Laboratory Standards Institute (CLSI).¹⁵ In contrast, the CLSI has not provided standards for other antimicrobials in broth microdilution or Kirby–Bauer tests. Although one of the isolates was resistant to ciprofloxacin, it was sensitive to moxifloxacin on broth microdilution and demonstrated a large Kirby–Bauer inhibition zone with enrofloxacin, marbofloxacin and pradofloxacin. Additionally, although the CLSI does not have standards for pradofloxacin,¹⁵ the susceptibility to another 8-methoxy fluoroquinolone (moxifloxacin) suggested that pradofloxacin would be an appropriate treatment in this case.

Pradofloxacin has activity against Gram-positive and anaerobic bacteria, good tissue and macrophage penetration¹⁶ and known retinal safety in cats.¹⁷ It has been shown to have a lower minimum inhibitory concentration and superior efficacy against *M goodii* and *M smegmatis* *sensu stricto* vs enrofloxacin and ciprofloxacin.¹⁸ It is generally recommended to use fluoroquinolones combined with macrolides or doxycycline to lower the chance of resistance development while treating mycobacterial infections, including RGM.¹⁹ However, *M goodii* is likely to develop resistance to macrolides because of an inducible rRNA methylase gene *erm*(38).²⁰ This phenomenon is unique when compared with other RGM species.⁸ In the current case, the species identification discouraged using macrolides (a decision later supported by the susceptibility results). Therefore, we decided to use a combination of pradofloxacin and doxycycline. The doxycycline dosage was increased to the level the cat could tolerate without gastrointestinal adverse effects, based upon previous reports.¹¹

Of note, the *M goodii* isolated from the cat described in the south-eastern US report² demonstrated virtually the same susceptibility pattern as our case, including resistance to clarithromycin. In contrast, the isolate from the dog in Georgia⁹ was sensitive to almost all the antimicrobials tested, including clarithromycin.

Additionally, the role of surgery in the management of RGM is somewhat controversial, with some authors recommending initiation of antimicrobial treatment and reassessment followed by surgical intervention.¹¹ Continued antimicrobial administration after surgery is

recommended to facilitate healing.^{10,11} However, other authors feel that there is insufficient evidence that surgery is required for resolution of the infection.² Further confusing the issue is the variable response to surgery observed in previous reports, as well as the lack of controlled comparison studies. Therefore, the decision to perform surgery generally depends on the practitioner's clinical experience and judgment.

In the current case, the last palpably abnormal tissue was associated with what seemed to be residual suture material. Subcutaneous closure had been performed using polyglyconate (Maxon; Covidien), which is a slowly absorbed suture. Biofilm development on slowly absorbed suture has the potential to serve as a nidus for future recrudescence of infection. Rapidly absorbed monofilament sutures have a lower risk of prolonged bacterial colonization and may be a better option for surgical closure.

As the present cat had already demonstrated disease recurrence following surgery, it was decided to postpone another surgery until the response to medical management reached a plateau. However, surgery was not required as medical management alone resulted in clinical resolution.

Conclusions

This is only the second case of cutaneous *M goodii* infection reported in North American cats. This case illustrates the importance of performing a culture of aseptically obtained tissue or fine-needle aspirates of fluid when clinical findings are consistent with a cutaneous RGM infection, even if histopathology does not demonstrate organisms. Genetically identical isolates may demonstrate different antimicrobial susceptibility results, and thus performing separate susceptibility testing on phenotypically dissimilar isolates is warranted. The use of modern techniques such as MALDI–TOF MS and 16S rRNA gene sequencing provides rapid differentiation of *M goodii* from other RGM species, which facilitates prompt selection of proper antimicrobial treatments. Further studies are needed to further characterize clinical differences in cutaneous infections caused by different RGM species.

Conflict of interest The authors declared no potential conflicts of interest with respect to the research, authorship, and/or publication of this article.

Funding The authors received no financial support for the research, authorship, and/or publication of this article.

Ethical approval The work described in this manuscript involved the use of non-experimental (owned or unowned) animals. Established internationally recognised high standards ('best practice') of veterinary clinical care for the individual

patient were always followed and/or this work involved the use of cadavers. Ethical approval from a committee was therefore not specifically required for publication in *JFMS Open Reports*. Although not required, where ethical approval was still obtained, it is stated in the manuscript.

Informed consent Informed consent (verbal or written) was obtained from the owner or legal custodian of all animal(s) described in this work (experimental or non-experimental animals, including cadavers) for all procedure(s) undertaken (prospective or retrospective studies). For any animals or people individually identifiable within this publication, informed consent (verbal or written) for their use in the publication was obtained from the people involved.

ORCID ID Sandra Diaz  <https://orcid.org/0000-0003-0205-2165>

Cherie Pucheu-Haston  <https://orcid.org/0000-0003-1916-7188>

References

- Lloret A, Hartmann K, Pennisi MG, et al. **Mycobacterioses in cats: ABCD guidelines on prevention and management.** *J Feline Med Surg* 2013; 15: 591–597.
- Horne KS and Kunkle GA. **Clinical outcome of cutaneous rapidly growing mycobacterial infections in cats in the south-eastern United States: a review of 10 cases (1996–2006).** *J Feline Med Surg* 2009; 11: 627–632.
- Brown-Elliott BA and Wallace RJ, Jr. **Clinical and taxonomic status of pathogenic nonpigmented or late-pigmenting rapidly growing mycobacteria.** *Clin Microbiol Rev* 2002; 15: 716–746.
- Lustgarten S. **The bacillus of syphilis.** *Lancet* 1885; 125: 609–610.
- Brown BA, Springer B, Steingrube VA, et al. ***Mycobacterium wolinskyi* sp. nov. and *Mycobacterium goodii* sp. nov., two new rapidly growing species related to *Mycobacterium smegmatis* and associated with human wound infections: a cooperative study from the International Working Group on Mycobacterial Taxonomy.** *Int J Syst Bacteriol* 1999; 49: 1493–1511.
- Rodriguez-Temporal D, Perez-Risco D, Struzka EA, et al. **Impact of updating the MALDI-TOF MS database on the identification of nontuberculous mycobacteria.** *J Mass Spectrom* 2017; 52: 597–602.
- Salas NM and Klein N. ***Mycobacterium goodii*: an emerging nosocomial pathogen: a case report and review of the literature.** *Infect Dis Clin Pract (Baltim Md)* 2017; 25: 62–65. DOI: 10.1097/IPC.0000000000000428.
- Brown-Elliott BA, Nash KA and Wallace RJ, Jr. **Antimicrobial susceptibility testing, drug resistance mechanisms, and therapy of infections with nontuberculous mycobacteria.** *Clin Microbiol Rev* 2012; 25: 545–582.
- Krimer PM, Phillips KM, Miller DM, et al. **Panniculitis attributable to *Mycobacterium goodii* in an immunocompetent dog in Georgia.** *J Am Vet Med Assoc* 2010; 237: 1056–1059.
- Malik R, Hunt GB, Goldsmid S, et al. **Diagnosis and treatment of pyogranulomatous panniculitis due to *Mycobacterium smegmatis* in cats.** *J Small Anim Pract* 1994; 35: 524–530.
- Malik R, Wigney DI, Dawson D, et al. **Infection of the subcutis and skin of cats with rapidly growing mycobacteria: a review of microbiological and clinical findings.** *J Feline Med Surg* 2000; 2: 35–48.
- Malik R, Shaw S, Griffin C, et al. **Infections of the subcutis and skin of dogs caused by rapidly growing mycobacteria.** *J Small Anim Pract* 2004; 45: 485–494.
- Kocincova D, Singh AK, Beretti JL, et al. **Spontaneous transposition of IS1096 or ISMsm3 leads to glycopeptidolipid overproduction and affects surface properties in *Mycobacterium smegmatis*.** *Tuberculosis (Edinb)* 2008; 88: 390–398.
- Wakamoto Y, Dhar N, Chait R, et al. **Dynamic persistence of antibiotic-stressed mycobacteria.** *Science* 2013; 339: 91–95.
- Clinical and Laboratory Standards Institute. **Antimicrobial agents and breakpoints for testing rapidly growing mycobacteria.** In: Woods GL, Wengenack NL, Lin G, et al (eds). M62 Performance standards for susceptibility testing of mycobacteria, *Nocardia* spp, and other aerobic actinomycetes. Wayne, PA: Clinical and Laboratory Standards Institute, 2018, pp 7–9.
- Papich MG. **Fluoroquinolone antimicrobial drugs.** In: Riviere JE and Papich MG (eds). *Veterinary pharmacology and therapeutics*. 10th ed. Hoboken, NJ: John Wiley & Sons, 2018, pp 953–987.
- Messias A, Gekeler F, Wegener A, et al. **Retinal safety of a new fluoroquinolone, pradofloxacin, in cats: assessment with electroretinography.** *Doc Ophthalmol* 2008; 116: 177–191.
- Govendir M, Norris JM, Hansen T, et al. **Susceptibility of rapidly growing mycobacteria and *Nocardia* isolates from cats and dogs to pradofloxacin.** *Vet Microbiol* 2011; 153: 240–245.
- Miller WH, Griffin CE and Campbell KL. *Muller and Kirk's small animal dermatology*. 7th ed. St Louis, MO: Saunders, 2013, pp 184–222.
- Nash KA, Andini N, Zhang Y, et al. **Intrinsic macrolide resistance in rapidly growing mycobacteria.** *Antimicrob Agents Chemother* 2006; 50: 3476–3478. DOI: 10.1128/AAC.00402-06.