



---

## **Successful treatment and long-term follow up of idiopathic immune-mediated polyarthritis with mycophenolate mofetil in a cat**

Authors: Tamura, Yu, Nagamoto, Tetsuro, Segawa, Kazuhito, Neo, Sakurako, Igarashi, Hirotaka, et al.

Source: Journal of Feline Medicine and Surgery Open Reports, 6(2)

Published By: SAGE Publishing

URL: <https://doi.org/10.1177/2055116920963995>



# Successful treatment and long-term follow up of idiopathic immune-mediated polyarthritis with mycophenolate mofetil in a cat

*Journal of Feline Medicine and Surgery Open Reports*

Volume: 6: 1–5

© The Author(s) 2020

Article reuse guidelines:

sagepub.com/journals-permissions

DOI: 10.1177/2055116920963995

journals.sagepub.com/home/jfmsopenreports

This paper was handled and processed by the European Editorial Office (ISFM) for publication in *JFMS Open Reports*



Yu Tamura<sup>1,2\*</sup> , Tetsuro Nagamoto<sup>1\*</sup>, Kazuhito Segawa<sup>3</sup>, Sakurako Neo<sup>4</sup>, Hirotaka Igarashi<sup>2</sup> and Masaharu Hisasue<sup>2</sup>

## Abstract

**Case summary** A 7-year-old neutered male Norwegian Forest Cat was presented with decreased appetite and activity, weight loss, fever, neutrophilia and hyperglobulinaemia. A physical examination showed painful stifle joints and enlarged popliteal lymph nodes. Blood examination showed neutrophilia, hyperglobulinaemia and increased serum amyloid A. Urinalysis, thoracic and abdominal radiographs, and abdominal ultrasonography were unremarkable. Synovial fluid from the knee joints had diminished viscosity and revealed neutrophilic inflammation on the smear. There was no evidence of infection in a microbiological culture of the synovial fluid. A diagnosis of idiopathic immune-mediated polyarthritis (IMPA) was made. Prednisolone was initiated at 2 mg/kg q24h PO and tapered with additional immunosuppressants (leflunomide, ciclosporin A and methotrexate); however, prednisolone could not be discontinued. Informed consent was obtained from the owner and mycophenolate mofetil (MMF) at a dosage of 10 mg/kg q12h PO was initiated on day 798. There were no adverse effects of MMF and prednisolone was discontinued on day 1183. Clinical signs resolved and the cat's general condition remained stable with MMF alone at a dosage of 10 mg/kg q48h PO on day 1600.

**Relevance and novel information** There is limited information describing feline IMPA and its treatment options other than the use of prednisolone. This is the first report of the successful treatment and long-term follow-up of feline IMPA with MMF. MMF may be a safe and effective option as an additional immunosuppressant in feline IMPA.

**Keywords:** Efficacy; immune-mediated disease; immunosuppressant; side effects; idiopathic immune-mediated polyarthritis; mycophenolate mofetil

**Accepted:** 7 September 2020

## Introduction

Feline idiopathic immune-mediated polyarthritis (IMPA) is a very rare disease compared with immune-based arthritis in dogs.<sup>1</sup> There are only two previous reports of feline IMPA.<sup>2</sup> IMPA is a non-infectious inflammatory joint disorder that is diagnosed by the presence of neutrophil-rich synovial fluid collected by arthrocentesis. It is categorised as an immune-mediated non-erosive polyarthritis.<sup>1,2</sup> Differential diagnoses of immune-mediated non-erosive polyarthritis are reactive polyarthritis and systemic lupus erythematosus (SLE).<sup>2</sup> Therefore, the diagnosis of IMPA is made as primary

<sup>1</sup>Veterinary Teaching Hospital, Azabu University, Sagami-hara, Kanagawa, Japan

<sup>2</sup>Laboratory of Small Animal Internal Medicine, School of Veterinary Medicine, Azabu University, Sagami-hara, Kanagawa, Japan

<sup>3</sup>Sagami-hara Animal Medical Centre, Kanagawa, Japan

<sup>4</sup>Laboratory of Clinical Diagnosis, School of Veterinary Medicine, Azabu University, Sagami-hara, Kanagawa, Japan

\*Yu Tamura and Tetsuro Nagamoto contributed equally to this work

### Corresponding author:

Masaharu Hisasue DVM, PhD, Laboratory of Small Animal Internal Medicine, School of Veterinary Medicine, Azabu University, 1-17-71, Fuchinobe, Chuo-ku, Sagami-hara, Kanagawa 252-5201, Japan  
 Email: hisasue@azabu-u.ac.jp



Creative Commons Non Commercial CC BY-NC: This article is distributed under the terms of the Creative Commons

Attribution-NonCommercial 4.0 License (<https://creativecommons.org/licenses/by-nc/4.0/>) which permits non-commercial use, reproduction and distribution of the work without further permission provided the original work is attributed as specified on the SAGE and Open Access pages (<https://us.sagepub.com/en-us/nam/open-access-at-sage>).

immune-mediated non-erosive polyarthritis by excluding SLE.<sup>2</sup> Corticosteroids are considered the first line of treatment and should be combined with other immunosuppressants if a single agent is not effective.<sup>1,2</sup> In cats, additional reported immunosuppressants used for immune-mediated polyarthritis are as follows: leflunomide (LEF), ciclosporin A (CsA), methotrexate (MTX) and chlorambucil.<sup>2</sup>

Mycophenolate mofetil (MMF) is an immunosuppressant that is a prodrug of the active moiety mycophenolic acid (MPA), a fermentation product of *Penicillium* species.<sup>3</sup> MPA inhibits inosine monophosphate dehydrogenase, a regulator of the intracellular guanine nucleotide pool, resulting in the inhibition of intracellular DNA synthesis. This, in turn, prevents lymphocyte proliferation, antibody production, cellular adhesion, and T and B lymphocyte migration.<sup>3</sup> In human medicine, MMF is used for organ transplants and various immune-mediated diseases.<sup>4</sup> Similarly, in veterinary medicine, MMF is also effective for immune-mediated diseases in dogs. It is used as an alternative immunosuppressant in dogs with IMPA.<sup>5,6</sup> Moreover, MMF is recommended as one of the additional immunosuppressants in dogs with immune-mediated haemolytic anaemia (IMHA).<sup>7</sup>

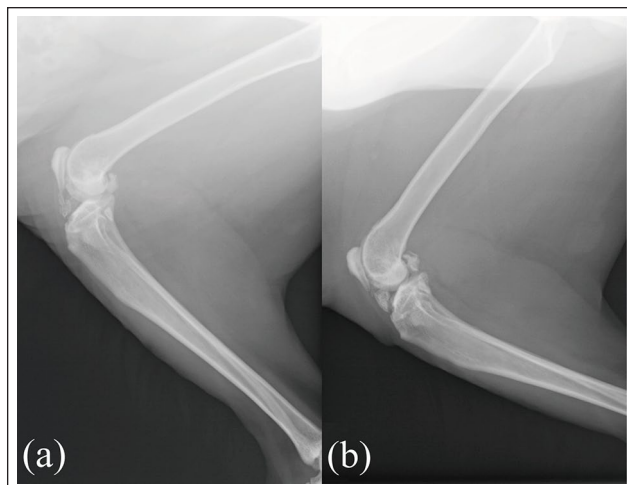
Meanwhile, there is little information about its safety and efficacy in cats.<sup>8,9</sup> It is reported that MMF is absorbed from intestines and biotransformed to MPA after oral administration in healthy cats.<sup>8</sup> Moreover, MMF was reported to be effective in cats with IMHA without significant side effects.<sup>10</sup> Therefore, MMF may be one of the safe and effective treatments for immune-mediated diseases in cats.

Here, we report the use of MMF in a cat with IMPA, which had a poor response to other immunosuppressants. As a result of using MMF, corticosteroids withdrawal became possible. No side effects were observed in the long-term administration of MMF lasting more than 2 years.

## Case description

A 7-year-old neutered male Norwegian Forest Cat was presented at Azabu University Veterinary Teaching Hospital with decreased appetite and activity, and fever (day 0). Prior to the referral, the cat was treated with robenacoxib (Onsior, Elanco; 1 mg/kg q24h PO) and amoxicillin (Amoxiclear, Kyoritsu Seiyaku; 20 mg/kg q12h PO); however, its clinical signs did not improve. Then it was treated with anti-inflammatory dosage of prednisolone (Predonin, Shionogi Seiyaku; q24h PO). The cat's clinical signs did not completely resolve, although its appetite improved.

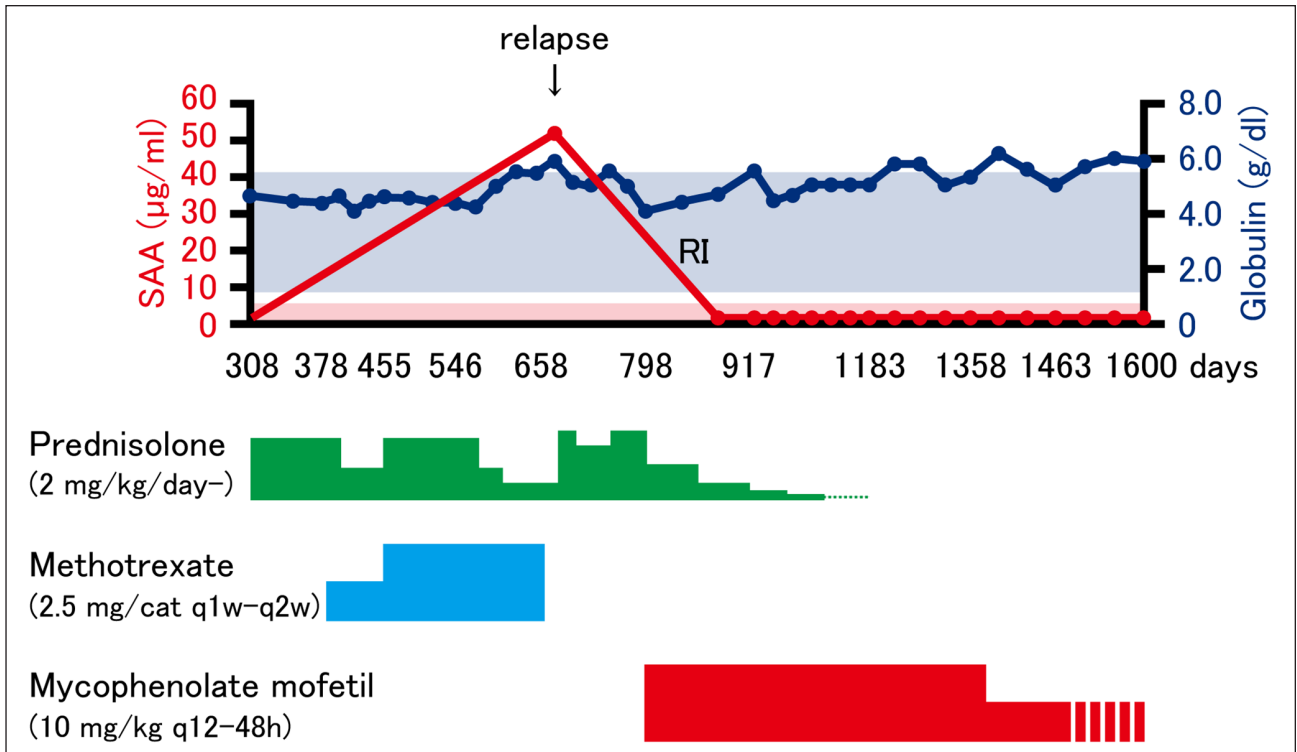
A physical examination showed hyperthermia (40.1°C), painful and enlarged stifle joints, and enlarged popliteal lymph nodes. Blood examination revealed neutrophilia (46,840 cells/ $\mu$ l; reference interval [RI]



**Figure 1** Lateral stifle radiographs of (a) right and (b) left sides. Neither show bone erosions, although increased synovial volume and meniscal mineralisation are visible

2500–12,500 cells/ $\mu$ l) and hyperglobulinaemia (7.3 g/dl; RI 1.5–5.3 g/dl) that revealed polyclonal gammopathy by serum protein electrophoresis (FUJIFILM VET Systems). Serum amyloid A (SAA; Sanritsu Zelkova) was increased to 36.16  $\mu$ g/ml (RI <6.0  $\mu$ g/ml). Feline leukaemia virus antigen and feline immunodeficiency virus antibody tests (SNAP FIV/FelV Combo Kit; IDEXX) were negative. Antinuclear antibody (IDEXX) was also negative. Urinalysis (including urine protein to creatinine ratio 0.13), thoracic and abdominal radiographs and abdominal ultrasonography were unremarkable. Lateral stifle radiographs showed increased synovial volume and meniscal mineralisation, although there were no bone erosions (Figure 1). Synovial fluid from the stifle joints had diminished viscosity and revealed neutrophilic inflammation on the smear. There was no evidence of infection by microbiological cultures of separated synovial fluids of each stifle joint. Therefore, the cat was diagnosed with IMPA.

Prednisolone was initiated at 2 mg/kg q24h PO (day 0). The clinical signs ameliorated. To taper prednisolone, leflunomide (LEF [Arava; Sanofi]) at a dosage of 10 mg/cat q24h PO was added as the first-line additional immunosuppressant from day 77. The prednisolone dosage was gradually tapered over 4 months; however, clinical signs recurred. Neutrophilia and increased SAA (18.76  $\mu$ g/ml; RI <6.0  $\mu$ g/ml) were seen again on day 147. LEF was then discontinued. A regimen of CsA (Atopica; Elanco) at a dosage of 4 mg/kg q24h PO was initiated, with prednisolone increasing to 2 mg/kg q24h again from day 175. After 3 months, a second relapse occurred on day 280 when oral prednisolone was reduced to 0.4 mg/kg q24h. Remission of IMPA could not be maintained with the treatment combining



**Figure 2** Clinical course of treatment with prednisolone and methotrexate (MTX) or mycophenolate mofetil (MMF). Prednisolone is discontinued with MMF but not with MTX. Dosage of MMF was tapered to 10mg/kg PO q48h. SAA = serum amyloid A; RI = reference interval

low-dose CsA and prednisolone. Increasing the dose of CsA was not possible because of treatment cost issues. Therefore, MTX (methotrexate tablets; Pfizer) at a dosage of 2.5mg/cat PO once a week was instituted. It was increased to twice a week with prednisolone from day 378 (Figure 2).

After 10 months, when oral prednisolone was reduced to 0.4mg/kg q24h, IMPA recurred with decreased appetite and activity and increased SAA (51.93µg/ml; RI <6.0µg/ml) again on day 690 (Figure 2). After that, the owner agreed to use MMF as an additional immunosuppressant, although there was little information on its use in cats. Therefore, MMF (CellCept Powder for Oral Suspension 31.8%; Chugai Pharmaceutical) at a dosage of 10mg/kg q12h PO was initiated with prednisolone on day 798. Following this medication change, the cat was generally in good physical condition, without fever and painful joints. Moreover, there were no adverse effects, including gastrointestinal signs or cytopenias due to bone marrow suppression with MMF administration. From day 798, prednisolone was reduced by 35–50% every 1–2months and was discontinued on day 1183 (Figure 2). Moreover, MMF was reduced from 10mg/kg q12h to 10mg/kg q24h on day 1358, and thereafter from 10mg/kg q24h to 10mg/kg q48h on day 1463 (Figure 2). After 802 days of MMF therapy, the cat was still under

treatment with the same dosage of MMF on day 1600. It was free of clinical signs, and SAA (<6.0µg/ml) was within the normal range after the initiation of MMF therapy (Figure 2).

**Discussion**

This is the first case report of the use of MMF in a cat with IMPA. After initiating its use, we successfully withdrew the corticosteroids. No side effects, such as gastrointestinal signs and bone marrow suppression, were observed during the long-term administration of MMF lasting >2 years. These results suggest that MMF may be effective in cats with IMPA and relatively safe even for long-term administration.

Recently, there have been some reports on the safety and pharmacokinetics of MMF in healthy cats.<sup>8,9,11,12</sup> In cats, when MMF is orally administered, it is absorbed in the intestine and rapidly converted to MPA in the plasma.<sup>9,11,12</sup> It is then bound to plasma proteins, rapidly metabolised by hepatocytes and excreted mainly in urine.<sup>11,12</sup> The main side effects of MMF are gastrointestinal signs and myelosuppression. It has been suggested that the accumulation of MPA causes side effects.<sup>12</sup> There was a concern that the side effects of MMF in cats would be greater than those in humans and dogs, as cats lack some enzymes normally expressed in the liver that are

important for glucuronidation, a process involved in metabolic pathway for drugs.<sup>13</sup> Slovak et al<sup>12</sup> reported that MPA phenol glucuronide formation was significantly slower in cats compared with humans and dogs because of enzyme deficiencies in glucuronidation; however, total MPA conjugations showed a much smaller difference in these species because MPA phenol glucoside formation occurred by glucosidation, another metabolic pathway, predominantly involved in MPA metabolism in cats.<sup>12</sup>

Before MMF was developed, azathioprine (AZA) was used as an immunosuppressant after transplantation in humans.<sup>14</sup> AZA is a prodrug of mercaptopurine, which acts as a purine analogue and inhibits DNA synthesis.<sup>13</sup> The mechanism of immunosuppression is similar in AZA and MMF. However, the risk of AZA toxicity is very high in cats because of their lower metabolic enzyme activity.<sup>5</sup> Therefore, the risk of MMF toxicity in cats may be considered at least lower than that of AZA toxicity. The side effects of MMF have been reported to occur in a dose-dependent manner, and up to 10 mg/kg q12h PO can be tolerated in cats.<sup>8,9</sup> Moreover, this dosage was reported to be effective in cats with IMHA without significant side effects for 2 months.<sup>10</sup> In this case, MMF at a dosage of 10 mg/kg q12h PO led to complete remission of IMPA, and no side effects were observed during the treatment period of >2 years. However, a recent report showed that MMF might have some side effects in cats other than gastrointestinal signs and myelosuppression such as hepatopathy and pancreatitis.<sup>15</sup> The side effects and safety of MMF for long-term administration remain unknown because there are only two reports that have described the clinical use of MMF in cats with IMHA.<sup>10,15</sup> Side effects were not observed in this case where treatment lasted for >2 years, indicating that previously reported doses of MMF do not necessarily cause side effects in long-term administration owing to inter-individual variability in the metabolism of MMF in cats.<sup>8,9</sup> MMF has been recommended as the first choice for additional immunotherapy in canine IMPA.<sup>6</sup> Similarly, in cats with IMPA, MMF may be a relatively safe and effective additional immunosuppressant when other drugs are inadequate. Further investigation will be needed to study any additional side effects in cats with long-term use of MMF.

Some limitations of this report relate to the treatment regimens and monitoring. First, chlorambucil was not used in this case because the drug was not licensed in Japan; therefore, a stable supply was not guaranteed. Secondly, we did not use the combination therapy of LEF with MTX previously reported to be effective in cats with rheumatoid arthritis.<sup>16</sup> Hanna<sup>16</sup> reported that 7/12 (58%) cats with rheumatoid arthritis showed a marked improvement, suggesting that this combination therapy may be effective for feline IMPA. Although we suggested the combination therapy (LEF and MTX) to the owner, this recommendation was not accepted because the cat

did not respond completely to each therapy. Finally, we did not investigate therapeutic drug monitoring (TDM) of MMF and LEF because the methods for TDM measurement of MMF and LEF are not established in veterinary medicine. Further studies, with a larger sample of feline IMPA cases, are required to clarify the indications, appropriate dosage, administration period, efficacy and side effects of MMF.

## Conclusions

In this case, MMF was more effective than LEF, CsA and MTX as an additional immunosuppressant in a cat with IMPA. Moreover, there were no adverse effects associated with using MMF in the cat for >2 years. Therefore, MMF may be a relatively safe and effective option as an additional immunosuppressant in cats with immune-mediated diseases such as IMPA.

**Acknowledgements** We would like to thank Editage (www.editage.com) for English language editing.

**Conflict of interest** The authors declared no potential conflicts of interest with respect to the research, authorship, and/or publication of this article.

**Funding** The authors received no financial support for the research, authorship, and/or publication of this article.

**Ethical approval** This work involved the use of non-experimental animals only (including owned or unowned animals and data from prospective or retrospective studies). Established internationally recognised high standards ('best practice') of individual veterinary clinical patient care were followed. Ethical approval from a committee was therefore not necessarily required.

**Informed consent** Informed consent (either verbal or written) was obtained from the owner or legal custodian of all animal(s) described in this work (either experimental or non-experimental animals) for the procedure(s) undertaken (either prospective or retrospective studies). No animals or humans are identifiable within this publication, and therefore additional informed consent for publication was not required.

**ORCID iD** Yu Tamura  <https://orcid.org/0000-0003-0624-9037>

## References

- Bennett D and Nash AS. **Feline immune-based polyarthriti: a study of thirty-one cases.** *J Small Anim Pract* 1988; 29: 501–523.
- Lemetayer J and Taylor S. **Inflammatory joint disease in cats: diagnostic approach and treatment.** *J Feline Med Surg* 2014; 16: 547–562.
- Bullingham RE, Nicholls AJ and Kamm BR. **Clinical pharmacokinetics of mycophenolate mofetil.** *Clin Pharmacokinet* 1998; 34: 429–455.
- Abd Rahman AN, Tett SE and Staatz CE. **Clinical pharmacokinetics and pharmacodynamics of mycophenolate**

- in patients with autoimmune disease. *Clin Pharmacokinet* 2013; 52: 303–331.
- 5 Viviano KR. **Update on immunosuppressive therapies for dogs and cats.** *Vet Clin North Am Small Anim Pract* 2013; 43: 1149–1170.
  - 6 Stone M. **Immune-mediated polyarthritis and other polyarthritides.** In: Ettinger SJ and Feldman EC (eds). *Textbook of veterinary internal medicine*. 8th ed. St Louis, MO: Elsevier, 2017, pp 861–866.
  - 7 Swann JW, Garden OA, Fellman CL, et al. **ACVIM consensus statement on the treatment of immune-mediated hemolytic anemia in dogs.** *J Vet Intern Med* 2019; 33: 1141–1172.
  - 8 Slovak JE, Hwang JK, Rivera SM, et al. **Pharmacokinetics of mycophenolic acid and its effect on CD4+ and CD8+ T cells after oral administration of mycophenolate mofetil to healthy cats.** *J Vet Intern Med* 2019; 33: 2020–2028.
  - 9 Slovak JE and Villarino NF. **Safety of oral and intravenous mycophenolate mofetil in healthy cats.** *J Feline Med Surg* 2018; 20: 184–188.
  - 10 Bacek LM and Macintire DK. **Treatment of primary immune-mediated hemolytic anemia with mycophenolate mofetil in two cats.** *J Vet Emerg Crit Care (San Antonio)* 2011; 21: 45–49.
  - 11 Rivera Vélez SM, Morassi A, Court MH, et al. **Development and validation of an ultrafast chromatographic method for quantification of the immunosuppressant mycophenolic acid in canine, feline and human plasma.** *J Pharm Biomed Anal* 2016; 131: 94–102.
  - 12 Slovak JE, Mealey K and Court MH. **Comparative metabolism of mycophenolic acid by glucuronic acid and glucose conjugation in human, dog, and cat liver microsomes.** *J Vet Pharmacol Ther* 2017; 40: 123–129.
  - 13 Court MH. **Feline drug metabolism and disposition: pharmacokinetic evidence for species differences and molecular mechanisms.** *Vet Clin North Am Small Anim Pract* 2013; 43: 1039–1054.
  - 14 Knight SR, Russell NK, Barcena L, et al. **Mycophenolate mofetil decreases acute rejection and may improve graft survival in renal transplant recipients when compared with azathioprine: a systematic review.** *Transplantation* 2009; 87: 785–794.
  - 15 Kopke MA and Galloway PEJ. **Suspected hepatopathy and pancreatitis associated with mycophenolate mofetil use in a cat with immune-mediated haemolytic anaemia.** *JFMS Open Rep* 2020; 6. DOI: 10.1177/2055116920905038.
  - 16 Hanna FY. **Disease modifying treatment for feline rheumatoid arthritis.** *Vet Comp Orthop Traumatol*. 2005; 18: 94–99.