



---

## **Corneal bee sting in a Bengal cat**

Authors: Dulaurent, Thomas, Perard, Bertille, Mathieson, Iona, Dulaurent, Anne-Maïmiti, and Isard, Pierre-François

Source: Journal of Feline Medicine and Surgery Open Reports, 6(2)

Published By: SAGE Publishing

URL: <https://doi.org/10.1177/2055116920962431>



# Corneal bee sting in a Bengal cat

Thomas Dulaurent<sup>1</sup> , Bertille Perard<sup>2</sup>, Iona Mathieson<sup>3</sup>, Anne-Maïmiti Dulaurent<sup>4</sup> and Pierre-François Isard<sup>1</sup>

*Journal of Feline Medicine and Surgery Open Reports*  
1–4

© The Author(s) 2020

Article reuse guidelines:

sagepub.com/journals-permissions

DOI: 10.1177/2055116920962431

journals.sagepub.com/home/jfmsopenreports

This paper was handled and processed by the European Editorial Office (ISFM) for publication in *JFMS Open Reports*



## Abstract

**Case summary** A 6-month-old female Bengal cat was referred for a suspected vegetal foreign body (FB) in the mid-stroma of the right cornea. A small dark linear FB was identified in the dorsal aspect of the cornea, with associated cell infiltrate. Ophthalmic examination was otherwise normal, with no inflammatory reaction of the anterior uvea, and no abnormalities of the lens or fundus. Surgical removal was performed under general anesthesia. The FB, as observed under an optic microscope, was a worker bee stinger without the venom sac. Medical treatment consisted of topical and systemic antibiotics and steroids, and topical administration of atropine. Follow-up was uneventful.

**Relevance and novel information** Ocular bee stings have been described in humans, with several consequences ranging from mild conjunctivitis to severe lesions affecting the cornea, iris, lens and retina. Most severely affected cases have been observed when the venom sac was found with the stinger, with a likely greater amount of venom being delivered into the ocular structures. The relatively benign presentation of this case was probably due to the lack of the venom sac within the bee sting. To our knowledge, this is the first documented case of a corneal bee sting in a cat.

**Keywords:** Foreign body; cornea; bee stinger; surgical removal

**Accepted:** 7 September 2020

## Introduction

Ocular foreign bodies (FBs) are quite uncommon in cats.<sup>1</sup> Vegetal,<sup>2,3</sup> metallic<sup>4</sup> or ballistic<sup>5</sup> in nature, their penetration into the eye is usually accidental or a consequence of human malice. The ocular penetration of FBs is linked to the interactions between the patient and their environment. The severity of presenting signs is associated with the type, size, location and point of entry of the FB. Young patients show inquisitive behaviour and sometimes come in contact with arthropods. Close interaction might lead to the ocular penetration of arthropod hairs (caterpillar, spider), so-called ophthalmia nodosa. Close contact with arthropods (hymenopteran insects) might also lead to the ocular penetration of venom via a sting. When introduced to the ocular surface, it might be associated with various ocular reactions which may range from mild conjunctivitis to sudden loss of vision in humans.<sup>6</sup> To the best of our knowledge, a corneal bee sting has never been reported in cats. The aim of this case report was to describe the clinical features of a bee sting to the cornea in a feline patient.

## Case description

A 6-month-old female Bengal cat initially presented to the referring veterinarian with a 2–3-day history of ocular discomfort of the right eye (OD). During the first consultation, the referring veterinarian suspected the presence of an FB in the OD cornea. At that time, topical antibiotic treatment (q6h OD; Neomycin, Polymyxin B, Tevemyxine, [TVM]) was prescribed and the cat was referred.

The cat had an indoor lifestyle and there were no other cats in the household. Ornamental houseplants were present in the cat's home. A general physical

<sup>1</sup>Saint-Martin Hospital Veterinary Centre, Saint Martin Bellevue, France

<sup>2</sup>Veterinary Clinic of Hers, Castelginest, France

<sup>3</sup>Eyevet Referrals, Sutton Weaver, UK

<sup>4</sup>UniLaSalle, AGHYLE, Beauvais, France

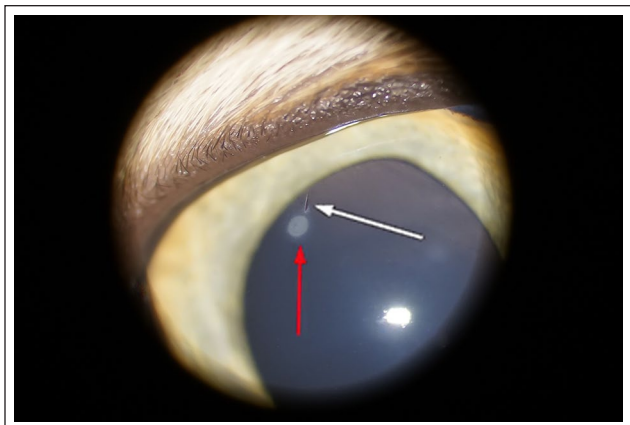
### Corresponding author:

Thomas Dulaurent DVM, Saint-Martin Veterinary Hospital Centre, 275 route Impériale, Saint Martin Bellevue 74370, France  
Email: ophthalmologie@chvsm.com



Creative Commons Non Commercial CC BY-NC: This article is distributed under the terms of the Creative Commons

Attribution-NonCommercial 4.0 License (<https://creativecommons.org/licenses/by-nc/4.0/>) which permits non-commercial use, reproduction and distribution of the work without further permission provided the original work is attributed as specified on the SAGE and Open Access pages (<https://us.sagepub.com/en-us/nam/open-access-at-sage>).



**Figure 1** OD aspect of the patient at initial presentation. The foreign body is visible in the dorsotemporal aspect of the cornea (white arrow), near a cellular infiltrate (red arrow)

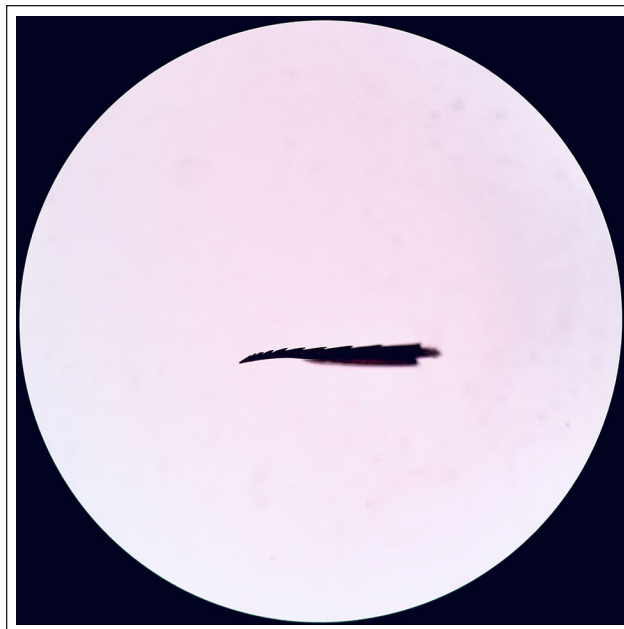
examination revealed no abnormalities. Menace response and dazzle reflex were normal bilaterally. Pupillary light reflexes were present and normal in both eyes (OU).

No ocular pain was observed. Examination of the left eye (OS) was unremarkable. A Schirmer tear test was 14 mm OD and 15 mm OS. Intraocular pressure, as measured by rebound tonometry (Tonovet; Icare), was 17 mmHg OU. Adnexal examination (OD) was unremarkable. Examination of the cornea confirmed the presence of a very small dark linear FB, located in the dorsotemporal quadrant of the cornea. Slit-lamp examination (KOWA SL-17; Kowa) revealed that the FB was embedded in the deep corneal stroma. A circumscribed circular white infiltrate surrounded by a very discreet focal corneal oedema was observed near the FB (Figure 1).

There was no reaction of the uveal tract observed on examination. The size of the pupil appeared normal and no inflammation of the iris was observed. Examination of the lens after pupillary dilation (three instillations at 5-min intervals; Tropicamide, Mydriaticum [Théa Pharma]) was normal. Fundus examination was unremarkable on indirect ophthalmoscopy (Omega 500 [Heine] and Volk 2.2, Panretinal lens [Mentor]). Fluorescein staining was negative OD, as was the Seidel test.

Although a corneal FB was identified, its precise nature could not be determined in a non-sedated patient. Considering the indoor lifestyle of the patient and the presence of ornamental houseplants, the suspected diagnosis was of a thorn or similar piece of plant material. However, other hypotheses such as metallic or plastic FBs could not be excluded at this stage.

Considering the high risk of migration of the FB into the anterior chamber (AC) and despite the recent improvement in ocular comfort, the removal of the FB was performed under general anaesthesia using a surgical microscope (OMS 600; TOPCON).



**Figure 2** Bee stinger observed under an optic microscope, with a sharp triangular shape and multiple barbs

The patient was positioned in dorsal recumbency. The eye surface was routinely prepared for corneal surgery with iodine 1% solution and draped. The cornea was incised above the FB with a 45° angled corneal knife. The keratotomy lips were gently retracted with Bohn forceps so as to reach the FB. The FB was firmly anchored to the corneal stroma, which resulted in several unsuccessful attempts at its extraction with a 30G needle. The contact between the needle and the FB pushed it to partially penetrate the AC. The keratotomy was then deepened with the same knife to reach the AC. Hyaluronate viscoelastic via a 10 o'clock limbal injection with a 25G needle was introduced to the AC. The FB was attached to the medial lip of the keratotomy and was gently removed by traction with Tano forceps. The keratotomy was then sutured with three interrupted sutures (polyglactin 9-0, Vicryl 9-0) after removal of the viscoelastic by flushing the AC with a balanced salt solution.

The FB was observed with an optic microscope for further analysis. Its shape was barbed, grossly triangular with a very thin and sharp tip, and it had eight barbs on one side. The appearance was characteristic of a bee stinger (Figure 2).

Postoperative treatment consisted of topical and systemic administration of antibiotics and steroids (Neomycin, Polymyxin B, Dexamethasone, Maxidrol [Alcon] q8h OD for 2 weeks; amoxicillin/clavulanate 12.5 mg/kg, Clavaseptin 62,5 [Vetoquinol] q12h PO for 10 days; Prednisolone 0.5 mg/kg [Dermipred; Ceva] q24h PO for 1 week, then every second day for the subsequent week) and topical administration of a mydriatic,

cycloplegic agent (Atropine 0.5% [Alcon] q8h OD on day 1, then q24h for 3 days).

Follow-up examination was performed 1 week post-operatively. A discreet corneal scar secondary to the penetrating keratotomy was observed. The patient was comfortable, with no signs of blepharospasm or photophobia. The iris was dilated because of the recent instillation of atropine and showed no signs of inflammation. Follow-up at 3 months revealed a complete healing of the corneal lesion.

## Discussion

Ocular surface FBs are uncommon in cats.<sup>7</sup> A recent report evaluated the epidemiological features of corneal and anterior segment FB trauma in dogs.<sup>8</sup> It revealed that young and working dogs were more exposed to ocular surface FBs. In the present case, the affected patient was a young cat that showed typical inquisitive playful behaviour. The most likely theory is a sting that would have occurred when the kitten tried to play with the bee.

In veterinary ophthalmology, FBs are often of vegetal nature.<sup>9</sup> The patient in this case was in contact with ornamental houseplants but had no access to the outdoor environment. The dark linear aspect of the FB raised our suspicion of a vegetal origin. Microscopic examination of the FB after surgical removal identified its actual nature. The appearance of the FB was characteristic of a worker bee stinger, with a sharp triangular shape, and multiple barbs allowing the stinger to be driven into a tissue in a forward direction only, like a harpoon or a fishing hook.<sup>10</sup> The stingers of other hymenopterans (wasps, hornets) are different and have a pointed and grossly conical appearance.<sup>10</sup> They are smooth and are more commonly used as a hunting tool. They allow insects to inject like a needle and allow subsequent retraction of the sting.<sup>10</sup>

To our knowledge, this is the first case describing a corneal bee sting in a cat. However, this lesion has been the subject of several reports in the human literature. The research of the keywords 'bee', 'sting' and 'cornea' in the PubMed Central database retrieved 24 publications since 2000 (19 single case reports and five case series, with a total number of 47 reported cases).

Corneal bee stings are rare in humans with infectious, toxic and immunological complications added to the mechanical damage caused by stinger penetration.<sup>11</sup> Ocular response to the stinger penetration varies from benign transient conjunctivitis, to corneal cell infiltrate, corneal ulcer, hypopyon, hyphema, iris atrophy, cataract, lens subluxation, optic neuritis, endophthalmitis and extraocular myositis.<sup>6,11–15</sup>

Two factors affect the severity of associated signs. The first is the presence of the venom sac, concurrently with the stinger; during the attack, the stinger penetrates into the target tissue and becomes anchored via the awns. When the hymenopteran leaves the site, the stinger remains in the tissue and a part of the insect's abdomen

is sometimes detached from its body with the venom sac.<sup>16</sup> Smooth muscles that surround the venom sac continue to contract and deliver venom for 30–60s.<sup>16,17</sup> When the stinger alone is present without the venom sac, detrimental effects are less severe.<sup>18</sup> These effects might be the consequence of the physical trauma itself and of the quantity of venom present in the stinger. In some patients, the stinger can become inert and remain in ocular structures (cornea, AC and lens) for weeks, months or years without associated ocular pathology.<sup>15,18</sup> However, when the venom sac adheres to the stinger and releases its content, the consequences are much more severe.<sup>11–15</sup> The venom of hymenopterans is composed of biological amines, low molecular weight peptides and enzymes (hyaluronidase, phospholipase A, lipase, acid and basic phosphatases, esterase and phosphodiesterase).<sup>15,19,20</sup> Bee venom also possesses melittin, a substance that provokes the disruption of phospholipid arrangement within the cell membranes, eventually leading to cellular lysis.<sup>15</sup> The leakage of cell compounds might be responsible for the chemotaxis of polymorphonuclear leukocytes, giving rise to the whitish appearance of the cornea described in most cases.<sup>15</sup> Ocular penetration of the venom provokes toxic and immune effects on the cornea, uvea, lens and posterior segment, and is responsible for the most severe clinical presentations.<sup>15</sup>

The second factor, which is much more difficult to assess, is the species of hymenopteran involved. There are many variations in the venom compounds among species.<sup>21</sup> These variations are probably associated with great variations in venom toxicity and, consequently, in the symptomatology of envenomed patients.<sup>15</sup>

In our patient, the stinger was found without the venom sac, probably explaining the absence of associated inflammatory manifestations. The small amount of venom remaining in the stinger, combined with its corneal penetration, probably caused the whitish lesion of localised cellular infiltrate. The presence of the barbs explains the difficulty extracting the FB from the cornea and its migration towards the AC.

In humans, there is no consensus on the appropriate treatment of corneal bee stings.<sup>11,22</sup> Some authors recommend leaving the stinger in place in the absence of the venom sac, believing that the chitinous exoskeleton is inert and unlikely to cause tissue inflammation if retained.<sup>18</sup> According to the same authors, the extraction of the FB could release even more venom, by the pressure exerted on the venom sac during gripping.<sup>18</sup> Finally, the extraction of a barbed stinger would be more likely to mechanically injure the cornea.

However, a retrospective study observed that the stinger is removed in 77% of cases.<sup>11</sup> Techniques used included needle extraction, forceps, endo-illumination guidance and different types of keratectomy, with varying degrees of success.<sup>11</sup> In the present case, the attempts to remove the stinger with a 30G needle were unsuccessful.

It would have probably been more effective to perform a deeper keratotomy in the region of the FB and to use Tano forceps straightaway. Regardless of the decision to remove the FB or not, follow-up is recommended over a long period of time to identify potential complications and manage them quickly.<sup>15,22</sup> In the present case, we could not identify the nature of the FB before its removal, so the presence or absence of the venom sac did not affect our decision to operate.

Inflammation associated with the presence of the FB was minor. The medical treatment prescribed following the removal of the FB was therefore focused on the septic risk and the pain and inflammation related to the surgical procedure. In humans, steroids, cycloplegics and antibiotics are widely used.<sup>22,23</sup>

## Conclusions

Among corneal FBs, hymenopteran stingers are rare. In the present case, the consequences seemed minor for the patient, probably owing to the absence of the venom sac. According to the literature, the associated lesions could have been much more serious. Consequently, in addition to the removal of the FB, regular follow-up is advised in order to manage potential corneal, uveal or retinal complications.

**Conflict of interest** The authors declared no potential conflicts of interest with respect to the research, authorship, and/or publication of this article.

**Funding** The authors received no financial support for the research, authorship, and/or publication of this article.

**Ethical approval** This work involved the use of non-experimental animals only (including owned or unowned animals and data from prospective or retrospective studies). Established internationally recognised high standards ('best practice') of individual veterinary clinical patient care were followed. Ethical approval from a committee was therefore not necessarily required.

**Informed consent** Informed consent (either verbal or written) was obtained from the owner or legal custodian of all animal(s) described in this work (either experimental or non-experimental animals) for the procedure(s) undertaken (either prospective or retrospective studies). For any animals or humans individually identifiable within this publication, informed consent (either verbal or written) for their use in the publication was obtained from the people involved.

**ORCID iD** Thomas Dulaurent  <https://orcid.org/0000-0002-1005-0154>

## References

- Belknap EB. **Corneal emergencies.** *Top Comp Anim Med* 2015; 30: 74–80.
- Brennan KE and Ihrke PJ. **Grass awn migration in dogs and cats: a retrospective study of 182 cases.** *J Am Vet Med Assoc* 1983; 182: 1201–1204.
- Foley RH. **Herbaceous ocular foreign body in a cat.** *Vet Med Small Anim Clin* 1977; 72: 38–39.
- Delgado E. **Endophthalmitis due to an intra-ocular linear foreign body in a cat.** *J Feline Med Surg Open Rep* 2015; 1: 2055116915585018.
- Robat C, Bemelmans I and Marescaux L. **Retrolbulbar lymphoma associated with a ballistic foreign body in a cat.** *J Small Anim Pract* 2016; 57: 217–219.
- Gudiseva H, Uddaraju M, Pradhan S, et al. **Ocular manifestations of isolated corneal bee sting injury, management strategies, and clinical outcomes.** *Indian J Ophthalmol* 2018; 66: 262–268.
- Stiles J. **Feline ophthalmology.** In: Gelatt KN, Gilger CG and Kern TJ (eds). *Veterinary ophthalmology*. 5th edn. Ames, IA: Wiley-Blackwell, 2013, pp 1477–1559.
- Tetas Pont R, Matas Riera M, Newton R, et al. **Corneal and anterior segment foreign body trauma in dogs: a review of 218 cases.** *Vet Ophthalmol* 2016; 19: 386–397.
- Ledbetter EC and Gilger BC. **Diseases and surgery of the canine cornea and sclera.** In: Gelatt KN, Gilger CG and Kern TJ (eds). *Veterinary ophthalmology*. 5th ed. Ames, IA: Wiley-Blackwell, 2013, pp 976–1049.
- Zhao Z-L, Zhao H-P, Ma G-J, et al. **Structures, properties, and functions of the stings of honey bees and paper wasps: a comparative study.** *Biol Open* 2015; 4: 921–928.
- Rai RR, Gonzalez-Gonzalez LA, Papakostas TD, et al. **Management of corneal bee sting injuries.** *Semin Ophthalmol* 2017; 32: 177–181.
- Chuah G, Law E, Chan WK, et al. **Case reports and mini review of bee stings of the cornea.** *Singapore Med J* 1996; 37: 389–391.
- Siddharthan KS, Raghavan A and Revathi R. **Clinical features and management of ocular lesions after stings by hymenopteran insects.** *Indian J Ophthalmol* 2014; 62: 248–251.
- Lin PH, Wang NK, Hwang YS, et al. **Bee sting of the cornea and conjunctiva: management and outcomes.** *Cornea* 2011; 30: 392–394.
- Arcieri ES, França ET, de Oliveria HB, et al. **Ocular lesions arising after stings by hymenopteran insects.** *Cornea* 2002; 21: 328–330.
- Aggrawal A. *Textbook of forensic medicine and toxicology*. New Delhi: Avichal Publishing, 2014.
- Ellenhorn MJ and Barceloux DG. *Medical toxicology: diagnosis and treatment of human poisoning*. New York: Elsevier, 1988.
- Gilboa M, Gdal-On M and Zonis S. **Bee and wasp stings of the eye. Retained intralenticular wasp sting: a case report.** *Br J Ophthalmol* 1977; 61: 662–664.
- Sobotka AK, Franklin RM, Adkinson NF, Jr, et al. **Allergy to insect stings. II. Phospholipase A: the major allergen in honeybee venom.** *J Allergy Clin Immunol* 1976; 57: 29–40.
- Hoffman DR, Shipman WH and Babin D. **Allergens in bee venom II. Two new high molecular weight allergenic specificities.** *J Allergy Clin Immunol* 1977; 59: 147–153.
- Schmidt JO, Blum MS and Overal WL. **Comparative enzymology of venoms from stinging Hymenoptera.** *Toxicon* 1986; 24: 907–921.
- Roomizadeh P, Razmjoo H, Abtahi MA, et al. **Management of corneal bee sting: Is surgical removal of a retained stinger always indicated?** *Int Ophthalmol* 2013; 33: 1–2.
- Razmjoo H, Abtahi MA, Roomizadeh P, et al. **Management of corneal bee sting.** *Clin Ophthalmol* 2011; 5: 1697–1700.