




Traumatic rib head subluxation through the intervertebral foramen causing spinal cord contusive injury in a cat

Authors: Lisiewicz, Natalie, Green, Matthew, Targett, Mike, and Lowrie, Mark

Source: Journal of Feline Medicine and Surgery Open Reports, 6(1)

Published By: SAGE Publishing

URL: <https://doi.org/10.1177/2055116920929260>



Traumatic rib head subluxation through the intervertebral foramen causing spinal cord contusive injury in a cat

Journal of Feline Medicine and Surgery Open Reports
1–4

© The Author(s) 2020

Article reuse guidelines:

sagepub.com/journals-permissions

DOI: 10.1177/2055116920929260

journals.sagepub.com/home/jfmsopenreports

This paper was handled and processed by the European Editorial Office (ISFM) for publication in *JFMS Open Reports*



Natalie Lisiewicz¹, Matthew Green¹, Mike Targett² and Mark Lowrie¹

Abstract

Case summary A 4-year-old cat involved in a road traffic accident presented with paraparesis, which was worse on the right-hand side. Neurolocalisation was to the T3–L3 spinal cord segments. Survey radiographs showed rib fractures but no definitive diagnosis for the paraparesis. CT revealed fracture of the dorsal rim and a T9 rib subluxation through the intervertebral foramen at T8–T9. This caused a contusive spinal injury. Treatment consisted of rest and analgesia. The cat recovered well, with the owner reporting no abnormalities 5 months following the injury.

Relevance and novel information Road traffic accidents are a common cause of injury in the cat population, with a significant number having thoracic injuries. These include rib injuries such as fractures. This is the first reported case of a traumatic rib subluxation causing a contusive injury in the spinal cord of any species. Previously reported rib subluxations have been seen in humans with spinal deformities. Conservative management in this case was sufficient.

Keywords: Traffic collisions; computed tomography; CT; injuries; spinal cord; dislocation; luxation; vehicular; traffic crashes; x-ray

Accepted: 28 April 2020

Case description

A 4-year-old domestic shorthair cat was referred for investigation of paraplegia 48h following a suspected road traffic accident. The cat had been initially stabilised with analgesia and fluid therapy at the referring veterinary surgery. No abnormalities had been detected at the referring veterinary surgery on survey spinal radiography (Figure 1). During the initial stabilisation period there was reported improvement from paraplegia to non-ambulatory paraparesis.

The cat presented with a non-ambulatory paraparesis with moderate movement of the left pelvic limb and minimal movement of the right pelvic limb. Conscious sensation and segmental spinal reflexes were retained, consistent with an upper motor neuron lesion localised to T3–L3 spinal cord segments. No pain was elicited on palpation of the vertebral column, although methadone

had been administered 2h prior to examination. No other neurological deficits were demonstrated. Clinical examination was otherwise within normal limits, with no evidence of thoracic or abdominal pathology

Differential diagnoses included non-displaced spinal fracture or luxation, or traumatic disc extrusion. Advanced imaging, including CT and MRI, were performed.

¹Dovecote Veterinary Hospital, Derby, UK

²School of Veterinary Medicine and Science, University of Nottingham, Sutton Bonington, UK

Corresponding author:

Mark Lowrie MA, VetMB, MVM, DipECVN, MRCVS, RCVS
Specialist in Veterinary Neurology and EBVS, Dovecote Veterinary Hospital, 5 Delven Lane, Castle Donington, Derby DE74 2LJ, UK
Email: mark.lowrie@dovecoteveterinaryhospital.co.uk



Creative Commons Non Commercial CC BY-NC: This article is distributed under the terms of the Creative Commons

Attribution-NonCommercial 4.0 License (<https://creativecommons.org/licenses/by-nc/4.0/>) which permits non-commercial use, reproduction and distribution of the work without further permission provided the original work is attributed as specified on the SAGE and Open Access pages (<https://us.sagepub.com/en-us/nam/open-access-at-sage>).

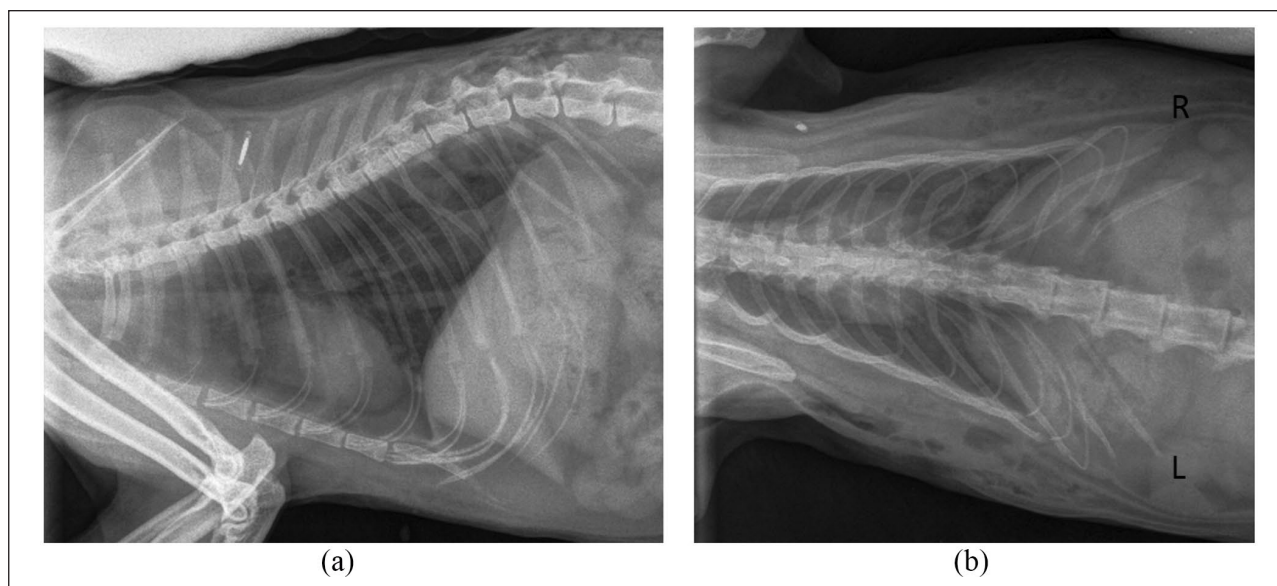


Figure 1 (a) Right lateral thoracic radiograph and (b) dorsoventral view of thorax. Both images were taken conscious with sandbags as restraints

CT of the vertebral column revealed fracture of the right T9 and T12 ribs in the dorsal third region (Figure 2). There was luxation of the T9 rib head, which appeared to be located within the T8–T9 intervertebral foramen. The dorsal rim of the T8–T9 foramen was fractured. On MRI there was a focal region of intraparenchymal T2 hyperintensity within the spinal cord adjacent to the rib head that was consistent with contusion. The rib head was located within the extradural space and creating some deviation of the spinal cord to the left with loss of the T2 hyperintense signal that normally surrounds the spinal cord. Although there was some reduction in dimension of the vertebral canal on transverse CT and MRI, there was no significant ongoing compression of the spinal cord demonstrated.

The diagnosis from the advanced imaging was of a focal contusive spinal cord lesion secondary to trauma from the luxated T9 rib head passing through the T8–T9 intervertebral foramen.

Although a surgical approach to remove the T9 rib head from the intervertebral foramen was discussed with the owner, owing to the absence of ongoing spinal cord compression and the improving neurological status, conservative management was initially pursued. The cat was hospitalised with buprenorphine and meloxicam analgesia on day 1, this was then reduced to meloxicam only. Potential urinary incontinence was managed by careful monitoring and gentle palpation of the bladder every 4h to see if manual expression was required. By the second day of hospitalisation urination continued after only minimal manual pressure. The cat was also monitored for its ability to defaecate, although the neurolocalisation

was cranial to the nerves innervating the anal sphincter and anal tone was present, suggesting problems would be less likely to develop.

After 3 days of hospitalisation the neurological status had further improved and the cat displayed greater movement of the right pelvic limb but remained non-ambulatory. It was now urinating spontaneously without the need for external bladder pressure. The cat was discharged with instructions to crate rest for a further 4 weeks before a gradual reintroduction to normal exercise. The meloxicam was continued for 5 days only as the cat did not appear to be in any further pain since the accident.

Six weeks following initial presentation, the cat was re-examined at the referral practice. The owner reported good improvement with return to ambulation, including an ability to jump up onto low surfaces. On neurological examination the cat was ambulatory paraparetic with good movement of both pelvic limbs with a moderate general proprioceptive ataxia. Five months later, the owners report that the cat has no discernible abnormality to its movement.

Discussion

Spinal cord injury secondary to rib head luxation through the intervertebral foramen has been reported sporadically in humans,^{1–7} where it has often been linked to an ongoing medical condition such as scoliosis or neurofibromatosis rather than isolated traumatic injury. In the majority of these cases,^{1–5,7} there was evidence of spinal cord compression on advanced imaging and all reported human cases underwent surgical management with rib resection.

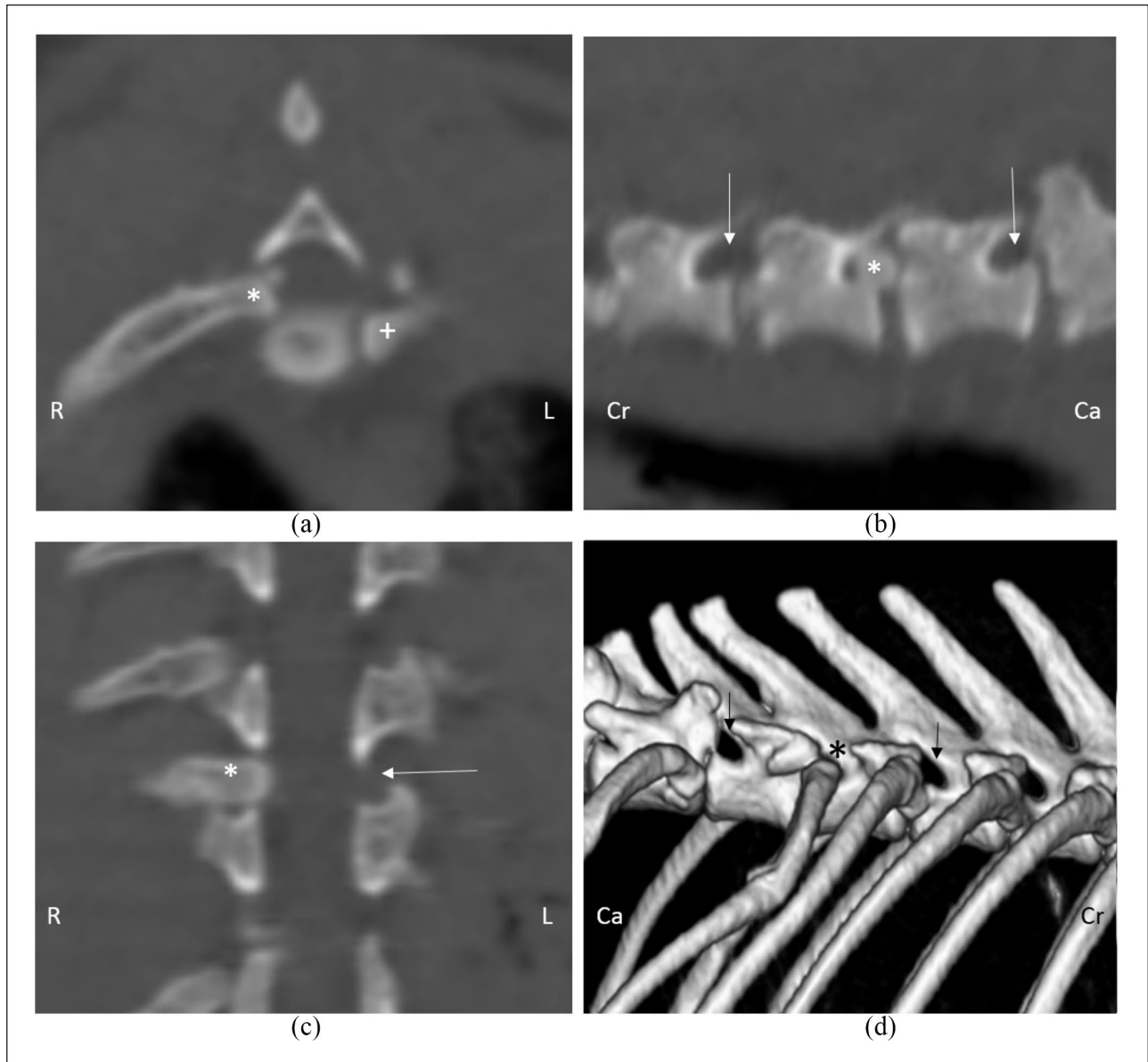


Figure 2 CT images of the affected rib head. Asterisks indicate the affected rib; arrows indicate normal foramina. (a) Axial view (plus sign indicates the normal position of the left rib), (b) sagittal view, (c) coronal view and (d) three dimensional reconstruction. R = right; L = left; Cr = cranial; Ca = caudal

Rib head intrusion through the intervertebral foramen in cats has never been reported, despite rib injuries being a significant consequence of traumatic injury.⁸ Measurement on the CT images in this case demonstrated the left and right rib heads to have a maximal diameter of 3.4mm, while the contralateral left foramen had a maximal diameter of 2.0mm. The fractured rim of the right gave a maximal diameter of 3.6mm, which had allowed penetration of the rib head into the vertebral canal. This suggests that the spinal cord concussive injury in this case was only facilitated by the fracture of the foraminal rim.

Human patients with neurofibromatosis dystrophic deformities exhibit varying degrees of lordosis and kyphosis with altered anatomy of the intervertebral

vertebral foramen. The foramen at the apex of a kyphotic curve may be larger than normal and if larger than the adjacent rib head predispose to impaction of the rib head within the vertebral canal. No fracture of the lamina has been reported associated previous human cases.

Spinal cord malformation with thoracic kyphosis is a common finding in brachycephalic breeds of dogs,^{9,10} which are becoming increasingly popular in the UK,^{11,12} and it will be interesting to see if this is associated with future identification of rib impaction into intervertebral foramen.

Glucocorticoids were not considered appropriate in this cat because the neurological status was already improving and analgesia was considered more appropriate in the

form of non-steroidal anti-inflammatory medication. Theoretically, glucocorticoids may have benefit in reducing vasogenic oedema associated with spinal cord contusion, they do not improve cytotoxic oedema. They are also associated with adverse side effects. Given that spinal cord contusion does not require treatment and side effects are a complication,^{13,14} glucocorticoids were not administered in this cat.

This case appears to present an interesting complication of traumatic rib luxation, which is normally prevented by the relative size of the rib head and the intervertebral foramen and only facilitated in this case by an associated fracture. Previous human cases have required spinal cord decompression due to the ongoing compression, while this case responded well to conservative therapy. Concussive spinal cord injury in cats might be expected to respond well to conservative therapy, as predicted from both classical experimental studies^{15,16} and previously reported non-compressive cases of intervertebral disc disease.¹⁷

Conclusions

Impaction of a luxated rib head through the intervertebral foramen is usually prevented by the relative dimensions of the structures. In cases such as this where there is associated fracture of the structures around the foramen and in animals with kyphotic thoracic spinal malformation, spinal cord trauma from rib head impaction through the foramen may need to be considered.

Acknowledgements We thank Sergio Gomes DVM, MRCVS for his help with the discussion and images.

Conflicts of interest The authors declared no potential conflicts of interest with respect to the research, authorship, and/or publication of this article.

Funding The authors received no financial support for the research, authorship, and/or publication of this article.

Ethical approval This work involved the use of non-experimental animals only. Established internationally recognised high standards ('best practice') of individual veterinary clinical patient care were followed. Ethical approval from a committee was therefore not necessarily required.

Informed consent Informed consent was obtained from the owner or legal custodian of all animal(s) described in this work for the procedure(s) undertaken. For any animals or humans individually identifiable within this publication, informed consent (either verbal or written) for their use in the publication was obtained from the people involved.

ORCID iD Mark Lowrie  <https://orcid.org/0000-0002-4993-589X>

References

- Cappella M, Bettini N, Dema E, et al. **Late post-operative paraparesis after rib penetration of the spinal canal in a patient with neurofibromatous scoliosis.** *J Orthop Traumatol* 2008; 9: 163–166.
- Mukhtar IA, Letts M and Kontio K. **Spinal cord impingement by a displaced rib in scoliosis due to neurofibromatosis.** *Can J Surg* 2005; 48: 414–415.
- Kamath SV, Kleinman PK, Ragland RL, et al. **Intraspinous dislocation of the rib in neurofibromatosis: a case report.** *Pediatr Radiol* 1995; 25: 538–539.
- Khoshhal KI and Ellis RD. **Paraparesis after posterior spinal fusion in neurofibromatosis secondary to rib displacement: case report and literature review.** *J Pediatr Orthop* 2000; 20: 799–801.
- Legrand B, Filipe G, Blamoutier A, et al. **Intraspinous rib penetration in four patients in neurofibromatosis vertebral deformities.** *Rev Chir Orthop Reparatrice Appar Mot* 2003; 89: 57–61.
- Dacher JN, Zakine S, Monroc M, et al. **Rib displacement threatening the spinal cord in a scoliotic child with neurofibromatosis.** *Pediatr Radiol* 1995; 25: 58–59.
- Deguchi M, Kawakami N, Saito H, et al. **Paraparesis after rib penetration of the spinal canal in neurofibromatous scoliosis.** *J Spinal Disord* 1995; 8: 363–367.
- Intarapanich NP, McCobb EC, Reisman RW, et al. **Characterization and comparison of injuries caused by accidental and non-accidental blunt force trauma in dogs and cats.** *J Forensic Sci* 2016; 61: 993–999.
- Guevar J, Penderis J, Faller K, et al. **Computer-assisted radiographic calculation of spinal curvature in brachycephalic "screw-tailed" dog breeds with congenital thoracic vertebral malformations: reliability and clinical evaluation.** *PLoS One* 2014; 9: e106957. DOI: 10.1371/journal.pone.0106957.
- Ryan R, Gutierrez-Quintana R, Ter Haar G, et al. **Prevalence of thoracic vertebral malformations in French Bulldogs, Pugs and English Bulldogs with and without associated neurological deficits.** *Vet J* 2017; 221: 25–29.
- Kennel Club. **French Bulldogs overtake Labradors as UK's most popular dog breed.** <https://www.thekennelclub.org.uk/press-releases/2018/june/french-bulldogs-overtake-labradors-as-uks-most-popular-dog-breed/> (2018, accessed March 12, 2020).
- Packer RMA, Murphy D and Farnworth MJ. **Purchasing popular purebreds: investigating the influence of breed-type on the pre-purchase motivations and behaviour of dog owners.** *Anim Welfare* 2017; 26: 191–201.
- Gopal MS and Jeffery ND. **Magnetic resonance imaging in the diagnosis and treatment of a canine spinal cord injury.** *J Small Anim Pract* 2001; 42: 29–31.
- Jeffery ND. **Corticosteroid use in small animal neurology.** *Vet Clin North Am Small Anim Pract* 2014; 44: 1059–1074.
- Ford RWJ. **A reproducible spinal cord injury model in the cat.** *J Neurosurg* 1983; 59: 268–275.
- Dohrmann GJ. **Experimental spinal cord trauma. A historical review.** *Arch Neurol* 1972; 27: 468–473.
- Newitt A, German AJ and Barr FJ. **Congenital abnormalities of the feline vertebral column.** *Vet Radiol Ultrasound* 2008; 49: 35–41.