



---

## **Photodynamic detection of a feline meningioma using 5-aminolaevulinic acid hydrochloride**

Authors: Osaki, Tomohiro, Gonda, Kengo, Murahata, Yusuke, Sunden, Yuji, Amaha, Takao, et al.

Source: Journal of Feline Medicine and Surgery Open Reports, 6(1)

Published By: SAGE Publishing

URL: <https://doi.org/10.1177/2055116920907429>



# Photodynamic detection of a feline meningioma using 5-aminolaevulinic acid hydrochloride

*Journal of Feline Medicine and Surgery Open Reports*  
1–5

© The Author(s) 2020

Article reuse guidelines:


sagepub.com/journals-permissions

DOI: 10.1177/2055116920907429

journals.sagepub.com/home/jfmsopenreports

This paper was handled and processed by the European Editorial Office (ISFM) for publication in *JFMS Open Reports*



Tomohiro Osaki<sup>1</sup> , Kengo Gonda<sup>1</sup>, Yusuke Murahata<sup>1</sup>, Yuji Sunden<sup>1</sup>, Takao Amaha<sup>1</sup>, Narumi Kunisue<sup>2</sup>, Kiwamu Takahashi<sup>2</sup>, Masahiro Ishizuka<sup>2</sup>, Tohru Tanaka<sup>2</sup>, Liming Li<sup>3</sup>, Inoru Yokoe<sup>1</sup>, Masamichi Yamashita<sup>1</sup>, Kazuo Azuma<sup>1</sup>, Takeshi Tsuka<sup>1</sup>, Norihiko Ito<sup>1</sup>, Tomohiro Imagawa<sup>1</sup> and Yoshiharu Okamoto<sup>1</sup>

## Abstract

**Case summary** The present study describes the case of a feline meningioma that was detected using 5-aminolaevulinic acid hydrochloride (5-ALA)-induced protoporphyrin IX (PpIX) fluorescence at surgery. An extra-axial mass in the temporoparietal region was observed by MRI. Following craniectomy and durotomy, photodynamic detection (PDD) was performed for detection of the tumour. Intratumour PpIX was detected using fluorescence spectrum evaluation and high-performance liquid chromatography. PDD revealed bright fluorescence of PpIX induced by 5-ALA, facilitating fluorescence-guided resection of the tumour tissue. Postoperative examination demonstrated an intratumour PpIX protein concentration of 16.8 nmol/g, and based on histopathological findings we diagnosed the mass as meningioma.

**Relevance and novel information** PDD using 5-ALA has been used to identify the surgical margins during resection of primary human brain tumours. Recently, we have reported post-mortem PDD using 5-ALA for a canine glioblastoma. To our knowledge, this technique has not been previously used for the detection and resection of feline brain tumours. Our findings suggest that PDD using 5-ALA is useful for intraoperative fluorescence-guided resection of malignant meningioma in cats.

**Keywords:** 5-Aminolaevulinic acid hydrochloride; meningioma; photodynamic detection; protoporphyrin IX

**Accepted:** 27 January 2020

## Introduction

Meningioma is the most common primary brain tumour in cats.<sup>1</sup> Meningiomas in cats are often fibrotic and usually do not infiltrate the surrounding normal tissues.<sup>2,3</sup> Therefore, surgery is considered the first-line therapy for feline solitary meningiomas.<sup>3</sup> However, it has been reported that recurrence of meningiomas after surgical excision in cats is about 22%.<sup>4</sup> One of the most important reasons for the recurrence of intracranial meningiomas is considered to be residual tumour tissue following resection.<sup>5</sup> To minimise the recurrence of intracranial meningiomas, many methods are used to distinguish the border of the malignant brain tumour from

the surrounding normal nervous tissue.<sup>6</sup> In human medicine, intraoperative visualisation of meningioma tissue

<sup>1</sup>Joint Department of Veterinary Medicine, Faculty of Agriculture, Tottori University, Tottori, Japan

<sup>2</sup>SBI Pharmaceuticals, Tokyo, Japan

<sup>3</sup>Department of Bio- and Material Photonics, Chitose Institute of Science and Technology, Chitose, Hokkaido, Japan

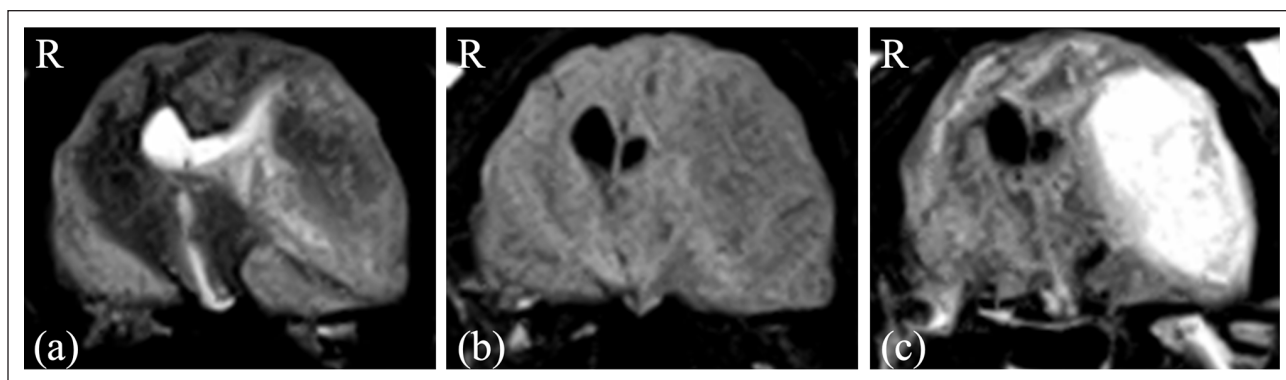
### Corresponding author:

Tomohiro Osaki DVM, PhD, Joint Department of Veterinary Medicine, Faculty of Agriculture, Tottori University, 4-101 Koyama-Minami, Tottori, 680-8553, Japan  
Email: [tosaki@muses.tottori-u.ac.jp](mailto:tosaki@muses.tottori-u.ac.jp)



Creative Commons Non Commercial CC BY-NC: This article is distributed under the terms of the Creative Commons

Attribution-NonCommercial 4.0 License (<https://creativecommons.org/licenses/by-nc/4.0/>) which permits non-commercial use, reproduction and distribution of the work without further permission provided the original work is attributed as specified on the SAGE and Open Access pages (<https://us.sagepub.com/en-us/nam/open-access-at-sage>).



**Figure 1** MRI of the brain. (a) Transverse T2-weighted image (WI) transverse MRI; (b) transverse T1-weighted image (T1WI) precontrast; and (c) transverse T1WI postcontrast

by means of protoporphyrin IX (PpIX) fluorescence, induced by 5-aminolaevulinic acid hydrochloride (5-ALA), has been investigated.<sup>5-7</sup> 5-ALA is a precursor of the well-known photosensitiser PpIX, to which it is converted in situ via the haem biosynthetic pathway.<sup>8</sup> 5-ALA has been successfully used for photodynamic detection (PDD) and photodynamic therapy (PDT) in various cancers.<sup>9,10</sup> Recently, we have reported post-mortem PDD of a canine glioblastoma using 5-ALA.<sup>11</sup>

To our knowledge, however, no reports have been published on fluorescence-guided resection (FGR) of brain tumours by means of 5-ALA in veterinary medicine. Here, we present the first case of a feline meningioma that was intraoperatively detected by fluorescence induced by orally administered 5-ALA. Furthermore, we show accumulation of PpIX in feline meningioma tumour tissue, therefore demonstrating that this technique is a powerful tool for the successful removal of tumour tissue.

### Case description

A 15-year-old neutered female domestic shorthair cat (2.9 kg body weight) was referred to Tottori University Animal Medical Centre with a 2-month history of depression and anticlockwise circling behaviour. Examination of complete blood count, blood biochemistry and thoracic radiographs did not show any abnormalities. Neurological examination revealed a dull mentation and confirmed the circling behaviour with slight generalised ataxia. Proprioception was slightly decreased on thoracic limbs and there was no menace response of the right eye by cranial nerve examination. Other cranial nerves and spinal reflexes were normal. Written informed consent was obtained from the owner, and ethical approval for the use of the animal in the current study was obtained from the Ethics Committee at the Faculty of Agriculture, Tottori University (ethical approval number: H28-003).

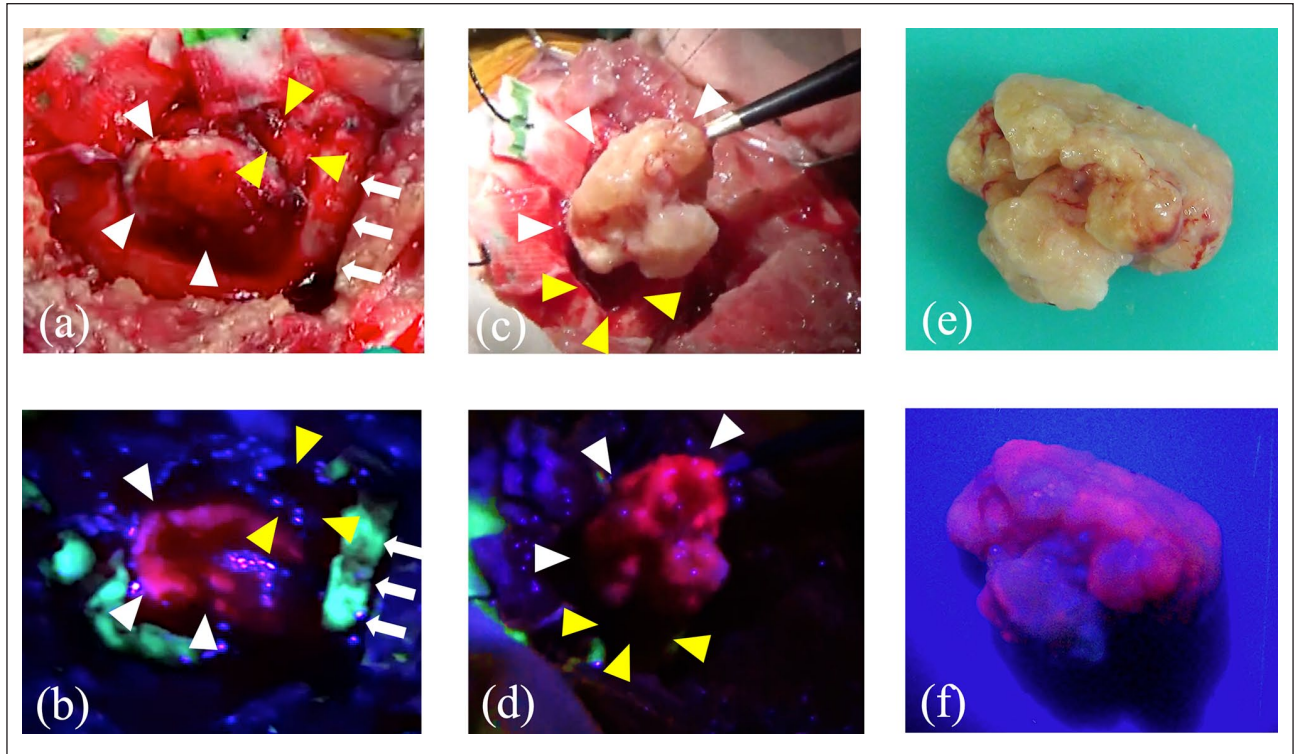
MRI was performed using a 0.3T permanent magnet MRI unit (AIRIS Vento; Hitachi) under combined

sedation. Gadopentetate dimeglumine (Magnevist; Bayer Yakuhin) was administered intravenously (IV) at 0.1 mmol/kg for contrast enhancement effects. MRI revealed an extra-axial mass in the temporoparietal region. The mass was ovoid with a regular, distinct margin, and it presented as iso- to hyperintense heterogeneous signal in the brain parenchyma on transverse T2-weighted images (T2WI), and hypointense, homogeneous signal in the brain parenchyma on transverse T1-weighted images (T1WI) (Figure 1a,b). Postcontrast T1WI indicated that the mass, measuring  $1.3 \times 1.5 \times 2.5$  cm, was homogenous (Figure 1c) and compressed the left lateral ventricle and thalamus. In addition, a peritumoural oedema was observed, altogether leading to a preliminary diagnosis of left-sided temporal meningioma.

As treatment with prednisolone (Takeda Pharmaceutical) at 2 mg/kg (body weight) PO q24h (to control the vasogenic tumour-induced oedema) only slightly improved the clinical signs, left temporal craniectomy was performed.

Oral administration of 5-ALA at a dose of 40 mg/kg was performed 4 h before surgery. Preoperatively, mannitol (20% mannitol 'YD'; Yoshindo), at 1 g/kg IV for 20 mins, and prednisolone (prednisolone injection solution 'KS'; Kyoritsu Seiyaku), at 2 mg/kg SC were administered. Anaesthesia was maintained using end-tidal isoflurane (Isoflo; DS Pharma Animal Health) at 0.7–1.0% and oxygen with mechanical hyperventilation. Intraoperative analgesia was provided using remifentanyl hydrochloride (remifentanyl for IV injection 2 mg 'Daiichi Sankyo'; Daiichi Sankyo) at 20 µg/kg/h constant rate infusion (CRI) and medetomidine hydrochloride at 1 µg/kg/h CRI.

Craniectomy was performed using SonoCure with bone tip (Tokyo Iken). Following craniectomy and durotomy under surgical microscope (Leica F50; Leica Microsystems), PDD for the detected tumour was performed. The fluorescence was observed using an LED light source at 405 nm. The video camera (HDR-CX180; SONY) was equipped with a long-pass filter designed to block blue light (for



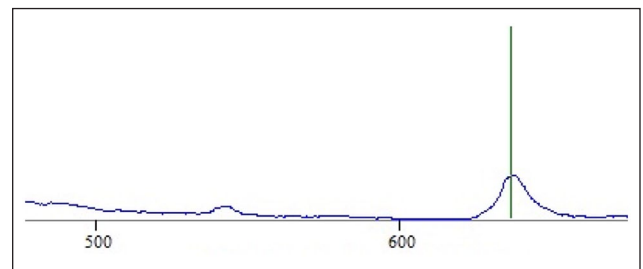
**Figure 2** Conventional white light and corresponding protoporphyrin IX fluorescence images. (a,b) Intraoperative images of the brain surface after craniotomy. (c,d) Intraoperative photograph at the moment of removal of the mass. (e,f) The resected mass. (a,c,e) White images; (b,d,f) fluorescence images. White arrows show the skull. White arrowheads show meningioma. Yellow arrowheads show the normal brain

observation of fluorescence). Visual analysis revealed bright red fluorescence of PpIX induced by 5-ALA (Figure 2). Most of the tumour was resected using PDD as needed.

The cat was kept in an oxygen kennel for 24h after surgery. Postoperative analgesia was provided using remifentanyl hydrochloride at 6–10 µg/kg/h CRI and medetomidine hydrochloride at 1 µg/kg/h CRI for the initial 24h, and thereafter with buprenorphine hydrochloride (Lepetan injection 0.2mg; Otsuka Pharmaceutical) at 20 µg/kg IV q8h. Lactated Ringer's solution was administered at 2–3 ml/kg/h for 48h. Neurological examination was normal at 3 days after surgery.

For fluorescence spectrometry, LED405-SMA-TI, R600-8-UV-VIS-SR and Black-Comet CXR-50 TEC spectrometers (StellarNet) were used to obtain the spectra for visualising the resected tumour tissue. A peak of PpIX was observed at 635nm, and the ratio of autofluorescence (505nm) to PpIX fluorescence (635nm) was 4.26 (Figure 3).

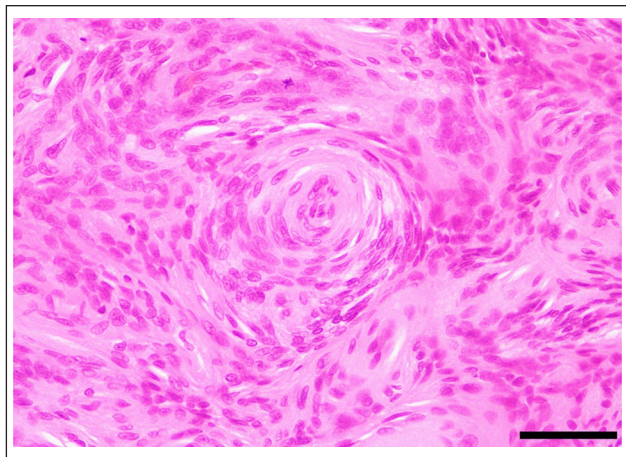
For determination of intratumour PpIX concentration, the tumour tissue was lysed by sonication for 30s, and 0.2ml of the homogenate was vigorously agitated for 60s with 0.02ml of 50% v/v acetic acid and 0.9ml of N,N-dimethylformamide-2-propanol solution (100:1 by volume) and centrifuged at 13,150 × g for 5mins at 4°C



**Figure 3** Fluorescence spectrum. The ratio of autofluorescence (505 nm) to protoporphyrin IX fluorescence (635 nm) was 4.26

to collect the supernatant. This was analysed by high-performance liquid chromatography (HPLC) using a Capcell Pak C18 UG120 column (5 µm, 4.6 × 150 mm; Shiseido), mobile phase of acetonitrile-10 mM tetrabutylammonium hydroxide solution (pH 7.5) (70:30 by volume; flow rate, 1.0 ml/min; elution temperature, 40°C) and fluorescence detector (excitation 400 nm, emission 630 nm), as described previously.<sup>12</sup> The intratumour PpIX protein concentration was 16.8 nmol/g.

For histopathological examination, sample pieces of surgically removed tissue and the cranial bone were



**Figure 4** Histopathological image of the mass. Histopathological examination (haematoxylin and eosin staining) of the resected mass revealed neoplastic proliferation of spindle eosinophilic cells resembling meningeal epithelium and/or fibroblastic cells, and which were frequently arranged in concentric patterns with occasional calcification at the centre (psammoma body); scale bar = 50  $\mu$ m

formalin-fixed and submitted for histopathology. The specimens were routinely processed for paraffin embedding, sliced and stained using haematoxylin and eosin. Histopathological examination of the removed tumour tissue by haematoxylin and eosin staining showed neoplastic proliferation of spindle eosinophilic cells, which resembled meningeal epithelium and/or fibroblastic cells (Figure 4). These cells were frequently arranged in concentric patterns with occasional calcification at the centre, also referred to as psammoma bodies. Even though the neoplastic cells were found in high densities, nuclear atypia was not evident and mitotic figures were rarely seen. Further, cholesterol depositions, small foci of necrosis and haemorrhage were observed within the mass. Based on these findings, our histopathological diagnosis of the mass as meningioma was confirmed. In addition, neither significant histopathological changes nor neoplastic cells were found within the cranial bone.

## Discussion

Surgery is considered the first line of therapy for feline solitary meningioma.<sup>3</sup> It was reported that surgery alone provided survival rates of 71% at 6 months, 66% at 1 year and 50% at 2 years post-procedure.<sup>13</sup> However, canine meningioma tends to infiltrate the brain parenchyma and cannot be demarcated from the normal brain tissue; the survival in dogs treated by conventional surgery alone is 7 months.<sup>14</sup> In the present study, 5-ALA-induced fluorescence was intraoperatively visualised on the surface of the tumour. It was reported that PDD using 5-ALA enables more complete resection of brain tumours, leading to improved progression-free survival

in patients with malignant glioma.<sup>15</sup> However, false-negative PDD using 5-ALA has been reported. If there were some normal tissues or blood over the tumours, PDD using 5-ALA would not have been able to detect these tumours. Also, emission light for PDD was unable to reach into the deep meningioma resection areas, because these areas were shaded by the skull or the normal brain tissues.<sup>16</sup>

In human medicine, attempts have been made to quantify the amount of PpIX for different grades of gliomas. It was reported that the amount of PpIX in glioblastoma was approximately 1000 ng/g wet brain. The amount of intracellular PpIX was reported to be correlated with the malignancy.<sup>6</sup> In human medicine, it was reported that PpIX fluorescence of meningioma was seen in 31–100% of patients who underwent this procedure.<sup>17–19</sup> PpIX accumulation via oral administration of 5-ALA is applied not only for FGR, but also for interstitial photodynamic therapy (iPDT), and a clinical trial of iPDT for human brain tumours has already been initiated.<sup>20</sup> Based on our findings of successful PpIX accumulation by means of 5-ALA in this study and our confirmation that this method facilitates detection and resection of tumour tissue, the development of iPDT for unresectable feline meningioma is expected in the future.

## Conclusions

To our knowledge, we have demonstrated for the first time an accumulation of PpIX in feline meningioma tumour tissue using fluorescence spectrometry and HPLC. Therefore, in the future, intraoperative FGR might help to reduce the risk of recurrence and improve survival in cats with intracranial meningioma. However, in order to confirm our findings and provide supporting evidence for the usefulness of this method, further studies on larger numbers of cats and dogs will be needed. When performing PDD using 5-ALA, the surgeon must know about the possibility of the photobleaching effect, and the false-positive and the false-negative PDD.

**Conflict of interest** Narumi Kunisue, Kiwamu Takahashi, Masahiro Ishizuka, and Tohru Tanaka are employees of SBI Pharmaceuticals.

**Funding** This study was partly funded by SBI Pharmaceuticals, Tokyo, Japan.

**Ethical approval** This work involved the use of non-experimental animals (owned or unowned) and procedures that differed from established internationally recognised high standards ('best practice') of veterinary clinical care for the individual patient. The study therefore had ethical approval from an established committee as stated in the manuscript.

**Informed consent** Informed consent (either verbal or written) was obtained from the owner or legal custodian of

all animal(s) described in this work (either experimental or non-experimental animals) for the procedure(s) undertaken (either prospective or retrospective studies). For any animals or humans individually identifiable within this publication, informed consent (either verbal or written) for their use in the publication was obtained from the people involved.

**ORCID iD** Tomohiro Osaki  <https://orcid.org/0000-0002-2689-9435>

## References

- 1 Troxel MT, Vite CH, Van Winkle TJ, et al. **Feline intracranial neoplasia: retrospective review of 160 cases (1985–2001).** *J Vet Intern Med* 2003; 17: 850–859.
- 2 Adamo PF, Forrest LJ and Dubielzig RR. **Canine and feline meningiomas: diagnosis, treatment, and prognosis.** *Compendium* 2004; 26: 951–966.
- 3 Horta RS, Martins BC, Martins GC, et al. **Advances in diagnosis and management of intracranial and spinal meningiomas in dogs and cats.** *Rev Port Cienc Vet* 2015; 110: 172–180.
- 4 Gallager JG, Berg J, Knowles KE, et al. **Prognosis after surgical excision of cerebral meningiomas in cats: 17 cases (1986–1992).** *J Am Vet Med Assoc* 1993; 203: 1437–1440.
- 5 Millesi M, Kiesel B, Mischkulnig M, et al. **Analysis of the surgical benefits of 5-ALA-induced fluorescence in intracranial meningiomas: experience in 204 meningiomas.** *J Neurosurg* 2016; 125: 1408–1419.
- 6 Kaneko S and Kaneko S. **Fluorescence-guided resection of malignant glioma with 5-ALA.** *Int J Biomed Imaging* 2016; Article ID 6135293. DOI: 10.1155/2016/6135293.
- 7 Motekallemi A, Jeltema HR, Methemaekers JD, et al. **The current status of 5-ALA fluorescence-guided resection of intracranial meningiomas – a critical review.** *Neurosurg Rev* 2015; 38: 619–628.
- 8 Wachowska M, Muchowicz A, Firczuk M, et al. **Aminolevulinic acid (ALA) as a prodrug in photodynamic therapy of cancer.** *Molecules* 2011; 16: 4140–4164.
- 9 Ishizuka M, Abe F, Sano Y, et al. **Novel development of 5-aminolevulinic acid (ALA) in cancer diagnoses and therapy.** *Int Immunopharmacol* 2011; 11: 358–365.
- 10 Nokes B, Apel M, Jones C, et al. **Aminolevulinic acid (ALA): photodynamic detection and potential therapeutic applications.** *J Surg Res* 2013; 181: 262–271.
- 11 Yamashita M, Osaki T, Sunden Y, et al. **Photodynamic detection of a canine glioblastoma using 5-aminolevulinic acid.** *J Small Anim Pract.* Epub ahead of print 23 October 2018. DOI: 10.1111/jsap.12947.
- 12 Osaki T, Yokoe I, Sunden Y, et al. **Efficacy of 5-aminolevulinic acid in photodynamic detection and photodynamic therapy in veterinary medicine.** *Cancers (Basel)* 2019; 11: 495. DOI: 10.3390/cancers11040495.
- 13 Gordon LE, Thacher C, Matthiesen DT, et al. **Results of craniotomy for the treatment of cerebral meningioma in 42 cats.** *Vet Surg* 1994; 23: 94–100.
- 14 Niebauer GW, Dayrell-Hart BL and Speciale J. **Evaluation of craniotomy in dogs and cats.** *J Am Vet Med Assoc* 1991; 198: 89–95.
- 15 Stummer W, Pichlmeier U, Meinel T, et al. **Fluorescence-guided surgery with 5-aminolevulinic acid for resection of malignant glioma: a randomised controlled multicentre phase III trial.** *Lancet Oncol* 2006; 7: 392–401.
- 16 Hefti M, Mehdorn HM, Albert I, et al. **Fluorescence-guided surgery for malignant glioma: a review on aminolevulinic acid induced protoporphyrin IX photodynamic diagnostic in brain tumours.** *Curr Med Imaging Rev* 2010; 6: 254–258.
- 17 Della Puppa A, Rustemi O, Giofrè G, et al. **Predictive value of intraoperative 5-aminolevulinic acid-induced fluorescence for detecting bone invasion in meningioma surgery.** *J Neurosurg* 2014; 120: 840–845.
- 18 Valdes PA, Bekelis K, Harris BT, et al. **5-Aminolevulinic acid-induced protoporphyrin IX fluorescence in meningioma: qualitative and quantitative measurements in vivo.** *Neurosurgery* 2014; 10: 74–83.
- 19 Yagi R, Kawabata S, Ikeda N, et al. **Intraoperative 5-aminolevulinic acid-induced photodynamic diagnosis of metastatic brain tumours with histopathological analysis.** *World J Surg Oncol* 2017; 15: 179. DOI: 10.1186/s12957-017-1239-8.
- 20 Johansson A, Faber F, Kniebühler G, et al. **Protoporphyrin IX fluorescence and photobleaching during interstitial photodynamic therapy of malignant gliomas for early treatment prognosis.** *Lasers Surg Med* 2013; 45: 225–234.