



---

## **Invasive nasal histiocytic sarcoma as a cause of temporal lobe epilepsy in a cat**

Authors: Santifort, Koen M, Jurgens, Ben, Grinwis, Guy CM, Gielen, Ingrid, Meij, Björn P, et al.

Source: Journal of Feline Medicine and Surgery Open Reports, 4(2)

Published By: SAGE Publishing

URL: <https://doi.org/10.1177/2055116918811179>



# Invasive nasal histiocytic sarcoma as a cause of *temporal lobe* epilepsy in a cat

Koen M Santifort<sup>1</sup>, Ben Jurgens<sup>2</sup>, Guy CM Grinwis<sup>2</sup>, Ingrid Gielen<sup>3</sup>, Björn P Meij<sup>4</sup> and Paul JJ Mandigers<sup>4</sup>

*Journal of Feline Medicine and Surgery Open Reports*  
1–6

© The Author(s) 2018

Article reuse guidelines:

sagepub.com/journals-permissions

DOI: 10.1177/2055116918811179

journals.sagepub.com/home/jfmsopenreports

This paper was handled and processed by the European Editorial Office (ISFM) for publication in *JFMS Open Reports*



## Abstract

**Case summary** A 10-year-old neutered female domestic shorthair cat was presented with an acute onset of neurological signs suggestive of a right-sided forebrain lesion, temporal lobe epilepsy and generalised seizure activity. MRI of the head revealed an expansile soft tissue mass in the caudal nasal passages (both sides but predominantly right-sided) involving the ethmoid bone and extending through the cribriform plate into the cranial vault affecting predominantly the right frontal lobe and temporal lobe. Histopathological examination of the tumour revealed a histiocytic sarcoma.

**Relevance and novel information** This is the first report of a cat with clinical signs of temporal lobe epilepsy due to an invasive, histiocytic sarcoma. Histiocytic sarcoma, although rare, should be included in the list of differential diagnoses for soft tissue masses extending through the cribriform plate. Other differential diagnoses are primary nasal neoplasia (eg, adenocarcinoma, squamous cell carcinoma, chondrosarcoma and other types of sarcomas), lymphoma and olfactory neuroblastoma. Temporal lobe epilepsy in cats can be the consequence of primary pathology of temporal lobe structures, or it can be a consequence of pathology with an effect on these structures (eg, mass effect or disruption of interconnecting neuronal pathways).

**Keywords:** Feline epilepsy; temporal lobe epilepsy; histiocytic sarcoma; invasive neoplasm; nasal neoplasia; ethmoid bone; forebrain; complex focal seizures

**Accepted:** 15 October 2018

## Introduction

Although rarely reported, histiocytic sarcomas are a differential diagnosis for nasal cavity masses in cats.<sup>1–4</sup> In feline cases with histiocytic sarcomas, epileptic seizures have not yet been reported in the literature.<sup>1,2,4</sup> This case report describes the clinical findings of temporal lobe epilepsy, MRI characteristics and pathological findings of a histiocytic sarcoma originating from the nasal cavity with extension into the cranial vault of a 10-year-old cat.

## Case description

A 10-year-old neutered female domestic shorthair cat was referred for an acute onset of cluster seizures. More than 10 seizures occurred in the 12 h prior to admission. No abnormalities had been noted by the owner prior to these seizures other than episodic sneezing for 2 weeks.

Clinical signs described by the owners were: abnormal behaviour such as looking around and stopping of current activity; licking; salivation; facial twitching; turning

<sup>1</sup>Veterinary Referral Practice 'de Pietersberg', Oosterbeek, The Netherlands

<sup>2</sup>Faculty of Veterinary Medicine, Department of Pathobiology, Utrecht University, The Netherlands

<sup>3</sup>Faculty of Veterinary Medicine, Ghent University, Belgium

<sup>4</sup>Faculty of Veterinary Medicine, Department of Clinical Sciences of Companion Animals, Utrecht University, The Netherlands

### Corresponding author:

Koen Maurits Santifort MVSc, DVM, Veterinary Referral Practice 'de Pietersberg', Pietersbergseweg 14, Oosterbeek 6862 BV, The Netherlands

Email: koensantifort@gmail.com



Creative Commons Non Commercial CC BY-NC: This article is distributed under the terms of the Creative Commons

Attribution-NonCommercial 4.0 License (<http://www.creativecommons.org/licenses/by-nc/4.0/>) which permits non-commercial use, reproduction and distribution of the work without further permission provided the original work is attributed as specified on the SAGE and Open Access pages (<https://us.sagepub.com/en-us/nam/open-access-at-sage>).

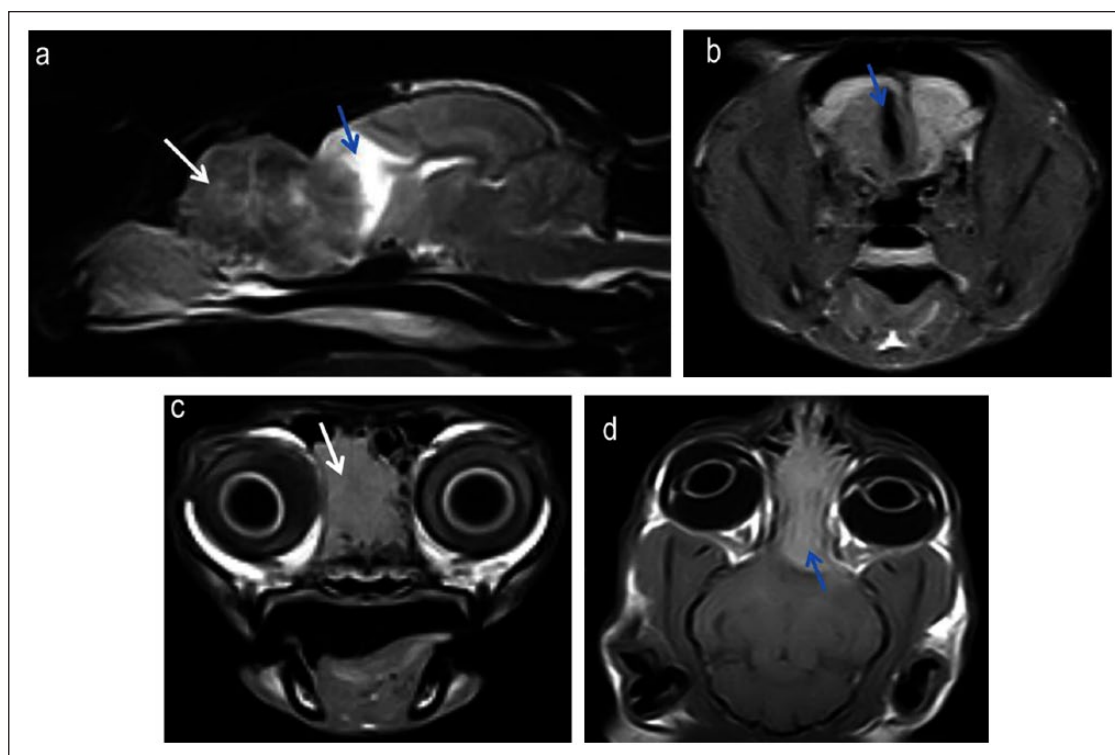
of the head; and at one time also falling and displaying a rigid posture (this was considered to be generalised seizure activity).

Routine physical examination was unremarkable. The cat circled to the right in the consultation room. Incomplete loss of sensation of the left facial area and concave surface of the ear, as well as an absent menace response of the left eye, were noted. After the examination, when the cat was walking freely in the consultation room, it showed clinical signs consistent with earlier seizures, as reported by the owner. Specifically, the cat (chronologically) suddenly looked around as if some stimulus was noted, stopped in mid-walk and stopped sniffing the floor. Then mydriasis, salivation and licking were noted, facial twitching (right facial musculature) became apparent and a head turn (to the right and then left) developed. No signs of generalisation were noted.

These findings, in combination with the results of the neurological examination, were consistent with a fore-brain lesion with right-sided lateralisation. Differential diagnoses considered most likely were neoplastic, vascular and infectious/inflammatory lesions (eg, empyema, *Toxoplasma gondii*, granulomatous lesion secondary to fungal infection).

Laboratory test results (complete blood count and serum biochemistry) revealed no abnormalities except for slightly elevated thyroxine levels (59.9 nmol/l; reference interval 13–52 nmol/l). Treatment was limited to intramuscular administration of midazolam to counter epileptic activity. Anaesthesia for MRI consisted of pre-medication with 0.15 mg/kg intravenous (IV) methadone, and induction was established with an IV infusion of propofol at 4 mg/kg. The cat was intubated, placed on mechanical ventilation and anaesthesia was maintained with a mixture of isoflurane and oxygen.

MRI of the head revealed an expansile soft tissue mass of about 3 cm in length in the caudal nasal passages (both sides, but predominantly right-sided) involving the ethmoid bone and extending through the cribriform plate into the cranial cavity affecting predominantly the right frontal lobe and temporal lobe and invading the skull (Figure 1a). A mass effect on the right frontal lobe, the right temporal lobe and right lateral ventricle was present. T2-weighted fluid-attenuated inversion recovery images showed suppression of a hyperintense area in the mass seen on T2-weighted MRI, which was hypointense on T1-weighted MRI (Figure 1b). These findings are consistent with a cystic component. Destruction of nasal

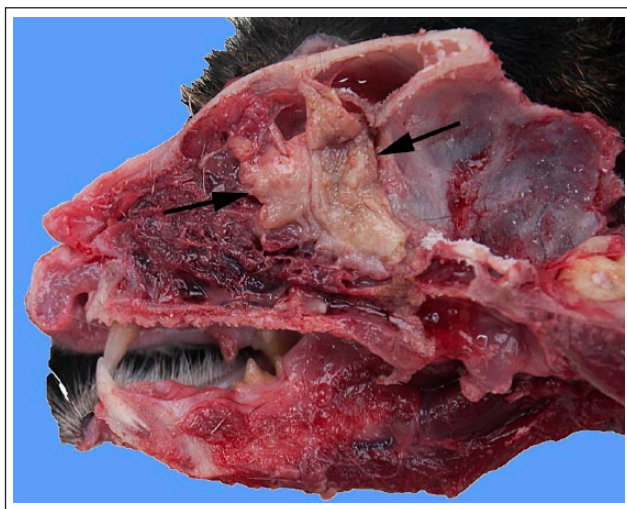

**Figure 1** (a) Sagittal T2-weighted MRI shows a heterogeneous hyperintense mass (white arrow) within the right caudal nasal passage. A hyperintense area is present within the calvarium (blue arrow). (b) On the transverse fluid-attenuated inversion recovery image at the level of the frontal lobes, the cerebrospinal fluid is suppressed (blue arrow). (c) Transverse T1-weighted image at the level of the caudal nasal passages showing the extension of the soft tissue mass and the destruction of nasal turbinates (white arrow). (d) On the dorsal T1-weighted contrast-enhanced image, intense and homogeneous contrast enhancement of the mass is apparent (blue arrow)

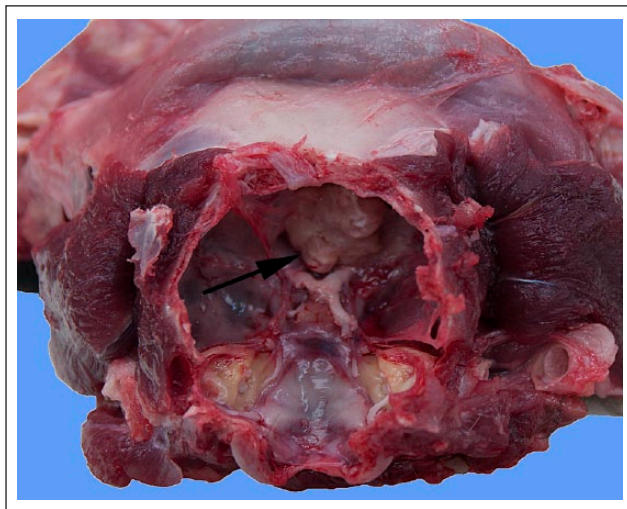
turbinates was extensive (Figure 1c). The mass showed marked and homogeneous enhancement after IV administration of gadolinium (0.1 mmol/kg; Figure 1d).

Based on the MRI findings, the differential diagnosis list was narrowed down to primary nasal neoplasia (eg, adenocarcinoma, squamous cell carcinoma, chondrosarcoma and other types of sarcomas), lymphoma and olfactory neuroblastoma. Primary intracranial neoplasms were also considered but deemed less likely. After discussing all treatment options, the owners elected euthanasia and the cat was submitted for necropsy.

Macroscopic evaluation revealed an irregular-shaped mass of 2 cm × 2.5 cm × 4 cm of friable, white-yellow



**Figure 2** Sagittal view of the cranium and nasal passages including the mass. Note the extension through the cribriform plate as evident in Figure 1. The neoplastic mass is indicated by the arrows



**Figure 3** Caudal view of the cranium including the mass. The arrow indicates the protruding neoplastic tissue

tissue at the dorsal nasal concha extending into ethmoid turbinates and ethmoid bone and protruding into the cranial cavity (Figures 2 and 3). Thus, it was morphologically extensive from the nasal cavity into the cranial cavity.

Histologically, the intranasal and intracranial mass was characterised by an infiltrative neoplastic proliferation of pleomorphic mesenchymal cells with a rounded-to-polygonal or somewhat spindle morphology. The growth pattern varied from sheets to bundles with occasional whirling around blood vessels. Several large, scattered multinucleated neoplastic cells were noted with atypical large nuclei. The mitotic rate was variable but low (1 per × 400 high-power field). The neoplastic cells contained a variable amount of pale, slightly eosinophilic cytoplasm and the cytoplasm of some neoplastic cells contained nuclear structures and remnants suggestive of nuclei of neutrophils (Figure 4). Within the neoplastic area, a marked inflammatory infiltrate consisting of neutrophils, lymphocytes and plasma cells was also noted.

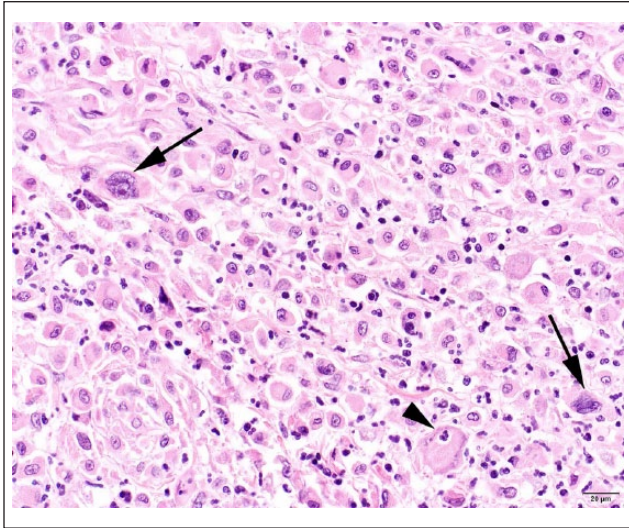
After staining with an antibody against ionised calcium binding adaptor molecule (IBA1),<sup>5</sup> a marker for cells of histiocytic lineage, the neoplastic cell population showed marked immunoreactivity (Figure 5). In addition, to analyse the nature of the lesion, immunohistochemistry for cytokeratin and glial fibrillary acidic protein (GFAP), as well as the histochemical stains, periodic acid–Schiff (PAS) and Fite-Faraco (acid-fast stain) were performed. The neoplastic cells were negative for cytokeratin and GFAP, and no infectious agents were noted in the PAS and Fite-Faraco stains.

## Discussion

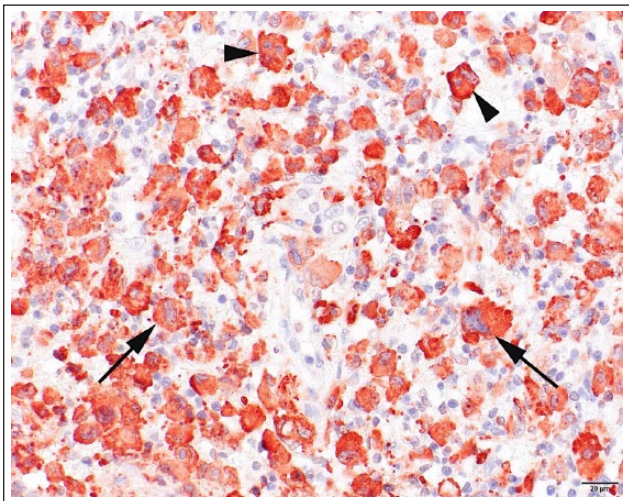
Feline seizures can be caused by idiopathic and structural epilepsy or metabolic/toxic disturbances of normal brain function (reactive seizures).<sup>6–9</sup> A recent study revealed that cats older than 7 years at seizure onset are at a four times greater risk of suffering from structural epilepsy than idiopathic epilepsy.<sup>6</sup> Therefore, in this case, idiopathic epilepsy was considered less likely, as both signalment (10-year-old cat) and abnormal findings in the neurological examination findings pointed towards a structural cause of the seizures. Abnormal findings upon neurological examination are a risk factor for structural lesions; cats with abnormal findings are three times more likely to have structural epilepsy than idiopathic epilepsy.<sup>6–9</sup>

Temporal lobe epilepsy is regarded a specific type of focal epileptic seizures and signs characteristic in cats in clinical, as well as research, settings are: (1) attention response; (2) arrest; (3) salivation, licking (orofacial automatisms); (4) facial twitching; (5) head turning or nodding; and, in cases where generalisation occurs, (6) generalised clonic convulsions, although other signs of





**Figure 4** Histological picture of the histiocytic sarcoma. Large atypical cells with large atypical nuclei are visible (arrows), as well as phagocytosis of a neutrophilic granulocyte (arrowhead). Haematoxylin and eosin,  $\times 40$  objective



**Figure 5** Immunohistochemistry of the histiocytic sarcoma with prominent membranous and cytoplasmic immunoreactivity in the neoplastic cells. Arrows indicate large atypical neoplastic cells with large atypical nuclei, and the arrowheads indicate multinucleated cells. Ionised calcium binding adaptor molecule immunohistochemistry, objective  $\times 40$

autonomic involvement (eg, mydriasis, urination) and behavioural abnormalities (eg, vocalisation) may also be noted.<sup>8–10</sup> Stages 1–5 (especially orofacial automatisms) can be considered characteristic for temporal lobe seizures.<sup>8,10</sup> In research settings, these characteristics have been correlated to stages of evolution of epileptic seizures that were induced in specific temporal lobe regions.<sup>10</sup> In this (clinical) case all the characteristic features were observed at home and at one point signs of

generalisation were also noted by the owner. Another term that has been used to describe this type of seizure (excluding generalisation) is ‘complex partial (cluster) seizures’, but the term complex has been discarded in a recent consensus report on epilepsy terminology and the term ‘focal’ is now preferred over ‘partial’.<sup>8,11</sup> An article on complex focal cluster seizures in cats devotes a large part of the discussion to the role of the temporal lobe structures in these seizures.<sup>8</sup>

Generalisation is not characteristic of temporal lobe epilepsy and occurs with all seizures that encompass hypersynchronous electrical activity in both cerebral hemispheres.<sup>11</sup> The term ‘kindling’ (or recruitment) has been used to describe the progressive involvement of more distant brain structures.<sup>10</sup> Factors influencing the pathophysiological epileptogenic processes involved in generalisation in conjunction with temporal lobe seizures and how this takes place are a matter of discussion.<sup>7–11</sup> The presence of features consistent with generalisation, while not characteristic of temporal lobe epilepsy, does not exclude the epileptic event to be of a temporal lobe origin; it has been observed in experimental settings where temporal lobe structures were the site of epileptogenesis.<sup>10</sup>

The characteristic features (stages 1–5, as defined in experimental setting, especially orofacial automatisms) of a seizure event are what points to the temporal lobe as the site of origin.<sup>10</sup> Clinically, these features might be used to corroborate the use of the term ‘temporal lobe epilepsy’ in cats. This is akin to the use of other characteristic neurological features in the examination to pinpoint a neurolocalisation (eg, hypermetric ataxia with intention tremors fits a cerebellar localisation). In this case, therefore, temporal lobe epilepsy was tentatively diagnosed, and in the light of the clinical findings, a structural lesion in the right forebrain was suspected to be the underlying cause. The only other sign reported to have been present before seizures developed in this case, was episodic sneezing, a common feature of intranasal neoplasia.<sup>1–3,12–14</sup>

Preferred diagnostic imaging modalities for identification of intracranial neoplasia are MRI and CT, of which MRI is preferred, although in cases of bony involvement CT will provide better visualisation of mass lesions in frontonasal regions.<sup>3,13,15–17</sup> In this case, MRI was elected and we observed an extra-axial space-occupying lesion in the nasal and intracranial cavity, with involvement of the ethmoid bone/cribriform plate consistent with disruption of the normal anatomy of nasal cavity and paranasal sinuses.<sup>18</sup>

The differential diagnoses for mass lesions with a large intranasal component, as well as an intracranial component, are primary nasal neoplasia (eg, adenocarcinoma, squamous cell carcinoma, chondrosarcoma and other types of sarcomas), lymphoma and olfactory

neuroblastoma.<sup>1,2,4,12,14,16,17</sup> Granulomas are considered a non-neoplastic differential diagnosis (ie, it is an inflammatory process with several possible aetiologies, including autoimmune disease, corpora aliena, bacterial infection and fungal infection).<sup>19,20</sup> Primary nasal tumours are reported to invade the intracranial cavity, although not many are associated with seizure activity.<sup>1–4,16,21,22</sup>

Primary brain tumours (eg, meningioma, glioma) are also to be considered as differential diagnoses.<sup>4,12,17,23,24</sup> Meningioma is the most prevalent primary brain tumour in cats (mean age of about 12 years).<sup>4,16,17,25–27</sup> Extracranial extension of a feline meningioma has been described.<sup>21</sup> Invasion of the nasal cavity, however, has not yet been described for any feline primary brain tumour. In this case, classical imaging characteristics of meningiomas in cats were absent.<sup>15,26</sup>

In the present case, a histiocytic sarcoma was diagnosed based on the morphological and immunohistochemical characteristics of the neoplastic cells. Although IBA1 immunoreactivity can also be seen in microglia cells, we decided that the neoplasm in this cat is a histiocytic sarcoma because the neoplasm, most likely, originated in the nasal region and subsequently infiltrated the cranial vault and the nervous tissue. Furthermore, the morphology of the neoplastic cells was different from the morphological characteristics described for microglial tumours.<sup>28,29</sup> Additional immunophenotyping for histiocytic cells was not performed because of the convincing staining for IBA1 and the morphology of the neoplastic cells. To evaluate a meningeal or (macro)glial origin of the neoplastic cells, GFAP and cytokeratin immunohistochemistry was performed, but neither antibody yielded any immunoreactivity in the neoplastic cells. The mitotic index in histiocytic sarcomas is reported to be variable but usually high.<sup>30</sup> In this case, it was low, as was the case in the only other report of a feline nasal histiocytic sarcoma.<sup>31</sup>

Histiocytic sarcomas in the nasal cavity of cats are rare; only one report describes a histiocytic sarcoma in the nasal cavity of a cat.<sup>31</sup> There are no reports of primary intracranial histiocytic sarcomas or nasal histiocytic sarcomas invading the cranial vault in the cat.<sup>4,30</sup> There are reports on histiocytic sarcomas with central nervous system involvement in dogs.<sup>32</sup> Cytological characteristics of histiocytic sarcomas include pleomorphic histiocytes, and both mononuclear and multinucleated giant cells. Marked cytological atypia is often noted.<sup>30</sup> In dogs, they have been reported to be associated with epileptic seizures and carry a poor prognosis due to very malignant behaviour.<sup>30,32</sup>

In general, treatment options for nasal and/or intracranial neoplasia include surgery, chemotherapy, radiotherapy, immunotherapy, cryotherapy and palliative medical therapy, or a combination thereof, obviously depending on the type of neoplasm.<sup>1,4,12,21,26,27</sup> Advances in surgical

technique (also in nasal regions) have improved survival times, cosmetically acceptable outcomes and quality of life in patients.<sup>3,13,26,33</sup> If epileptic seizures are present, antiepileptic medication is advised to control seizure activity.<sup>7–9,26</sup> However, treatment options for histiocytic sarcomas in cats have not been evaluated and are very limited in dogs. The prognosis for animals with histiocytic sarcomas, especially when intracranial involvement is present, is very poor.

## Conclusions

To the best of our knowledge, this is the first report of a cat with clinical signs of temporal lobe epilepsy and generalised seizure activity due to an invasive, histiocytic sarcoma. Temporal lobe epilepsy in cats can be the consequence of primary pathology of temporal lobe structures or it can be a consequence of pathology with an effect on these structures.

**Acknowledgements** The authors would like to thank HJ Dekker (DVM) of Veterinary Clinic Den Ham, The Netherlands, for acquisition of the magnetic resonance images.

**Conflict of interest** The authors declared no potential conflicts of interest with respect to the research, authorship, and/or publication of this article.

**Funding** The authors received no financial support for the research, authorship, and/or publication of this article.

## References

- 1 Malinowski C. **Canine and feline nasal neoplasia.** *Clin Tech Small Anim Pract* 2006; 21: 89–94.
- 2 Mukaratirwa S, van der Linde-Sipman J and Gruys E. **Feline nasal and paranasal sinus tumours: clinicopathological study, histomorphological description and diagnostic immunohistochemistry of 123 cases.** *J Feline Med Surg* 2001; 3: 235–245.
- 3 Weeden A and Degner D. **Surgical approaches to the nasal cavity and sinuses.** *Vet Clin North Am Small Anim Pract* 2016; 46: 719–733.
- 4 Troxel M, Vite C, Van Winkle T, et al. **Feline intracranial neoplasia: retrospective review of 160 cases (1985–2001).** *J Vet Intern Med* 2003; 17: 850–859.
- 5 Pierezan F, Mansell J, Ambrus A, et al. **Immunohistochemical expression of ionized calcium binding adapter molecule 1 in cutaneous histiocytic proliferative, neoplastic and inflammatory disorders of dogs and cats.** *J Comp Pathol* 2014; 151: 347–351.
- 6 Stanciu G, Packer R, Pakozdy A, et al. **Clinical reasoning in feline epilepsy: which combination of clinical information is useful?** *Vet J* 2017; 225: 9–12.
- 7 Pakozdy A, Leschnik M, Sarchahi A, et al. **Clinical comparison of primary versus secondary epilepsy in 125 cats.** *J Feline Med Surg* 2010; 12: 910–916.
- 8 Pakozdy A, Gruber A, Kneissl S, et al. **Complex partial cluster seizures in cats with orofacial involvement.** *J Feline Med Surg* 2011; 13: 687–693.

- 9 Pakozdy A, Halasz P and Klang A. **Epilepsy in cats: theory and practice.** *J Vet Intern Med* 2014; 28: 255–263.
- 10 Kitz S, Thalhammer JG, Glantschnigg U, et al. **Feline temporal lobe epilepsy: review of the experimental literature.** *J Vet Intern Med* 2017; 31: 633–640.
- 11 Berendt M, Farquhar RG, Mandigers PJ, et al. **International veterinary epilepsy task force consensus report on epilepsy definition, classification and terminology in companion animals.** *BMC Vet Res* 2015; 28: 182. DOI:10.1186/s12917-015-0461-2.
- 12 Söffler C, Hartmann A, Gorgas D, et al. **Magnetic resonance imaging features of esthesioneuroblastoma in three dogs and one cat.** *Tierarztl Prax Ausg K Kleintiere Heimtiere* 2016; 44: 333–340.
- 13 Worley D. **Nose and nasal planum neoplasia, reconstruction.** *Vet Clin North Am Small Anim Pract* 2016; 46: 735–750.
- 14 Lubojemska A, Borejko M, Czapiewski P, et al. **Of mice and men: olfactory neuroblastoma among animals and humans.** *Vet Comp Oncol* 2014; 14: e70–e82.
- 15 Kneissl SM, Fuchs-Baumgartinger A, Gloesmann M, et al. **Correlation of diagnostic imaging and necropsy findings in intracranial meningiomas in dogs and cats.** *Wien Tierarztl Monatsschr* 2014; 101: 50–57.
- 16 Tomek A, Cizinauskas S, Doherr M, et al. **Intracranial neoplasia in 61 cats: localisation, tumour types and seizure patterns.** *J Feline Med Surg* 2006; 8: 243–253.
- 17 Troxel M, Vite C, Massicotte C, et al. **Magnetic resonance imaging features of feline intracranial neoplasia: retrospective analysis of 46 cats.** *J Vet Intern Med* 2004; 18: 176–189.
- 18 Conchou F, Sautet J, Raharison F, et al. **Magnetic resonance imaging of normal nasal cavity and paranasal sinuses in cats.** *Anat Histol Embryol* 2011; 41: 60–67.
- 19 Chawla P, Cook L, Himmell L, et al. **Coextensive meningioma and cholesterol granuloma in the forebrain of a cat.** *J Vet Intern Med* 2015; 29: 1638–1642.
- 20 Pfohl JC and Dewey CW. **Intracranial *Toxoplasma gondii* granuloma in a cat.** *J Feline Med Surg* 2005; 7: 369–374.
- 21 Karli P, Gorgas D, Oevermann A, et al. **Extracranial expansion of a feline meningioma.** *J Feline Med Surg* 2013; 15: 749–753.
- 22 Smith MO, Turrel JM, Bailey CS, et al. **Neurologic abnormalities as the predominant signs of neoplasia of the nasal cavity in dogs and cats: seven cases (1973–1986).** *J Am Vet Med Assoc* 1989; 195: 242–245.
- 23 Rissi D and Miller A. **Feline glioma: a retrospective study and review of the literature.** *J Feline Med Surg* 2017; 19: 1307–1314.
- 24 Vanhaesebrouck A, Posch B, Baker S, et al. **Temporal lobe epilepsy in a cat with a pyriform lobe oligodendroglioma and hippocampal necrosis.** *J Feline Med Surg* 2012; 14: 932–937.
- 25 Forterre F, Tomek A, Konar M, et al. **Multiple meningiomas: clinical, radiological, surgical, and pathological findings with outcome in four cats.** *J Feline Med Surg* 2007; 9: 36–43.
- 26 Motta L, Mandara M and Skerritt G. **Canine and feline intracranial meningiomas: an updated review.** *Vet J* 2012; 192: 153–165.
- 27 Sessums K and Mariani C. **Intracranial meningioma in dogs and cats: a comparative review.** *Compend Contin Educ Vet* 2009; 31: 330–339.
- 28 Koestner A, Bilzer T, Fatzer R, et al. **Histological classification of tumors of the nervous system of domestic animals.** In: World Health Organization international histological classification of tumors of domestic animals. Washington, DC: Armed Forces Institute of Pathology, 1998, pp 1–71.
- 29 Summers BA, Cummings JF and De Lahunta A. **Tumors of the central nervous system.** In: Summers BA, Cummings JF and De Lahunta A (eds). *Veterinary neuropathology*. St Louis, MO: Mosby, 1995, pp 351–401.
- 30 Moore PF. **A review of histiocytic diseases of dogs and cats.** *Vet Pathol* 2014; 51: 167–184.
- 31 Wong VM, Snyman HN, Ackerley C, et al. **Primary nasal histiocytic sarcoma of macrophage-myeloid cell type in a cat.** *J Comp Pathol* 2012; 147: 209–213.
- 32 Mariani CL, Jennings MK, Olby NJ, et al. **Histiocytic sarcoma with central nervous system involvement in dogs: 19 cases (2006–2012).** *J Vet Intern Med* 2015; 29: 607–613.
- 33 Cameron S, Rishniw M, Miller A, et al. **Characteristics and survival of 121 cats undergoing excision of intracranial meningiomas (1994–2011).** *Vet Surg* 2015; 44: 772–776.